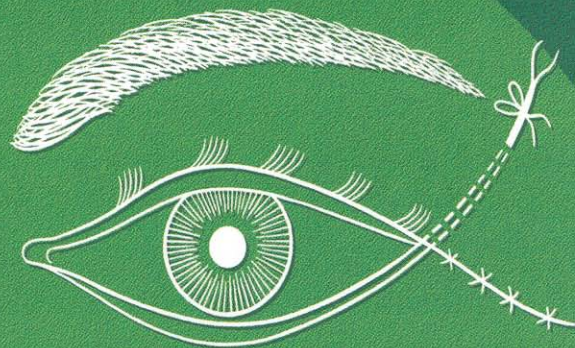



# *Surgical Reconstruction & Rehabilitation in Leprosy and other Neuropathies*

---

*Richard Schwarz* MD, FRCS  
*Wim Brandsma* RPT, PhD



*Surgical Reconstruction &  
Rehabilitation in Leprosy  
and other Neuropathies*

Richard Schwarz  
Wim Brandsma

**EKTA BOOKS**

Kathmandu, Nepal

First published in 2004

Distribution Information

**Ekta Books Distributors Pvt. Ltd.**

GPO Box 6445, Thapathali

Kathmandu, Nepal

e-mail: [info@ektabooks.com](mailto:info@ektabooks.com)

<http://www.ektabooks.com>

Copyright © Reserved 2004

All Rights Reserved. No part of this book may be reproduced in any form, by photocopying or by and electronic or mechanical means, including information storage or retrieval system, without permission in writing from both the author and the publisher of this book.

Artwork : *Kishor Joshi*

Layout : *Shyam K. Dongol*

**ISBN 99933-1-371-8**

Printed in Nepal

At *Monaj Offset Press Pvt. Ltd.*, Kathmandu





**Dedicated to the Memory of  
Dr. PAUL BRAND  
(1914-2003)**

*Dr. Paul Brand in the early nineteen fifties researched the pathogenesis of deformity in leprosy. Dr. Brand was the 'advocate' that most impairments and deformities in leprosy are the results of nerve function impairment and that these impairments could, to a large extent, be prevented and corrected. They are not an inevitable result of the disease. His research covered areas such as the aetiology and treatment of plantar ulceration, the pattern of nerve function impairment, and surgical techniques to reconstruct paralytic deformities. From the pioneering days onwards he also emphasised that the rehabilitation of leprosy affected persons was teamwork. He trained his own technicians at the time when qualified therapists were not available. Above all, he was also the physician that would look beyond the visible physical impairments and would treat each patient with the respect and love he felt they should receive. His approach and attitude to leprosy affected persons was holistic. It is with great gratitude that we dedicate this book to his memory.*

## Editors

**Richard J. Schwarz, MD, FRCS.** He started work in leprosy as the reconstructive surgeon at Anandaban Hospital, Kathmandu, Nepal from 1996-1998. He has worked as the reconstructive surgeon at Green Pastures Hospital and Rehabilitation Center, Pokhara, Nepal since 1998 and as the medical superintendent since 2002.

**J. Wim Brandsma, physiotherapist, PhD.** He first joined leprosy work in 1973 in Uganda, Kumi Leprosy Centre. From 1977-1983 and 1986-1989 he was based at the All Africa Leprosy and Rehabilitation Training Centre (ALERT), Addis Ababa, Ethiopia. During 1983-1986 he was a rehabilitation research consultant at the National Hansen's Disease Centre in the USA (Head Dr. Paul Brand). From 1990 until 1998 he was a research associate with the Dutch National Institute for Allied Health (NPI, Amersfoort, Netherlands). From 1998, he has been a rehabilitation consultant in India (Karigiri Leprosy Research and Training Centre, Tamil Nadu, India) and Nepal, Green Pastures Hospital and Rehabilitation Centre. In 1993 he obtained his PhD: "Intrinsic Minus Hand: Pathokinesiology, Reconstruction and Rehabilitation".

# Contributors

**J. Wim Brandsma**, RPT, PhD. Physiotherapist, consultant rehabilitation, Green Pastures Hospital and Rehabilitation Centre, Pokhara, Nepal.

**Wim H. van Brakel**, MD, MSc, PhD. Epidemiologist, Consultant Leprosy and Tuberculosis, Royal Tropical Institute (KIT), Amsterdam, The Netherlands. Former Research Coordinator, The Leprosy Mission International, New Delhi.

**G. Chauhan**, MS Orthopaedics. Orthopedic Surgeon, Vimala Dermatological Centre, Mumbai, India.

**Hugh Cross**, PhD. Podiatrist. Rehabilitation consultant, American Leprosy Missions, Cebu, Phillipines. Former Orthotic Consultant and Medical Director, Lalgadh Leprosy Hospital, Lalgadh, Nepal.

**Frank Duerksen**, MD, FRCS. Orthopaedic Surgeon. Associate Professor of Surgery, University of Manitoba - Chief Orthopaedic Hand Surgery Program - Former Consultant in Rehabilitation to American Leprosy Missions.

**M. Ebenezer**. Orthopaedic Surgeon. Chief of Surgery, Schieffelin Leprosy Research and Training Centre, Karigiri, Tamil Nadu, India.

**Paul E. Gravem**, Plastic Surgeon, Haukeland University Hospital, Bergen, Norway. Former Plastic Surgeon and Head of Department of Surgery, ALERT, Addis Ababa, Ethiopia.

**Friedbert Herm**, MD, Former Rehabilitation Physician and Medical Superintendent, Green

Pastures Hospital and Rehabilitation Center, Pokhara, Nepal.

**Jerry Joshua**, MS, MCh (plastics). Plastic and Reconstructive Surgeon, The Leprosy Mission Trust India, Premananda Memorial Leprosy Hospital, Kolkata.

**Mark R.C. Macdonald**, MBBS. Surgeon, Medical Superintendent, Anandaban Leprosy Hospital, Kathmandu, Nepal.

**G.N. Malaviya**, MB, MS, MSc, DHRM. Head, Reconstructive Surgery Unit, Central JALMA Institute for Leprosy, Agra, India.

**Sarah Meanly**. BSc, MSc, PhD, Prosthetist /Orthotist, West Midlands Rehabilitation Centre, Birmingham, England. Former Appliances Design Technologist, Green Pastures Hospital and Rehabilitation Centre, Pokhara, Nepal.

**Hamilton da Rosa Pereira**, MD, PhD. Professor Department of Orthopedics. School of Medicine. UNESP-Botucatu - SP, Brazil.

**Bruce Richard**, MS, FRCS (Plast). Consultant Plastic Surgeon, Birmingham Children's Hospital, England. Former Reconstructive Surgeon, Green Pastures Hospital and Rehabilitation Center, Pokhara, Nepal.

**Antonio Salafia**, MBBS, Dip. Hand Surgery and Microsurgery. Hand Surgeon, Chief of Reconstructive Surgery Vimala Dermatological Centre, Mumbai, India.

**Richard J. Schwarz, MD, FRCS.** Reconstructive Surgeon, Acting Medical Superintendent, Green Pastures Hospital and Rehabilitation Center, Pokhara, Nepal.

**H. Srinivasan, MBBS., FRCS, FRCS Ed.** Former Senior Orthopaedic Surgeon, Central Leprosy Teaching & Research Institute, Chengalpattu (South India); Director, Central JALMA Institute for Leprosy (ICMR), Agra, India.

**Marcos Virmond, MD, PhD.** Plastic surgeon. Professor, University of the Sacred Heart. Director, Instituto Lauro de Souza Lima, Bauru-SP, Brazil.

**Cornelis Visser, BSc, Prosthetist /Orthotist.** Consultant P&O, Green Pastures Hospital and Rehabilitation Center, Pokhara, Nepal.

**Grace Warren, MD, MS, FRCS, FRACS.** International Consultant in Leprosy and Rehabilitation Surgery. Former Advisor in Leprosy and Reconstructive surgery for The Leprosy Mission. Former Medical Superintendent and Surgeon at Hong Kong Government Leprosarium.

# Foreword

I deem it a great honor to have been invited to contribute a foreword for this book on the management and prevention of disability resulting from leprosy.

The non-dermatological manifestations of leprosy had received little or no recognition before the pioneering research of the late Dr. Paul Brand and his associates and disciples. That the nerves were an important target structure for the mycobacterium leprosy was known; but it was Dr Brand who pointed out and directed the attention of the medical world to the need of protecting nerves from the effects of damage to the hands and feet of patients.

Both the authors have a wide experience in the management of nerve involvement in leprosy in many countries and ethnic groups, and are eminently qualified to present this book to those involved in the care of these patients.

But why should we still need such a book when WHO and the general public are being told that leprosy is no longer a public health hazard? I remember the wise words of Dr. Cap, a Belgian pioneer in the control of leprosy during the preceding 3-4 decades of the twentieth century. I quote from my memory: "The best way to control leprosy is to stop looking for new cases". And that is exactly what we have

been doing! Total population surveys have been discontinued. Random area surveys have revealed that the incidences of new cases have shown no significant reduction. To pull out of the field the trained leprosy control workers at this stage is to invite a return to the situation as it was in the mid forties. Hence, this book is still appropriate and needed in spite of claims that the battle has been won.

This book has been written by professionals with wide experience in their special fields and its wisdom is intended for general application wherever leprosy is still prevalent as part of a general service. This book is offered to those who have to cope with the still active pandemic of leprosy in the whole developing world.

I congratulate its authors and wish the book all success.

**Dr. EF Fritschi**  
Surgeon

**(Retired) Formerly**  
Director Schieffelin  
Leprosy Research and Training Centre, Karigiri,  
Tamil-Nadu India,  
and Chief of Surgery and Rehabilitation  
All Africa Leprosy and Rehabilitation Training  
Centre (ALERT), Addis Ababa, Ethiopia



# Foreword

The issue of rehabilitation, i.e. enablement of the 'disabled' due to leprosy is today very topical. The infection is on the verge of being fully contained. However the number of disabled leprosy affected persons is staggering. In India there are around 200 thousand such persons even though cured of the disease. About 4 to 8 thousand disabled are being added to this figure every year, even now. They demand restoration of the lost function to the extent possible as also prevention of its worsening by surgical and other means. A book on this subject is very much needed today.

There are many books on this subject starting with the book titled "Surgical Reconstruction and Rehabilitation in Leprosy" by Ernest P. Fritschi in 1971. The present book has a very broad scope and successfully brings up to date our knowledge on this subject. The timing is right because the treatment of leprosy-affected persons is slowly being integrated into the general health stream from an exclusive vertical set up it had before. Such a book is urgently needed for the general health system.

This multi-authored book is the result of the enthusiasm and intense diligence of the young general surgeon, Richard Schwarz. After starting to work exclusively for persons affected with leprosy at Pokhara-Nepal, he meticulously studied all the available literature on this subject and made efforts to interact individually with the workers in this field. Wim Brandsma has extensive experience in the rehabilitation of leprosy patients and his writing and editing skills have served this book well. They felt the need of updating the knowledge,

theory and practice of surgical and associated measures available today for the reablement of persons affected by disabilities secondary to peripheral nerve paralysis and tissue destruction caused by the disease leprosy. They have succeeded very well indeed.

Most of the authors are young professionals, like general, orthopedic, and plastic surgeons, podiatrists, and prostheticians, who have come from different disciplines to work in this branch of medicine, not lucrative financially but very satisfying in scientific and humane terms. The two stalwarts and senior surgeons, Grace Warren and H. Srinivasan give us authoritative chapters on the Neuropathic Foot and the Management of Ulcers respectively.

It all started nearly 60 years ago with Dr. Paul Brand, who initiated and continued throughout his life to constantly better understand and propagate the theory and practice of surgery and other measures to treat the disabilities of persons affected by leprosy. He trained directly and indirectly, through the force of his personality and publications, a number of surgeons and other workers to enter and enrich this field all over the world. Simultaneously, a number of French surgeons and other workers in the French speaking nations in Africa and Asia were contributing to the evolution of our knowledge.

Understanding evolved slowly with major contributions in pathomechanics, biomechanics, neurology and surgical methods by Paul Brand, Landsmeer, Srinivasan, Bourrel, Carayon and others. The latest contribution,

from a podiatrist, is on biomechanics of the foot and provision of simple orthotic devices that are of great value in prevention of plantar ulcers and their recurrence. I am glad that this has been included in this book. This knowledge needs to be widely applied.

I hope this book will be widely used in medical colleges and by general health systems everywhere, particularly in countries like India, Brazil and others where there are a large numbers of persons cured of the disease but left with persistent disabilities secondary to leprosy.

**Dinkar D. Palande**

Surgeon (retired)

Formerly Sacred Heart Leprosy Centre

Kumbakonam, Tamil Nadu, India

29th October 2003

# Preface

Over 50 years have now passed since Dr. Paul Brand first began performing reconstructive surgery for persons affected with leprosy. Tens of thousands of persons with impairments have since that time benefited from the development and application of the principles developed by Dr. Brand. Since his pioneering efforts, many surgeons, especially in India, have joined in with new techniques and modifications of old ones, such that we have seen a significant growth in the understanding and breadth of reconstructive surgery for neuropathies. During this time the medical community has recognized that principles and procedures developed for leprosy patients are applicable to persons affected by neuropathies from other etiologies. Surgeons in other fields, especially in reconstructive facial surgery and tendon transfer surgery to correct paralytic deformities, have adopted operations developed and refined by surgeons working with leprosy patients. Techniques such as Total Contact Casting have found wide acceptance in the diabetic medical community for the treatment of plantar ulcers and neuropathic bone disintegration.

During this time the effectiveness and widespread use of multi-drug therapy combined with extensive awareness education has markedly reduced the numbers of leprosy patients presenting with disability. It has not yet resulted in a global decrease in the number of newly diagnosed patients. This is very welcome progress, but in many countries the existing leprosy population with disabilities along with those developing new deformities will

continue to require reconstructive surgical services for years to come. The number of centers where these specialized procedures can be performed has declined over the last two decades. Getting adequate training in the full breadth of procedures developed is becoming more of a challenge. This book was developed with this in mind.

This book is designed for those with some training in reconstructive surgery for peripheral neuropathies, but who have not been exposed to all of the procedures presently available. It was written as a follow-up to Dr. Fritschi's textbook written in 1971 with a second edition in 1984. These books were clearly written with sufficient detail to enable a surgeon with reasonable training to carry out the procedures described. The present textbook has a somewhat different format, and has included new procedures and sections, but the reader will notice many similarities in style and content. This was intended on behalf of the editors. We also wanted to make this a multi-author effort, drawing upon the expertise of experts in the field from around the globe.

In this field it is absolutely essential that the surgeon works closely with a therapist able to educate the patient following reconstructive surgical procedures. As such the book is also designed for therapists, with chapters covering the principles and techniques of pre- and post-operative therapy for neuropathic limbs. The book also contains sections on orthopaedic appliances and prosthesis, but only in sufficient detail to allow the surgeon to have a rea-

sonable understanding of how to choose an appropriate orthosis/ prosthesis and what can be expected of the same.

We would like to express our sincere appreciation to all the authors who contributed chapters to this textbook. All did this taking time out of already busy schedules, and did so at their own expense. As this is the first experience for the editors in editing a multi-author text, we had much to learn during the process. The contributing authors were all patient with us as we learned together throughout the process. Many thanks to Dr. P. Saunderson and the American Leprosy Missions for generously

covering the costs of publishing this book, and to ILEP for helping with the distribution. Thanks as well to Dr. Fritschi for allowing us to use his illustrations. Thanks also to Dr. Paul Brand, who was supportive of the project but unfortunately passed away before he could write the forward to the book.

We would also like to express our appreciation to Mr. Timothy, Shyam Dongol and other staff of EKTA Publishers for their professionalism and advise in helping to bring this book into reality.

**RJS and WB**

# Contents

Topics	Page
1 General Principles of Reconstructive Surgery for Leprosy and other Peripheral Neuropathies – R. Schwarz	1
2 Peripheral Nerve Function Assessment – W. van Brakel	11
3 Surgical Management of Neuritis – B. Richard	25
4 Prevention and Non-surgical Treatment of Common Impairments: An Overview – W. Brandsma	33
5 Functional Anatomy and Assessment of the Hand – W. Brandsma, M. Ebenezer	39
6 Ulnar Nerve Palsy – F. Duerksen, R. Schwarz	47
7 Median Nerve Palsy – R. Schwarz	65
8 Radial Nerve Palsy – R. Schwarz, J. Joshua, G. Warren	83
9 Management of Miscellaneous Conditions in the Paralysed Hand – M. Virmond, H. da Rosa Pereira	97
10 Restoration of Function in a Mitten Hand – G.N. Malaviya, B. Richard	113
11 Use of External Fixators in the Neuropathic Hand – A. Salafia	127
12 Biomechanical Assessment of the Foot – H. Cross	133
13 Neuropathic Feet – G. Warren	147



14	Common Peroneal and Posterior Tibial Nerve Paralysis – <i>M. Macdonald</i>	175
15	Management of Ulcers in Neurologically Impaired Feet – <i>H. Srinivasan</i>	193
16	Role of Flaps and Skin Grafts in the Management of Neuropathic Plantar Ulcers – <i>P.E. Gravem</i>	227
17	Foot Orthotic Therapy – <i>H. Cross</i>	237
18	Squamous Cell Carcinoma and Amputations – <i>R. Schwarz</i>	249
19	Surgery of Facial Palsy in Leprosy – <i>J. Joshua</i>	257
20	Surgery of the Nose and other Aesthetic Surgery – <i>G. Warren</i>	271
21	Pre- and Postoperative Therapy following Tendon Transfer Surgery – <i>W. Brandsma, M. Ebenezer</i>	303
22	Unfavourable Outcomes after Reconstructive Surgery in Leprosy – <i>G.N. Malavya</i>	317
23	Prosthetics and Orthotics in Neuropathy – <i>C. Visser, S. Meanly</i>	327
24	Rehabilitation – <i>F. Herm</i>	343
	<b>● Appendices</b>	355
	A Nerve Function Assessment form: Muscle Testing	357
	B Nerve Function Assessment form: Sensory Testing	358
	C Skin Care / Self care training	359
	D (Removable) Modified Total Contact Cast: TCC	363
	E Trial Walking	372
	F Tendon Transfer Surgery Assessment Form: Eye	374
	G Tendon Transfer Surgery Assessment Form: Hand	375
	H Tendon Transfer Surgery Assessment Form: Foot	378
	I Trns Tibial Amputation Measurement Form	379
	<b>● Indexes</b>	381

# General Principles of Reconstructive Surgery for Leprosy and Other Peripheral Neuropathies

• R. SCHWARZ

In dealing with patients with peripheral neuropathies one must be careful to consider the whole patient and not focus strictly on the nerve deficit presented to the surgeon. Nerve deficits are often multiple, and the urgency of dealing with these deficits differ. In general it is best to listen to the patient as to what their particular needs and priorities are, and to develop a rehabilitative/surgical program in response to these perceived needs. However, patients occasionally have misguided priorities and may need counselling and advice to convince them of the need for certain interventions. For instance, a patient may wish to have their claw hand corrected first for work purposes or social reasons, whereas the surgeon may advise him/her to correct a concomitant lagophthalmos first to prevent corneal ulceration. Similarly a foot drop may seem less of a problem to the patient than a claw hand, yet the former carries a greater risk to the patient and should receive priority.

The attitude and motivation of the patient is focal to the success of therapy or any surgical intervention. Rehabilitative interventions are rarely curative but rather improve function. However continued misuse of the anaesthetic limb can quickly eliminate any benefit the patient received from the surgery. The patient must therefore first understand the care of neuropathic limbs in order to prevent further disability. During this time the patient's attitude to their disease and bodies can be assessed. The patient who will not carry out the simple daily

checks required of a patient with a neuropathic limb is unlikely to gain long-term benefit from a complicated surgical procedure.

Most patients will be very cooperative with therapy, as it is in their self-interest to do so. However some may be more resistant to intervention, as Enna has described.<sup>4</sup> Particularly in leprosy there are patients who have had their deformity for long periods of time and have simply adapted to it. For those living in a leprosy settlement even the stigma of the deformity may be gone and with it the patient's motivation for change. Other patients may have excessive fears of the potential adverse effects of surgery, especially if they know a patient who has experienced an adverse result. These patients need to be given a realistic understanding of the risks and benefits of surgery so that they do not deny themselves the chance for rehabilitation on the basis of misunderstanding. Other patients with long-standing neuropathies have developed adaptive habits to circumvent the motor deficit, and it will be more difficult in these patients to get them to consistently use the transfer. An example of this would be the patient with median nerve loss who uses the key pinch to grasp objects, and may from force of habit fail to use a "successful" opponensplasty.

The introduction of multi-drug therapy for leprosy over a decade ago has rendered a prolonged and inadequate treatment into a rapid, reliable and effective cure. Neuritis secondary to reaction is also much more effectively treat-

## 2 Surgical Reconstruction & Rehabilitation in Leprosy

ed now. As a result the number of patients presenting with disability has decreased considerably over the years.

Great care must be taken when caring for patients with peripheral neuropathies. Insensate limbs are prone to pressure ulceration while in plaster and to tearing or cracking the skin during therapy. After autonomic denervation the skin becomes dry, making patients prone to ulcers and cracks which increase the risk of post-operative infection. Infection can occur without pain and when hidden by dressing or plaster detection can be dangerously delayed. The results of tendon transfer surgery are greatly diminished by adhesions and so all care must be taken to avoid these. Much has been written about appropriate surgical technique, and the reader is referred to any standard surgical textbook for these techniques. A few important points of surgical technique as related to reconstructive surgery will be covered in this chapter, as well as particular considerations in tendon transfer surgery.

Often primary care workers are not aware about reconstructive surgery and do not refer patients with a paralytic deformity to a surgical service, if available. Most university surgical departments have specialists on staff, who could perform most operations needed by leprosy patients. The leprosy program could call on an experienced leprosy surgeon to provide the necessary training of the surgeons willing to help. This will also help in removing the fear for leprosy when leprosy patients are treated in a University Hospital.

### **ANAESTHESIA**

Most patients coming to operation will have significant sensory loss and often smaller procedures can be done with no anaesthetic or only local anaesthesia. All patients will find the operative experience easier with a peri-operative narcosis, such as Pethidine mixed with

Phenergan. Hand procedures will usually require a tourniquet and thus will require anaesthesia of the upper arm. An axillary or brachial block will be sufficient in almost all cases. Mixing Bupivacaine 0.5% with Lignocaine 2% will increase the duration of action while decreasing the toxicity.

For minor procedures in the foot an ankle block will often suffice. Removal of the plantaris tendon can be quite painful and a spinal anaesthetic may be needed. If an anaesthetist is present a short general anaesthetic can be used. For this reason fascia lata is easier to harvest. Lignocaine 0.5% can be used as local anaesthesia for this. Alternatively a lateral femoral cutaneous nerve block with a femoral nerve block can be used. However these are not always successful and if supplemental local is needed there are potential problems with Lignocaine toxicity when the axillary block is added. For larger procedures below the waist spinal anaesthetic is used.

I have found that virtually all procedures on the face can be carried out using local anaesthesia with adrenaline. Planning and marking should be done before the local infiltration to avoid confusion from distortion. Again Bupivacaine should be added for longer procedures or those requiring large volume of anaesthetic.

### **PREPARATION FOR SURGERY**

#### ***Foci of Sepsis***

The operative area should be free of wounds and cracks for at least one week prior to surgery. These are a potential portal of entry for organisms. As well the limb must be inspected on the table as patients or staff may cause skin trauma in the immediate pre-operative period. Callouses need to be trimmed and examined carefully. Controversy arises when considering operating in the presence of a wound elsewhere on the body. There is increased risk of

wound infection in the presence of distal sepsis, and one also has to consider the risk to other patients when a patient with an ulcer is transferred into the clean surgery ward. The latter risk should be minimal with appropriate dressing technique, and there is considerable mixing of patients regardless of bed location due to social interactions. When considering this issue it is important to distinguish the type of wound present, in essence whether this is a superficial healing ulcer or an infected or deep ulcer. If the latter type is present reconstructive operations should be delayed. If the ulcer is superficial and clean then it is reasonable to put the affected limb in a plaster one or two days prior to surgery and then proceed with surgery.<sup>5</sup> One has to keep in mind the psychological, financial and relational effects of prolonged hospitalization on the patient and his family. Scabies should be treated and operation deferred until at least one week after the burrows have disappeared.

### **The Use of the Tourniquet**

A tourniquet is helpful for almost all operations on the extremities, including many septic operations. The safest type is the pneumatic tourniquet inflated to about 100 mm Hg above the patient's blood pressure. The following points need to be considered:

- 1) A smooth layer of cotton wool should be applied before applying the cuff.
- 2) The cuff must be applied smoothly to ensure even distribution of pressure. The tourniquet must be rapidly inflated to avoid temporary venous tourniquet effect.
- 3) Gravity exsanguination for 60 seconds is adequate. I do not use an Esmarch bandage as seeing some blood in the vessels as the procedure progresses helps in hemostasis.

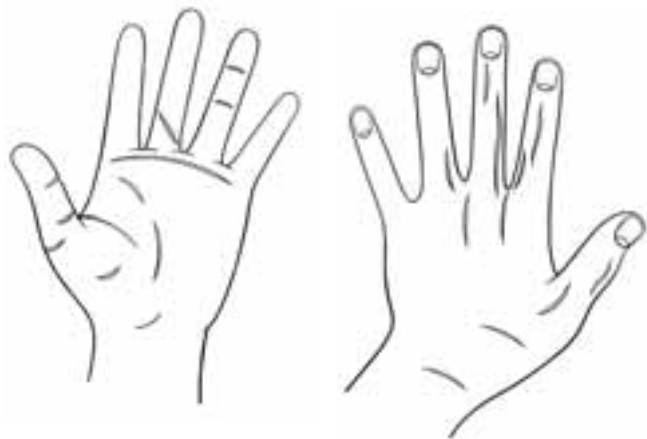
- 4) A limit of 90 minutes tourniquet time is advisable. After this point the tourniquet can be deflated and re-inflated ten minutes later if need be.
- 5) It is best to deflate the tourniquet before skin closure to check for hemostasis, although with careful technique one can leave the tourniquet in place until the skin is closed.

### **Skin Preparation**

We use two ten minute soap and water scrubs, on the night before and on the morning of the surgery. The shaving is done the morning of surgery. Povidine is used for pre-operative skin disinfecting.

### **Skin Incisions**

In general skin incisions in the hand should be made in the skin creases. Incisions on the fingers should be longitudinal just dorsal to the mid-lateral line, or along the joint crease on the palmar surface. (Fig. 1-1). Diagonal incisions on the palmar surface are also acceptable, ensuring that a longitudinal palmar incision never crosses a joint line. The interphalangeal joints should be approached with a midline dorsal longitudinal incision. Transverse or



**FIGURE 1-1** Palmar and dorsal views of the hand showing acceptable incisions in the hand.

#### 4 Surgical Reconstruction & Rehabilitation in Leprosy

oblique incisions will impair the venous drainage with resultant potential loss of the digit. The longitudinal incision does leave one with buckled skin after straightening a joint but this is preferable to losing the finger! When straightening a chronically contracted joint it is imperative that it is not fixed under tension. Tension on the soft tissues can cause spasm of the vessels with ischaemic necrosis of the digit. Therefore following such surgery frequent vascular checks of the digit are necessary.

In the foot, incisions on the weight-bearing surfaces are to be avoided. Surgery on the metatarsal-phalangeal joints should be through a dorsal incision rather than yielding to the temptation to approach through an ulcer on the sole. The dorsal skin often has a poor blood supply and thus all flaps and incisions should have a broad proximal base. Toes, like fingers, should be approached via a mid-lateral or dorsolateral incision, and the joints should be approached via a dorsal longitudinal incision.

### TENDON TRANSFERS IN PERIPHERAL NEUROPATHIES

#### *Etiology*

The number of diseases for which tendon transfers are an appropriate and effective method of treatment are limited (see Table 1-1). There are a host of other peripheral neuropathies described but the vast majority do not lend themselves to tendon transfers due to their progressive nature. World-wide the most common disease requiring tendon transfer surgery is leprosy, although there are large regional variations in frequency of etiologies. In the West trauma would be the leading etiology. It is important for the physician caring for these patients to recognize conditions which can be benefited by transfer surgery so that patients with a correctable deformity are referred in a timely fashion.

**TABLE 1.1 Etiology of Neuropathies Suitable for Tendon Transfer.**

1. Trauma    a) Nerve  
              b) Nerve root  
              c) Incomplete spinal cord
2. Leprosy
3. Charcot- Marie-Tooth Disease
4. Polio
5. Guillain- Barré Syndrome
6. Bell's Palsy
7. Spinal Muscular Atrophy
8. Syringomyelia
9. Congenital Absence of Muscle/Nerve
10. Cerebral palsy

#### ***Pre-Operative Preparation***

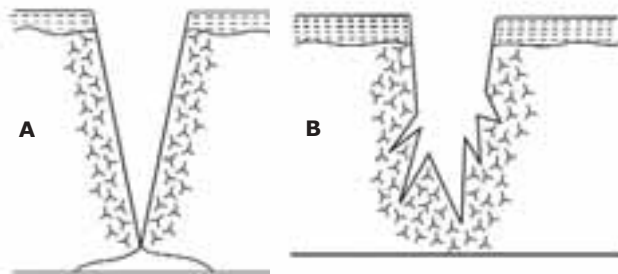
The patient must be properly evaluated and prepared for the planned surgery. Most of this process is covered in the chapter on pre-operative physiotherapy as well as in each individual chapter. It is essential to understand the concepts in this chapter before embarking on any tendon transfer operation. The operation must be done right the first time, as secondary procedures give less than satisfactory results. The presence of deformity does not constitute an indication for surgery. Some patients with long-standing deformity have developed compensatory habits which can give adequate function. Surgical intervention can disrupt this habit and render the hand less functional, even though more cosmetically pleasing, than before surgery. Especially with severely disabled hands thorough discussion with both the patient and therapists is necessary pre-operatively to determine the patient's needs and expectations. The patient must understand what the operation can be expected to accomplish, and also be informed of non-surgical alternatives such as small prosthetic aids or splints.



## Considerations in Tendon Transfer Surgery

### Technique

It is of particular importance that trauma to the tendons and surrounding tissues are kept to a minimum. The opening incision should be done firmly, and then deepened in a single plane rather than opening separate planes, which causes more scarring and potential devascularized fat (Fig. 1-2). Scissor dissection should be done with careful snipping using sharp scissors rather than tearing tissues with forced opening of the scissors. Tissues, especially tendons, must be kept moist throughout the procedure. Gloves should be washed of powder prior to commencing the procedure.

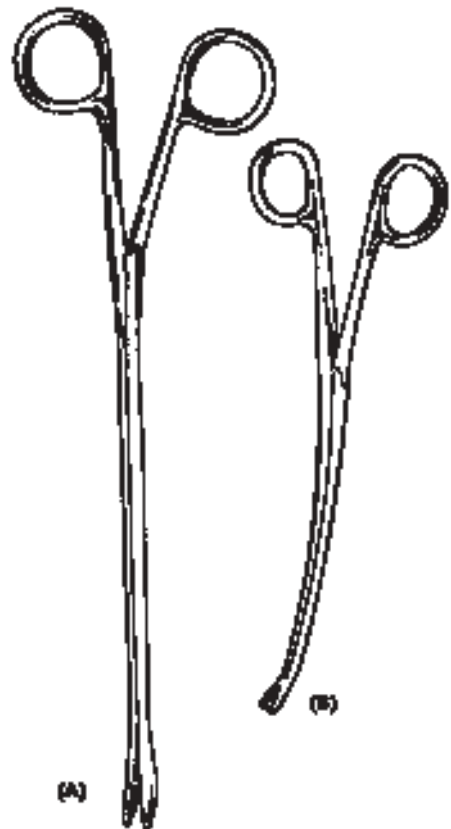


**FIGURE 1-2** Technique of making an incision.  
A. Correct B. Incorrect

The time that the tendon is out of the body should be minimized to avoid dessication of the tendon. It should be kept moist while it is exposed. Preparing routes prior to taking out the donor tendon minimizes tendon exposure. To reduce the risk of infection the tendon should not be allowed to touch the patient's skin nor should it be handled with the fingers. Dissection should be minimized and incisions and routes carefully planned before commencing. Tendons should not be tunnelled through scar tissue or under a skin graft. Either a different route must be chosen or a flap done prior to embarking on a transfer. Skin incisions should

be planned so that skin sutures will not be in contact with tendon sutures. Skin closure should be done with monofilament nylon so that they may be left in the full three weeks the limb is in plaster without developing stitch infection. Skin closure should be meticulous with careful approximation and no inversion.

Tunnels must not be made too tight to cause friction on movement, but neither should they be so large as to cause a large healing response with subsequent adhesions. The tendon must be checked for free gliding after it is brought through the tunnel. Tunneling should be done with a fine-jawed tendon passer such as an Anderson tunneller (Fig. 1-3). When tunneling one needs to probe around with the tip to find the path of least resistance. As Brand points out, forcing a tunneller through a layer of fascia



**FIGURE 1-3** Anderson tunnellers.

can cause adhesions at that point, and natural tunnels must be used as much as possible. The anastomosis should be done in a way to minimize raw or uneven surfaces, and tendon ends should be buried. A Brand anastomosis (see Fig. 1-4) is an excellent technique of end-to-end tendon anastomosis that buries both ends of tendons and creating a smooth join with a very gradual profile, which will minimize friction. For tendon joins distal to the last moving joint where the anastomosis is not gliding, a Pulvertaft weave is appropriate. It is strong and technically simple, and if free gliding is not required tendon ends do not need to be covered. Transfers should not be left adjacent to bone as the incidence and consequences of adhesions are greater than with fascia or muscle, as adhesions to bone will be immobile. For strength and ease of tying a fine multifilament nylon is used, whereas fine monofilament nylon is used when the suture will be exposed on or near a moving tendon.

It is not advisable to carry out an arthrodesis of a joint close to a tendon transfer at the same time. Either the prolonged immobilization will adversely affect the transfer mobilization, or the early mobilization will harm the bony fusion.

Tension must be set carefully. In many standard procedures, tensions have already been determined and often splints are available to assist in obtaining the correct tension. In each case however the actual result should be assessed visually to ascertain that the tension is correct for the individual patient. The reconstructive surgeon should always be prepared to revise an anastomosis if the tension is not correct. Do not accept a less than ideal result—future revision is much more difficult!

### **Patient Factors**

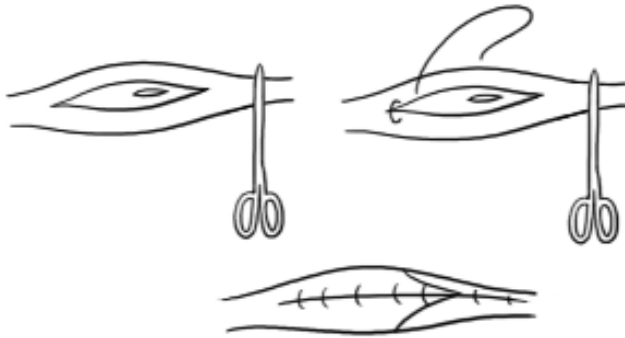
Any patient who may benefit functionally from a transfer procedure should be considered for surgery. The patient needs to be motivated to

be considered a candidate for tendon transfer surgery. We use the pre-operative physiotherapy period to assess the patient's motivation. Time and patience are required in order to learn the transfer, and the patient must be intelligent enough to be able to isolate the donor muscle. The patient must be willing to take the time required for healing and learning to use the transfer. Occasionally more than two procedures are required and the patient must have the patience and understanding to be able to tolerate this.

Patients as young as age eight to ten are able to understand transfer concepts, and patients younger than this will usually start spontaneously using a transfer once they are free to use the operated limb. A young child should not have necessary surgery deferred due to young age, as the risk of developing secondary deformity is too great. In our experience, older age is not a predictor of poor transfer results.<sup>6</sup> Therefore advanced age in itself should not be a factor in the decision. There should be no medical or anaesthetic contraindications. The patient should have been off steroids for at least two weeks.

### **Timing of Transfer**

In general the operative area should be infection-free, with good skin condition and free of any wounds for at least one week. In the hand there should be minimal long flexor tightness as well as minimal joint contractures. In late presenting cases it may take many months of physiotherapy and serial casting before the limb is ready for tendon transfer, but attempting transfer before proper preparation would invite failure. In nerve trauma following repair one should in general wait until reasonable hope of recovery of nerve function is lost. If nerve function is regained after a transfer procedure is done it will simply not be used, and the donor morbidity incurred will be for nought. Some, including Brand<sup>2</sup> and



**FIGURE 1-4** Brand tendon anastomosis (from Fritsch<sup>5</sup>, used with permission).

Burkhalter<sup>3</sup>, have advocated early transfer surgery to function as a splint in order to prevent deformity and prevent the patient from learning bad habits. This approach is reasonable in some patients who appear to be developing early deformity or in those in whom the chance of recovery is considered remote, especially if the proposed donor morbidity is minimal (i.e. palmaris longus). However, for the most part a good therapy unit can keep a hand or foot supple and contracture-free with simple exercises while awaiting nerve recovery.

In leprosy the patient should have completed at least six, and preferably the full course of MDT (multi-drug therapy) prior to transfer, as this early period has an increased frequency of reactions with possibility of further nerve damage and loss of function of the donor muscle. Likewise the patient should have been reaction-free for at least six months prior to surgery. This applies particularly to transfers in the hand. It has also been argued that the stress of surgery may precipitate a reaction, although there is no concrete evidence to support this theory. Again one must balance the potential risks of early operation with the risk that the patient may not return in a reasonable time for the necessary surgery. The nerve palsy should have been present for at least one year to allow the nerve time for potential nerve regeneration.

### Choice of Muscle-Tendon Unit

The choice of tendon is predicated initially on what muscles are available. Therefore full voluntary muscle testing must be carried out on the involved limb to determine the full breadth of options. Following transfer the muscle must work at a disadvantage, and as well must contend with adhesions. The strength must therefore be at least 4/5 on the MRC scale, as usually the strength will drop one grade post-transfer. The excursion of a muscle is also important, in that the donor muscle must have equal or greater excursion than the recipient tendon in order to produce a full range of motion of the recipient biomechanical unit. For instance flexor carpi ulnaris is a powerful muscle but its minimal excursion makes it a poor option to use as a transfer to extensor digitorum communis with its greater excursion. The excursion of a muscle is dependent largely on its muscle fibre length, and these are usually recorded as resting fibre length. These excursions can be found in standard charts.<sup>2</sup> The strength of the donor and recipient as well should roughly match. Muscle strengths have been measured by their tension fraction, which is the percentage of the total power in the limb provided by the given muscle. Examples of standard muscle excursions and strengths are seen in Table 1-2.

Donor morbidity must always be minimized. If the choice is available one must attempt to use the operative procedure with the least trauma to the hand to minimize post-operative hand swelling. The procedure should be easy for the patient to learn. Check to ensure that the patient is able to localize the proposed donor muscle. In general in-phase (i.e. a flexor tendon being used as a flexor) operations are easier to learn than out of phase ones. There are exceptions to this such as the extensor to flexor multi-tailed transfer (EFMT) in which wrist extension actually accentuates the efficiency of MCP joint flexion.

TABLE 1-2 Muscle Variables

Muscle	Excursion	Tension Fraction
ECRL	9.3	3.5
ECRB	6.1	4.2
FCR	5.2	4.1
PL	5.0	1.2
EIP	5.5	1.0
EDM	5.9	1.0
FDS(M)	7.0	3.4
FDS(R)	7.3	2.0
Interossei	1.4-2.5	2.8-4.5
Lumbricals	4.9-6.6	0.1-0.2

Numbers from Brand PW. *Clinical Mechanics of the Hand*. CV Mosby, St Louis, 1985.

The type of hand must also be taken into consideration. A stiff or large hand will tend to do better with an EFMT whereas a fine mobile hand does well with a "Lasso" procedure, and a hypermobile hand such as is often seen in India may do best with a palmaris many-tailed transfer. The possibilities should be discussed with both the patient and the hand therapist to assist in the decision of which donor would best suit the particular needs of the patient. Obviously the surgeon and therapist's experience is important, as an unfamiliar procedure with good reported results can fare disastrously in inexperienced hands. It is best to become expert with the technique and potential problems of two or three transfers than to attempt all available transfers.

### Route

The particular route chosen depends principally on the operation being carried out but also depends on what the operation is intending to accomplish. For example, there is a choice of six routes for a standard FDS opponensplasty. The particular route chosen will depend on the patient's occupation and his own stated need for the type of grasp required. A labourer might require a wide grip and so a more proximal

pulley would be used giving more abduction. However a teacher may require more fine tip-to-tip opposition and so a more distal pulley would be used. The reader should refer to the specific surgical chapter for more detail.

Acute angulation at a pulley is to be avoided as this increases friction and reduces the efficiency of the transfer. If the line of pull is not in a straight line then there should be no more than one pulley, as again the friction may prove too great for function of the pulley.

### CONTRAINDICATIONS

These are best described as correctable/ uncorrectable than relative/ absolute.

#### Correctable

1. Sepsis in limb or distant site.
2. Joint or skin contracture.

#### Uncorrectable

1. Lack of suitable muscle/tendon to transfer.
2. Non-compliant patient.
3. Progressive neuropathy.
4. Inappropriate disease i.e. some spastic conditions.

### POST-OPERATIVE CARE

The cast needs to prevent movement and tension of the transfer, but need not be tight enough to effect bony immobilization. The limb is put in a position to take the tension off the transfer in a safe position i.e. in the hand the metacarpal-phalangeal joints at 80° and the inter-phalangeal joints straight. The cast should be well padded especially in the sensory deficient limb. Within the constraints of keeping tension off the transfer the cast should be made as comfortable as possible. Edema predisposes to adhesions and as such the limb should be elevated for one week post-operatively.

The period of immobilization is variable. For tendon to tendon joins, in the foot where

stiffness is less of a problem the cast is removed at 4 weeks. However in the hand where stiffness can adversely affect results mobilization is commenced by three weeks, and often at one week. Joint stiffness is particularly a problem in the elderly. Tendon to bone joins require immobilization for 6 to 8 weeks. Protection of the transfer against sudden strain during sleep or at-risk activities is required for 3 months after the operation.<sup>7</sup>

### **TRANSFER FAILURE TO FUNCTION**

A transfer may fail to function adequately for several reasons as follows:

1. Incorrect tension. It is unusual to have a transfer sutured under too much tension. The more usual situation is inadequate tension. If this is the case one should wait at least three months before re-operation.
2. Slipped Suture. This is usually due to post-operative infection where the suture is rejected and extrudes from the wound some weeks after the procedure. It can also happen if the mobilization is too vigorous. In this situation the tendon cannot be felt and no movement of the transfer is seen.
3. Adhesions. Adhesions can develop after any tendon transfer. The best policy is avoidance by good surgical technique, appropriate routing and early mobiliza-

tion. When established, early 'aggressive' therapy is needed to prevent this from becoming permanent.

4. Lack of patient understanding. Again, the solution is more therapy- with understanding.
5. Reaction following operation. This is unusual but possible. This can be detected by voluntary muscle testing and sensory testing. If the transferred muscle/tendon has become paralyzed, a second tendon could be transferred, but only after a period of a year.

### **REFERENCES**

1. Brand PW: described in Fritchi, EP: Surgical Reconstruction and Rehabilitation in Leprosy. The Leprosy Mission, New Delhi, 1984
2. Brand PW, Hollister A: Clinical Mechanics of the Hand, 3rd ed. CV Mosby, St. Louis, 1999
3. Burkhalter WE: Early tendon transfer in upper extremity peripheral nerve injury. Clin Orthop 104:68-79, 1974
4. Enna CD: Preoperative Evaluation. pp. 16-30. In Enna CD, McDowell F (eds): Surgical Rehabilitation in Leprosy. The Williams and Wilkins Company, Baltimore, 1974
5. Fritchi, EP: Surgical Reconstruction and Rehabilitation in Leprosy. The Leprosy Mission, New Delhi, 1984
6. Schwarz RJ: Results of opponensplasty. J Hand Surg (in press)
7. Warren G: Tendon Transfers. pp. 215-222. In Conally WB (ed): Atlas of Hand Surgery. Churchill Livingstone, 1997



# Peripheral Nerve Function Assessment

• WIM H. VAN BRAKEL

## INTRODUCTION

Leprosy is essentially a disease of the peripheral nervous system.<sup>24,28,49</sup> It has therefore been encouraging to see an upsurge in interest in the detection and treatment of peripheral neuropathy in leprosy – commonly called ‘nerve damage’ or ‘nerve involvement’ – in recent years. Apart from early detection of leprosy and prompt treatment with multidrug therapy (MDT), nerve function assessment (NFA) and steroid treatment of any impairment detected is the main method of primary prevention of impairment and disability.<sup>46</sup> Since most deformity, activity limitation (disability) and ultimately, even psychosocial problems in leprosy result from nerve damage, NFA has a very important role to play in leprosy control programmes.<sup>47,96</sup> The purpose of this chapter is to review the existing methods to detect and monitor peripheral nerve damage, with a particular reference to field programmes.

## RELATIVE IMPORTANCE OF DIFFERENT KINDS OF NEUROPATHY

Leprosy may result in damage of sensory, motor and autonomic nerve fibres. Motor nerve impairment has been recognised as an important problem in leprosy, because it often leads to visible impairment (deformity). Regular testing of voluntary muscle strength was already suggested in the sixties.<sup>42</sup> It has been adopted on a worldwide scale as a measure of neural function and is often the only outcome parameter reported.<sup>52,70,84,88</sup> Although the importance of motor function in daily life is beyond dispute, the importance of sensory

function is often underestimated. Moberg put it very clearly when he called sensibility “the eyes of the hands”.<sup>67</sup> The importance of sensibility to the patient cannot be overemphasized. A patient with insensitive feet is at constant risk of injury, while those with insensitive hands are often severely disabled.<sup>25</sup> The role of protective sensation of eyes, hands and feet has been repeatedly emphasised.<sup>83,95</sup> Loss of protective sensation in eyes, hands and feet is responsible for much of the long-term morbidity caused by leprosy. The usefulness of sensibility testing of leprosy patients with graded nylon monofilaments was reported by Naafs & Dagne as early as 1977.<sup>69</sup> Autonomic nerve damage is important because the resulting dryness of the skin and possibly also the changed microvascular physiology are additional risk factors for injury.

Histopathological evidence shows that small unmyelinated and myelinated fibres are affected at an early stage of the disease.<sup>66,81</sup> Assessment of modalities mediated by such fibres, which include autonomic function, temperature and pain sensation, would therefore be theoretically advisable. However, these are difficult to measure reliably and are currently impossible to quantify with instruments suitable for field use. Several studies have shown sensory function to be more frequently affected than motor function.<sup>75,78,90</sup>

## Recent vs. Late

The dilemma often faced is “is this NFI ‘recent’ or ‘old’?” The implication being that recent NFI should be treated with corticosteroids, while it is assumed that old NFI would no longer

respond. It is common practice to call NFI that occurred *within* the last six months 'recent' and beyond six months 'old'.<sup>9,52</sup> Support for this cutoff has recently been obtained in a controlled, randomised trial in Nepal and Bangladesh (Richardus et al., in preparation).

### Mild vs. Severe

If treatable forms of neuropathy were detected and treated at an early stage, i.e. when they are still 'mild', the prognosis is likely to be better than when treated at an advanced, severe stage. The question is "How do we know whether a given patient has early or advanced neuropathy?" 'Early neural impairment' is a different concept from 'recent NFI'. Patients with 'recent NFI' who fail to respond to steroid treatment may in fact have had advanced neuropathy. Early detection of NFI calls for regular nerve function assessment (NFA), so that changes can be noted early in time. It also requires sensitive testing instruments, so that early changes in nerve function would not go unnoticed. In compression neuropathy it is possible to predict severity from the results of testing several different modalities of peripheral nerve function.<sup>32,41</sup> Whether this is also true for leprosy neuropathy can only be answered by prospective studies of the prognostic value of various NFA instruments. However, under field conditions, the best we can hope for is the use of a sensitive instrument that would detect neuropathy at an early stage. If appropriate normal values are available, then instruments measuring thresholds (e.g. monofilaments and (moving) two-point discrimination) will be more sensitive than methods that rely on supra-threshold stimuli (e.g. ballpen and pin prick testing).

Another issue related to the stage of neuropathy is the distinction between impairment *per se* and impairment of protective sensation.<sup>29</sup> Evidence to date shows that it is possible to

have sensory impairment *without* loss of protective sensation.<sup>17,44,54</sup> It is very important to be able to predict whether a patient is at risk of injury due to his NFI or not. Patient education, provision of protective footwear, and even choice of vocation may depend on this. An assessment method that can distinguish between presence and absence of protective sensation is clearly advantageous. However, for screening purposes it may only be possible to test for either normal threshold *or* presence of protective sensation. Where the circumstances permit, I would recommend the former, followed by a more extensive test if impairment is found. Expressed as touch/pressure sensibility and based on cross-sectional data, protective thresholds have been shown to be 2 g for the hand<sup>54</sup> and 10 g for the foot.<sup>17,44</sup> In a prospective study, Rith-Najarian *et al.* found a strong association between the inability to feel the 10 g filament on the feet of diabetic patients and the risk of amputation of the lower extremity.<sup>76</sup> Prospective confirmation of these findings in leprosy patients is needed.

### Graded vs. Non-graded Tests

Non-graded tests are mostly used for screening purposes. The result is simple to interpret: 'Yes' or 'No', 'Felt' or 'Not felt'. Their cutoff should be set at a level that provides the optimum combination of sensitivity and specificity for the screening purpose. A non-graded test can only answer the question "present or not?" In practice, because the biological parameters measured are usually continuous, an in-between category of 'partial' or 'indecisive' is often used. Examples of non-graded tests used in NFA in leprosy are ballpen testing of sensibility, hot and cold testing, pin prick testing of pain sensation and various tests to assess sweating. The main advantage of non-graded tests is that they are usually quicker and cheaper than graded tests and therefore can be applied to many people in a short time.

The main disadvantage of non-graded tests is that they cannot give quantitative results. They can therefore not distinguish between mild and severe neuropathy, nor are they suitable to monitor progress of NFI during treatment. Often a kind of pseudo-grading is used. For example, if a fixed number of sites on the palm of the hand are tested with a ballpen or single filament, the 'threshold' for impairment is often set at more than one site 'not felt'.<sup>8,29,77</sup> Severity of sensory impairment is thus expressed in terms of extent, instead of a threshold.

### Normal (reference) Values

When graded tests are used with the aim of giving a quantitative result, it is very important that appropriate reference values should be used.<sup>38</sup> Where these are not available, normative studies should be carried out. Normal values for Semmes-Weinstein monofilament testing and moving two-point discrimination have been found to differ between North-America and Asia.<sup>5,51,61</sup> Voluntary muscle testing is an exception to the rule, in that the test is standardised on what the examiner believes to be the normal strength for the person tested. It requires experience to know what is 'normal' in a given population, taking into account age and gender. Therefore, it is advisable to use a scale with clearly distinguishable categories (e.g. strong, weak, paralysed, or strong, weak, reduced range of movement, paralysed), particularly for use by non-specialised staff.

### Properties of a Good Test

A good test should have good measurement properties. A good test should be valid, able to discriminate between groups, reliable, responsive to change and relevant.<sup>37,63</sup> A valid test measures what it is intended to measure. This is often expressed as the sensitivity and specificity of a test, compared to a 'gold standard'

test of what we want to measure. A closely related concept is that of 'discrimination'. A good test should be able to discriminate between people who have a condition and those who don't, or between those who have a severe condition and those in whom the condition is mild.

The 'reliability' or 'reproducibility' of a test is its ability to give the same results if the test is repeated, when the condition measured remains the same.<sup>18</sup> A test is responsive to change if it is able to detect change in what is measured. It is also important that a test is relevant to the investigation and, perhaps more importantly, to the person examined. For example, a test to see if one can discriminate hot from cold may be more relevant to a person with leprosy than a test that measures touch thresholds.

### Available Instruments and Tests

Table 1 below gives an overview of available instruments and tests to assess peripheral nerve function. The list is not comprehensive, but includes the most commonly used methods that do not need advanced or expensive equipment.

### Clinical Assessment of Dryness of the Skin

Assessing dryness with the fingers or back of the hand is a simple but crude test, which can be difficult to interpret on the soles of people walking barefoot or wearing open chappals, particularly in the dry season. It is as such a valid and relevant test of autonomic function, although the sensitivity and specificity are likely to be low. One study compared clinical assessment of dryness with measurement of vasomotor reflexes using laser doppler flowmetry,<sup>2</sup> but the authors did not attempt to calculate sensitivity or specificity. Because the test is crude, the responsiveness to change is also likely to be poor.

TABLE 1

Instrument/test	Modality assessed	Description	References
<b>Autonomic function</b>			
Assessing dryness of the skin	Autonomic innervation of sweat glands	Use the finger or back of the hands to assess whether an area on the palm or sole feels dry or moist	83,96
Sweat provocation tests	Innervation and/or function of sweat glands	Sweating can be provoked using a direct method (intra-dermal methacholine injection) or indirectly (axon-reflex sweating) with intradermal nicotine	39,62
<b>Sensibility</b>			
<b>Pain</b>			
Pin prick	Pain	Use a sharp object (needle, weighted pins, toothpick) to assess whether the subject can feel pricking pain sensation	48,73,93
<b>Touch</b>			
Gentle stroking or touching with finger, feather or cotton wool	Light touch sensation (static or moving)	Gently stroke or touch an area of skin and let the subject indicate whether (s)he feels this or not	3,74
Ballpen test	Touch sensation / skin indentation	Touch the skin lightly with the tip of a ballpen and let the subject indicate whether (s)he feels this or not	4,9,26,96
Monofilament testing	Touch sensation / skin indentation	Touch the skin with a nylon monofilament and let the subject indicate whether (s)he feels this or not	4,11,20,69,93
<b>Two-point discrimination</b>			
Static two-point discrimination	Discrimination of two simultaneous, separate tactile stimuli; innervation density	Touch the skin with a calliper, bent paperclip or Discriminator and determine the minimum inter-prong distance the subject can detect as separate stimuli	23,33,68,74
Moving two-point discrimination	Discrimination of two moving simultaneous, separate tactile stimuli; innervation density	Move a calliper, bent paperclip or Discriminator over the skin and determine the minimum inter-prong distance the subject can detect as separate stimuli	31,41,74,89
<b>Thermal sensation</b>			
Warm and cold test tubes	Thermal sensation; Discrimination between hot and cold	Touch the skin alternately with the warm and cold test tubes and ask if the person can tell which one is warm and which is cold	3,73,74
Ether or alcohol test	Cold sensation	Dip a cotton wool swab in ether and alcohol and touch the skin of the person to be tested alternatively with a dry swab and the ether (alcohol) swab and ask whether the person can tell which one feels cold	
<b>Motor function</b>			
Voluntary muscle test (manual muscle strength test)	Muscle strength as a proxy for motor fibre function	Ask the subject to perform a specified movement and grade the muscle strength against resistance given by the tester	20,42,96
Dynamometry / pinch grip testing	(pinch) grip strength	Ask the subject to squeeze or pinch the instrument with as much force as they can and read off the results on the meter	80,82

### Pin prick test

The pinprick has been widely used, particularly in India. In its basic form it is a non-graded 'yes/no' test, but modifications using spring-loaded devices or sliding weights have been proposed.<sup>48,73</sup> Given that loss of pain sensation is one of the key problems in leprosy,<sup>19,39</sup> and that histopathological evidence indicates that small (unmyelinated) fibres are among the first to get affected,<sup>7,81</sup> the validity of testing pain sensation seems beyond question. The test also seems relevant, as long as the affected person understands that their problems may be related to loss of pain sensation. We compared the reliability of a pinprick test performed with a wooden toothpick with that of monofilament testing and moving two-point discrimination.<sup>92</sup> The pin prick test performed less well than the two touch sensibility tests. Although careful testing with a wooden toothpick could be defended, the use of reusable pins should be discouraged, because of the risk of transmission of HIV and Hepatitis B infection.

### Ballpen test

The ballpen test is perhaps the most widely used sensory test in the field of leprosy.<sup>8,15,26</sup> Its strengths lie in its simplicity and in the almost universal availability of the instrument.<sup>97</sup> The validity of the test has not been formally evaluated against a reference test, but theoretically, it should have good validity as a test of touch sensation. Given that a light touch with a ballpen will generate touch pressure in the range of 4 g upwards,<sup>12</sup> the ballpen test is not a valid test of normal sensibility, at least not on the hand (see normal thresholds under monofilament testing below).<sup>51</sup> The ballpen test is likely to be more valid as a test of protective sensation, although prospective evidence for this is lacking.<sup>17,76</sup>

Ballpen testing is often believed to be easy. However, applying a ballpen tip with consistent light pressure is far from easy. The tip of the ballpen should be applied to the skin with just enough force to see the skin move. If the skin blanches, too much pressure is being applied.

Reliability has been studied in Ethiopia, Nepal and Bangladesh and has been found to be moderate to good.<sup>4,57</sup> Responsiveness to change has not been studied separately, but several studies have reported use of the ballpen test in monitoring sensory function during MDT and also during steroid treatment of reactions and NFI.<sup>8,15,27</sup> From these reports it appears that the test is capable of detecting deterioration in sensory function and subsequent improvement during steroid therapy. However, as a non-graded test it is likely to respond only to major changes.

### Static two-point discrimination

The (static) two-point discrimination (2PD) test has been widely used to evaluate sensibility, mainly of the hand. It is a test of innervation density of the skin.<sup>32</sup> Its main field of use has been neural compression syndromes and traumatic nerve lesions.<sup>41,68,87</sup> Only one study has reported the use of static 2PD in people affected by leprosy.<sup>23</sup> The validity of the test is good in relation to hand function.<sup>33,35</sup> However, with regard to sensory function in patients with compression of the median nerve in the carpal tunnel, static 2PD was considerably slower to respond to change than monofilament and vibration perception testing.<sup>41,87</sup> Reliability has been reported to be good.<sup>34</sup>

### Moving two-point discrimination

Like static 2PD, moving two-point discrimination (M2PD) is a test of innervation density, which is a valid parameter to measure nerve function in leprosy. It is an example of a test



that is not very relevant to the person tested and, indeed, we have found it difficult at times to explain what we were asking the person to indicate. This was particularly true for measurements on the sole of the foot.<sup>51</sup> The validity of M2PD in terms of correlation with functional sensation of the hand has been extensively documented.<sup>33,35,71,89</sup> The same is true for reliability, which is good, despite the fact that the application force of the test instrument is not controlled.<sup>34,72,92</sup> Reference values are available from different populations.<sup>30,36,51,58</sup>

### Monofilament testing

The principle of sensibility testing with graded filaments (or horsehairs as were originally used) was invented by von Frey, towards the end of the 19th century. Semmes and Weinstein introduced the idea of using standardised nylon monofilaments, instead of hairs.<sup>98</sup> The method was first used in leprosy by Naafs<sup>69</sup> and later by Judith Bell-Krotoski at the National Hansen's Disease Centre in Carville, Louisiana.<sup>10-12</sup> The appropriate stimulus in this type of sensibility testing is skin indentation and that monofilament testing is a valid way of approximating this.<sup>50</sup> With regard to functional

sensation of the hand, a useful correlation has been demonstrated.<sup>89</sup> We showed that people who were unable to feel a 2-g filament on the hand, also had difficulties with functional sensation, such as texture discrimination and dot detection. However, other investigators found that monofilament testing did not correlate well with a timed object recognition test,<sup>33</sup> or the sensibility involved in Braille reading.<sup>71</sup>

Reliability has been tested in different settings and generally has been found to be very good.<sup>4,14,16,57,92</sup> Responsiveness to change has been shown in experimentally induced compression of the median nerve,<sup>41,59</sup> and in patients with carpal tunnel syndrome.<sup>87</sup> Normal thresholds for monofilament testing have been established for populations in North America as ~70 mg on the hand and ~300 mg on the foot.<sup>13,43,99</sup> In Nepal and India, these thresholds are around 200 mg for the hand and 2 g for the foot (see Table 2).<sup>5,51,60</sup> Thresholds for protective sensation are generally accepted to be in the range of 2 g for the hand<sup>54</sup> and 10 g on the sole of the foot.<sup>17,44</sup>

Often 10 or even more sites are tested on each hand and foot. This is time consuming and may compromise test reliability, particular-

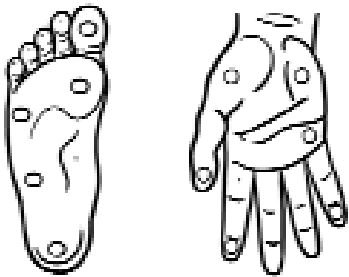
**TABLE 2** Summary of normal sensory monofilament thresholds (95th centiles) by age group for some commonly tested sites on hands and foot (data obtained in Nepal;  $n = 600$ ).

Site	< 20 yrs		20-50 yrs		> 50 yrs		Overall	
	Force	Colour	Force	Colour	Force	Colour	Force	Colour
Little finger	120 mg	(Blue)*	200 mg	Blue	200 mg	Blue	200 mg	Blue
Hypothenar	120 mg	(Blue)*	200 mg	Blue	200 mg	Blue	200 mg	Blue
Thumb	120 mg	(Blue)*	200 mg	Blue	200 mg	Blue	200 mg	Blue
Big toe	500 mg	(Purple)*	2 g	Purple	6 g	(Orange)*	2 g	Purple
MTP1	500 mg	(Purple)*	2 g	Purple	6 g	(Orange)*	2 g	Purple
MTP5	500 mg	(Purple)*	2 g	Purple	6 g	(Orange)*	2 g	Purple
Heel	2 g	Purple	10 g	Orange	29 g	(Pink)*	10 g	Orange

\* The filament in parenthesis, though not corresponding with the actual threshold, is the one that should be used for the given test site and age. MTP1(5) = first (fifth) metatarsophalangeal joint.



ly when clinics are busy. Statistical analysis has shown that the number of test sites may be reduced, while preserving 95% of the sensitivity for detecting NFI obtained with testing ten sites. We currently recommend 6 sites on the hand (3 ulnar and 3 median) and 4 on the foot. The recommended test sites are shown in Figure 2-1.



**FIGURE 2-1:** Sensory test sites on hands and feet.

The disadvantages of monofilament testing are the limited availability of the standardised filaments, the lack of standardisation of filaments,<sup>65</sup> their fragility and the fact that careful testing methods and training are required,<sup>56</sup> particularly also in the *interpretation* of the results. In addition, the results – monofilament thresholds – are not very relevant to a person's daily life.

Despite these difficulties, the monofilament is increasingly used, also in the monitoring of diabetic neuropathy.<sup>34,45,71</sup> Some programmes use a two-filament screening test, usually 2-g for the hand and 10-g for the foot, others use a graded 5, 6 or even 20-filament test. The full advantage of the monofilaments can only be appreciated when a graded test is used.<sup>55</sup> This allows monitoring of touch thresholds over time using visually easy-to-interpret colour coding of results, matching the colours of the filaments (personal experience of the author).

Monofilament testing is often considered difficult, especially when compared to ballpen

testing. In my experience, the reverse is true. While filament testing requires careful training, the buckling qualities of the nylon ensure a repeatable touch stimulus for a given filament. In contrast, the pressure exerted by the ballpen is dependent on the force applied by the tester. Ballpen testing can provide reliable results, but (maintaining) a good technique is not easy. Other issues in monofilament testing are that thresholds may vary 1) with the moistness of the skin,<sup>64</sup> 2) with (non-)use footwear,<sup>86</sup> and 3) with age, with filament thresholds increasing with age.<sup>5</sup> With subjects above 60 years of age, higher normal reference values should be used.

### Temperature discrimination test

Temperature sensation is a potentially important test because it is mediated by small myelinated and unmyelinated fibres, which are affected early in leprosy (see above).<sup>81</sup> Testing for temperature discrimination using hot and cold test tubes or cotton swabs dipped in ether or alcohol has been used for a long time. However these tests are crude, cumbersome (test tube testing) and are not always easy to perform under field conditions. WHO introduced a handheld thermal testing probe, which was battery powered and had one hot tip and one at ambient temperature. Some investigators found it very useful,<sup>85</sup> others found that even healthy volunteers could often not distinguish both ends of the probe.<sup>79</sup> The latter could be due to high environmental temperatures. In recent years, automated computerised systems have become available, with which quantitative assessment of warm and cold perception thresholds is possible.<sup>6,39</sup> However, these systems are not practical under field conditions. They may be very useful in certain research settings. The validity and relevance of temperature discrimination testing in leprosy is high, as wounds due to impairment of thermal sensation are very common.

**Voluntary muscle test**

The voluntary muscle test (VMT) or manual muscle strength test (MMST) has been in use for a long time.<sup>1</sup> Goodwin first recommended voluntary muscle testing for use in leprosy.<sup>42</sup> As several muscle groups in face, hands and feet are commonly affected in leprosy, the VMT would seem a valid and relevant test. Brandsma recommended a modified MRC scale for grading the test when assessing people affected by leprosy.<sup>20</sup> In the modified scoring system, because only small muscles are evaluated, the effect of gravity is not taken into account (see Table 3). Although formal validity evaluation has not been done in the field of leprosy, many studies bear witness to the validity of the VMT as a proxy measure to monitor motor nerve function.<sup>9,27,52,91</sup> Reliability of the 0-5 MRC scale has been well established.<sup>21,22,40,53</sup> However, extending the scale by adding in-between categories (e.g. 4+, 3+, etc) was not found to be helpful, as such grading was not reproducible.<sup>22</sup> No reports on formal reliability testing of the abbreviated 3-point (strong, weak, paralysed) and 4-point scales (strong, resistance reduced, movement

reduced, paralysed) have been published. Responsiveness to change has been operationally confirmed through the use of the test in many studies. The test is technically one of the more difficult ones to perform, as the tester uses 'intrinsic normal values', based on the tester's experience of what is normal muscle strength. Since normal muscle strength varies with sex and age, this requires considerable practice. A strength of this type of testing is the fact that no testing instruments are required. The simplified version of the VMT, called the Quick Muscle Test (QMT) is often used in the field (Table 4).<sup>15</sup>

**TABLE 4** Muscles and movements tested in the Quick Muscle Test (QMT). Each movement is graded as 'Strong', 'Weak' or 'Paralysed'.

Nerve	Muscle (group)	Movement
Facial	Orbicularis oculi	Tight eye closure
Ulnar	Hypothenar muscles	Little finger out
Median	Thenar muscles	Thumb up (with palm horizontal)
Radial	Wrist extensors	Wrist up (forearm pronated)
Lateral popliteal	Foot dorsiflexors	Foot up

**TABLE 3** Modified MRC grading for voluntary muscle testing.

	Grade	Criteria
Hands & Feet	5	Full range of movement of the joint on which the muscle or muscle group is acting. Normal resistance can be given.
	4	Full range of movement but less than normal resistance
	3	Full range of movement but no resistance
	2	Reduced range of movement with no resistance
	1	Perceptible contraction of muscle(s) not resulting in joint movement
	0	Complete paralysis
Eyes	5	Normal forced eye closure
	4	Full closure against reduced resistance
	3	Full closure without resistance
	2	Partial closure (lid gap persisting)
	1	Muscle flicker (no closure)
	0	Complete paralysis

### Dynamometry and pinch grip testing

Dynamometry – measurement of grip and pinch strength – has not been used widely in leprosy. Soares & Riedel have reported its use with people affected by leprosy.<sup>82</sup> They described an inexpensive dynamometer, made of a blood pressure cuff. Other investigators have published normal values,<sup>94</sup> but these would need to be repeated in local populations. The discriminative ability of hand-held dynamometry is good for ulnar nerve lesions.<sup>80</sup> While attractive because of the quantitative results, normal values vary considerably with sex and age. The test is therefore most useful if the person can be used as his/her own control. Its value to discriminate between people with mild to moderate weakness (normal range of motion) should be evaluated, as this is the range in which the 0-5 MRC scale has little discriminative power. The test is relevant to people who complain of weakness of the hand.

### Which tests to choose?

Table 5 summarises the measurement properties of the most commonly used sensory and motor tests. In the field of hand surgery, (moving) two-point discrimination is also often used. However, this test is less suitable for use on the soles of the feet and therefore less useful in leprosy.<sup>92</sup>

For most field programmes, a combination of the ballpen test and the QMT is probably the most feasible option, particularly in integrated programmes. However, in referral centres and hospitals where patients are evaluated for surgery or are treated with corticosteroids for nerve function impairment, use of the graded monofilament test and the 6-point VMT is strongly preferable. To assess the need for and success of reconstructive surgery, an activities of daily living (ADL) assessment should be added to the nerve function assessment. Discussion of the latter is outside the scope of this chapter.

**TABLE 5** Qualities of tests commonly used in nerve function assessment.<sup>7-10</sup>

	Ballpen	SWM	VMT <sup>1</sup> (0-5 scale)	QMT <sup>2</sup>
Validity	/ +++? <sup>3</sup>	++++	++++	+++
Repeatability	+++ <sup>4</sup>	++++	+++	?
Sensitivity to early impairment	–	+++	++	++
Responsiveness to change	++	+++	++	++?
Normal values available	NA <sup>5</sup>	yes	NA	NA
Availability	++++	++	++++	++++
Ease of use	++ <sup>6</sup>	+++	+	+++

Comments: **1** Voluntary muscle test. **2** Quick muscle test. **3** Probably good for screening for protective sensation; poor for detecting normal sensibility. **4** Good, provided the testing technique is good and consistent. **5** Not applicable. **6** The correct technique to provide a light touch stimulus is not as easy as often thought.

In addition to choosing the most appropriate tests, one needs to decide on criteria for the diagnosis ‘impairment’. The following are recommended for sensory and motor impairment.

### Sensory impairment

A patient is diagnosed as having sensory impairment if the monofilament threshold is increased by three or more levels (filaments) on any site, two levels on one site AND at least one level on another site, OR one level on three or more sites for one nerve.

### Motor impairment

A patient is diagnosed as having motor impairment if the VMT score for any muscle is less than four on the 0-5 (modified) MRC scale.

Similar criteria need to be formulated to define what constitutes a clinically significant change in impairment.

## RECOMMENDATIONS

1. In the context of reconstructive surgery, the graded monofilament test is currently the sensory test of choice, provided standardised filaments are available, staff can be adequately trained and filaments can be replaced when damaged or bent. If a rapid test is required, a two-filament screening test is recommended. On the Indian sub-continent, a 2-g and 10-g filament may be used for protective sensation screening the hand and foot respectively. To screen for impairment of normal sensibility, 200 mg and 2 g are more appropriate. Higher thresholds should be used for people above 50 and for barefoot walkers.
2. Voluntary muscle testing should complement sensory testing. The choice of a 3-, 4- or 6-point scale will depend on the level of skill and understanding of the staff, but for pre- and post-operative surgical assessment, the 6-point modified MRC scale is recommended.
3. Testing of autonomic function, temperature discrimination or pain sensation might detect early sensory impairment, but tests are not (yet) available to do this easily and reliably under field conditions.
4. Sensory testing should always be included in a nerve function assessment, as a) sensibility is more frequently affected than motor function, b) current sensory tests are probably more sensitive than motor tests and c) sensory loss may precede motor impairment.
5. Moving 2-point discrimination is an attractive alternative to monofilament testing, if a quantitative test is required. It can be done with simple and robust instruments, such as a paperclip, but is less suitable for sensory testing of the foot.

6. If a non-graded screening test is sufficient and the use of filaments is not possible for whatever reason, the ballpen test offers a cheap and easily available alternative. Care should be given that staff is carefully trained in the correct technique and that this technique is maintained.

## REFERENCE LIST

1. Aids to the investigation of peripheral nerve injuries. London, HMSO. Medical Research Council War Memorandum, 1943
2. Abbot NC, Beck JS, Bhaskar RB et al: Circulation and sensation in the fingertips of claw hands. *Lepr Rev* 65:341-349, 1994
3. Abbot NC, Beck JS, Samson PD et al: Cold fingers in leprosy. *Int J Lepr* 60:580-586, 1992
4. Anderson AM, Croft RP: Reliability of Semmes Weinstein monofilament and ballpoint sensory testing, and voluntary muscle testing in Bangladesh. *Lepr Rev* 70:305-313, 1999
5. Anderson AM, van Brakel WH: Age specific normal thresholds for sensibility testing with monofilaments in a Nepali population. *Int J Lepr* 66:69A-69A, 1998
6. Antia NH: Leprosy - a disease of the Schwann cell. *Lepr Ind* 54:599-604, 1982
7. Antia NH, Mehta LN, Shetty VP et al: Clinical, electrophysiological, quantitative, histologic and ultrastructural studies of the index branch of the radial cutaneous nerve in leprosy, I Preliminary report. *Int J Lepr* 43:106-113, 1975
8. Becx-Bleumink M, Berhe D, 't Mannetje W: The management of nerve damage in the leprosy control services. *Lepr Rev* 61:1-11, 1990
9. Becx-Bleumink M, Berhe D: Occurrence of reactions, their diagnosis and management in leprosy patients treated with multidrug therapy; experience in the Leprosy Control Program of the All Africa Leprosy and Rehabilitation Training Centre (ALERT) in Ethiopia. *Int J Lepr* 60:173-184, 1992
10. Bell-Krotoski JA: Light touch-deep pressure testing using Semmes-Weinstein monofilaments. pp 585-593 *In* Hunter et al (ed): *Rehabilitation of the hand* C.V. Mosby Co., 1989
11. Bell-Krotoski JA: "Pocket" filaments and specifications for the Semmes-Weinstein Monofilaments. *J Hand Ther* 3:26-31, 1990

12. Bell-Krotoski JA, Buford JW: The force/time relationship of clinically used sensory testing instruments. *J Hand Ther* 1:76-85, 1988
13. Bell-Krotoski JA, Coor V: Semmes-Weinstein monofilament detection thresholds: a comparative study. *Int J Lepr* 61:146A, 1993
14. Bell-Krotoski JA, Tomancik E: The repeatability of testing with Semmes-Weinstein Mono-filaments. *J Hand Surg* 12A:155-161, 1987
15. Bernink EHM, Voskens JEJ: Study on the detection of leprosy reactions and the effect of prednisone on various nerves. *Lepr Rev* 68:225-232, 1997
16. Birke JA, Brandsma JW, Schreuders TA et al: Sensory testing with monofilaments in Hansen's disease and normal control subjects. *Int J Lepr* 68:291-298, 2000
17. Birke JA, Sims DS: Plantar sensory threshold in the ulcerative foot. *Lepr Rev* 57:261-267, 1986
18. Bland JM, Altman DG: Statistical methods for assessing agreement between two methods of clinical measurement. *Lancet* Febr 8:307-310, 1996
19. Brand PW, Thomas RE: The place of physical medicine and orthopaedic surgery in leprosy. An investigation into paralysis patterns in the forearm and hand in leprosy. Physiotherapy and neural involvement in leprosy. Suggestions for treatment by physical methods in neural leprosy. *Lepr Rev* 25:5-41, 1954
20. Brandsma JW: Basic nerve function assessment in leprosy patients. *Lepr Rev* 52:161-170, 1981
21. Brandsma JW, Schreuders TA, Birke JA et al: Manual muscle strength testing: intraobserver and interobserver reliabilities for the intrinsic muscles of the hand. *J Hand Ther.* 8:185-190, 1995
22. Brandsma JW, van Brakel WH, Anderson AM et al: Intertester reliability of manual muscle strength testing in leprosy patients. *Lepr Rev* 69:257-266, 1998
23. Brunel W, Schechter WP, Schechter G: Hand deformity and sensory loss due to Hansen's disease in American Samoa. *J Hand Surg* 13A:279-283, 1988
24. Charosky CB, Gatti JC, Cardama JE: Neuropathies in Hansen's disease. *Int J Lepr.* 51:576-586, 1983
25. Coleman WC, Madrigal DR: The patient with sensory loss. *Int J Lepr.* 53(2):255-257, 1985
26. Croft RP, Richardus JH, Nicholls PG et al: Nerve function impairment in leprosy: design, methodology, and intake status of a prospective cohort study of 2664 new leprosy cases in Bangladesh (The Bangladesh Acute Nerve Damage Study). *Lepr Rev* 70:140-159, 1999
27. Croft RP, Richardus JH, Smith WC: Field treatment of acute nerve function impairment in leprosy using a standardized corticosteroid regimen--first year's experience with 100 patients. *Lepr Rev* 68:316-325, 1997
28. Dastur DK, Ramamohan Y, Shah JS: Ultrastructure of lepromatous nerves; Neural pathogenesis in leprosy. *Int J Lepr* 41:47-79, 1973
29. de Rijk AJ, Byass P: Field comparison of 10-g and 1-g filaments for the sensory testing of hands in Ethiopian leprosy patients. *Lepr Rev* 65:333-340, 1994
30. Dean LS, Greene TL, Jacobson KE et al: Evaluation of normal values for stationary and moving two-point discrimination in the hand. *J Hand Surg* 9A:552-555, 1984
31. Dellon AL: The moving two-point discrimination test: clinical evaluation of the quickly adapting fiber/receptor system. *J Hand Surg* 3:474-, 1978
32. Dellon AL. Evaluation of sensibility and re-education of sensation in the hand. Baltimore, John D. Lucas Printing Co, 1988
33. Dellon AL, Kallman CH: Evaluation of functional sensation in the hand. *J Hand Surg* 8A:865-870, 1983
34. Dellon AL, Mackinnon SE, Crosby PM: Reliability of two-point discrimination measurements. *J Hand Surg* 12A:693-696, 1987
35. Dellon ES, Keller KM, Moratz V et al: Validation of cutaneous pressure threshold measurements for the evaluation of hand function. *Ann Plast Surg* 38:485-492, 1997
36. Dellon ES, Mourey R, Dellon AL: Human pressure perception values for constant and moving one- and two- point discrimination. *Plast Reconstr Surg.* 90:112-117, 1992
37. Dyck PJ: Quantitating severity of neuropathy. pp 686-697 *In* Dyck PJ, Thomas PK, Griffin J et al (eds): *Peripheral neuropathy*. Philadelphia, W.B. Saunders, 1993
38. Dyck PJ: Quantitative sensory testing: A consensus report from the peripheral neuropathy association. *Neurology* 43:1050-1052, 1993
39. Facer P, Mathur R, Pandya SS et al: Correlation of quantitative tests of nerve and target organ dysfunction with skin immunohistology in leprosy. *Brain* 121:2239-2247, 1998



## 22 Surgical Reconstruction & Rehabilitation in Leprosy

40. Florence JM, Pandya S, King WM et al: Intrarater reliability of manual muscle test (Medical Research Council scale) grades in Duchenne's muscular dystrophy. *Phys Ther* 72:115-122, 1992
41. Gelberman RH, Szabo RM, Williamson RV et al: Sensibility testing in peripheral-nerve compression syndromes. An experimental study in humans. *J Bone Joint Surg* 65A:632-638, 1983
42. Goodwin CS: The use of the voluntary muscle test in leprosy neuritis. *Lepr Rev* 39:209-216, 1968
43. Griener JS, Muro LB, Jones SV: Threshold of sensation; interrater reliability and establishment of normal using the Semmes-Weinstein monofilaments. *J Hand Ther* 1989
44. Hammond CJ, Klenerman P: Protective sensation in the foot in leprosy. *Lepr Rev* 59:347-354, 1988
45. Holewski JJ, Stess RM, Graf PM et al: Aesthesiometry: quantification of cutaneous pressure sensation in diabetic peripheral neuropathy. *J Rehab Res Devel* 25:1-10, 1988
46. ILEP. Prevention of disability in leprosy. Issue no. 8. 95. Medical Bulletin. ILEP Medical Commission.
47. ILEP. Prevention of disability. Guidelines for leprosy control programmes. 1995. London, ILEP.
48. Jain GL, Pasricha JS, Guha SK: Objective grading of the loss of pain and touch sensations in leprosy patients. *Int J Lepr* 54:525-529, 1986
49. Job CK: Pathology of leprosy. In Hastings RC (ed): *Leprosy*. Edinburgh, Churchill Livingstone, 1994
50. Johansson RS, Vallbo AB, Westling G: Thresholds of mechanosensitive afferents in the human hand as measured with von Frey hairs. *Brain Res* 184:343-351, 1980
51. Kets CM, van Leerdam ME, van Brakel WH et al: Reference values for touch sensibility thresholds in healthy Nepalese volunteers. *Lepr Rev* 67:28-38, 1996
52. Kiran KU, Stanley JNA, Pearson JMH: The outpatient treatment of nerve damage in patients with borderline leprosy using a semi-standardized steroid regimen. *Lepr Rev* 56:127-134, 1985
53. Kleyweg RP, Meché FGAvd, Schmitz PIM: Interobserver agreement in the assessment of muscle strength and functional abilities in Guillain-Barré syndrome. *Muscle Nerve* 14:1103-1109, 1991
54. Kuipers M, Schreuders T: The predictive value of sensation testing in the development of neuropathic ulceration on the hands of leprosy patients. *Lepr Rev* 65:253-261, 1994
55. Lehman LF, Orsini MBP, Nicholl ARJ: The development and adaptation of the Semmes-Weinstein monofilaments in Brazil. *J Hand Ther* 6:290-297, 1993
56. Levin S, Pearsall G, Ruderman R: Von Frey's method of measuring pressure sensibility in the hand: an engineering analysis of the Weinstein-Semmes pressure aesthesiometer. *J Hand Surg* 3:211-216, 1978
57. Lienhardt C, Currie H, Wheeler J: Inter-observer variability in the assessment of nerve function in leprosy patients in Ethiopia. *Int J Lepr* 63:62-76, 1995
58. Louis DS, Greene TL, Jacobson KE et al: Evaluation of normal values for stationary and moving two-point discrimination in the hand. *J Hand Surg* 9A:552-555, 1984
59. Lundborg G, Gelberman RH, Minter-Convery M et al: Median nerve compression in the carpal tunnel - functional response to experimentally induced controlled pressure. *J Hand Surg* 7:252-259, 1982
60. Malaviya GN, Husain S, Girdhar A et al: Sensory functions in limbs of normal persons and leprosy patients with peripheral trunk damage. *Ind J Lepr* 66:157-164, 1994
61. Malaviya GN, Husain S, Mishra B et al: Protective sensibility - its monofilament nylon threshold equivalents in leprosy patients. *Ind J Lepr* 69:149-158, 1997
62. Mathur NK, Pasricha JS, Pal D et al: Comparison of the cutaneous autonomic and somatic nervous functions in the lesions of leprosy. *Int J Lepr* 39:146-150, 1971
63. Matsuoka M, Kashiwabara Y, Namisato M: A Mycobacterium leprae isolate resistant to dapson, rifampin, ofloxacin and sparfloxacin. *Int J Lepr* 68:452-455, 2000
64. McAuley DM, Ewing PA, Devasundaram JK: Effect of hand soaking on sensory testing. *Int J Lepr* 61:16-19, 1993
65. McGill M, Molyneaux L, Yue DK: Use of the Semmes-Weinstein 5.07/10 gram monofilament: the long and the short of it. *Diabet Med* 15:615-617, 1998



66. Mehta LN, Shetty VP, Antia NH et al: Quantitative, histologic and ultrastructural studies of the index branch of the radial cutaneous nerve in leprosy and its correlation with electrophysiologic study. *Int J Lepr* 43:256-264, 1975
67. Moberg E: Objective methods of determining functional value of sensibility in the hand. *J Bone Joint Surg* 40B:454-466, 1958
68. Moberg E: Criticism and study of methods for examining sensibility in the hand. *Neurology* 12:8-19, 1962
69. Naafs B, Dagne T: Sensory testing: a sensitive method in the follow-up of nerve involvement. *Int J Lepr* 45:364-368, 1977
70. Naafs B, Pearson JMH, Wheate HW: Reversal reaction: the prevention of permanent nerve damage - comparison of short and long term steroid treatment. *Int J Lepr* 47:7-12, 1979
71. Nakada M, Dellon AL: Relationship between sensibility and ability to read braille in diabetics. *Microsurgery* 10:138-141, 1989
72. Novak CB, Mackinnon SE, Williams JI et al: Establishment of reliability in the evaluation of hand sensibility. *Plast Reconstr Surg* 92:311-322, 1993
73. Palande DD, Bowden REM: Early detection of damage to nerves in leprosy. *Lepr Rev* 63:60-72, 1992
74. Pearson JMH: The evaluation of nerve damage in leprosy. *Lepr Rev* 53:119-130, 1982
75. Richardus JH, Finlay KM, Croft RP et al: Nerve function impairment in leprosy at diagnosis and at completion of MDT: a retrospective cohort study of 786 patients in Bangladesh. *Lepr Rev* 67:297-305, 1996
76. Rith-Najarian SJ, Stolusky T, Gohdes DM: Identifying diabetic patients at high risk for lower- extremity amputation in a primary health care setting. *Diab Care* 15:1386-1389, 1992
77. Schipper A, Lubbers WJ, Hogeweg M et al: Disabilities of hands, feet and eyes in newly diagnosed leprosy patients in eastern Nepal. *Lepr Rev* 65:239-247, 1994
78. Schreuder PA: The occurrence of reactions and impairments in leprosy: experience in the leprosy control program of three provinces in northeastern Thailand, 1978-1995. III. Neural and other impairments [see comments]. *Int J Lepr* 66:170-181, 1998
79. Schreuders TAR, Kuipers M: Thermal sensibility tester - can it be used to find early nerve damage in leprosy. *Lepr Rev* 63:294., 1992
80. Schreuders TAR, Stam HJ: Strength measurements of the lumbrical muscles. *J Hand Ther* 9:303-305, 1996
81. Shetty VP, Antia NH, Jacobs JM: The pathology of early leprous neuropathy. *J Neurol Sci* 88:115-131, 1988
82. Soares D, Riedel A: A simple and inexpensive pinch meter to detect subclinical weakness among leprosy patients. *Lepr Rev* 68:55-60, 1997
83. Srinivasan H: Prevention of disabilities in patients with leprosy. A practical guide. Geneva, WHO, 1993
84. Srinivasan H, Rao KS, Shanmugam N: Steroid therapy in recent "quiet nerve paralysis" in leprosy. *Lepr Ind* 54:412-419, 1982
85. Srinivasan H, Stumpe B: Value of thermal sensibility testing in leprosy diagnosis in the field - field trial of a pocket device. *Lepr Rev* 60:317-326, 1989
86. Stratford CJ, Owen BM: The effect of footwear on sensory testing in leprosy. *Lepr Rev* 65:58-65, 1994
87. Szabo RM, Gelberman RH, Dimick MP: Sensibility testing in patients with carpal tunnel syndrome. *J Bone Joint Surg* 66A:60-64, 1984
88. Touw-Langendijk EMJ, Brandsma JW, Andersen JG: Treatment of ulnar and median nerve function loss in borderline leprosy. *Lepr Rev* 55:41-46, 1984
89. van Brakel WH, Kets CM, van Leerdam M et al: Functional sensibility of the hand in leprosy patients. *Lepr Rev* 68:25-37, 1997
90. van Brakel WH, Khawas IB: Nerve damage in leprosy: an epidemiological study of 396 patients in West Nepal - part 1: definitions, methods and frequencies. *Lepr Rev* 65:204-221, 1994
91. van Brakel WH, Khawas IB: Nerve function impairment in leprosy: an epidemiological and clinical study--Part 2: Results of steroid treatment. *Lepr Rev* 67:104-118, 1996
92. van Brakel WH, Khawas IB, Gurung KS et al: Intra- and inter-tester reliability of sensibility testing in leprosy. *Int J Lepr* 64:287-298, 1996
93. van Brakel WH, Shute J, Dixon JA et al: Evaluation of sensibility in leprosy - compari-

## 24 Surgical Reconstruction & Rehabilitation in Leprosy

- son of various clinical methods. *Lepr Rev* 65:106-121, 1994
94. van der Ploeg RJO, Fidler V, Oosterhuis HJGH: Hand-held myometry: reference values. *J Neurol Neurosurg Psych* 54:244-247, 1991
  95. Watson JM: WHO disability grading (letter). *Lepr Rev* 56:172-175, 1985
  96. Watson JM: Preventing disability in leprosy patients. London, The Leprosy Mission International, 1986
  97. Watson JM: Disability control in a leprosy control programme. *Lepr Rev* 60:169-177, 1989
  98. Weinstein S: Tactile sensitivity of the phalanges, perceptual motor skills. *South Un Press*. 14:351-354, 1962
  99. Weinstein S: Intensive and extensive aspects of tactile sensitivity as a function of body part, sex and laterality. pp 193-218 *In* Kenshalo DR (ed): *The Skin Senses*. Springfield, 1968

## Surgical Management of Neuritis

• B. RICHARD

### INTRODUCTION

Impairment of peripheral nerve function may lead to the loss of autonomic, sensory and motor functions. In the upper extremity this may lead to dry, insensate skin on fingers that can no longer grasp and manipulate objects with precision and power control. The inappropriate use of the unbalanced hand or foot, and its inability to protect itself from the strains of daily stress, can lead to skin breakdown, infection and the more serious sequelae of neglected painless sepsis. While it is reasonable to say that the patient with leprosy can be cured of his bacteriological infection, we are less able to deal with the problem of nerve damage. Neuritis is a state of inflammation within a peripheral nerve that may lead to impaired function. There are a number of modalities to manage this problem. These can be divided into medical and surgical interventions and are attempts to reverse the pathology or mitigate its effects. Medical treatment mainly involves the use of anti-inflammatory drugs (e.g. steroids) and splints (rest) to encourage nerve recovery. Health education is also invaluable in preventing disability by promoting understanding of the aetiology of tissue damage. Occupational therapy and assistive devices can be employed to enhance function and prevent or reduce deterioration when established nerve damage is present. Surgery is of benefit in alleviating nerve pain in those with chronic painful irreversible nerve impairment. Draining a compressive sterile nerve abscess and motor reactivation of hand, foot and facial palsies, by tendon transfer, are all valuable interventions. Surgery, while heralded as a

method of reversing nerve impairment by decompressive neurolysis operations, is actually of unproven benefit and in urgent need of a controlled clinical trial to test its true usefulness.

The primary task of the leprologist is to cause no harm and if possible to alleviate nerve damage. This responsibility is most easily carried out by first assessing the extent and reversibility of the nerve damage. Those with a new nerve impairment (less than 3 months) and those with a recent nerve impairment (less than 12 months) may benefit from a course of steroids. Nerve function impairment must not be considered irreversible until the deficit has been present for at least three years. Irreversible means that the motor end plates and sensory organs are biologically present but completely non-functional because of atrophy and are no longer capable of recovery in the presence of a new or recovered nerve axon reaching the end plate or sense organ. Whilst no studies exist in support of this recommendation, and some surgeon would consider eighteen months of no recovery to be irreversible, I believe we should not consider a period less than 3 years or patients may be submitted to unnecessary treatments. This is especially true of the very long peripheral nerves like the lateral popliteal which often show improved function some years after a complete foot drop.

In many of its chapters, this book deals with the use of surgical motor reactivation for established palsy. This chapter will first address the issues of surgical intervention that attempt to reverse nerve function loss. Indications and

techniques for nerve surgery will then be discussed.

## LITERATURE REVIEW

In the 1970's there were several publications on neurolysis of peripheral nerves that reported improvement in nerve function. Antia stated in 1974 that "... careful and complete release of the thickened nerve may not only relieve the pain, but may also result in recovery of sensory and motor function".<sup>1</sup> Twenty years later Antia says, "Traditional surgical decompression of the posterior tibial nerve yields equivocal results".<sup>2</sup> Why after twenty years do we still not know whether surgical decompression of the leprosy nerve is beneficial?

The answer lies in a review of the neurolysis papers. In most of these studies the patients were poorly selected with acute new cases mixed with longstanding nerve impairment cases. More importantly, there were no control groups.<sup>6-10,16,17,19,20</sup>

Neurolysis means different things to different surgeons and this has made comparison of results of limited value. Neurolysis can mean, a simple surgical decompression at the sites of predilection (for example dividing the flexor retinaculum at the wrist); an epineurotomy, which can be longitudinal or meshed, deroofing or excisional; interfascicular neurolysis with microsurgical instruments; or simple nerve rerouting, such as an anterior transposition of the ulnar nerve. Neurolysis has been performed by few surgeons and has not gained universal acceptance. That patients who have a surgical decompression do improve is not in doubt. The question is whether they improve more than if they had received only medical therapy. There is a study purporting to demonstrate that decompression used in conjunction with steroids is better than decompression alone.<sup>21</sup> However, in this study patients with

an acute painful neuritis received steroids in addition to the surgical decompression, while the decompression alone was for patients with established sensory loss. The first group fared better than the second. It is not surprising that the patients with more recent loss had better results. In a comparative study, Dandapat has shown a benefit with perineural steroid injections given at the same time as a neurolysis.<sup>11</sup> Group A received surgical decompression and epineurotomy while group B, in addition to surgery, received an injection of long acting steroid placed around the nerve after completion of the neurolysis. In Group A, 57.1% showed an improvement in the nerve evaluation test score, whilst in Group B, 83.3% of patients had improved. This demonstrates only that steroid injection improves the results of ulnar nerve decompression.

One study compared oral steroids against surgery and oral steroids.<sup>18</sup> Patients were randomly allocated to the medical or surgical group. Surgery consisted of a medial epicondylectomy and decompression of the nerves. The results showed a statistically significant improvement in both groups as assessed by improvement in motor and sensory functions and reduction of pain and tenderness. The study did not demonstrate any added benefit from the surgery as compared to steroid therapy alone. Clearly decompression surgery has no present or substantial evidence base for its claimed advantage of nerve function improvement.

There are other reasons why neurolysis has not been more widely practiced. Firstly, with the development of steroid therapy to control reactional episodes, there appears to be an effective 'medical decompression' of nerves often with subsequent nerve recovery. Many patients presenting with a nerve function loss of less than three months duration will gain a complete or good recovery with steroid therapy. This has certainly taken the pressure off any

need to find a surgical method of improving nerve function, especially when many leprosy control programs do not have a competent reconstructive surgical arm to their program.

Just how steroids work in patients with recent nerve impairment is not known. Whether it is a reduction of oedema in the swollen nerve effecting a 'medical decompression', and/or the steroids mitigate the immune reaction more systemically, is not known. Steroids have not been tested in a blind controlled trial for their efficacy in controlling and reversing recent nerve impairment. It would be unethical to carry out such a study now.

For the present, in most centres, steroids have replaced surgical decompression in the treatment of recent nerve impairment, and surgery is reserved for nerve abscess and unresponsive nerve pain.<sup>3,14</sup>

However, despite the success of chemotherapy there is a group of patients who fail to respond and are left with a social and functional disability. This has given impetus to explore new avenues in the search for motor and sensory recovery in the hand.

## **SURGICAL OPTIONS AND THE FUTURE**

The scientific rationale for surgery in promoting motor and/or sensory recovery is to decompress the nerve at the sites of mechanical compression. This could be supplemented with an epineurotomy or interfascicular neurolysis in order to permit the regenerating nerve to pass through the 'compressive' area and reach its end organs. For this to be effective the surgery needs to be performed before the skin's sense organs or skeletal muscle fibres have irreversibly atrophied. This probably means the patient should have a nerve impairment of less than three years, although many surgeons would use a rule of less than one year. Alternatively, if the understanding is that the

nerve is irreversibly damaged at the site of 'compression', then jumping the lesion with a muscle graft or other nerve conduit is a surgical possibility (Pereira). Again this must be done before the sense organs have atrophied. However, any patient receiving any of these types of operations within the desired three year period could just as well have made a nerve recovery spontaneously. So it behooves those who do these operations to demonstrate not only that they are successful, but that they are more successful than if the operation had not been done. The International Federation of Anti-Leprosy Associations (ILEP) has reviewed the history of neurolysis and made a plea for controlled, multicentre, trials to test the hypothesis that surgical decompression has a benefit over steroids alone.<sup>5</sup> Others have made similar pleas.<sup>4, 21,22,23</sup>

## **INDICATIONS FOR SURGERY**

### ***Nerve abscess***

The presence of a fluctuant swelling on or within a fusiform swollen peripheral nerve suggests a nerve abscess.<sup>3</sup> Often the patient is classified towards the tuberculoid end of the spectrum, and usually the nerve has some residual nerve function. The differential diagnosis is reaction neuritis with oedema of the nerve, which will be soft and tender. The fusiform swelling may also represent a chronic fibrosis, which will be hard, non-tender and more symmetrically swollen. The patient may recently have had an episode of reaction. The first line of management must be directed towards control of the disease process with a course of steroids and splinting if the nerve is painful. The diagnosis of an abscess can be confirmed by ultrasound, when available, and by needle aspiration of purulent material, which proves sterile for bacteria on microbiological culture. The pathology of the condition is necrosis of one or more fascicles within the

nerve with pus production and a capsule formation. This may be within the swollen peripheral nerve or it may herniate like a pedunculated cyst. The swelling will be fluctuant and mobile transversally but not longitudinally. It is important that the surgeon does not make the nerve function worse by surgery, nor create a chronic wound sinus. It may be possible, under local anesthetic to simply aspirate the nerve abscess with a large bore needle, and wait for nerve function to improve. A chronic, or recurrent abscess can be surgically exposed under regional or general anaesthesia, the abscess cavity opened and drained and very carefully cleaned of its pseudocapsule wall, without avulsing nerve fascicles. The wound is then closed with separate fascial layers to reduce the chance of a chronic wound sinus. Under no circumstances should the abscess be surgically excised as this might slice through nerve fascicles that might otherwise have recovered.

### ***Nerve Pain***

Patients with established irreversible nerve impairment occasionally suffer from persistent nerve pain many months or years after completing chemotherapy. Examination of these peripheral nerves will demonstrate firm hard fusiformly swollen nerves. Shooting pains and paraesthesia can be elicited by tapping the nerve trunks at the sites of predilection and often more proximally as well (Tinel-Hoffman sign). In these patients the distal nerve and its sensory organs or muscle end plates are not functioning, but the peripheral nerves are full of thousands of proximal regenerating nerve fascicles trapped in a fibrotic mass. There is no strategy at present to provide viable endpoints for these regenerating nerve axons which cause the nerve pain. While there has been no randomized controlled trial to demonstrate the efficacy of neurolysis for such patients there is much anecdotal evidence to suggest that

releasing the proximal compression in these patients reduces their pain. An oral course of Gabapentin or Cabamazipine should first be tried for several weeks, as this may suffice. Surgery to relieve pain is designed to release compressive forces on the swollen peripheral nerve. This is only after all the acute or acute on chronic loss of nerve function has been adequately dealt with by courses of steroids and splintage. Patients with persistent pain may have fibrotic scars causing compression. These can be external to the nerve at the sites of predilection, and worsened by osseo-ligamentous tunnels, or intraneural fibrosis. In these instances, nerve decompression will often reduce the pain. Procedures include any of the techniques of decompressing the anatomical area in which the nerve lies, deroofting the epineurium, or inter/intra fascicular neurolysis.

### ***Lack of improvement of nerve impairment with steroid therapy***

While more controversial (see above), many surgeons strongly advocate surgical nerve decompression for patients who fail to respond to steroid therapy. For this to be effective it should be done early (less than three months), which of course will obscure the possible effect of the steroids, emphasizing again the need for a randomized controlled trial.

## **SURGICAL TECHNIQUES**

Once it has been agreed that some form of surgical decompression of the leprosy involved nerve is needed, mechanical decompression of the fibro-osseous tunnel and release of the intermuscular membrane at the site of predilection can be considered to be the minimum level of intervention. The next issue to consider is the type and extent of an epineurotomy and interfascicular neurolysis. In considering the



choice, the surgeons experience of intra-neural surgery, and availability of micro instruments and magnification should be taken into account. How far to extend the neurolysis proximal and distal to the site of predilection is also not determined. Turkof and Richard have demonstrated a reduction in electrophysiological nerve conduction considerably more proximal than the macroscopically obviously involved section of an involved nerve.<sup>23,26,27</sup> Therefore any neurolysis required at the site of nerve compression might need to be extended, at least by an epineurotomy, into the more proximal nerve trunk. Whether this is an absolute or relative indication is not known at present.

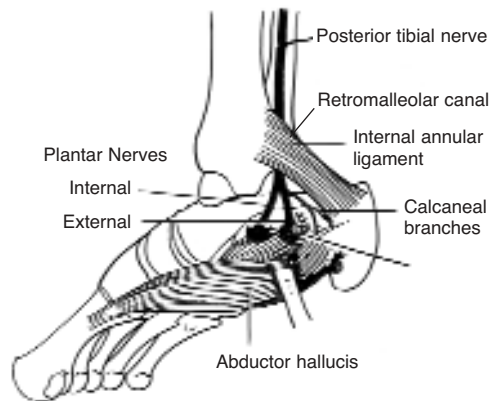
Neurolysis, as a technique, demands micro-instruments and magnification in order to safely operate on, and in a nerve. The interested reader should consult Salafia and Chauhan's book on Treatment of Neuritis in Leprosy.<sup>24</sup> However, it is my opinion that such techniques need to be validated by randomised controlled trials to assess their usefulness, rather than offering the technique to occasional patients.

### **Posterior Tibial Nerve**

#### **Release**

Using appropriate anaesthesia, either general, regional or local, and after limb exsanguination by elevation and application of a tourniquet on the thigh, the medial aspect of the ankle is prepared for surgery. An incision behind the medial malleolus, approximately 6-8 cm long, will expose the flexor retinaculum (Fig. 3-1). When the whole extent of the retinaculum is visible it can be incised by sharp dissection to expose the underlying posterior tibial vessels and nerve. It may be necessary to release the neurovascular bundle more proximally into the calf and under the medial gastrocnemius. There is no evidence that a more proximal or distal neuro-

lysis will improve the result of the decompression.<sup>16</sup>



**FIGURE 3-1** Anatomy of posterior tibial nerve at ankle. (Modified from Carayon A, Surgical Rehabilitation in Leprosy, Williams and Wilkins, 1974).

### **Ulnar nerve at the elbow**

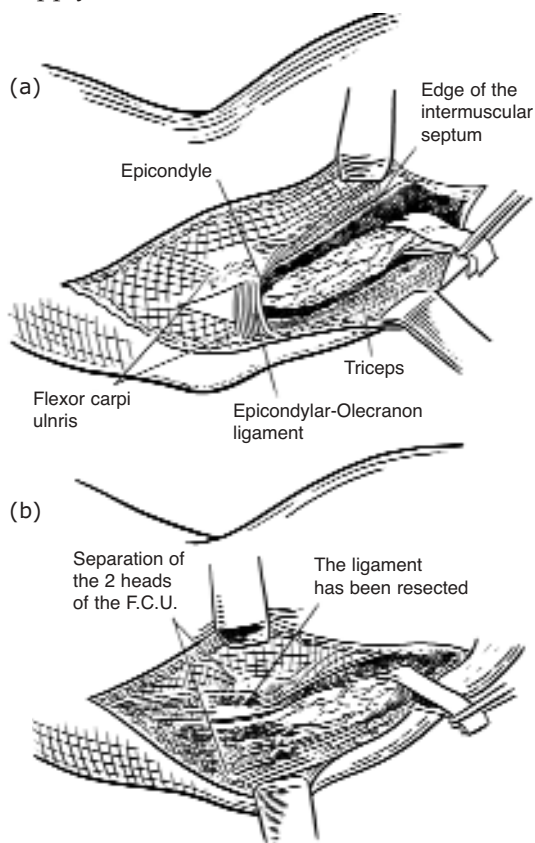
Using appropriate anaesthesia and following limb exsanguination by elevation and application of a tourniquet as proximal as possible on the upper arm, the elbow is prepared for surgery with the shoulder abducted and fully externally rotated and the arm on a side table.

Options for surgery on the ulnar nerve are varied. Traditionally the operation of choice was an anterior transposition of the nerve. A simple nerve release and epineurotomy are advocated by some.<sup>13</sup> A medial epicondylectomy is preferred by some as it does not interfere with the blood supply and patients regain use of the limb faster.

#### **Simple Decompression**

Simple decompression involves an 8 cm incision, a little anterior to the skin markings of the nerve, to expose the medial epicondyle and the medial intermuscular septum. The fascia that overlies the nerve is divided and the dissection is extended to release the crescentic free margin of the flexor carpi ulnaris beneath which the nerve disappears (Fig. 3-2). The proximal medi-

al intermuscular septum is released as it may be compressing the swollen nerve. An epineurotomy is then carefully carried out along its exposed length. Devascularising the nerve is avoided by dissecting its deep aspects. There is evidence in non-leprosy ulnar nerve surgery that a simple epineurotomy, with or without a medial epicondylectomy, gives similar results to an anterior transposition. It also has the advantage of not interfering with the blood supply of the ulnar nerve.<sup>12,13,15</sup>

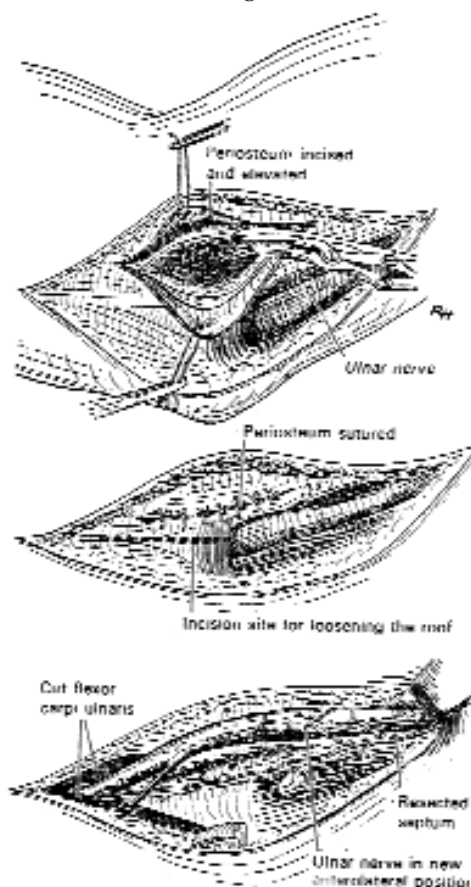


**FIGURE 3-2** Simple unroofing of ulnar nerve at elbow. **A.** Following exposure **B.** Following unroofing. (Modified from Carayon A, Surgical Rehabilitation in Leprosy, Williams and Wilkins, 1974).

### Medial Epicondylectomy

Patients with a large fusiform nerve that on elbow flexion dislocates out of the ulnar groove between the medial epicondyle and the olecra-

non may benefit from an additional medial epicondylectomy or anterior transposition of the ulnar nerve. Once the ulnar nerve is seen and retracted posteriorly the medial epicondyle is exposed by sharp subperiosteal dissection and reflection of the common flexor origin. The ulnar nerve, with its blood supply and fascial bed, are visualised in order to protect these tissues during the osteotomy. One then proceeds to remove, obliquely, the medial epicondyle and a portion of the supracondylar ridge (Fig. 3-3). An osteotome or ronguers suffice to remove the bone. The periosteum is closed over the filed bone edges and with the nerve



**FIGURE 3-3** Medial epicondylectomy. **A.** Removal of medial epicondyle after raising periosteal flap. **B.** Periosteum closed to minimize adhesions, fibrous arch divided and two heads of flexor carpi ulnaris separated. The ulnar nerve is then translocated anteriorly. (Modified from Carayon A, Surgical Rehabilitation in Leprosy, Williams and Wilkins, 1974)

retracted anteriorly, the common flexor origin is sutured to its new bone origin. The collateral elbow ligaments are left intact in this dissection. The wound is closed and a bulky soft dressing applied for 10 days. Decompression of the ulnar nerve at the wrist (Guyon's canal) alone may not be beneficial when in most cases the nerve may be more severely damaged proximally in leprosy affected persons.

### **Median Nerve**

#### **Release**

Following appropriate anaesthesia and application of a tourniquet, the whole upper limb is prepared allowing access to the wrist, the forearm and cubital fossa. This is because the median nerve needs to be decompressed at the wrist and sometimes at the pronator teres arch as well. A longitudinal anterior wrist incision that extends 4 cm proximal and 3 cm distal to the wrist crease, and lies to the ulnar side of the palmaris longus, will allow adequate direct vision of the carpal tunnel ligament and minimise surgical damage to any aberrant motor branch of the thenar muscles when dividing the ligament with a scalpel. Whilst the mechanical cause of the compression is the carpal tunnel itself the nerve is often grossly swollen proximal to the carpal tunnel. As with other decompression surgery, if the epineurium looks thickened, tight or pale in colour then a longitudinal epineurotomy can be performed and extended proximally into the forearm if necessary. When a positive pronator arch impingement provocation test is present (Tinel sign in the cubital fossa, pain on pronation of the flexed forearm against resistance, or pain on resisted flexion of the middle and ring fingers) then a cubital fossa exploration for a possible second median nerve granuloma should be performed. A second curved incision is made over the proximal volar forearm across the cubital fossa and up the medial side of the distal upper arm after dividing the lacertus fibrosus. This exposes the pronator teres arch

and the fibrous origin for the deep head of the flexor digitorum superficialis. Release of these tight structures might expose a second fusiform swelling in the median nerve deep in the cubital fossa.<sup>27</sup> An epineurotomy may also be appropriate.

### **Other Surgery**

Decompression of the Facial nerve has been described.<sup>28</sup> However, there is inadequate evidence to recommend it as a treatment option at present. Similarly, anyone contemplating decompression of the Common Peroneal nerve should only do so as part of a Randomised Controlled Trial. They should consider continuing the neurolysis into the thigh as far as the bifurcation of the sciatic nerve.<sup>23</sup>

### **CONCLUSION**

While surgical release of compressed nerves is associated with nerve recovery in many cases, a randomized controlled trial is necessary to prove that surgery with steroids is better than steroids alone. For those with neuritis pain or nerve impairment not responding to steroids, nerve decompression may be indicated. Complete release avoiding devascularization of the nerve may lead to safe and good results in competent hands.

### **REFERENCES**

1. Antia NH: The significance of nerve involvement in leprosy. *J Plast Reconst Surg* 54:55, 1974
2. Arolkar SK, Antia NH: Vascular surgery of the posterior tibial compartment for plantar ulceration in leprosy. *Lepr Rev* 66:48-54, 1995
3. Bhagat KP, Wange HM, Tekani BU: Management of nerve abscesses in leprosy. *Ind J Derm Ven Lepr* 46:110-112, 1980
4. Bourrel P: Surgical Rehabilitation. *Lepr Rev* 62:241-254, 1991
5. Bourrel P: Preliminary recommendations on the uses of surgery for the treatment of leprosy neuritis. *ILEP Medical Bulletin* No. 4, 1-3, 1992

6. Brandsma JW, Nugteren WAH, Andersen JB, Naafs B: Functional changes of the ulnar nerve in leprosy patients following neurolysis. *Lepr Rev* 54:31-38, 1983
7. Carayon A: Surgical decompression of leprosy neuritis. Objectives, techniques, indications and results. *Chirurgie* 110:225-234, 1984
8. Carayon A: Surgical decompression of leprosy neuritis: Anatomico-clinical and physiopathological bases. *Chirurgie* 110:219-224, 1984
9. Chaise F, Bourrel P: Les resultats eloignes de la decompression chirurgicale du nerf tibial posterieur dans les neuropathies de la maladia de Hansen. *J Chir (Paris)* 124:315-318, 1987
10. Chaise F, Roger B: Neurolysis of the common peroneal nerve in leprosy. *J Bone Joint Surg* 426-429, 1985
11. Dandapat DD, Sahu DM, Mukherjee LM, Panda C, Baliarsing AS: Treatment of leprosy neuritis by neurolysis combined with perineural corticosteroid injection. *Lepr Rev* 62:27-34, 1991
12. Froimson AL, Zahrawi F: Treatment of compression neuropathy of the ulnar nerve at the elbow by epicondylectomy and neurolysis. *J Hand Surg* 5:391-395, 1980
13. Guegan Y, Pinel JF, Javaudin Y: Neurolysis of the ulnar nerve at the elbow: Report on 20 cases. *Neurosurgery* 28:127-129, 1982
14. Nores JM, Redondo A, Vernerey C, Gentilini M: Surgical treatment of leprosy neuritis. Results of 114 operations. *Presse Médicale* 17:1756-1759, 1988
15. Oommen PK: Ulnar nerve decompression by medial epicondylectomy of the humerus and a method of assessing muscle power status by totaling the muscle grading. *Lepr India* 51:336-340, 1979
16. Palande DD, Azhaguraj M: Surgical decompression of posterior tibial neurovascular complex in treatment of certain chronic plantar ulcers and posterior tibial neuritis in leprosy. *Int J Lepr* 43:36-40, 1975
17. Pandya NJ: Surgical decompression of nerves in leprosy. An attempt at prevention of deformities. A clinical, electrophysiological, histopathological and surgical study. *Int J Lepr* 46:47-55, 1978
18. Pannikar VK, Ramprasad S, Reddy NR, Andrews P, Ravi K, Fritschi EP: Effect of epicondylectomy in early ulnar neuritis treated with steroids. *Int J Lepr* 52:501-505, 1984
19. Ramarorazana S, Rene JP, Schwartzl E, Randrianomenjanahary J: Résultats à un de 466 décompressions nerveuses réalisées chez 123 lepreux en cours de polychimiothérapie à Madagascar. *Med Trop* 55:146-150, 1995
20. Rao KS, Balakrishnan S, Oommen PK, Swamy MKS, Durai V: Restoration of plantar sweat secretion in the feet of leprosy patients. *Ind J Lepr* 59:442-449, 1987
21. Rao KS, Swamy MKS: Sensory recovery in the plantar aspect of the foot after surgical decompression of posterior tibial nerve: Possible role of steroids along with decompression. *Lepr Rev* 60:283-287, 1989
22. Richard BM. Sensory Re-ablement of the hand in leprosy : The next surgical frontier. *Ind J Lepr* 69:109-117, 1997
23. Richard B, Khatri B, Knolle E, Lucas S and Turkof E: Leprosy affects the tibial nerves diffusely from the middle of the thigh to the sole of the foot, including skip lesions. *Plast Reconstr Surg* 107:1717-1724, 2001
24. Salafia A, and Chauhan G: *Treatment of Neuritis in Leprosy*. A Salafia, Mumbai, 1997
25. Shah A: Evaluation of nerve function deficit. Its improvement by nerve decompression or corticosteroid therapy. *Ind J Lepr* 58:216-224, 1986
26. Turkof E, Tambwekar S, Mansukhani K, Millesi H, Mayr N: Intraoperative spinal root stimulation to detect most proximal site of leprosy ulnar neuritis. *Lancet* 343:1604-1605, 1994
27. Turkof E, Tambwekar S, Mansukhani K, Millesi H, Mayr N: Intraoperative electroneurodiagnostics to detect a second granuloma in the cubital area of the median nerves affected by leprosy: a new approach to prevent incomplete surgery. *Int J Lepr* 63:409-416, 1995
28. Turkof E, Richard B, Assadian O, Khatri B, Knolle E, Lucas S : Leprosy affects facial nerves in a scattered distribution from the main trunk to all peripheral branches and neurolysis improves muscle function of the face. *Am J Trop Med Hyg* 68:81-88, 2003

**Other Reading**

Ebenezer M, Andrews P, Solomon S: Comparative trial of steroids and surgical intervention in the management of ulnar neuritis. *Int J Lep* 64:282-286, 1996

Pereira, JH, Bowden, REM, Narayanakumar, TS and Gschmeissner, SE: Peripheral nerve reconstruction using denatured muscle autografts for restoring protective sensation in hands and feet of leprosy patients. *Ind J Lepr* 68, 83-91, 1996

Pereira, JH, Palande, DD, Subramanian, A, Narayanakumar, TS, Curtis J, and Turk, JL: Denatured autologous muscle grafts in leprosy. *Lancet* 338, 1239-1240, 1991



## Prevention and Non Surgical Treatment of Common Impairments: An Overview

• J. WIM BRANDSMA

### INTRODUCTION

In this chapter the common primary and secondary impairments as they often occur in patients with peripheral nerve injuries and neuropathies are discussed. These impairments are also discussed from a different perspective in some other chapters: anatomy and assessment of the hand (Chapter 5), pre- and postoperative therapy in connection with tendon transfers (Chapter 21) and ulcer care and prevention (Chapters 13,15). Nerve function assessment is discussed in Chapter 2.

Primary impairments are seen as the direct result of nerve function impairment (Fig. 4-1). The common primary impairments are: muscle imbalance, loss of (protective/functional) sensation and loss of autonomic function (sweating). Secondary impairments may 'follow' primary impairments. The secondary impairments can be prevented by different interven-

tions including modification of life style. The important interventions will be discussed in the following sections: prevention of nerve function impairment (NFI), protection, exercises and splinting, and ulcer care and prevention.

### PREVENTION OF NERVE FUNCTION IMPAIRMENT

Most impairments in leprosy can be attributed to nerve function impairment (NFI). Early diagnosis and regular and adequate treatment will in most cases prevent permanent NFI. Nerve function assessment (NFA) at time of diagnosis is mandatory to evaluate and monitor nerve function for as long as patients are under treatment/surveillance. NFA is not only important to know if nerve function is changing in (progressive) neuropathies but also when considering tendon transfer surgery. Which muscles are active and do they have adequate strength?

There are two widely accepted ways to assess and monitor nerve function: manual muscle testing and sensory testing.

In manual muscle testing the muscles are usually graded on the MRC 0-5 scale. With respect to the neuropathic limb a few studies have reported on reliability and method of assessment. Grip- and pinch strength assessments could also be included when evaluating motor impairment in the upper extremity.<sup>5-8</sup>

The instruments of choice in evaluating sensibility are Semmes-Weinstein monofilaments. These are graded nylon filaments that, when applied to the skin, give a reproducible force.

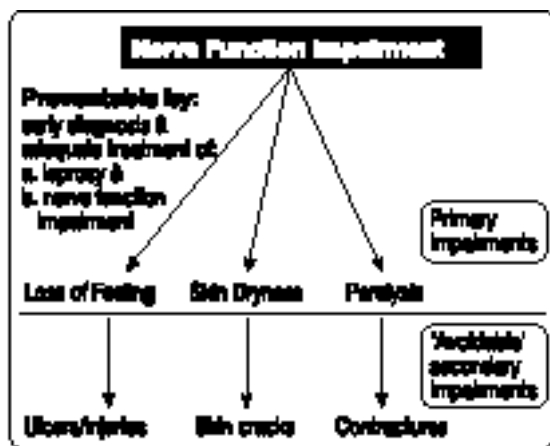


FIGURE 4-1 Primary and Secondary Impairments

Several studies have assessed reliability, and levels of normal and protective sensation have been determined for hands and feet in different studies for different populations.<sup>2,3,9</sup>

In one study in a population of patients with diabetes, the responsibility to evaluate and report on sensory impairment was given to the patients.<sup>1</sup> Subjects were given a monofilament to monitor sensation of their feet. A number of subjects reported with decreased sensory nerve function in the course of the study. Nerve function assessment is more extensively covered in Chapter 2.

### PROTECTION

Patients with loss of protective sensation of hands and/or feet are in danger of sustaining injuries that they are sometimes unaware of. Pain (discomfort), as a warning sign for pending tissue break down is often lacking. Loss of protective sensation is not a cause but a risk factor in the a-sensate hand or foot for injuries (ulcers). Patients need to know that the skin and underlying tissue are healthy and that when proper care is taken and attention is given to early signs of skin break down, the a-sensate hand and foot can serve a lifetime.

Tool adaptations can be helpful in preventing burns while cooking. Similarly, tool adaptations (including padding of handles) can prevent injuries and friction blisters when working on the land (Chapter 23). In addition, it is important that people with a-sensate hands know that they need to regularly change the way a tool is held and rest the hands. It is good practice to inspect the hands and feet, especially after a day's work out in the field, and if there is any sign of skin break down, to treat the hand as if it could still feel pain.

Plantar ulceration is a common occurrence in patients with insensitive feet. Patients with loss of protective sensation should wear appropriate footwear at all times. The footwear should ideally have a hard sole, which can pro-

tect against penetrating injuries (e.g. thorns and nails). A soft insole will be useful for cushioning the sole of the foot and may help in redistribution of body weight. Outer sole (rock-er sole) and in-shoe modifications (orthoses) can further help to redistribute pressures in the foot with severe secondary impairments (Chapter 17).

Many patients with a neuropathy may also have dry skin that easily cracks. It is good practice that these patients at least once a day soak and oil their skin (See appendix on skin care and self-care). Passive finger straightening exercises can be done as oil is rubbed into the skin.

### EXERCISES

There are basically two objectives for exercises of the hand or foot with weak or paralyzed muscles:

- a) Strengthening;
- b) Prevention/correction of contractures.

#### a) Strengthening exercises

In the authors' opinion no specific exercises are needed to strengthen weak muscles. Patients should be encouraged to use their hands as much as possible in meaningful activities. This will help to maintain available muscle strength or it may slow down the increase in muscle weakness in certain neuropathies.

#### b) Exercises to prevent or overcome contractures

Many patients with paralysis of the muscles of the hand develop, or present with, a 'claw' position of the fingers. The 'clawing' may be severe when there is paralysis of the intrinsic muscles only, less severe when there is also weakness of the extrinsic muscles. A few basic exercises will help to prevent joint stiffness (contractures) or they may help in overcoming joint stiffness. Joint stiffness may especially occur in the middle joints of the fingers (PIP joints) and the thumb. Exercises will always be



helpful to prevent the stiffness from becoming worse. If the stiffness in the middle joints of the fingers is less than 30-40 degrees there is a good possibility that the angles may improve.

### **The mobile and the stiff 'claw-hand'**

When you are able to straighten the joints 'passively' the fingers are considered mobile. There are different exercises for the stiff and the mobile hand (Fig. 4-2a,b).

**A**     **A Mobile**     **Twice daily-III**     **May take**  
**'claw hand'**     **repetitions**     **II minutes only**

**A1 Fingers**  
 Press with the other hand (forearm) the palm/knuckle joints firmly down on your thigh. Straighten fingers, actively, as much as you can. Hold straight for few seconds and relax. Repeat.

**A2 Thumb**  
 (Only when there is tendency for the thumb joint to bend!) Support with other hand middle joint (MCP) of the thumb. Straighten and joint (IP), hold for few seconds; relax and straighten again. Repeat.

**B**     **Stiff**     **Twice daily-III**     **May take**  
**claw-hand**     **repetitions**     **15-18 minutes**

**B1 Fingers**  
 With the hand supported on the thigh (palm up) passively straighten the finger joints with the other hand (forearm).

**B2 Thumb**  
 Straighten the thumb joint between the thumb and the index finger of other hand.

**C Thumb Web**  
 In patients with combined ulnar-medial palsy thumb web contracture may develop, or may be present. Two exercises help to prevent a contracture, overcome a mild contracture or prevent worsening:

**C1 'Rub' thumb web space with the ulnar border of the other hand pushing against the first metacarpal bone.**

**C2 'Interlock' the thumb and press with the thumb against the metacarpal of the thumb.**

Figure 4-2a,b Exercises for the paralysed hand.

### **Aim of exercises:**

- 1 Mobile 'claw hand': to prevent joint stiffness.
- 2 Stiff 'claw-hand': to overcome/decrease joint stiffness or prevent worsening.

Patients with a mobile 'claw-hand' only need to do the exercises listed under A. Patients who have stiffness of the finger joints should always start with the B exercises and finish with the A exercises.

### **Surface**

The patient is instructed to do the exercises on his/her upper thigh. This provides for a soft surface and the back of the knuckle joints is protected. Because the patient may have been soaking and oiling his hands before doing his exercises, it is advisable that the patient puts a piece of old cloth on his thigh to protect his clothes.

### **NOTE**

- Care should be taken not to 'break' or further damage the skin when there are skin cracks.

### **SPLINTING**

Generally speaking, splints may serve two purposes:

- a) facilitation of use (functionality) of the hand or foot and
- b) prevention or correction of secondary impairments.

#### **a) Facilitation of use**

Wrist extension is essential for most activities of daily living (ADL) involving the hands. In patients with wrist drop, wrist extension can be achieved with a so-called cock-up splint. This splint can be attached to the hand either on the volar or dorsal side. The fingers and thumb should be free to move in extension/flexion

and opposition. There is usually no need to maintain the fingers in extension by a modification of the splint.

In patients with median nerve palsy, dynamic thumb opposition can be achieved by a rubber band that is directed to the thumb from the ulnar side of a wristlet.

A footdrop can be corrected by a back splint that is worn in the shoe or by a footdrop spring device. This orthosis is on the anterior side of the lower leg and originates from above or below the knee. It is usually made of leather (straps) in which a spring can be incorporated.

A splint is rarely needed for a patient with 'claw' fingers. Only if a splint would enhance the function of the hand would a splint be justified.

### **b) Prevention or correction of secondary impairments: contractures**

The most likely joints to contract in the hand are the PIP joints. Basic exercises (see above) will prevent and may overcome mild contractures. With more severe contractures serial finger casting with Plaster of Paris has been shown to be most effective in releasing contracted PIP joints.

Finger flexor tightness may develop secondary to longstanding claw position of the fingers. Serial casting with wrist and fingers in extension will be effective in overcoming tightness of the extrinsic finger flexors.

A thumb web contracture may develop in the presence of paralysed intrinsic muscles that oppose the thumb. Serial casting of the thumb in maximum opposition and abduction will be beneficial in releasing the contracted tissues. It is mandatory that before the application of a new cast the patients do the necessary exercises (Fig. 4-2).

Generally speaking, no specific exercises are needed for the paralysed foot. The likelihood of a severe Achilles tendon contracture develop-

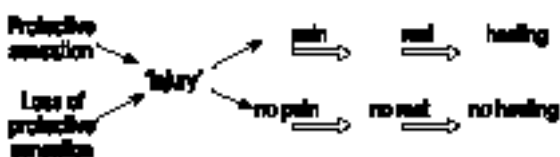
ing in ambulant patients is rare. Moreover, in cultures in which squatting is a common 'exercise' in 'toilet visits' or where people just commonly sit down (squat) to rest or 'chat', the Achilles tendon will maintain adequate length for walking. However when footdrop corrective surgery is carried out the Achilles tendon usually needs to be surgically lengthened to allow the tendon transfer to function adequately.

### **ULCER CARE**

One of the main concerns in the management of the a-sensate hand or foot is the (re) occurrence of ulcers and injuries. Patients with loss of protective sensation need to know how to care for their insensitive limbs and how to prevent/ minimise the risk of an ulcer (see above).

Once an ulcer or injury is present they should treat it as if they can feel the pain.

The sensitive hand or foot would not be used or activities would be done in a different way not to feel pain until such time when there is no more pain. By that time the tissues are healed. Pain is a natural way (gift) of 'splinting' a painful limb.<sup>4</sup>



**FIGURE 4-3** Rest is the treatment for an ulcer/injury.

Rest can be accomplished in a variety of ways. As most of the ulcers will occur on insensate feet we will give some methods to rest the ulcerated foot. Taking pressure off the ulcer is usually achieved by crutches or bed rest. Minimising pressure can be achieved by POP walking casts and modifications to the footwear.

The best option is decided between health worker and patient but will often depend on what is available and practical.

**a) Bed-rest:** Not always practiced and practical. Patients want to go outside and sit in the sun, go to the bathroom, or play games in a recreation room.

**b) Pair of crutches:** These can be given to most patients for walking.

**c) Trolley:** This is a small stool with wheels. This is especially suitable for patients that can not use their hands. They can 'propel' themselves with the non-ulcerated foot or with the heel(s) of affected feet as most ulcers occur on the forefoot.

**d) Wheelchairs:** Should not be used for patients with plantar ulcers! When a patient can not 'handle' crutches, can not bear weight on both feet, and a trolley is not an option, only then should a wheelchair be given.

**e) Heel-walking:** If an ulcer is located on the forefoot, especially with only one foot affected, patients can be taught to walk on their heel. (Not for patients with footdrop!)

*Providing splints for patients with plantar ulcers to rest their feet may create a sense of dependency on splints. "Splints are needed to heal an ulcer" (not true).*

**Partial** weight bearing takes place in a **Total Contact Cast**.

Total Contact Casting is very effective in the healing of plantar ulceration. (See appendix A)

There is evidence that 'some' weight bearing on a granulating ulcer enhances ulcer healing more than non-weight-bearing.

Generally, no medication either by mouth, injection or on the ulcer is needed to heal an ulcer. Soak and wash an ulcer and keep it clean.

A dressing will prevent dirt from entering into an ulcer.

## ELECTROTHERAPY AND OTHER PHYSICAL THERAPY MODALITIES

Electro-stimulation is often used in peripheral nerve injuries. There is no evidence that electrotherapy will help in the recovery of peripheral nerve function or muscle strength. It may aid in slowing down the rate of atrophy but electrostimulation sessions will have to be frequent (a few times daily every day of the week). As soon as there is evidence of returning muscle function purposeful activities/exercises should be instructed to the patient.

## ULTRASOUND/TENS

Ultrasound and TENS (Transcutaneous Electrical Nerve Stimulation) could be beneficial in the treatment of painful nerves as sometimes seen in leprosy. The relief of pain by these modalities, however, has not been shown in controlled clinical studies.

## WAX BATH

Wax bath is often given for patients with insensitive hands and/or contractures, sometimes postoperatively following tendon transfer surgery. If the purpose of wax bath is to make the skin 'supple' then this objective could also be achieved by soaking in water. The 'superiority' of a wax bath over water soaking in achieving this objective has not been shown. A wax bath may create a sense of dependency in patients who would not soak their dry hands and feet when discharged from a hospital/clinic where a wax bath was used.

## CONCLUSION

Early diagnosis of leprosy can prevent nerve function impairment in many patients. Early

diagnosis of nerve function impairment can also prevent permanent nerve function impairment in many persons through appropriate medical and educational intervention. If nerve function is lost, secondary impairments due to sensory, autonomic and motor impairment can be prevented or corrected by strategies of self-care, education to prevent (re) ulceration and surgery.

## REFERENCES

1. Birke JA, Rolfsen RJ: Evaluation of a self-administered sensory testing tool to identify patients at risk of diabetes-related foot problems. *Diabetes Care* 1998;21:23-25, 1998
2. Birke JA, Brandsma JW, Schreuders TAR, Piefer A: Sensory testing with monofilaments in Hansen's disease and normal control subjects. *Int J Lepr* 68:291-298, 2000
3. Brakel WH van, Khawas IB, Gurung KS, Kets CM, Leerdam ME van, Drever W: Intra- and intertester reliability of sensibility testing in leprosy. *Int J Lepr* 64:287-298, 1996
4. Brand PW, Yancey P: *The Gift of Pain*. Grand Rapids, Zondervan, 1993
5. Brandsma JW, Brakel WH van, Anderson AM, Kortendijk AJ, Gurung KS, Sunwar SK: Intertester reliability of manual muscle strength testing in leprosy patients. *Lepr Rev* 69:257-266, 1998
6. Brandsma JW: Monitoring motor nerve function in leprosy patients. *Lepr Rev* 71:258-267, 2000
7. Brandsma JW, Brakel WH van: Protocol for motor nerve function assessment in leprosy and related research questions. *Ind J Lepr* 73:45-58, 2001
8. Brandsma JW, Schreuders TAR: Sensible manual muscle testing to evaluate and monitor strength of the intrinsic muscles of the hand: a commentary. *J Hand Ther* 14:273-278, 2001
9. Novak CB: Evaluation of hand sensibility: a review. *J Hand Ther* 14:266-272, 2001

## Further recommended reading

- Brand PW: *Insensitive Feet*. The Leprosy Mission London, 1996
- Basker RJ: *Prevention of Impairments and Disability in Leprosy*. Video and booklet, SLR & TC, 632 106, Karigiri, India, 2000
- ILEP: *Prevention of Disability: Guidelines for Leprosy Control Programmes*. London, 1993
- Kelly E: *Physical Therapy in Leprosy for Paramedicals*. American Leprosy Missions, 2nd ed. 1985
- Watson JM: *Preventing Disability in Leprosy Patients*. The Leprosy Mission, London, 1986
- Brandsma JW, Macdonald MRC, Warren AG, et al: Assessment and examination of the neurologically impaired foot. *Lepr Rev* 72:254-262, 2001
- Macdonald MRC, Brandsma JW, Warren AG, et al: Complications and management of the neurologically impaired foot. *Lepr Rev* 72:263-275, 2001
- Cross H, Sane S, Dey A, Kulkarni VN: The efficacy of podiatric orthoses as an adjunct to the treatment of plantar ulceration in leprosy. *Lepr Rev* 66:144-157, 1995

# Functional Anatomy and Assessment of the Hand

• J. WIM BRANDSMA  
M. EBENEZER

## INTRODUCTION

This chapter reviews the anatomy and (patho)kinesiology of the hand as it relates to weakness and paralysis of the intrinsic and/or extrinsic muscles. First, the muscles of the hand and their innervation will be discussed. Second, normal hand function will be reviewed followed by a discussion of the primary and secondary impairments that may be present, or that may develop when there is weakness of the muscles of the hand.

The chapter concludes with a discussion of specific examination techniques for the hand. This will be discussed in relation to tendon transfer procedures aimed at improving the function of the hand.

## ANATOMY REVIEW

The muscles of the hand can be divided into extrinsic and intrinsic muscles. The extrinsic muscles are the long muscles for movements of the wrist and fingers originating proximal to the hand. The intrinsic muscles are the small muscles within the hand itself.

The extrinsic muscles can be divided into five groups of three muscles each: 1) wrist flexors; 2) wrist extensors; 3) finger flexors; 4) finger extensors and 5) a fifth group comprising the thumb extensors (Table 5-1). An additional group of five muscles make up the pronators and supinators of the forearm (Table 5-2).

Table 5.1: Extrinsic Muscles of the Hand (5x3)

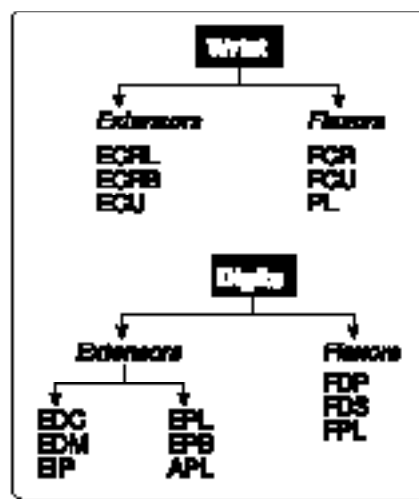



Table 5.2: Primary Pro- and Supinators of the Hand/Wrist



The intrinsic muscles can be divided into five groups of four muscles each: 1) hypothenar; 2) thenar; 3) dorsal interossei; 4) palmar interossei and 5) lumbricals (Table 5-3).



Table 5.3: Intrinsic Muscles of the Hand (5x4)

<b>Hypothenar</b>		<b>Thenar</b>
Abd. dig. min.		Abd. poll. brevis
Flex. dig. min.		Flex. poll. brevis
Opp. dig. min.		Opp. poll.
Palm. brevis		Acid. poll.
	<b>Dorsal</b>	<b>Palmar</b>
<b>Lumbricals</b>	<b>Interosseal</b>	<b>Interosseal</b>
Index	Index	Index
Middle	Middle (?)	
Ring		Ring
Small	Small	Small (Thumb)

### Innervation

- 1 All *extrinsic extensors* are innervated by the *radial nerve*.
- 2 All *extrinsic flexors* are innervated by the *median nerve* except: the ulnar half of the flexor digitorum profundus (FDP) and the Flexor Carpi Ulnaris (FCU) which are innervated by the *ulnar nerve*.
- 3 All *intrinsic muscles* are innervated by the *ulnar nerve* except: the muscles that will bring the thumb into opposition, and the lumbricals for the index and middle finger which are innervated by the *median nerve*.

When dealing with a peripheral neuropathy or nerve injury it may be helpful to recall the innervation of the individual muscles. This will help to establish the extent of the paralysis, monitor changes in muscle strength and to determine which muscles might be available for transfer.

When dealing with peripheral neuropathies or nerve injuries, the surgeon and therapist need to be aware of the presence of a Martin Gruber 'anastomosis'.<sup>4,11,15</sup> In the Martin-Gruber anastomosis nerve fibers from the

median nerve in the forearm cross over into the ulnar nerve (Fig. 5-1). Reported prevalence of this occurrence is between 10-25 percent. In such cases a variable number of intrinsic muscles on the radial side of the hand, but especially the flexor pollicis brevis and first dorsal interosseus, are median innervated through the distal ulnar nerve. In 'confirmed' high ulnar lesions the clinical signs and symptoms may therefore be fewer or less obvious. In the presence of a Martin-Gruber anastomosis, a high ulnar palsy and a low median palsy in the same extremity may confuse the surgeon and therapist that are unaware of this 'anomaly'. A patient with a high ulnar lesion and a low median lesion may still be able to abduct the thumb and may have a very active first dorsal interosseus muscle.

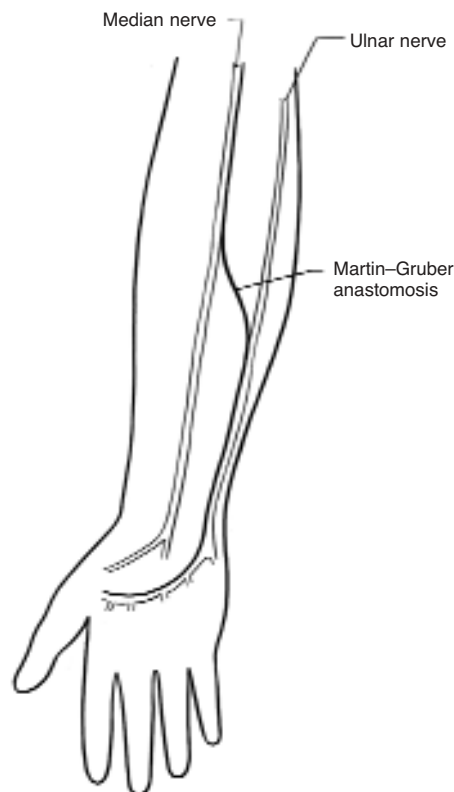


FIGURE 5-1 Martin-Gruber 'anastomosis'.

## BASIC FUNCTIONS OF THE HAND: GRASPING AND PINCHING

Many hand functions require an extended and stable wrist. Weakness in wrist extension may cause the wrist to go into flexion when a strong grip is required. Wrist extension (radial innervated muscles) may be corrected 'statically' by providing a splint that will support the wrist in extension. It may also be corrected 'dynamically' by a tendon transfer.

Full finger extension is both a function of the radial innervated wrist muscles and the intrinsic finger muscles, primarily the interossei. Full finger extension can also be enhanced by either a splint or a tendon transfer. Restoring full finger extension, however, in a radial palsy is functionally less important than restoring wrist extension.

In a radial nerve palsy thumb interphalangeal (IP) extension is usually still possible. Surgeons and therapists should not mistake this to be the result of 'anomalous' innervation or think that the radial nerve is only partially damaged. The intrinsic muscles of the thumb have an expansion into the thumb extensor mechanism similar to the extension of the interossei and lumbricals into the extensor mechanism of the fingers.

Loss of strength in the median innervated thenar muscles will 'dis-able' the thumb. The thumb will often not be able to 'oppose' the fingers in various activities of daily living for which a pinch is required. Again, a splint could be provided which will enable the thumb to meet the other fingers in opposition. A single tendon transfer, an 'internal-dynamic' splint, will achieve the same. Some cases with an isolated median nerve palsy in which the FPB is entirely ulnar innervated may show full opposition of the thumb.

If there is also weakness of the adductor-flexor muscles of the thumb then grip strength may also be impaired. Generally speaking, the

*median* innervated muscles *position* the thumb for pinching, the *ulnar* innervated muscles, adductor-flexor group, provide the *power* that is needed in pinch activities. In addition, the first dorsal interosseus is an important muscle providing pinch strength.

Weakness or paralysis of the ulnar innervated thenar muscles may result in a flexion deformity of the thumb IP joint (Froment's sign) or hyperextension of the metacarpophalangeal (MCP) joint (Jeanne's sign). Whether these impairments occur depends on such factors as: use of the hand, hand dominance, degree of weakness, innervation pattern of the Flexor Pollicis Brevis (FPB), MCP joint articulating surfaces, and joint laxity.

## PATHOKINESIOLOGY OF THE ULNAR PARALYSED HAND

In lesions of the ulnar and median nerves, the intrinsic muscles of the hand are paralysed and will fail to modulate and balance the role of the extrinsic muscles. In peripheral neurological conditions, weakness and paralysis follow the innervation pattern of the nerve. This will not be the case in 'central' neurological conditions or a motor neuron disease. The impairments commonly seen in isolated nerve lesions will then be less severe or may even be absent.

### **Clawing**

Weakness or paralysis of the intrinsic muscles of the fingers may result in the so-called claw position. Loss of the primary flexors of the MCP joints (interossei) causes the fingers to 'claw' when the patient is asked to fully straighten the fingers, or open the hand. Often patients will get into the habit of flexing the wrist when asked to straighten the fingers. Wrist flexion enhances opening of the hand because it decreases tension in the long finger flexors thereby facilitating opening of the hand by the extrinsic finger extensors.

Clawing may be *overt*, obvious, or it may only become evident on finger loading: *latent*, or hidden clawing. A push on the volar side of the proximal phalanx by the examiner will reveal weakness and will cause the finger to buckle. The interossei are the anti-clawing muscles.

Alternatively, to reveal weakness in the interosseus muscles, the examiner could ask the patient to grasp his own forearm. The fingers with weak/paralysed interossei will show hyperflexion of the proximal inter-phalangeal (PIP) and limited flexion of the MCP joints (compare both hands when only one is weak/paralysed). The degree and extent of clawing may be dependent on such factors as: duration of the paralysis, degree of weakness of the extrinsic finger muscles, whether there is a high or low ulnar palsy, and the presence of a Martin-Gruber nerve anastomosis.

Clawing is a visible, and functional, impairment. However, it is not the only functional impairment when there is weakness or paralysis of the ulnar innervated muscles (Table 5-4).

Table 5-4: Primary Impairments

1. Loss of protective sensation and functional sensibility.
2. Clawing due to loss of primary finger (MCP) flexors (interossei).
3. Reversed finger closing pattern: distal to proximal.
4. Loss of ab- and adduction of fingers.
5. Loss of metacarpal arch / ulnar opposition (hypothener muscles).
6. Decreased grip strength.
7. Decreased pinch strength (pulp-pulp and key-pinch).

A second functional defect is the 'reversed' finger closing pattern. In the normal hand the finger joints more or less flex sequentially: first the MCP joints, followed by the PIP joints and finally the distal inter-phalangeal (DIP) joints.

This makes it possible for the fingers to grasp larger objects. This pattern is reversed in the fingers with paralysis of the intrinsic muscles. The fingers start flexing from a hyperextended position in the MCP joints and the finger closing sequence will be from distal to proximal making it difficult for patients to grasp larger objects.

Abduction and adduction of the fingers will also be lost. A tendon transfer, by virtue of the insertion of the grafts, is aimed at bringing the fingers together in an adducted position, but active abduction and adduction will not be restored.

Paralysis of the hypothener muscles causes the hand to become 'flat'. Ante- or propulsion of the fifth and fourth metacarpals is important in cupping of the hand. Cupping of the hand is important in cultures in which for drinking and/or eating, no other 'tool' but the hand is used. Propulsion of these metacarpals also contributes to grip strength and secures the grip.<sup>4</sup>

The main functional impairment, however, may be loss of functional sensibility and loss of protective sensation. Patients may unwittingly injure their hands. They must learn to substitute with their eyes (vision) for the loss of functional sensibility and protective sensation and use adaptive (safety) devices to protect their insensitive hands.

### Secondary impairments (Table 5-5)

The hand with paralysis of intrinsic and extrinsic muscles may be in danger of developing secondary impairments.<sup>5</sup> These will develop as a result of muscle imbalance, 'clawing', and loss of opposability of the thumb. Splinting and specific exercises will prevent these secondary defects (Chapter 4). If present at the time of surgery they may influence the final outcome of tendon transfer surgery.

In the a-sensate hand, injuries (e.g. burns, wounds) are considered secondary impairments. Tool adaptations and an adapted life

style modifications should minimise the occurrence of these impairments.

Table 5.5: Secondary Impairments

1. Ulcers/Scars/Absorption
2. Contractures (PIP joints; skin/joint structures)
3. Long Finger Flexor Tightness
4. Contracture Oblique Retinacular Ligament
5. Hooding/Attenuation of extensor mechanism
6. Habitual wrist flexion
7. Z-thumb

### **Joint contractures**

The joints most likely to contract are the PIP joints. As long as there is sufficient strength in extrinsic finger extensors and flexor muscles patients will continue to use their hands thereby maintaining flexion and extension range of motion of the MCP joints. The DIP joints are usually pushed into extension when objects are grasped which will maintain the mobility in these joints. To test for this, passive extension of the PIP joint is attempted with the wrist and MCP joints flexed. Extension limitation of the PIP joint will be present.

### **Flexor tightness**

Longstanding claw position of the fingers, together with the often present habitual wrist flexion position, may result in adaptive shortening of the extrinsic finger flexors.

The clinical test for tightness is as follows: The examiner keeps the wrist and MCP joints in flexion. Complete PIP extension, in the absence of joint contractures, should then be possible without feeling restraint from the extrinsic finger flexors. The test is now repeated with both the wrist and MCP joints fully extended. Complete DIP-PIP joint extension may now no longer be possible when adaptive shortening of the multi-articular finger flexors is present.

### **Skin Contracture**

Longstanding clawing of the fingers will result in contracture of the skin on the volar surface of the finger. To test for this, passive extension of the finger is attempted with the MCP joints extended. When a skin contracture is present the extension limitation decreases as the MCP joint flexes, but there is no change with wrist flexion. Tightness of the skin can also be felt with forced extension of the finger.

### **Contracture of oblique retinacular ligament**

Some patients with long-standing claw position of the fingers may develop a contracture of the oblique retinacular ligament. The function of this ligament has been explained as contributing to the synchronisation of finger flexion and extension.

To test for contracture of this ligament the examiner keeps the PIP joint extended and then assesses range of motion and resistance towards DIP flexion. In the second part of this test DIP flexion is assessed with the PIP joint in flexion. A significant difference between range of flexion in the two tests denotes a contracture of this ligament. In severe contractures hyperextension of the DIP joint may be seen when the PIP joint is extended.

### **“Hooding” or attenuation of extensor mechanism**

A chronic flexion posture of the fingers may result in adaptive changes (growth-lengthening) of the extensor hood. In severe cases this may result in anterior displacement of the lateral bands which then often come to lie on the anterior side of the PIP joint axis. The result is functionally rather like the Boutonnière deformity. A lag in active-assisted extension may develop.

Asking the patient for assisted- active extension reveals 'stretching' of the extensor mechanism. The examiner stabilises the MCP joints

and asks for active extension. The lag (difference) between active-assisted and passive extension angles is an indication of the severity of 'hooding' of the extensor mechanism. This, of course, is only a valid test if the extrinsic finger extensors are not weak/paralysed and there are no severe contractures of the PIP joints.

#### **Habitual wrist flexion posture**

In the presence of paralysis of the intrinsic muscles of the hand the patients may develop the habit of flexing the wrist to enhance opening of the fingers. With wrist flexion the tension in the extrinsic finger flexors decreases which will facilitate a better opening of the hand (less clawing).

#### **Z-thumb**

Depending on the innervation pattern of the FPB, the MCP joint articulating surfaces (mobility) and use of the hand, a patient may develop IP joint flexion deformity and MCP joint hyperextension deformity.

### **SECONDARY DEFECTS IN THE PRESENCE OF PARALYSIS OR WEAKNESS OF THE MEDIAN AND/OR RADIAL INNERVATED MUSCLES**

Patients who have lost the ability to extend the wrist have a poorly functioning hand. Many activities will require an extended wrist. Wrist extension can be achieved with a splint. Loss of wrist and finger extension may contribute to 'tightening' of the wrist- and finger flexors.

With paralysis of the intrinsic muscles of the thumb, the thumb loses its ability to oppose the other fingers in pinch activities. The thumb will come to lie in an adducted and supinated position next to the 2nd metacarpal. A thumb web contracture is the main complication that

may occur. Splinting and exercises will prevent or may overcome a thumb web contracture.

### **ASSESSMENT**

In the preceding paragraphs the relevant basic anatomical features of the hand and the assessment of specific primary and secondary impairments that may occur in the hand with paralysis of the intrinsic and extrinsic muscles were discussed. Now we will briefly discuss the four main general assessment areas: 1) angle measurement; 2) muscle testing; 3) sensory testing (impairment level) and 4) functional assessment (activity level). It should be remembered that functionality of the hand and the result of interventions (splints/tendon transfers) are determined by the presence and extent of primary and secondary impairments as discussed in the first section of this chapter. (See also Chapter 21 on pre- and postoperative rehabilitation, Chapter 4 on prevention of impairments and the assessment forms in the appendices).

#### **Angle measurement**

The key joints in the hand with paralysis of the intrinsic muscles to evaluate are the PIP joints of the fingers and the IP and CMC joint of the thumb. The results of various PIP joint extension measurements indicate the presence and severity of primary and secondary impairments.

##### **a) Active extension**

The examiner asks the patient to extend the IP joints while the patient tries to maintain the MCP joints in active flexion. The lag in active PIP extension is recorded. Lag in extension is an indication of the in-effectiveness of the extensor mechanism (intrinsic) to extend the PIP joint in the weak/paralysed hand.

Alternatively, in the hand following tendon



transfer for intrinsic paralysis the extension angle is an indication of the efficacy of the tendon transfer to contribute to active extension of the IP joints.

#### **b) Assisted or assisted-active extension**

The examiner stabilises the MCP joints in some flexion. The patient is asked to actively extend the fingers at the IP joints. The examiner prevents MCP extension so that all extensor force is directed at the IP joints. A possible lag in assisted-active extension, in the absence of a contracture, is indicative of 'stretching' (hooding) of the extensor mechanism. This presupposes that the radial innervated extensors are not weak/paralysed.

#### **c) Passive extension (contracture angle)**

This angle measures the possible restraint in PIP extension when the examiner passively extends the PIP joint. Different tissues could contribute towards a lag in passive extension: skin, ligament and joint capsule. In other words, causes of a lag in passive extension could be in intra-articular and/or extra articular tissues.

#### **d) Thumb web**

In an ulnar-median palsy the first metacarpal may come to rest against the 2nd metacarpal. Active opposition is not possible and the thumb web and CMC joint may become contracted. There are different ways of measuring the thumbweb angle. The examiner can measure the angle between the first and 2nd metacarpal or the distance between the centre of the first and second metacarpal heads.<sup>13</sup>

### ***Muscle testing***

Manual muscle strength testing is useful in establishing the extent and degree of muscle weakness. In nerve injuries and neuropathies muscles strength is a 'proxy' for evaluating the

motor conduction of the nerve. The muscles are graded using the Medical Research Council 0-5 (MRC) scale. It should be realised that it is difficult and often impossible to grade individual muscles.<sup>6</sup> Some studies have reported on the reliability of manual muscle strength testing<sup>8</sup> (Chapter 2).

Grip- and pinch strength is also useful to evaluate and monitor strength. Both intrinsic and extrinsic muscles contribute to grip- and pinch strength. It has been shown that paralysis of the intrinsic muscles alone will greatly effect grip- and pinch strength. A sphygmomanometer (blood pressure cuff) can be converted into a grip- or pinch strength dynamometer.<sup>9,10,14</sup>

### ***Sensory testing***

Nylon filaments (Semmes-Weinstein monofilaments) are now the instrument of choice to evaluate and monitor sensory status of the skin. With a set of graded nylons the sensory status can be semi-quantitated. The level of protective sensation of the hand and foot has been established in various studies.

The main loss to the hand, however, when sensation is impaired, might be the loss of 'tactile gnosis' or functional sensibility. Some studies have determined a relation between functional sensibility and the 2-point discrimination test. For more information and testing techniques the reader is referred to Chapter 2.

### ***Functional assessment***

Different tests have been developed to assess 'functionality' of the hand. What is the hand able to do? With some degree of difficulty? Taking more time? With or without adaptation or substitution? Commonly used tests to assess hand function are grip strength and key pinch strength. The Moberg test and nine hole pegboard test assess hand dexterity, and grip contact assesses the pattern of hand closure.



The D.A.S.H. score (Disability of Arm, Shoulder and Hand) is a useful and valid assessment of hand disability, although its use has not been reported in leprosy.

To date, most studies reporting on the effects of tendon transfer surgery have reported on improved angles (appearance) and some on grip strength. It is often assumed that when the fingers have a proper opening and closing sequence, and when the thumb is an 'opposable' thumb again, that this will benefit the functionality of the hand. Studies are needed to show that this is the case. One scale is being developed, part of which will also be able to assess and monitor activities related to the hand in patients with neurologically impaired function of the hand.<sup>1</sup>

### **Postoperative assessment and review**

Surgeons and therapists alike should be interested in long-term outcome of the surgery. The result at time of discharge from the hospital may not be the same after a few months or years of active use of the hand. Forms that are helpful to review the surgery are given in the appendices. A critical appraisal of corrective surgery and comparing techniques may help the surgeon and therapist to make better decisions about management of the paralysed limb.<sup>2,7,12</sup>

### **REFERENCES**

1. Anderson AM, Benbow C, Ebenso J: Development of an activity limitation scale for persons with sensory loss. Abstract, Int Leprosy Congress, Salvador, Brasil, 2002. *Int J Lepr* 70(4):74A, 2002
2. Beine A: Reoperation in failed correction of claw fingers. *Ind J Lepr* 74:221-231, 2002
3. Brand PW, Hollister AM: *Clinical Mechanics of the Hand*. 3rd ed. St. Louis, Baltimore, Mosby, 1999
4. Brandsma JW, Birke JA, Sims MS: The Martin-Gruber innervated hand. *J Hand Surg* 11A:536-539, 1986
5. Brandsma JW: Secondary defects of the hand with intrinsic paralysis: prevention, assessment and treatment. *J Hand Ther* 3:14-19, 1990
6. Brandsma JW, Schreuders TAR: Sensible manual muscle testing to evaluate and monitor strength of the intrinsic muscles of the hand: a commentary. *J Hand Ther* 14:273-278, 2001
7. Brandsma JW, Richard BM: The need for controlled studies in tendon transfer surgery of the hand. *Ind J Lepr* 69:77-82, 1997
8. Brandsma JW, Brakel WH van, Anderson AM, Kortendijk AJ, Gurung KS, Sunwar SK. Intertester reliability of manual muscle strength testing in leprosy patients. *Lepr Rev* 69:257-266, 1998
9. Desrosiers J, Hebert J, Bravo J, Dutil E: Comparison of the Jamar dynamometer and the Martin vigorimeter for grip strength measurements in a healthy elderly population. *Scand J Rehab Med* 27:137-143, 1995
10. Kozin SH, Porter S, Clark P, Thoder JJ: The contribution of the intrinsic muscles to grip and pich. *J Hand Surg* 24A:64-72, 1999
11. Leibovich SJ, Hastings H: Martin-Gruber revisited. *J Hand Surg* 17A:47-53, 1992
12. Malaviya GN: Some more about unfavourable results after corrective surgery as seen in leprosy. *Ind J Lepr* 74:243-257, 2002
13. Murukar PM, Brandsma JW, Anderson AM, Gurung KS: Reliability of thumb web measurements. *J Hand Ther* (accepted for publication).
14. Soares D, Riedel A: A simple and inexpensive pinch meter to detect subclinical weakness among leprosy patients. *Lepr Rev* 68:55-60, 1997
15. Uchida Y, Sugioka Y: Electrodiagnosis of Martin-Gruber connection and its clinical importance in peripheral nerve surgery. *J Hand Surg* 17A:54-59, 1992

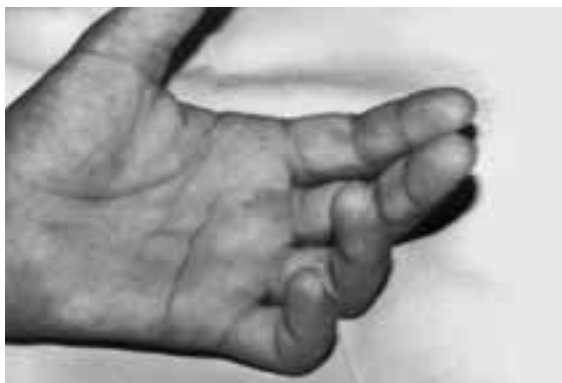## Ulnar Nerve Palsy

• F. DUERKSEN  
R. SCHWARZ

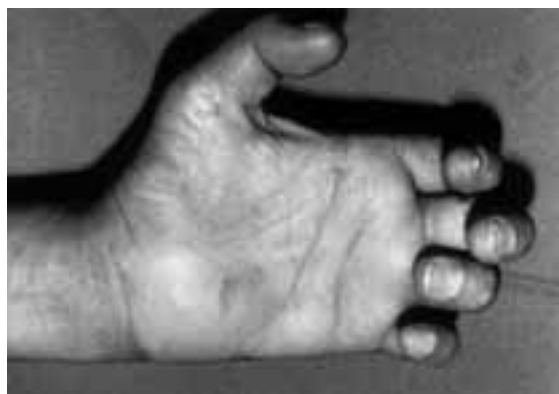### INTRODUCTION

This chapter discusses the various techniques that can be used to correct the hand with paralysis of the ulnar-innervated muscles. For a relevant understanding of the anatomy of the hand and the pathokinesiology of the 'intrinsic minus' hand the reader may also want to refer to Chapter 5. First, the functional impairments of the hand will be briefly discussed. The author then will discuss the procedures to correct the hand which can be divided in what are commonly called static (passive) and dynamic (active) procedures or tendon transfers.

The mixed nerve trunk most often damaged by leprosy in the upper extremity is the ulnar nerve. Less often the median nerve is involved, usually in combination with the ulnar nerve. The radial nerve is rarely involved. With paralysis of the intrinsic muscles, the hand adopts the typical posture of clawing, initially maybe only the ring and little fingers (Fig. 6-1), eventually often all fingers (Fig. 6-2). Latent or 'hidden' clawing is usually present in the index and middle fingers in a recent ulnar palsy.



**FIGURE 6-1** Ulnar nerve paralysis with overt clawing confined to the ring and little fingers.



**FIGURE 6-2** Ulnar nerve palsy with clawing of all four fingers.

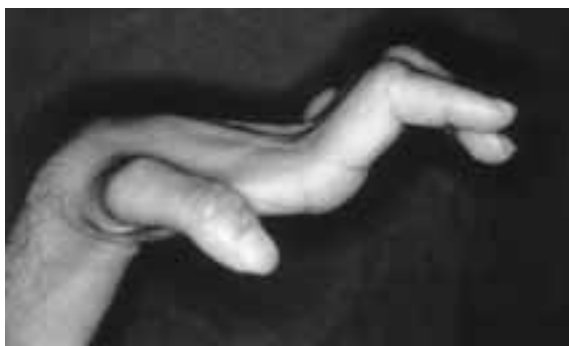The clawing of the fingers can be very stigmatizing in leprosy endemic areas, and is especially obvious when greeting in almost any culture. It becomes also evident when eating in cultures that use their fingers.

The important loss of sensation in ulnar nerve palsy is in the ulnar border of the hand. This may not seem important but most of our activities at home and at work are with the hand on surfaces like a desk, carpentry bench, working on a car motor or with tools in the garden. These activities all require the fine feedback of the little finger exploring first the areas where the hand is going to act. The loss of sensation therefore greatly increases the disability of the already paralyzed hand.

### PATHOPHYSIOLOGY OF DISABILITIES IN THE INTRINSIC MINUS HAND

With ulnar nerve palsy all interosseous muscles are paralyzed and therefore the primary flexors

of the metacarpophalangeal (MCP) joints are absent. This leads to the hyperextension deformity of the MCP's when the extensor digitorum communis tries to extend the finger to open the hand. Since the extensor digitorum is tethered by the sagittal bands, there is hyperextension of the MCP (Fig. 6-3), and the distal part of the extensor loses excursion over the distal joints and therefore the flexion posture of the proximal interphalangeal joint (PIP) and distal interphalangeal joint (DIP) occurs.<sup>12,14,16,20,23</sup>



**Figure 6-3** Ulnar-median palsy with metacarpophalangeal hyperextension.

The intrinsic minus hand loses power in grip but has also a decrease in control of the fine coordinated movements necessary in delicate work. With ulnar nerve palsy the hand loses 40-70% of power.<sup>15,19,33</sup> The ulnar nerve provides most of the strong motor power to the hand through the flexor digitorum profundus, hypothenar muscles, all interossei and the adductor- and flexor pollicis muscles.

By not being able to spread the fingers the hand loses span of grasp. Surgery is indicated when there is disability in grasp, grip, pinch, greeting, eating, flat hand, human contact and when the deformities caused by the intrinsic paralysis lead to stigma and handicap.<sup>26,28-30</sup>

If the median nerve is still intact, the lumbricals to index and long fingers, together with the tissue restraint of the volar structures of the MCP joint, can maintain extension for some

time, with normal appearance, but there is very minimal primary MCP flexion strength. It is for these reasons that tendon transfers should always be done to all four fingers, even if the paralysis is only ulnar.<sup>4,13</sup>

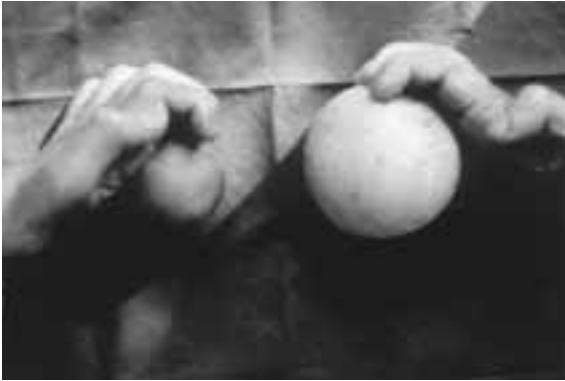The distal palmar arch is lost or reversed in ulnar nerve palsy mainly due to loss of hypothenar muscle function. This does not allow for cupping of the hand and keeping of water or other substances. For a secure grasp it is also essential to have a transverse distal metacarpal arch.<sup>22,24,25</sup>

The fine finger coordination and sequence of joint movements or synergism is lost with paralysis of the intrinsic muscles.<sup>20,28</sup> The normal hand initiates flexion at the MCP joints, followed by flexion at the proximal interphalangeal (PIP) and distal interphalangeal (DIP) joints. In the ulnar palsied hand this sequence is reversed (Figs. 6-2, 6-4b). This represents loss of a great part of normal hand function.

The intrinsic minus or claw position, predisposes to high pressure points on the finger tips and the metacarpal heads area. (Fig. 6-4a and 6-4b) Flexion contractures predispose to fissures when fingers are stretched. With loss of protective sensation, this can lead to wounds and infection. Therefore, by correcting the claw hand, wounds can be prevented. Almost all reconstructive operations done on leprosy patients have a preventive aspect.



**FIGURE 6-4a** Normal grasp with pressure equally distributed over surface of the palm.



**FIGURE 6-4b** Grasp in ulnar palsy with pressure concentrated over fingertips and MCP joints.

It is important to emphasize the importance of the flexor digitorum profundus of the 5th and 4th fingers in grasp, as in closing the fist and also the importance of the strong flexor carpi ulnaris stabilizing the wrist in ulnar deviation in all power functions. These muscles are also innervated by the ulnar nerve in the forearm and are often totally or partially paralyzed.

The patient needs to be informed in detail about what surgery will most likely achieve. Only then can and should he or she make the decision to have surgery. It is also mandatory that a plan for the whole person should be made, not only for the hands. Patients also have to demonstrate that they have learned to care for hands that have loss of protective sensation. It is tragic to sometimes see a hand beautifully reconstructed by tendon transfers, rapidly being destroyed by the new forces because the patient has not incorporated care of the anaesthetic hand. We also need to assess if the patient can understand what the tendon transfer will do and if he or she will cooperate fully i.e. is motivated.

It is important to stress the absolute need for physiotherapy and/or occupational therapy in the pre-and postoperative period.<sup>2,13</sup> Contractures need to be corrected, and the muscle to be transferred must be isolated and later re-educated in its new function. As a gen-

eral rule, if contractures of PIP and/or DIP joints are severe, even after full correction it will be necessary to splint these fingers also in the post operative period to prevent recurrence.

Once the decision to operate has been made, the next step is to decide on the surgical technique to be used.

## SURGICAL PROCEDURES

The surgical techniques can be classified as Static and Dynamic procedures. The dynamic techniques can further be classified according to the muscle used, the insertion of the transferred tendon and/or the route the transfer takes.

### STATIC PROCEDURES

These procedures basically provide a static block preventing MCP hyperextension. In this position the sagittal bands move distally and the extensor digitorum has enough excursion to extend the PIP and DIP joints. These procedures do not provide an active MCP joint flexor. The normal synergistic closure mechanism is not restored, but some of the mechanics and position of the hand are restored as well as the appearance. These procedures are normally not used in leprosy, unless there is a triple or high median paralysis and there are not enough muscles available for transfer. Static procedures are used mostly in quadriplegia or brachial plexus paralysis. Some surgeons have a preference for static procedures and report good results. Static surgical procedures do not require much re-education and avoid complications that may happen with a dynamic procedure e.g. an intrinsic plus or swan neck deformity.

Many procedures have been described. All follow the same principle of limiting MCP extension.

### Parkes graft tenodesis<sup>22</sup>

A fascia lata tendon graft is sutured into the distal edge of the transverse ligament of the carpal tunnel, then divided into four slips and tunneled through the lumbrical canals and inserted into the lateral band of each finger. Tension is regulated so that the MCP joints are in 15 to 20 degrees of flexion with the wrist in neutral. With wrist action some control can be gained over the degree of tension in the tenodesis.

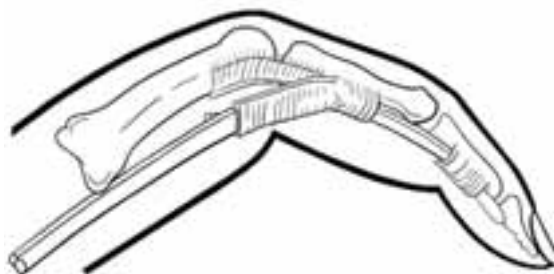### Zancolli's volar MCP capsulodesis

In this operation the volar plate of the finger MCP's is sectioned transversally or in a longitudinal flap and then re-sutured, overlapping in such a way that the MCP is held in 20° of flexion.<sup>1,17,21</sup> This surgical technique does not restore normal hand kinetics, but allows the EDC to open the hand for grasp. The main problem encountered is that the capsule stretches with time. Tenodesis are easier to perform if one prefers a static procedure. Technically the volar MCP capsulodesis is not easy. It requires good surgical experience.

### Pulley advancement (Bunnell – Palande)

In combination with volar capsulodesis or alone, advancement of the proximal edge of the A1 pulley creates a semi-active flexion of the MCP.<sup>1,3,8,9,17,21</sup> Through a volar approach, the A1 pulley is cut longitudinally at each side, close to the insertion of the pulley into bone, for a distance of 1-1.5 cm (Fig. 6-5), until the flexors bowstring on contraction. If not enough pulley is liberated, the moment arm of the flexor is not enough to flex the MCP. For this reason the pulley advancement works best in combination with volar capsulodesis. Some surgeons report good results with this operation.

There are many other static procedures using tendon graft as tenodesis to block the



**FIGURE 6-5** Pulley advancement procedure. The A1 pulley has been cut close to the bone on each side.

MCP joints in some degree of flexion.<sup>28-30</sup> An interesting technique is Srinivasan's extensor diversion graft.<sup>31</sup> Four fascia lata strips are tunneled through the interosseous spaces from the dorsum of the hand, volar to the transverse intermetacarpal ligament and again to the dorsum of the proximal finger. The tendon graft is sutured to the extensor tendon on the dorsum of the hand and to the lateral bands in the finger. Tension is such, that the MCP's are held in 20° of flexion. There is a small dynamic component in this tenodesis that initiates MCP flexion. A more dynamic tenodesis described by Warren (personal communication) is to attach a graft to the lateral bands and fix the proximal end to the palmaris longus or flexor carpi radialis insertion with the MCP joints at 20 degrees with the wrist in the neutral position. This transfer will give some MCP flexion on wrist extension.

In general, static surgical procedures for correction of the intrinsic minus hand are poor substitutes for normal intrinsic action. For these reasons I recommend a dynamic transfer whenever possible.

## DYNAMIC PROCEDURES

### Wrist Motors

#### Brand extensor to flexor four tailed (EF4T)

The motor or muscle used is the extensor carpi radialis longus (ECRL).<sup>2,4</sup> Since this tendon is too short to reach the fingers, a graft is needed.



Brand proposed the use of the plantaris tendon but it is often absent. For this reason we use fascia lata graft routinely which gives similar results.<sup>13</sup> There are special tendon strippers for plantaris and for fascia lata that can be used to minimize the incisions. An open tensor fascia lata graft can also be taken if the stripper is not available, although it is easy to use ladder-like small incisions and long Metzenbaum scissors to harvest the graft. The distal insertion of the transferred tendon is into the lateral bands of the extensor mechanism of the fingers.

### Technique

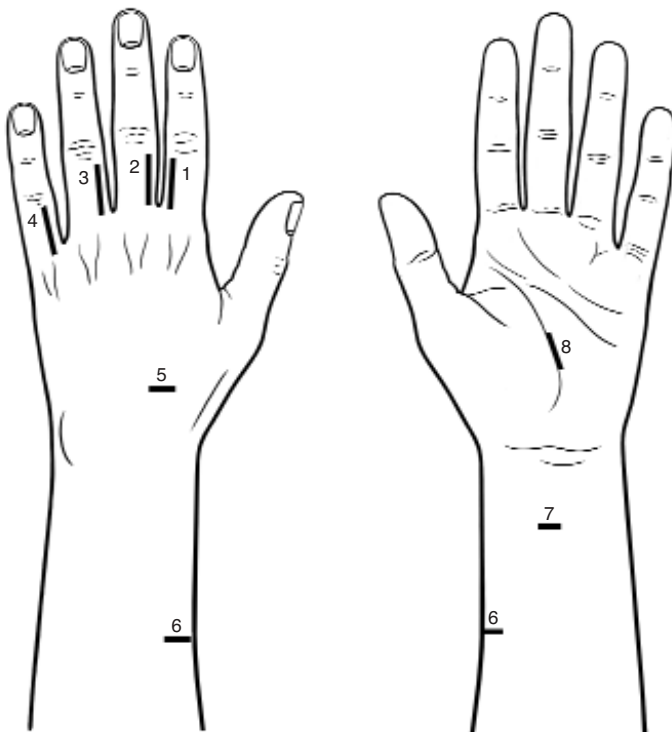
**Incisions:** The recipient area should be prepared first as this will minimize the exposure time of the transferred tendon if the insertion sites are exposed at the end of the procedure.

Incisions 1-4 are made on the dorsolateral border of the proximal phalanx on each finger (Fig. 6-6). Care is taken to preserve the dorsal

vein. The incision is on the radial side of little, ring and long finger and on the index it is done on the ulnar side. This facilitates the three finger (chuck) pinch with the thumb. This is the most commonly used form of pinch and is very important for people who eat with their hands. Note that the Chinese often prefer the index insertion on the radial side to facilitate holding chopsticks. The extensor mechanism is exposed, especially the lateral bands and the central tendon. The thin synovial film that covers the extensor mechanism is removed in the area where the transfer will be sutured, otherwise the synovial film might prevent firm adhesions of the transferred tendon.

Incision 5 - A 2-3 cm transverse incision is made on the dorsiradial aspect of the wrist. Feel for the insertion of ECRL and make the incision just over this. Protect the radial cutaneous nerve branches. Dissect the tendon of the extensor carpi radialis longus free (make sure it is not the brevis or extensor pollicis longus!) and transect the tendon near its insertion, grasping the proximal end with a hemostat.

Pulling on the tendon you can feel the movement in the mid forearm (on the radial side) and make incision N° 6 which is transverse and 2 cm long 10 cm proximal to the radial styloid. Free the extensor carpi radialis longus tendon from the brevis and with a blunt instrument pull the distal part of the tendon out through the incision. Sometimes there are tendon strips crossing from ECRL to ECRB and the tendon cannot be extracted. Pulling too hard on the ECRL tendon can damage or disrupt the musculo-tendinous junction. It is best to make a longitudinal incision near the wrist and free the tendons. Sometimes it is also possible to push the tendon from distal to proximal.

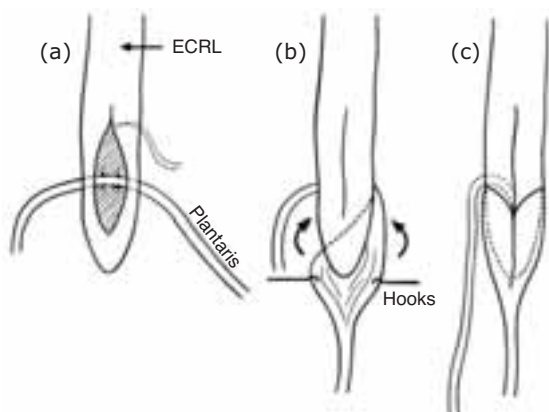


**FIGURE 6-6** Incisions for EF4T. **a.** Dorsal aspect **b.** Palmar aspect.



Incision N° 7: This is made in the distal third on the volar forearm, opening the aponeurosis. With the tunneller coming from incisions 7 to 6 under the fascia, grasp the end of the ECRL and exteriorize it in the volar incision.

The graft is now anastomosed to the graft according to Brand's technique. The plantaris or tensor fascia lata are most commonly used. If the plantaris longus is used, the motor tendon is incised longitudinally for about 1 cm and through 2/3 of its thickness (Fig. 6-7). The site is near the end of the tendon or more proximal so that the anastomosis does not enter the carpal tunnel, although it has not created problems if it does.<sup>6</sup> With a scalpel, the tendon is then pierced from side to side in the middle of the opening created and the plantaris graft passed through at 90° to the ECRL. With fine monofilament sutures the graft is sutured to the deep fibers in the longitudinal incision. The graft should have two halves of the same length.

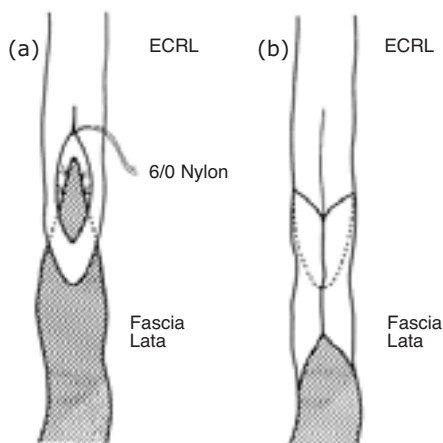


**FIGURE 6-7** Brand anastomosis using plantaris tendon. **a.** 1.5 cm boat-shaped opening made in ECRL and plantaris tendon passed through the ECRL tendon at this level and sutured at its base. **b.** ECRL opening closed, plantaris stretched out flat. **c.** Plantaris tendon wrapped around the end of ECRL tendon and sutured.

The incision in the ECRL is now closed with 5/0 or 6/0 monofilament nylon and the suture

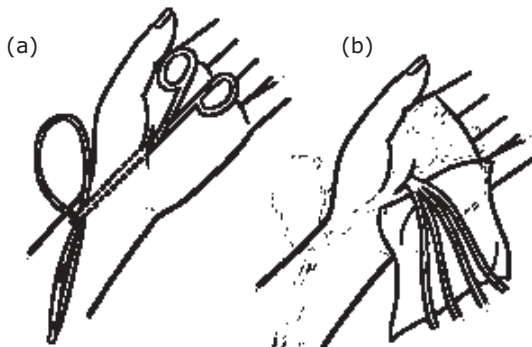
left in the field. The suture should be invaginating, so that knots and sutures are buried. One of the plantaris tendons is spread out by pulling the tendon transversally with hooks or stay sutures. The plantaris and palmaris have this quality of being able to stretch out like a film. The end of the ECRL is trimmed to size with a long oblique cut. Next the stretched plantaris is wrapped around the ECRL stump. Again 3 or 4 sutures fix the ECRL stump to the plantaris. The same fine nylon suture used to close the incision in the ECRL is now used to close the graft around the motor tendon going well beyond the end of the ECRL.

If fascia lata is used, the distal end of the graft is cut in a pointed fashion and introduced into the ECRL tendon through a hole made at the distal end of the longitudinal incision. The graft is sutured deep to the fibers of the ECRL with 3-4 fine stitches (Fig. 6-8a). The longitudinal incision is closed as described above. The ECRL is trimmed obliquely and the fascia lata is wrapped around the tendon stump and sutured into a tube, after fixing the motor tendon to the graft with interrupted sutures (Fig. 6-8b). The ECRL tendon and the graft are now

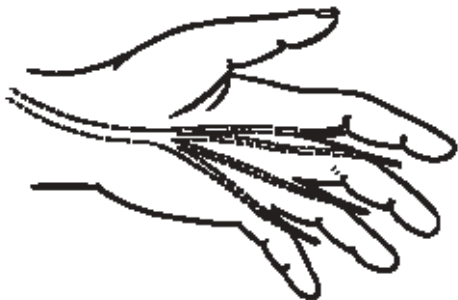

**FIGURE 6-8** Brand anastomosis using fascia lata. **a.** Fascia lata passed into boat-shaped opening near the end of ECRL tendon and sutured. **b.** ECRL opening closed, fascia lata wrapped around end of ECRL and sutured in continuity with ECRL closure.

united to each other by 6-8 sutures and the wrap around reinforces this even more. This gives a very strong anastomosis. The graft is then tunneled deep to all structures to incision N° 8, a 2cm incision in the proximal palm in line with the thenar crease. The tendon graft anastomosis should not enter the carpal tunnel.<sup>6</sup> The anastomosis should therefore be placed proximally enough on the ECRL tendon and the graft long enough to reach the dorsum of the fingers. Care is taken that the superficial vascular palmar arch is not compromised. It is best to come out with the tendon distal to the vascular arch. The graft is now divided in 4 slips (strands or tails) (Fig. 6-9). Each slip is now tunneled from the palm to the dorsal incisions on the fingers (Fig. 6-10). Care is taken to

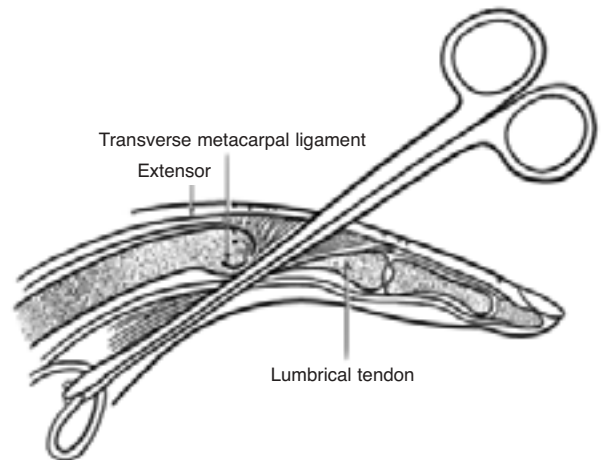


**FIGURE 6-9** EF4T procedure. **a.** Passing graft into palmar incision using Anderson tunneler. **b.** Graft divided into 4 slips (from Fritschi<sup>13</sup>, used with permission).



**FIGURE 6-10** EF4T procedure, showing route of grafts from wrist to fingers (from Fritschi<sup>13</sup>, used with permission).

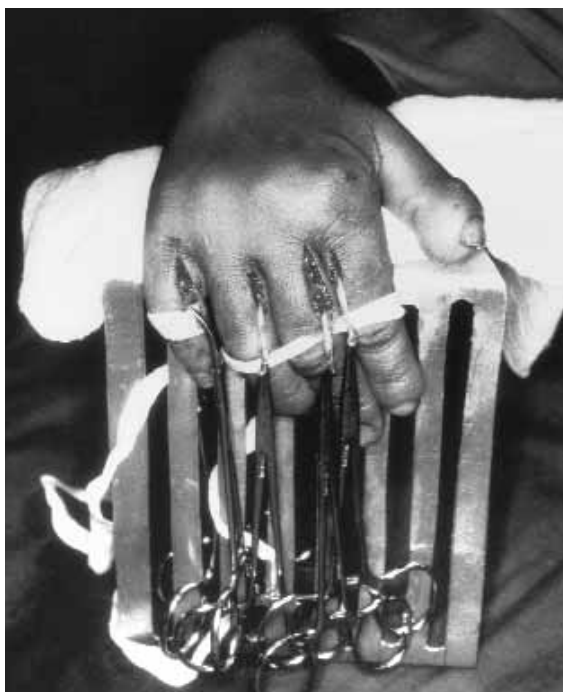pass *volar* to the transverse intermetacarpal ligament to ensure MCP joint flexion (Fig. 6-11). Passing the tunneller from the dorsal incision to the palm, the ligament can be easily felt moving the tunneller tip volar to dorsal, back and forth. Holding the finger with the MCP in flexion will facilitate this maneuver. Possible errors are also to tunnel subcutaneously or bridge part of the palmar aponeurosis. The tunneller has to come out exactly in the middle of the incision. It is important to probe around when tunnelling to find a route with minimal resistance. All incisions, except those for the fingers, are now closed.



**FIGURE 6-11** EF4T procedure, showing passage of graft palmar to the transverse metacarpal ligament.

Important in all tendon transfers is the tension given to the transfer. Experience has shown that by using a standard position for the hand, more consistent tension can be judged. Recommended is to position the hand with the wrist in 30° of flexion and MCP's at 80°-90° and the DIP and IP joints at 0° or neutral extension. There are special splints designed which can easily be made out of metal (Fig. 6-12) or wood, but it can easily be arranged with rolled up green towels or a sterilized can of pop or beer. The total tendon excursion will be about 2 cm.

For a stiff hand more than half the total excursion for tension should be used. In mobile hands almost no tension is adequate. Usually the index transfer is done first and then the little finger which always receives 1 cm more tension to assist in restoring the distal transverse metacarpal arch.



**FIGURE 6-12** EF4T procedure/ sublimus transfer, showing hand on splint with grafts coming out of the dorsal finger incisions ready to suture to lateral bands.

By dividing the tendon graft in 5 bands, one slip can be tunnelled to the ulnar side of the little finger and sutured to the abductor digiti minimi tendon with slightly more tension. This extra step usually results in a good transverse metacarpal arch if the hand is mobile.

If the fingers are in a Boutonniere position that does not correct with physiotherapy, we have used very successfully a technique shown to me by Dr. Ernest Fritschi, referred to as dorsal fixation of the lateral band (see Chapter 9). The recipient lateral band of the tendon trans-

fer, is freed from all underlying tissue to the middle of the mid phalanx and is folded on itself 180°. The band should cross the PIP in the middle. It is sutured to the central tendon and extensor apparatus. The tendon transfer is now sutured to the doubled up lateral band. This leaves a stiff PIP in extension initially, but physiotherapy will usually correct this.

If the DIP is fixed in extension, a tenotomy of the distal extensor tendon is done. A N° 15 knife is pushed under the skin, flat, to the DIP. It is then turned 90° with the blade towards the bone and a long oblique tenotomy of the extensor is done from the DIP proximally. Check for release of the DIP to be sure that all fibers have been cut. The DIP joint should flex to at least 45 degrees. Early mobilization of the DIP is started in the post-operative period. The tendon will heal in a stretched position. Mallet finger is seldom seen. Sometimes I have also cut the collateral ligaments at the PIP joint partially and released the volar plate as well.

The tourniquet is now released, finger incisions closed and a strong plaster splint is applied with wrist slightly in flexion, fingers straight and MCP in maximum flexion. Some use a full cast. It is essential to keep the operated hand elevated at all times for at least 72 hours.

The initial cast stays on until physiotherapy starts at about 3-4 weeks, unless there are complications. This transfer is one of the best. It adds a strong muscle to the flexor group. It is not difficult to re-educate and removing the extensor carpi radialis longus leaves very little loss of function if the radial nerve is normal. Pre- and postoperative views are seen in Fig. 6-13 a,b.

Complications of EF4T: Swan neck or "Intrinsic plus" can occasionally be seen if the tension is too strong or when the fingers are hypermobile. Unequal tension on the 4 bands can be very disabling (quadriga effect).



**FIGURE 6-13** Claw hand. **a.** Pre-operatively. **b.** Following EF4T procedure with restoration of primary MCP flexion.

### Palmaris longus transfer (PMT, palmaris many tailed)

Fritschi and Ranney reported on the use of the palmaris longus with a tendon graft<sup>13,28,29,30</sup> (fascia lata or plantaris) for intrinsic replacement of the fingers. The tendon graft anastomosis can be difficult because of the small size of the palmaris, although a Brand anastomosis should deal with this problem. It is ideal for hypermobile hands. It is not as powerful as the other motors used in the other techniques. The palmaris has a tension fraction similar to that of the lumbricals, and so can just produce primary MCP flexion in the mobile hand but with minimal strength.

Another approach to the hypermobile hand is to insert the tendon slips of FDS into the A1 pulley or as Palande has shown, into the tendons of the interossei.<sup>22</sup>

### Extensor Extensor Many Tailed (EEMT)

Before using the volar route, Brand first described the same operation, transferring the tendon through the interosseous spaces.<sup>2</sup> From the palm each tendon is then tunnelled volar to the intermetacarpal ligament to the lateral bands. The main problems encountered are adhesions to the interosseous aponeurosis, reverse metacarpal arch and tenodesis effect

with wrist flexion. Adhesions can be avoided by carefully probing for a defect in the fascial layers when doing the tunnelling as described above. Some surgeons still prefer to use this surgical technique, reporting good results (personal communication).

### Flexor Carpi Radialis Transfer

Riordan uses the flexor carpi radialis as motor.<sup>26,27,28</sup> This also needs a tendon graft. He re-routes to the dorsum of the forearm, then perforates the interosseous spaces and then routes the transfer from the palm to the lateral bands for insertion. It is a strong transfer. Perforating both interossei fascia may cause adhesions. This technique uses the principal wrist stabilizer which may leave a serious weakness. This problem can be avoided by routing it on the flexor side of the wrist as a palmaris longus transfer, which will keep its role as a wrist flexor.

### Finger Motors

#### Flexor Sublimis Transfer

The reason we use the sublimis transfer as routine in South America, is to avoid having to do the tendon anastomosis. It takes a skilled and delicate surgeon to perform the EF<sub>4</sub>T procedure. Our aim is to include as many surgeons as possible and it is easier and faster to perform the sublimis transfer. [RS: I would suggest training surgeons to do the best procedure possible for each patient if the skill level is present.] The types of hands are also generally the strong stiff European hands and severe contractures are also common. The aboriginals have hypermobile hands similar to that seen in India or Asia.

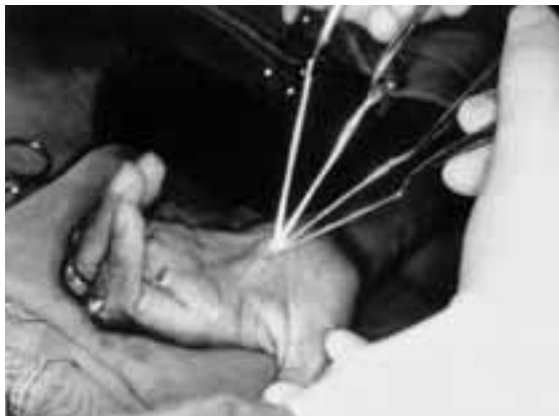Usually the long finger flexor superficialis is used as the motor and the insertion can be into the lateral bands in the same manner as described for the EF<sub>4</sub>T, or the insertion can be into the A1 pulley as described by Zancolli or Brooks.<sup>4,5,13,25,26,27,28,29</sup>

**Lateral Band Insertion:** (Stiles - Bunnell - Brand)<sup>8,9,32</sup> Incisions in the fingers are the same as described in the EF<sub>4</sub>T. The tendon of the long finger sublimis is harvested through an oblique incision on the volar aspect of the proximal phalanx. The tendon on one side is transected just proximal to the vinculae longa. If the vinculae is transected then complete hemostasis must be achieved to avoid scarring and later flexion contracture of the PIP (check rein). Fritschi recommends to cut the flexor superficialis as close as possible to its insertion.<sup>13</sup> The other tendon can be visualized and cut by pulling on the first tendon. The second tendon will appear underneath the flexor profundus.

The decussation of the tendon has to be divided, otherwise it slings around the flexor profundus and the flexor sublimis can not be withdrawn. This is done by flexing the wrist and MCP's and pulling on the two tendon slips with hemostats. A closed scissor is passed along the flexor superficialis until a window is felt. Pulling on the scissor hooked into the window, the union between the two slips is visualized and can be transected.

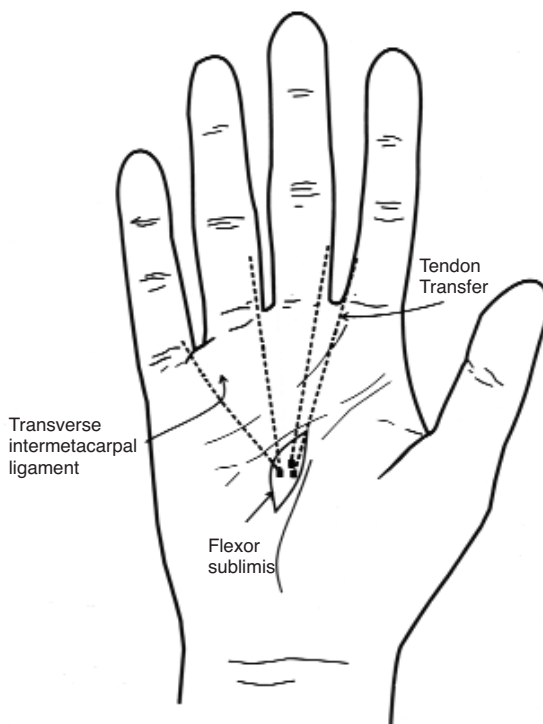
The sublimis tendon can also be harvested through a transverse incision just proximal to the flexion crease at the MCP joint. The tendon is withdrawn through the interval between A1 and A2 pulley or an interval is created. Pulling hard the sublimis tendon can usually be exteriorized and cut just proximal to the decussation and vincula.

Through a 2 cm incision at the base of the palm in line with the thenar crease, the flexor superficialis of the long finger is withdrawn, preferably distal to the superficial palmar vascular arch. The sublimis is divided into 4 equal slips (Fig. 6-14). This is not difficult because the fibers are very parallel and straight. Maintaining strong tension on the tendon, a knife can be passed from proximal to distal.



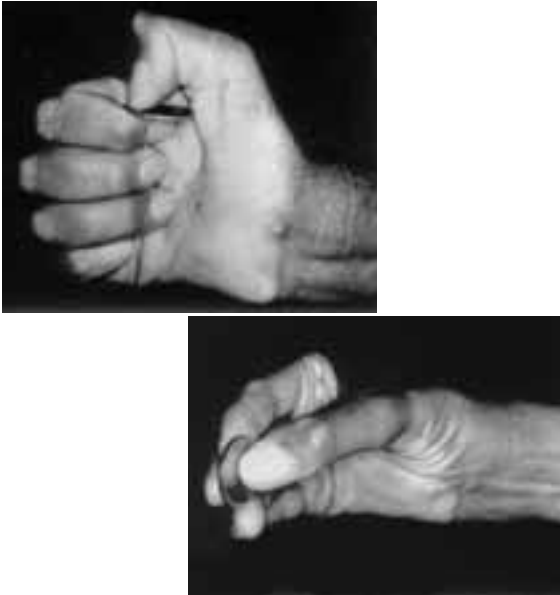**FIGURE 6-14** Sublimis transfer with sublimis tendon split into four tails in palm.

The remainder of the surgical technique is as described for the EF<sub>4</sub>T with similar tensions (Fig. 6-15). Pre-and post-operative results are seen in Fig. 6-16 a,b.



**FIGURE 6-15** Route of sublimis transfer to lateral bands.





**FIGURE 6-16** Ulnar/ median palsied hand. **a.** Pre-operatively. **b.** Following sublimis transfer to lateral bands and opponensplasty, with full restoration of primary MCP flexion.

### Insertion into Flexor Pulley (Zancolli Lasso-Brooks)<sup>7,13,27,28,29,33</sup>

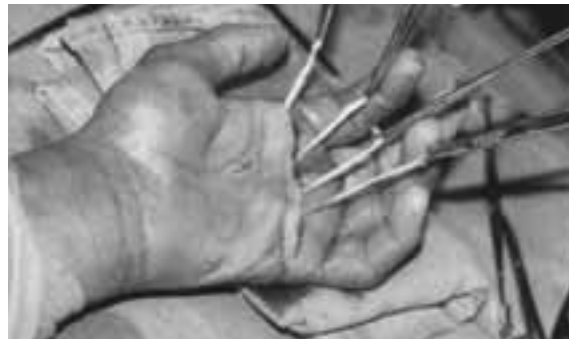The area of insertion is the distal palm. A curved, transverse incision is made in the palm from the radial border to the ulnar border, about 1 cm proximal to the MCP flexion creases.

The flexor tendon sheaths are dissected free and the proximal border of the A1 pulley identified. The synovial sheaths are opened just proximal to the A1 pulley border with scalpel or pointed scissors, care taken not to injure the flexor digitorum superficialis.

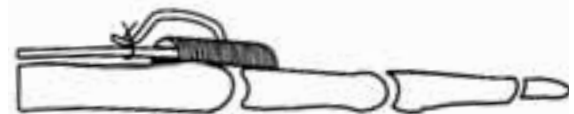The flexor superficialis of the long finger is transected distally as described above. It can easily be withdrawn through the long transverse incision. The tendon is withdrawn through a small separate incision at the base of the palm and divided into 4 slips or bands as described before. A fifth slip can be divided.

The 4 slips are tunneled close to the radial side of each flexor sheath into the transverse

incision (Fig. 6-17). Each slip is then pulled through the proximal 5-7 mm of the A1 pulley (Fig. 6-18). A small gallbladder hemostat is quite helpful. Grinding the tips of a gallbladder forceps or a curved mosquito hemostat makes it easier to pierce through the pulley. With the hand flat on the table and the fingers in extension, the slips are sutured to itself under maximum tension. The little finger receives about 1 cm more tension. Some surgeons insert the tendon into the A2 pulley to increase the moment arm. The problem is that the tendon bowstrings. I have seen patients with large calluses at the volar MCP and also with problems in grasping small objects like tool handles, especially brooms. [RS: I routinely use the A2 pulley without seeing the problems noted above. It has the same moment arm as the interossei insertion.<sup>4</sup>]



**FIGURE 6-17** Zancolli "Lasso" procedure, showing sublimis tendon split into four slips and having been passed from palmar incision back to transverse palmar incision.



**FIGURE 6-18** Zancolli "lasso" procedure, showing transferred sublimis slip looped around the A1 pulley and sutured to itself.

A 5th slip can be created and inserted into the ulnar side of the MCP of the little finger to increase the transverse arch.<sup>32</sup>

**Complications:** Check rein (scarring at PIP level) presents as a PIP flexure contracture, and is dealt with in chapters 7 and 22. MCP flexion contracture can rarely be seen if sutures of the tendon slips are done with fingers in flexion. Intrinsic plus, superficialis minus or profundus plus deformity at the donor or other fingers are fairly common. These are all swan-neck-like deformities but are the result of too much power in the transfer, taking the superficialis away or of the FDP creating a flexion deformity at the DIP, respectively (see chapters 7, 9 and 22).

### **Extensor Proprius Transfer**

Fowler uses as motor the extensor indicis proprius and extensor digiti quinti minimi, each divided into two slips and the same as Riordan, perforates the interosseous membranes.<sup>13,28,29,30</sup> I have used this technique in my initial years of leprosy work. The results were consistently poor. Adhesions and difficulty in re-education were the main problems.

### **Intrinsic Reactivation Technique**

Palande, in this technique, uses the extensor carpi radialis longus as motor, with fascia lata graft. The insertion is into the adjacent interosseous tendons in the interdigital space. It reactivates the primary flexors of the MCP joints leaving extension for the extrinsic extensors. The results seen by these techniques in Palande's patients are really excellent, but it is an operation for the well experienced hand surgeon.

### **The Contracted Claw Hand**

If the contracture of the PIP is less than 45°, and physiotherapy is of no help, tendon transfers can still be done for claw hand deformity. Function increases greatly. Surgical methods releasing skin and ligaments can also be used successfully. When the contracture is near 90° soft tissue release may be attempted and

arthrodesis of the PIP gives a functional hand (chapter 9). As Dr. Paul Brand so often said "an arthrodesed hand loses a lot of its humanness" and there is seldom a patient happy with an arthrodesis. Especially in interpersonal contact a rigid finger feels very unnatural.

The long standing paralysis of the intrinsics in the hand can lead to fixed contractures with MCP's in extension and PIP and DIP's in full flexion. Function of the hand is severely reduced and the patient basically uses the hands as paddles. Physiotherapy should always be attempted for 2 or 3 months. It is surprising how often contractures improve.

The surgical solution is to arthrodesise the PIP and DIP in extension. This leaves the finger at half its length because of the amount of bone to be resected. Non union and mal union are common (see chapter 9).

One patient showed me another way. By hacking off the 4 fingers of both hands with a machete at the PIP level, he forced me to tidy up his surgery. He was a bricklayer and later had improved function of the hands with only proximal phalanges. Observing other patients I noticed that when finger injuries reach the PIP level, often no more injuries occurred. The length is the same as the arthrodesed finger. The only thing missing is the fingernail which is important to some patients, especially females. The proximal phalanx is well padded and the long flexors act now as MCP flexors, improving function greatly as compared to the rigid claw position. I now prefer the PIP level amputation.

### **Summary- intrinsic loss**

We have used the Brand EF<sub>4</sub>T transfer with insertion into the A1 pulley in hands that needed a strong transfer, but were hypermobile. There is often discussion as to which technique is better: the A1 pulley or the extensor insertion. We believe each has its place. In hypermobile hands the insertion in the A1 pulley pro-

vides an active MCP flexor and restores the normal sequence in closing the hand used in grasp without acting on the extensor mechanism. The danger of producing a swan neck is less. But the extending of the fingers has to be done by the extensor digitorum communis, which in turn will act against the transfer. This may need extra attention in re-education. It is easy to recognize a “Zancolli” hand, because the fingers are seldom fully extended when adopting the intrinsic position. Functionally this is not important, but it may be cosmetically.

The insertion of the transfer into the lateral bands restores most of the intrinsic function and is reserved for stronger, stiff hands, or with residual contractures.

With the EF<sub>4</sub>T and the two FDS transfers we have been able to solve most problems with the intrinsic minus hand. The palmaris longus transfer for hypermobile hands is also reasonable.

### **FLEXOR DIGITORUM AND FLEXOR CARPI ULNARIS WEAKNESS**

When the FDP of the long finger is weak, all 4 flexor digitorum profundus tendons can be sutured together in the distal forearm in the natural finger cascade position. However Brand did not consider this a major problem and only recommended surgery if the FDS to the little finger was weak or absent.<sup>4</sup> If the long finger FDP is strong, the index FDP does not need to be included. Use a strong non-absorbable suture like 3/0 nylon and free the tendons of synovium at the transfixing suture site. In this situation it would be advisable to use a wrist motor procedure such as the EF<sub>4</sub>T as opposed to an FDS transfer.

Rarely a patient may complain of significant effect of the loss of wrist ulnar deviation (due to loss of FCU) on his ability to function well. In this case the FCR tendon could be trans-

ferred to the FCU insertion, and use brachioradialis to attach to the FCR stump, as Brand suggests.<sup>4</sup> This is seldom a problem.

### **ULNAR NERVE PARALYSIS IN THE THUMB**

In ulnar nerve paralysis the adductor pollicis, the first dorsal interosseous and often flexor pollicis brevis (FPB) are paralyzed. Loss of adductor pollicis causes marked weakening of key pinch. Loss of FPB causes interphalangeal (IP) hyperflexion (Froment’s sign) or metacarpophalangeal hyperextension (Z-thumb), depending on the individual hand. Prolonged uncorrected ulnar/median palsy is not infrequently associated with trapezio-metacarpal subluxation.

#### ***Restoration of Key Pinch***

Approximately 25 percent of thumb adduction strength is provided by the extensor pollicis longus (EPL) and flexor pollicis longus (FPL) and as such most patients do not request intervention to strengthen key pinch. However, a patient with particular work requirements with an ulnar palsy in the dominant hand may request increased thumb adduction strength. The infrequency of this procedure being performed may be partly due to the surgeon failing to either examine the hand at work or to actually measure pinch strength, as Brand has pointed out<sup>6</sup>, and the defect may go unrecognized. Adductor pollicis (AP) is a powerful muscle with a tension fraction (TF) of 3.0, with FPB providing an additional 1.3. For comparison the FPL has a tension fraction of only 2.7. For those who do require strengthening of key pinch, either extensor carpi radialis brevis (TF 4.2) or flexor digitorum superficialis (m) (TF 3.4) can be used. Extensor indicis proprius has been used<sup>7</sup> but with a tension fraction of only 1.0 this seems rather weak to be very effectual, although Palande also confirms its usefulness

(personal communication). Brand suggests using two tendon grafts to the thumb in ulnar/median nerve palsy, using FDS to the adductor and extensor indicis proprius for opposition.<sup>3</sup> Boyes<sup>1</sup> has used the brachioradialis extended with a graft, taking this through the third metacarpal space, but this can be difficult to re-educate.

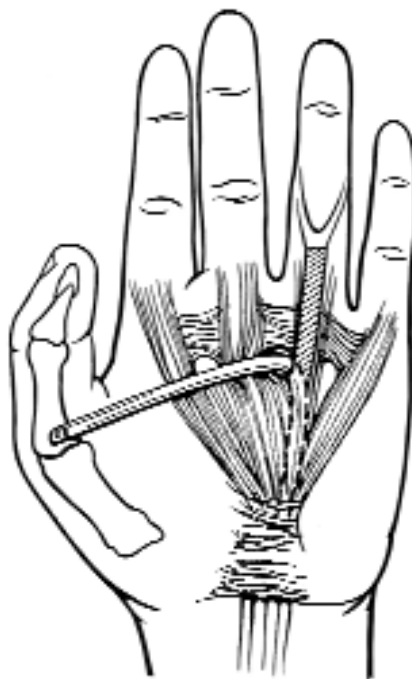### Extensor Carpi Radialis Longus to Adductor Transfer-Technique (Omer)

This technique was originally described by Smith<sup>7</sup> and modified by Omer.<sup>6</sup> The extensor carpi radialis brevis (ECRB) tendon is divided at its insertion and extended with a free tendon graft using a Brand anastomosis. The graft is then tunnelled through the third intermetacarpal space to the palm. It is then brought volar to the AP and dorsal to the flexor tendons and neurovascular bundle to be attached to the abductor pollicis brevis insertion. The tension is adjusted so that the thumb is just palmar to the index finger when the wrist is straight. Immobilization is continued for three to four weeks after which therapy is commenced. Wrist flexion allows thumb abduction, and when the wrist is extended the thumb is adducted against the palm. The key pinch strength is doubled on average by this operation.<sup>7</sup> This operation has the disadvantages of using ECRB, the principle wrist extensor, and an angle at the pulley of 90°. Smith stopped using this transfer subsequent to his publication (personal communication).

### Flexor Digitorum Superficialis to Adductor Pollicis Transfer- Technique

Littler first described this procedure.<sup>19</sup> The disadvantage of this procedure is the loss of one flexor digitorum superficialis (FDS), especially if another is going to be used for intrinsic replacement for the fingers. This will further weaken power grip. The FDS is divided

through a distal palmar incision just proximal to its decussation. It is brought out in the palm and then tunnelled across the palm volar to the adductor pollicis (AP) to be attached to the AP insertion (Fig. 6-19). The palmar fascia where it has been split serves as the pulley. Tension again is set so that the thumb lies close to the index finger with the wrist in neutral. Plaster is applied with the wrist in 30° of flexion with the thumb adducted, and the hand kept immobilized for three to four weeks. Brand prefers attachment to abductor pollicis brevis insertion or to extensor pollicus longus halfway along the proximal phalanx in patients with median/ulnar palsy. This will give both adduction/flexion and also improve thumb pronation.<sup>3</sup> A separate tendon such as extensor indicis proprius is then used for thumb opposition. Hamlin and Littler<sup>4</sup> reported a pinch power of 70 percent of the opposite hand following this procedure.



**FIGURE 6-19** Flexor digitorum superficialis to adductor pollicis transfer (from Omer<sup>25</sup>, used with permission).

## **Restoration of Primary thumb MCP Flexion**

Patients with isolated ulnar nerve palsy usually have adequate primary MCP flexion and do not require further surgery. With combined ulnar- median paralysis primary MCP flexion is lost, which may produce variable amounts of I-P hyper-flexion as well as MCP hyper-extension. This in turn may produce an unstable pinch as the grip surface is the tip rather than the pulp. Often the double-insertion FDS (Brand) opponensplasty as described in chapter 7 adequately stabilizes the thumb to prevent IP hyper-flexion. If not, there are five ways this problem can be corrected.

Metacarpophalangeal joint arthrodesis.

Half flexor pollicis longus to extensor pollicis longus transfer.

Additional slip from 'Lasso' to AP insertion.

Interphalangeal joint arthrodesis.

Flexor- adductor replacement.

The best technique depends on the patient, the thumb and the hand (see below). For a Z-thumb deformity, the most reliable technique is metacarpal-phalangeal joint arthrodesis. For isolated interphalangeal joint hyperflexion, half FPL to EPL transfer gives the best result.

### **1) Metacarpophalangeal Arthrodesis**

Similar to the fingers, when the metacarpophalangeal joint of the thumb is stabilized the interphalangeal joint is able to extend. As well, fixing the metacarpophalangeal joint in slight flexion will allow the distal joint to flex independently, avoiding the hyperflexion produced when the proximal joint is hyperextended. The metacarpophalangeal joint functionally has a limited range of movement, from 0-20° in the flexion-extension plane. The loss of this movement does not result in any functional impairment, and arthrodesis will restore control of the

distal joint. For this reason for a patient with a mobile interphalangeal joint the MCP joint should be arthrodesed, and the distal joint should only be arthrodesed when there is a fixed flexion deformity present. This is the procedure of choice for a fixed deformity of the MCP joint such as a fixed hyperextension.

### **Technique**

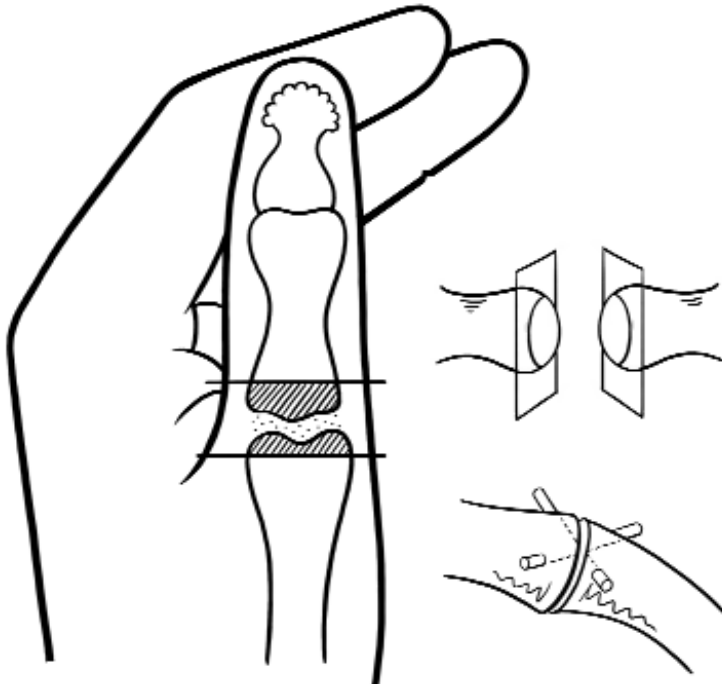
There are many ways to fuse a digital joint. The following technique I have found quite satisfactory. A 4 cm dorsal incision is made over the dorsum of the MCP joint, displacing the extensor tendon and then proceeding to cut down to bone. The fibres of the extensor brevis are divided and the joint capsule is opened. The collateral ligaments are divided to allow dislocation of the joint. The joint surfaces are cut with either a saw or bone cutters so that when opposed the joint will be in 15° of flexion and 5° of abduction (Fig. 6-20a). A Chevron cut (Fig. 6-20b) will give a larger surface area and more stable fixation. Two crossed K-wires are then advanced into the proximal phalanx to exit the skin. The two bone surfaces are then opposed with the thumb in 15° of pronation and the K-wires drilled into the metacarpal. The thumb is immobilized in a short thumb spica for 8 weeks and then active motion of the thumb is permitted. The K-wires are removed at 8 weeks or when bone healing is seen on X-ray.

### **2) Half Flexor Pollicis Longus to extensor pollicis longus transfer.**

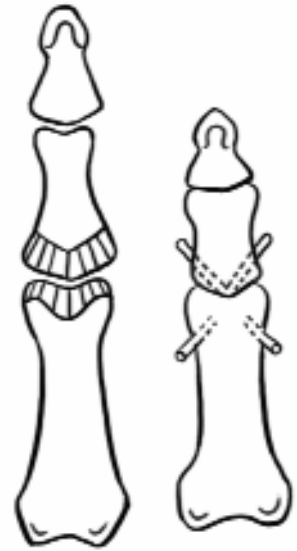
This procedure, described by Malaviya<sup>20</sup> stabilizes the interphalangeal joint by making the flexor pollicis longus both a flexor and extensor of the joint, but a pure flexor of the MCP joint. This prevents extension of the MCP joint during thumb flexion and corrects the interphalangeal hyperflexion resulting from this. It is the procedure of choice in a patient with a mobile IP joint with Froment's sign.



(a)



(b)

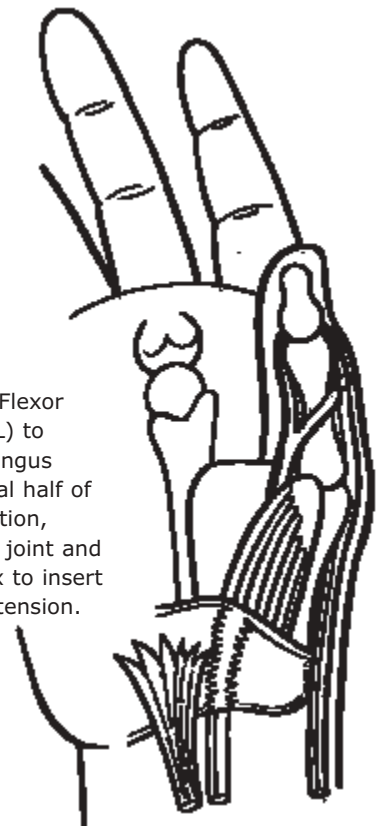


**FIGURE 6.20** Metacarpophalangeal joint arthrodesis. **a.** Flat surfaces. Oblique cuts made through bone. Angle of cut determines amount of joint flexion. Fixation with cross K-wires. **b.** Chevron arthrodesis.

### Technique

The flexor pollicis longus is identified through a small transverse incision along the interphalangeal joint crease and again through a second incision along the metacarpal joint crease. From the first incision the radial half of the tendon is separated and cut off its insertion. It is then separated as proximally as possible by flexing wrist and thumb and pulling on both slips. The cut slip is then identified and withdrawn from the proximal incision. It is then brought around the radial aspect of the proximal phalanx to be inserted into the extensor pollicis longus at the mid-point of the proximal phalanx (Fig. 6-21). Tension should be adjusted so that in full interphalangeal extension and 20° of metacarpophalangeal flexion the two slips of the flexor pollicis longus are at the same tension. The dorsal slip therefore becomes taut in flexion, and because the tendon is volar to the MCP joint it will then flex

**FIGURE 6.21** Half Flexor Pollicus Longus (FPL) to Extensor Pollicus Longus (EPL) transfer. Radial half of FPL divided at insertion, brought out at MCP joint and then across phalanx to insert into EPL at neutral tension.



this joint. A thumb spica including the wrist is placed with the thumb in full opposition and the wrist in 20° flexion for three weeks.

### 3) Additional slip from 'Lasso'

When a lasso procedure is being carried out for intrinsic loss replacement (see intrinsic replacement section of this chapter), a fifth tail can be added to the transfer to provide first MCP flexion. The radial-most slip from the superficialis tendon is brought radially over the adductor pollicis and deep to the digital vessels to insert into the abductor pollicis brevis insertion. The distal edge of the palmar fascia therefore becomes the pulley. It is sutured with the thumb in near full abduction. If this is too tight the grip span will be reduced. This will produce thumb adduction, pronation and MCP flexion. This may be expecting too much of a single transfer in some hands and detract from the intrinsic function of the transfer on the fingers.

### 4) Arthrodesis of Interphalangeal Joint

This procedure is only indicated in the presence of a relatively severe fixed flexion contracture of the IP joint. It is rather disabling as it does not allow the patient to adjust the thumb tip angle in pinch, yet if the MCP joint is mobile patients cope well. It is preferable to a fixed contracture in which the nail is part of the contact surface, which predisposes to ulceration. A mild flexion contracture is usually best not interfered with.

The technique is as for finger I-P fusion. The ideal position is straight or even in slight extension, although in the presence of shortened digits slight flexion may be necessary to facilitate contact.

### 5) Flexor-adductor replacement

The adductor replacements described above also provide primary MCP flexion and can be used as such.

## SUMMARY

In general, surgery for the ulnar deficit hand in leprosy is most rewarding and if good physiotherapy is available, most patients have excellent results, the hands look better and function better and are less likely to have injuries.

Do not embark on surgical correction of claw hands without the presence of experienced hand therapists. Preparing the hands and re-educating the transferred muscle, is an essential part in the rehabilitation of any paralyzed hand.

Ideally, nerve function loss should be prevented in leprosy patients. If present, the secondary complications such as contractures should be prevented so that dynamic tendon transfer procedures can be employed to give maximum functional and cosmetic benefit to the hand. Only if hands are very badly contracted need the surgeon resort to arthrodesis and other operations to restore some functionality to the hand.

## REFERENCES

1. Bourrel P: Raccourcissement capsulaire metacarpo-phalangien et avancement des poulies des flechisseurs dans les paralysies des muscles intrinseques des doigts. *Ann Chir Plast* 15:27-33, 1970
2. Brand PW: Tendon grafting. Illustrated by a new operation for intrinsic paralysis of the fingers. *J Bone Joint Surg* 43B:444-453, 1961
3. Brand PW: Discussion, capsulodeses and pulley advancement for correction of claw-finger deformity. *J Bone Joint Surg* 54A:1470, 1972
4. Brand PW, Hollister A: Operations to restore muscle balance to the hand. *Clinical Mechanics of the Hand*. 2nd ed. St. Louis: Mosby, 170-222, 1995
5. Brand PW: Paralytic hand claw: with special reference to paralysis in leprosy and treatment by the sublimis transfer of Stiles and Bunnell. *J Bone Joint Surg* 40B:618-632, 1958
6. Brandsma JW, Brand PW: Median nerve function after tendon transfer for ulnar paralysis. *J Hand Surg* 10B:30-32, 1985
7. Brooks AG, Jones DS: A new intrinsic transfer for the paralytic hand. *J Bone Joint Surg* 57A:730, 1975

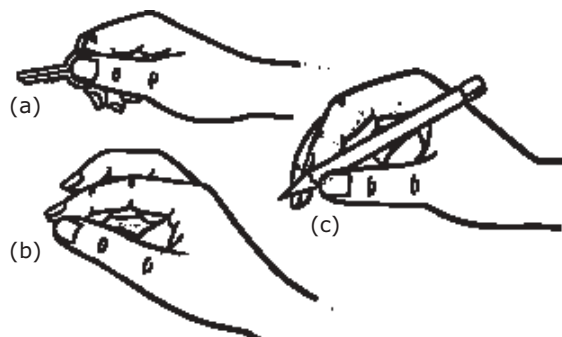
8. Bunnell S: Surgery of the intrinsic muscles of the hand other than those producing opposition of the thumb. *J Bone Joint Surg* 24:1-31, 1942
  9. Bunnell S: *Surgery of the Hand*. ed.3, Philadelphia, J.B. Lippincott Co., 1956
  10. Chacko V, Mall B, Shukla RK, Gupta AK: Assessment of sublimis transfer operation in leprosy. *Lepr India* 45:146-150, 1973
  11. Enna CD, Riordan DC: The Fowler procedure for correction of the paralytic claw hand. *Plast Rec Surg* 52:352-360, 1973
  12. Eyer DL, Markee JE: The anatomy and function of the intrinsic musculature of the fingers. *J Bone Joint Surg* 36A:1, 1954
  13. Fritschi EP: *Surgical Reconstruction and Rehabilitation in Leprosy*. The Leprosy Mission New Delhi. 1984
  14. Hastings H. II, McCollam SM: Flexor digitorum superficialis lasso tendon transfer in isolated ulnar nerve palsy: A functional evaluation. *J Hand Surg* 19A:275-280, 1994
  15. Kozin SH, Porter Scott, Clark P, Thoder JJ: The contribution of the intrinsic muscles to grip and pinch strength. *J Hand Surg* 24A:64-72, 1999
  16. Landsmeer JMF: Power grip and precision handling. *Ann Rheum Dis* 21:164, 1962
  17. Leddy JP, Stark HH, Ashworth CR, Boyes JH: Capsulodesis and pulley advancement for the correction of claw-finger deformity. *J Bone Joint Surg* 54A:1465-71, 1972
  18. Lee DH, Rodriguez JA: Tendon transfer for restoring hand intrinsic muscle function: A biomechanical study. *J Hand Surg* 24A:609-13, 1999
  19. Linscheid RL, An KN, Gross MR: Quantitative analysis of the intrinsic muscles of the hand. *Clin Anat* 265-284, 1991
  20. Mulder JD, Landsmeer MF: The mechanism of claw finger. *J Bone Joint Surg* 50A:664-668, 1968
  21. Palande DD: Correction of paralytic claw finger in leprosy by capsulorrhaphy and pulley advancement. *J Bone Joint Surg* 58A:9-66, 1976
  22. Palande DD: Correction of intrinsic-minus hands associated with reversal of the transverse metacarpal arch. *J Bone Joint Surg* 65A:514-521, 1983
  23. Parkes AR: Paralytic claw fingers - a graft tenodesis operation. *Hand* 5:192, 1973
  24. Ranney DA: The mechanism of arch reversal in the surgically corrected claw hand. *J Hand Surg* 6:266-272, 1974
  25. Ranney DA: Reconstruction of the transverse metacarpal arch in ulnar palsy by transfer of the extensor digiti minimi. *Plast Rec Surg* 52:406-412, 1973
  26. Riordan DC: Tendon transplantations in median-nerve and ulnar-nerve paralysis. *J Bone Joint Surg* 35:312-320, 1953
  27. Riordan DC: Surgery of the paralytic hand. In: *Am Ac Orthop Surg: Instructional Course Lectures*. 16, St. Louis, CV Mosby, 79-90, 1959
  28. Smith RJ: Intrinsic muscles of the fingers: function, dysfunction, and surgical reconstruction. In *Am Ac Orthop Surg: Instructional Course Lectures*. 24, St. Louis 1975, CV Mosby 200-220, 1975
  29. Smith RJ: Surgical treatment of the clawhand. In *AAOS: Symposium on tendon surgery in the hand*. St. Louis 1975, CV Mosby Co., 181-203, 1975
  30. Smith RJ: *Tendon transfers of the hand and forearm*. Boston, Little, Brown: 103-133, 1987
  31. Srinivasan H: The extensor diversion graft operation for correction of intrinsic minus fingers in leprosy. *J Bone Joint Surg* 55B:58-65, 1973
  32. Stiles HJ, Forrester-Brown MF: *Treatment of injuries of the peripheral spinal nerves*. London, H Frowde: 166, 1922
  33. Talsania JS, Kozin SH: Normal digital contribution to grip strength assessed with a computerized digital dynamometer. *J Hand Surg* 23B:162-166, 1998
  34. Zancolli E: Correccion de la "garra" digital por paralisis intrinseca; la operacion del "lazo" *Acta Orthop Latino Am* 1: 65, 1974
- Ulnar Nerve Paralysis in the thumb
1. Boyes JH: *Bunnell's Surgery of the Hand*. 4th Ed. p.514. JB Lippincott, Philadelphia, 1964
  2. Brown PW: Reconstruction for pinch in ulnar nerve palsy. *Orthop Clin North Am* 5:323-342, 1974
  3. Edgerton MT, Brand PW: Restoration of abduction and adduction to the unstable thumb in median and ulnar nerve paralysis. *Plast Reconstr Surg* 36:150-164, 1965
  4. Hamlin C, Littler JW: restoration of power pinch. *Orthop Trans* 3:319-320, 1979
  5. Littler JW: Restoration of power and stability in the partially paralyzed hand. pp 1674-1695. In *Converse JM: Reconstructive Plastic Surgery*, Vol. IV. WB Saunders, Philadelphia, 1964
  6. Omer GE Jr: Reconstruction of a balanced thumb through tendon transfers. *Clin Orthop* 195: 104-116, 1985
  7. Smith RJ: Extensor carpi radialis brevis tendon transfer for thumb adduction- a study of power pinch. *J Hand Surg* 8:4-15, 1983

## Median Nerve Palsy

• R. SCHWARZ

### INTRODUCTION

The simian hand is defined by the presence of a thumb, which is able to oppose against the other digits in a "pinch grip." Two basic types of functional pinch are described the key pinch and the pulp-to-pulp pinch (Fig. 7-1). In the key pinch the pulp of the thumb is opposed to the side of the index finger. This action requires strong adduction of the index finger by the first dorsal interosseous and adductor pollicis, which is only possible if the ulnar nerve is functional. This type of pinch is used in holding a key, lifting heavy objects such as books etc.. The pulp-to-pulp pinch is stressed by Brand<sup>5</sup> as being the most important function of the thumb. This action is used for picking up small objects, buttoning etc. It requires slight rotation of the index finger to face the thumb. This movement is carried out by the first palmar interosseous. Fritschi<sup>14</sup> has emphasized the three-finger pulp-to-pulp pinch, which involves the pulp of the thumb opposing to the pulp of the index and long fingers. This position is used for picking up small objects, holding a pen and eating with the hand. It requires

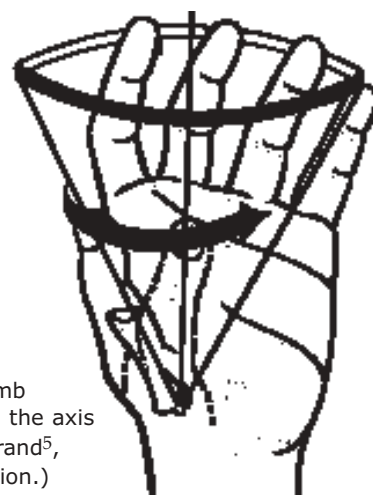


**FIGURE 7-1** Three types of pinch (from Fritschi<sup>14</sup>, used with permission.) **a.** Key Pinch, **b.** Two finger pulp-to-pulp pinch, **c.** Three finger pinch.

slight adduction/abduction of the long and index fingers against each other. Antia<sup>3</sup> also describes the short thrust pinch in which the thumb interphalangeal joint is hyperextended, providing both increased stability and greater strength in pinch.

### Mechanism of Pinch

Thumb opposition occurs mainly through movements at the carpometacarpal (CMC) joint. Opposition of the thumb is a compound movement involving simultaneous abduction and flexion at the CMC joint. The movement can best be described as that of movement around a cone, although it superficially appears to be a rotation movement (Fig. 7-2). The thumb pulp when beside the palm lies at about 45° supination and when fully opposed has moved to about 40° of pronation. This pronation is probably a secondary passive movement brought about by a combination of intrinsic muscle pull and joint ligamentous stability.<sup>9</sup>



**FIGURE 7-2** Thumb movement around the axis of a cone (from Brand<sup>5</sup>, used with permission.)

Thumb opposition requires the action of several muscles. Abductor pollicis brevis and the opponens carry out the abduction component along with the flexor pollicis brevis superficial head. Abductor pollicis longus effects retroposition of the metacarpal and has little role in thumb opposition. The flexion component is carried out by the flexors pollicis brevis (FPB) and longus (FPL). Simultaneously the lumbrical, interossei and long flexors of the index and middle fingers are activated along with the adductor pollicis to complete the pinch. In pure median nerve palsy, only the abductor brevis and opponens muscle will be non-functional in most cases, as in 73% of patients FPB has at least partial innervation from the ulnar nerve.<sup>24</sup> Zancolli and Cozzi<sup>26</sup> state that the superficial head of FPB has dual ulnar/ median nerve supply in 30 percent of hands while the deep head is supplied by the ulnar nerve exclusively in 19 percent and has dual supply in 79 percent of hands. This explains why pure median nerve palsy will often maintain functional opposition.

### ***Deficit in Low Median Nerve Palsy and Combined Ulnar/Median Palsy***

The variability of innervation described above explains why many patients with pure median nerve loss maintain opposition function. Patients with isolated median nerve injury without recovery will often not require opponens reconstruction.<sup>11,13</sup> However with combined ulnar/median nerve palsy, as is usually seen in leprosy, the FPB as well as adductor pollicis and the intrinsic of the index fingers will be paralysed. This leads to retroposition and supination of the thumb by the unopposed extrinsic muscles of the thumb. In combined ulnar and median nerve palsy the intrinsic muscles to the fingers are also paralyzed, causing instability of the fingers, loss of adduction of the index finger and loss of primary MCP flexion (Chapter 6). In the context of thumb

function combined ulnar/ median paralysis may make the squeeze pinch the only pinch mechanism possible, that is contact of the side of the thumb to the side of the hand or index finger. At best an ineffective key pinch will be possible. This severe disability requires a different approach than a pure median nerve palsy. These patients will all require restoration of opposition with effective pronation of the thumb tip to allow pulp-to-pulp pinch.

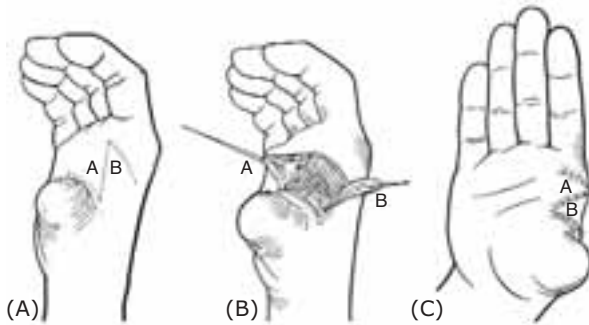
## **SURGICAL TREATMENT OF MEDIAN NERVE PALSY**

### ***Management of Contractures***

First web space contractures are occasionally associated with median nerve palsy, especially in association with ulnar nerve palsy. This may be due to associated trauma and scarring, or more commonly due to the chronically retropositioned thumb. Pre-operatively the web space must be fully opened with stretching exercises and any IP or MCP joint contractures corrected with therapy. Practically it is difficult to open a severely contracted webspace with therapy alone. If the patient presents early these should be prevented with first web space splints and exercises. If there is an established first web space contracture which fails to respond to therapy it must be corrected prior to or preferably simultaneous with the opponensplasty. Web space contracture is easy to detect clinically. Passive abduction/opposition will demonstrate limitation with tightness of the dorsal skin of the first web space. Carpometacarpal joint contracture is more difficult to detect. In this situation abduction is possible but opposition is restricted. The conditions may be present simultaneously.

With a moderate web contracture a simple large Z-plasty will usually suffice with the dorsal flap based distally and the palmar flap based proximally (Fig. 7-3). Dorsal fascia is



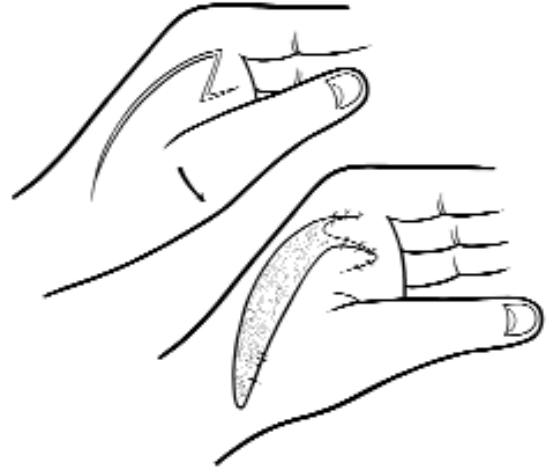


**FIGURE 7-3** Simple Z-plasty (from Kleinman and Strickland<sup>16</sup>, used with permission).

divided completely down to the level of the CMC joint and any restraining bands felt for and divided. In case of combined median/ulnar palsy the adductor pollicis is often contracted and the transverse head at least should be divided. A single large Z-plasty will give a better release than multiple Z-plasties as the contracture extends to the base of the metacarpal. This procedure also gives the advantage of deepening the web space, which can be of benefit if the thumb is short. It can be done concomitantly with an opponensplasty. It may be combined with full-thickness skin grafting on the dorsum to complete the release. An alternative is to release the contracture through a dorsal incision and apply a full-thickness graft (Fig. 7-4). An incision is made through skin and fat from the radial side of the index MCP joint, curving dorsally and ending over the first CMC joint. The skin is then undermined towards the thumb, and the dorsal fascia, thus exposed, is divided along its full length such that the skin flap will cover the fascial defect. Any restraining bands are felt for and divided. A full-thickness skin graft, usually from the groin, is then harvested to size and sutured in place with a bulky dressing tied over it. This procedure should be done prior to the opponensplasty and as soon as the graft is healed the opponensplasty should be carried out before the graft has a chance to contract.

Alternatively it can be done at the same time as the opponensplasty.

For more severe contractures a dorsal flap webplasty may be required (Chapter 10).



**FIGURE 7-4** First webspace webplasty with full-thickness skin grafting (from Fritsch<sup>14</sup>, used with permission).

### Opponensplasty Techniques

General principles of tendon transfer apply (Chapter 1). Four standard methods will be described followed by two other methods for special situations. It is advisable for a surgeon to become proficient in the performance and problems of only two or three of these techniques rather than attempt all available transfers. For combined ulnar/median palsy the flexor digitorum superficialis (FDS) transfer is the most commonly used transfer. Some recommend a two tendon transfer, using extensor indicis proprius (EIP) for abduction and FDS or extensor carpi radialis brevis (ECRB) for short flexor replacement.<sup>5</sup> For isolated median nerve palsy, especially a high palsy, the EIP transfer is ideal. Others should be used only in special situations as described below.

### Standard Opponensplasties

1. Superficialis transfer.
2. Extensor indicis proprius transfer.

3. Palmaris longus transfer (Camitz procedure).
4. Extensor pollicis longus re-routing.

### Other Opponensplasties

1. Flexor pollicis longus transfer.
2. Abductor pollicis longus re-routing.
3. Abductor Digiti Minimi Transfer.

#### 1. Superficialis Transfer

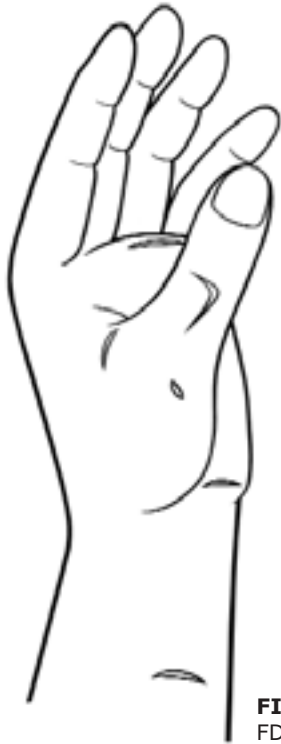The ring finger superficialis tendon is usually chosen. It is less important in pinch function than the long FDS and being more ulnar gives a slightly less acute angle at the pulley. The long sublimus is an acceptable alternative. The index FDS is too important in pinch function to be sacrificed and that of the little finger is too weak to be used and is sometimes absent. The function of flexor digitorum profundus must be checked and should be at least 4/5 on the MRC scale. The strength of the ring sublimus is usually maintained even in the presence of a high ulnar nerve palsy due to cross-over of fasciculi in the main muscle belly.

Traditionally the FDS was harvested through a lateral incision at the level of the proximal interphalangeal (PIP) joint. This was to maximize the length of the tendon. However this was found to lead to a number of checkrein or swan-neck deformities. North and Littler<sup>20</sup> felt that division of the FDS near its insertion may cause trauma to the PIP joint capsule. It may also destroy the distal vinculae and disrupt the blood supply to the FDP. They recommended division of the FDS through an opening between the A1 and A2 pulleys, proximal to its bifurcation. Anderson et al<sup>2</sup> compared harvesting FDS through either a mid-lateral or a palmar incision. Extension lag at the distal interphalangeal (DIP) joint (swan-neck deformity) developed in 44% of cases with the mid-lateral incision compared with 8% with the palmar approach. Likewise, check-rein deformity developed in 8% of cases having had the later-

al approach compared with 0 percent in those having had the palmar approach. He suggested that the higher incidence of complications was due to adhesions to the lateral bands, which are exposed during this procedure. In our experience harvesting over 400 FDS tendons via an opening between the A1 and A2 pulleys, few have developed significant checkrein deformity. It would seem that given the evidence of increased complications with the lateral approach and the fact that adequate length can be obtained through a distal palmar approach, that it would be prudent to cut the tendon through the latter incision.

As stated above most patients with median nerve palsy secondary to leprosy also have an ulnar nerve palsy. While some authors have stated that finger intrinsic and opponens operations should be done separately, in our experience and that of Mehta et al<sup>18</sup>, combining opponens replacement with a "Lasso" procedure shortens the rehabilitative process without compromise in results. We obtained a good or excellent result in 93% of those undergoing opponens replacement regardless of whether they had a simultaneous "Lasso" procedure or not. Therefore if the surgeon is well experienced and the patient is intelligent and a candidate for each procedure, then both can be performed in the same operation.

**Technique:** An axillary block is usually used. A small transverse incision is made just proximal to the ring MCP crease and a small transverse opening made between the A1 and A2 pulleys. The FDS tendon is then divided as far distally as possible. Four more incisions are then made (Fig. 7-5). An 8 mm incision is made 1 cm. distal and radial to the pisiform, and deepened until the loose large fat lobules of Guyon's canal are seen protruding up from the small firm fat globules typical of the palm. A 1 cm incision just palmar to the mid-point of the thumb MCP joint is made on the lateral surface.

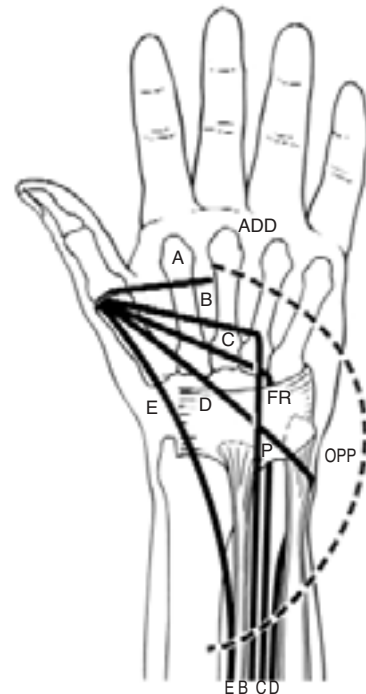


**FIGURE 7-5** Incisions for FDS opponensplasty.

A third, 1.5 cm curved incision, is made over the insertion of the adductor pollicis, and the fourth, an L-shaped incision, is made over the dorsum of the I-P joint.

A 1.5 cm transverse incision is then made about 3 cm proximal to the distal wrist crease. The ring finger FDS is the identified and then brought out of this incision. There are frequently vinculae between the FDS and flexor digitorum profundus (FDP), which may need to be divided from both incisions. If necessary another incision can be made mid-palm. A small curved tendon tunneller is then passed from the pisiform incision to the forearm incision, passing deep to the piso-hamate ligament and emerging in the same plane as the ulnar nerve and artery. The tendon is then withdrawn into the palm and checked for easy gliding. It is then passed deep subcutaneously into the thumb MCP incision and again checked for free gliding. A wide passage is not created, as this will increase the likelihood of adhesions.

**Alternative Routes:** It has been shown that the route of the tendon transfer can be altered to best suit the patient's needs<sup>10</sup> (Fig. 7-6). Placing the pulley more distally in the palm produces more thumb flexion and may be appropriate in patients with combined ulnar/ median nerve palsy. Similarly, placing the pulley more proxi-



**FIGURE 7-6** Potential routes of FDS opponensplasty. The arc of possibility is indicated by broken semicircle marked ADD (uction), ABD (uction) and OPP (osition). The most frequently used types of transfer are: **a.** Adductor replacement. Pulley is metacarpal two or three. **b.** Thompson route. Pulley is palmar fascia. True opponens action. **c.** Guyon's canal. Pulley is palmaris brevis/ palmar fascia. **d.** Pulley is at pisiform (on FCU). **e.** Camitz route. Weak abductor without pulley. Full adduction is type A, opposition is type B, C and D, and type E is full abduction. (from Warren<sup>25</sup>, used with permission.)

mally will produce more abduction at the expense of flexion and opposition. Placing the pulley near the pisiform will produce maximal abduction/opposition. Alternate routes are described as follows:

**Campbell-Thompson Route**

The FDS is withdrawn via a 3 cm incision just radial to the hypothenar eminence. The ulnar border of the palmar aponeurosis is exposed and the FDS tendon withdrawn just distal to the flexor retinaculum and then tunnelled across to the thumb MCP with the insertion as described below. This will give greater MCP flexion but not full abduction and may need combined abductor pollicis longus re-routing. (See below)

**Bunnell's Flexor Carpi Ulnaris (FCU) Pulley**

A 4 cm incision is made just medial to the FCU insertion. Half the FCU is cut across 4 cm from its insertion and then the tendon is split distally to leave a distally based strip. This is then sutured back to the FCU insertion at the pisiform to create a fixed pulley. Some have found that this pulley tends to drift medially.<sup>14</sup>

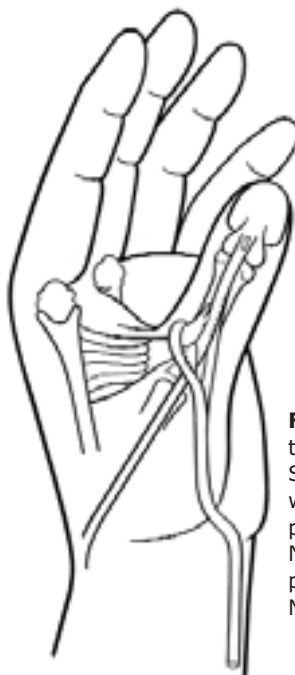
**Transverse Carpal Ligament (TCL)**

An incision is made over the TCL and a window made at the desired level, more proximally for greater abduction and distally for greater flexion. The FDS tendon is brought out in the forearm and passed through the TCL window and then across to the thumb.

**Insertion:** In a pure medial nerve palsy, thumb MCP flexion is preserved and so pure abduction-opposition only is sought. This can be obtained simply by encircling the insertion of abductor pollicis brevis and suturing the tendon to itself. To set the tension, the thumb should be put into full opposition with the wrist in neutral position. The tendon should be pulled 1 cm past zero tension, and sutured with three to four sutures in this position with the wrist flexed to relieve tension.

Insertion into bone has been described by Bunnell<sup>6</sup>, but there is no advantage to this and it does add to both time and potential morbidity.

In combined ulnar/ median nerve palsy it is desirable to stabilize the thumb MCP joint as well. This can be accomplished by a double insertion technique as described by Brand.<sup>5</sup> In this procedure, the transferred tendon at the MCP incision is divided into two slips up to 5 cm proximally (Fig. 7-7). One slip is passed just distal to the MCP joint over the dorsal aspect and is then looped around the adductor insertion adjacent to bone. It is important to keep this slip distal to the MCP to prevent a Z-thumb deformity (Fig. 7-7). The other slip is routed palmar to the MCP joint to insert with a triple weave on the Extensor pollicis longus (EPL). This serves as a MCP flexor as well as IP extensor to correct the deformity arising from the FPB paralysis. With a dual insertion only the insertion with the shortest moment arm or under the highest tension is activated.<sup>5</sup> As such the tensions are adjusted to make the adductor insertion functional and the EPL insertion functions largely to prevent any Z-thumb deformity rather than to create active IP extension. The transfer functions very well in this dual role. To set the tension the adductor slip is sutured with 1 cm tension with the thumb in full opposition



**FIGURE 7-7** Double insertion of FDS opponensplasty. Shows recommended route with insertion into adductor pollicis insertion and EPL. Note how slip to adductor pollicis lies just distal to the MCP joint.

as described for the ABP insertion technique. The IP slip is sutured at neutral tension.

If a fixed I-P joint flexion deformity is present, an I-P fusion should be carried out.

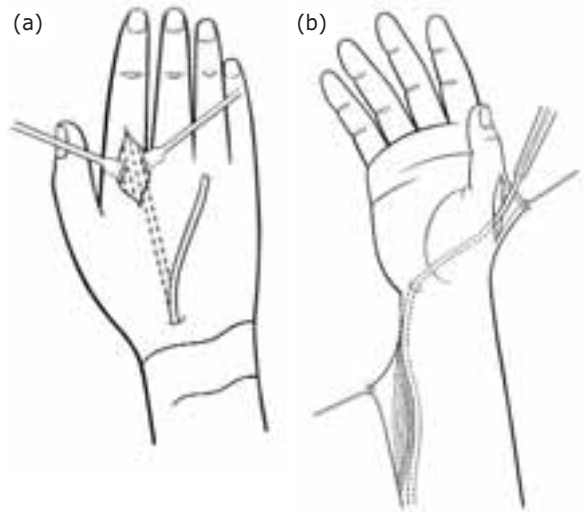
The hand is placed in POP with the wrist flexed 15-20° and the thumb in full opposition-abduction. This is kept in place for three weeks after which careful therapy is commenced.

## 2. Extensor Indicis Proprius (EIP)

### Opponensplasty

This is very useful in high median paralysis where FDS tendons are not available, and is very popular for pure low median palsy as well as it does not create a secondary deformity on the donor finger and does not weaken grip.<sup>7</sup> (ed. note (WB): It also can create a defect on the donor finger. In leprosy I have rarely seen consistent good results of an EIP transfer). In combined ulnar-median palsy Brand recommends combining it with an FDS to adductor pollicis transfer to provide adduction/pronation in ulnar/median palsy (chapter 6).<sup>5</sup>

**Technique:** A 2 cm incision is made over the index MCP joint and the EIP cut away from its attachment to the extensor expansion. A contiguous slip of extensor hood is not required.<sup>10</sup> It is withdrawn through a 4 cm dorsal forearm incision starting 2 cm proximal to the wrist crease and muscle attachments freed (Fig. 7-8). It is quite deep here and may be entirely muscular, and if adhesions to index communis tendon are present it may have to be withdrawn via an incision at the proximal metacarpal level. Small incisions are then made just medial to the pisiform and over the dorsoradial aspect of the thumb MCP joint. The tendon is tunneled around the ulnar border of the wrist, superficial to FCU to the pisiform incision, and thence across the palm to the thumb. In pure median palsy it is attached to the FPB insertion with the thumb in full opposition and the wrist in 30° flexion. In combined ulnar/median



**FIGURE 7-8** Extensor Indicis Proprius (EIP) transfer. **a.** Tendon is divided and delivered into a dorso-ulnar incision. **b.** Tendon is passed around ulnar side of wrist to an incision medial to the pisiform and then by a subcutaneous tunnel to the MCP joint.

palsy a split insertion to adductor pollicis and EPL can be used as described above. Riordan attaches the tendon in sequence to abductor pollicis bravis (APB) insertion, the MCP capsule and the extensor pollicis longus tendon over the proximal phalanx.<sup>23</sup> Alternatively, the tendon can be routed through the interosseous membrane, although some feel that the risk of adhesions is greater and the amount of opposition obtained may be decreased. Mehta et al<sup>17</sup> add a radial half FPL to EPL transfer to stabilize the MCP joint. Post-operatively a POP is applied with the thumb in full opposition and the wrist in 40° flexion for 3 weeks. Rehabilitation can be difficult with some patients and the patient should focus on opposition to middle and ring fingers.

Anderson et al<sup>1,2</sup> reported the use of this transfer in 13 high and 38 low median nerve palsies. Excellent or good results were reported in 89% of patients. They then compared their results with those of superficialis transfer and concluded that EIP transfer is indicated only in



those patients with supple hands. This is probably explained by the fact that FDS of the ring finger has a tension fraction (strength) double that of the EIP muscle, and is thus better able to overcome the resistance in stiff hands.

### 3. Palmaris Longus Opponensplasty

This relatively simple procedure is best suited to those patients with severe carpal tunnel syndrome and isolated median nerve palsy as it can be done simultaneous with a tunnel release with little excess morbidity. With a tension fraction of 1.0 it is not powerful enough by itself in combined ulnar- median palsy. It should be combined with FDS transfer for adduction/pronation as described for EIP transfer. As described by Camitz<sup>9</sup> it produces principally abduction, but by a simple modification it can also produce opposition (see below). The presence of palmaris longus (PL) muscle can be checked by cupping the tips of the fingers with the wrist flexed.

*Technique:* A longitudinal incision is made just ulnar to the PL extending from 2 cm proximal to the wrist crease to the proximal palmar crease in line with the index finger. The palmaris is then dissected along with 1 cm of palmar fascia in continuity with the tendon. A tunnel is then created to an incision over the insertion of abductor pollicis brevis (APB). The tendon with its attached fascia is then passed to the thumb incision and the fascia looped around the insertion of APB and sutured at 1 cm tension with the wrist neutral and the thumb in maximum opposition. Foucher et al<sup>13</sup> recommended insertion to the extensor pollicis brevis tendon or the dorsal capsule of the MCP joint to produce opposition and abduction although he found that this caused a slight reduction in MCP joint mobility in some patients. Alternatively the tendon can be passed up Guyon's canal and then across the palm, across the palmar incision to the thumb,

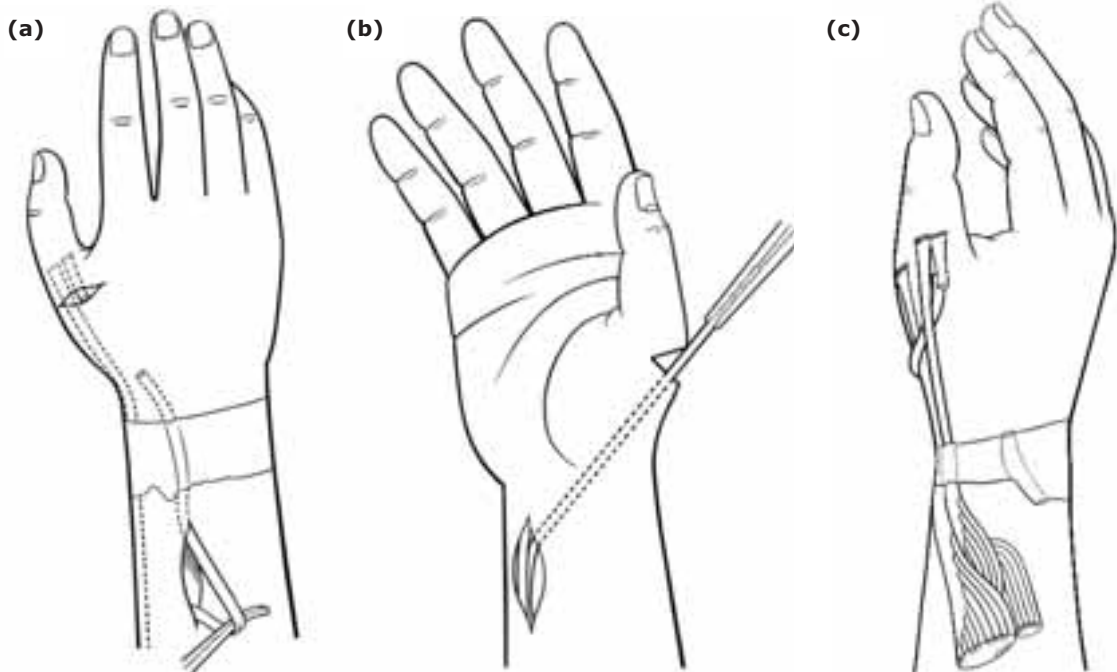
which will also produce greater opposition.

The hand is placed in a plaster for three weeks with the thumb in full opposition and the wrist slightly flexed after which therapy is started. This is a relatively weak muscle with a tension fraction of 1.2 and should only be used in supple hands. Excellent results have been reported in series of patients with carpal tunnel syndrome. These results may not apply to other causes of median palsy. Therapy is relatively simple for most patients.

### 4. Extensor Pollicis Longus Re-Routing

The extensor pollicis longus functions as both a thumb extensor and adductor. As such it works against thumb opposition and can be the cause of long-term failure of opponensplasty, especially with a weak motor such as EIP.<sup>22</sup> This procedure effectively transforms the EPL from an extensor/adductor to an extensor/abductor. While excellent results have been reported with this procedure in patients with various etiologies<sup>19,22</sup>, in our experience the therapy can be difficult. There is a definite learning curve to this procedure for the whole hand team, and should only be done in a patient of reasonable intelligence and motivation. This transfer is especially helpful in those patients with a deficit of donor tendons.

*Technique:* The extensor pollicis longus (EPL) is divided through a 2 cm incision just proximal to the MCP joint (Fig. 7-9). It is then brought out from a 3 cm incision 5 cm proximal to the wrist crease, where the tendon is quite deep. A 1 cm defect is then created in the interosseous membrane, after which the tendon is passed through the interosseous membrane (IOM) to a 2 cm incision on the radial side of the flexor carpi ulnaris, keeping radial to the ulnar artery and nerve. Unrestricted gliding through the IOM should be checked. It is then passed subcutaneously along the line of the metacarpal (palmar-dorsal junction) back to the original

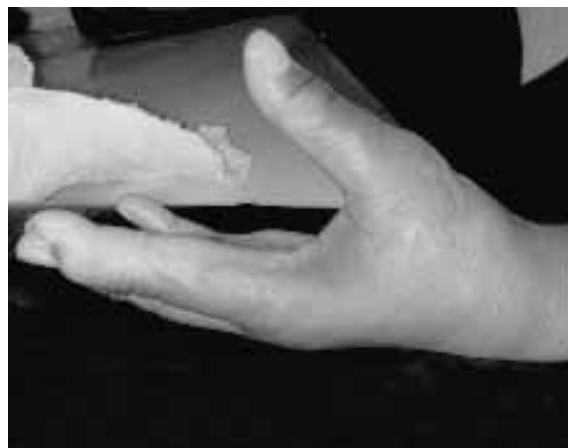

**FIGURE 7-9** Extensor Pollicis Longus (EPL) re-routing. **a.** The tendon has been divided proximal to the MCP joint, and is being brought out on the dorsum of the wrist before being passed through the interosseous membrane. **b.** It is brought through just radial to the FCU and then tunneled in a subcutaneous plane along the junction of palmar and dorsal skin to the original MCP joint incision. **c.** It is passed under the extensor pollicis brevis and sutured to itself with 1 cm overlap.

incision, routing it deep to extensor pollicis brevis. This prevents future palmar subluxation. It is then sutured back to the stump of EPL with a 1 cm overlap, which will adjust the tension. Riley and Burkhalter<sup>22</sup> pass the tendon around the ulnar border of the wrist and add an arthrodesis of the MCP joint. I also believe that it is necessary to stabilize the thumb in cases of combined ulnar/median palsy and usually add a half FPL to EPL transfer (see Part 2 below) in place of MCP arthrodesis with good results.

A short arm thumb spica is then applied with the thumb in full opposition and the wrist flexed at 30°. The plaster is removed at 4 weeks and therapy commenced. The patient should attempt thumb opposition with the I-P joint extended, activating the transfer. Extension and opposition are not necessarily contradictory movements. The EPL should continue to

function as an extensor after this procedure. A dynamic opposition splint is helpful at this time. Good or excellent results were reported by Mennen et al<sup>19</sup> in 31/35 patients. Clinical results are shown in Fig. 7-10.



**FIGURE 7-10** EPL re-routing post-operatively. Note excellent abduction obtained.

## *Other Opponensplasties*

### **1. Flexor Pollicis Longus Transfer**

This transfer is indicated in those patients with a combined ulnar/median palsy with a fixed flexion contracture of the IP joint. In this situation the IP joint must be fused. As such moving the FPL insertion to the FPB insertion does not diminish thumb function nor decrease strength, as the moment arm on the MCP joint for the FPL tendon sheath and the FPB insertion are almost identical. It is especially useful in those patients with a severely affected hand such as a triple nerve palsy where there is a deficit of tendons available for transfer. Routing through the carpal tunnel as described by Davis<sup>11</sup> produces limited pronation of the thumb but routing via Guyon's canal will give satisfactory opposition as well as short flexor action. This transforms a thumb extrinsic muscle that was contributing to the deformity into one that improves function, similar in concept to the EPL re-routing described above. This procedure also has the obvious benefit of creating no donor deficit, although the risk of weakening thumb flexion power must be recognized.

**Technique:** The insertion of FPL into the distal phalanx is exposed through a volar V-incision and then divided. The FPL tendon is withdrawn into the wound as much as possible to enable division of vinculae. A more proximal incision at the level of the A1 pulley is sometimes required to divide the rest of these. A longitudinal incision is then made over the dorsum of the IP joint and an arthrodesis carried out as described in chapter 9. I use K-wires for fixation. Through a 3 cm incision starting 3 cm from the wrist crease the FPL is identified and withdrawn. A 1 cm incision is then made 1 cm distal and radial to the pisiform, and deep dissection done until the large fat globules of Guyon's canal are seen. The tendon is then passed to this incision, and then passed

through a small subcutaneous tunnel to an incision on the dorso-radial aspect of the MCP joint. It is then looped around the FPB tendon and sutured with 1 cm tension with the wrist neutral and the thumb fully opposed. As there is a wide excursion of the FPL setting the tension is relatively easy. It is important not to insert the transfer onto the abductor pollicis brevis insertion, as this would give principally thumb abduction with insufficient power in flexion. The routing through the ulnar side of the wrist produces the necessary opposition and insertion into the FPB insertion will give the MCP flexion action that is necessary for a powerful pinch grip.

### **2. Re-Routing Abductor Pollicis Longus**

This does not produce true opposition but rather turns the abductor pollicis longus (APL) from a thumb supinator/extensor into an abductor. I have not found it to produce a great deal of abduction and is better combined with another procedure. This procedure can be useful in those patients with functional flexor pollicis brevis needing only more thumb abduction for grasping large objects. It is also indicated in some patients with extensive deficits in whom donor tendons are limited and donor deficits may be very detrimental to overall hand function.

**Technique:** The APL is divided 1 cm proximal to its insertion into the base of the metacarpal and brought out 6 cm proximal to the first incision. It is then passed to a small incision 3 cm proximal to the wrist crease over the palmaris longus (PL) tendon, looped around the PL tendon, passed to the first incision and sutured to the APL stump with 1 cm overlap. This is immobilized for 3-4 weeks before therapy is commenced.

### **3. Abductor Digiti Minimi Transfer**

This is a good procedure for isolated median nerve palsy. It is a technically demanding pro-

cedure, and the reader is referred to a textbook of hand surgery for a description.

### *Potential Pitfalls of Opponens Surgery*

#### **1. Use of Extensor Pollicis Longus in Pinch**

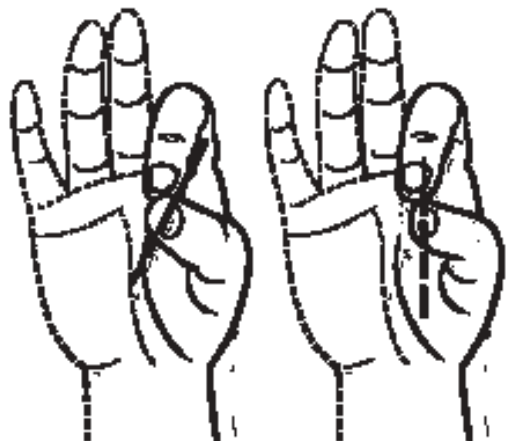
In long-standing ulnar/median paralysis the patient often has learned to use the extensor pollicis longus as an adductor to effect a lateral squeeze to hold objects between the side of his thumb and index finger. This can become a problem after the surgery if he uses this trick movement to grasp objects. This trick movement produces thumb supination and will overpower an attempt at thumb opposition by the transferred tendon. The patient may use the transfer well in therapy, but may habitually use the EPL lateral squeeze to pinch objects due to habit and simplicity. It is important that the patient is observed during regular activities of daily living to see whether he is using the transfer in pinch grip or whether he is using his EPL. If not detected in time the transfer may be lost due to neglect.

Brand proposes four ways of dealing with this problem.<sup>5</sup> Firstly, one should do the opponensplasty soon, before the patient has time to develop this trick movement. Obviously this depends upon the patient presenting in a timely fashion. Secondly, the patient requires thorough re-education with therapy carried out at the workbench as well as through exercises. Thirdly, in more established cases, the surgeon should consider re-routing the EPL at the same time as the opponensplasty. With this technique the EPL is freed from its retinaculum and transposed over the course of the abductor pollicis longus and anchored here with a pulley made from fascia. The incision extends from the MCP joint to 4 cm above the radial styloid. Two or three small incisions on this line are adequate. This procedure can also be used when the problem is detected following an opponensplasty. Finally, in very established

cases, the EPL can be used as the opponens motor by re-routing it through the interosseous membrane as described above.

#### **2. Crank handle action**

This problem can occur following an opponensplasty when complete pronation of the thumb is not obtained at surgery. This complication occurs when the metacarpophalangeal joint is flexed and the interphalangeal joint is extended, such as following an interphalangeal joint arthrodesis for a severe Froment's sign or an opponensplasty with insertion on the EPL tendon. With incomplete pronation, the pulp of the index finger makes contact with the ulnar side of the thumb. When pinch is attempted, the distal part of the thumb functions as a crank handle, forcing the thumb into supination (Fig. 7-11). The moment arm of this supinating force is large, and will overpower the small moment arm of the opponens transfer as it attempts to pronate the digit. The thumb will gradually be forced into more and more supination and the opponensplasty will have failed. Brand has several suggestions to prevent this.<sup>5</sup> Firstly, complete pronation of the thumb must be obtained at surgery. Often a webplasty will be required to accomplish this, and possibly a carpometacarpal joint release. If



**FIGURE 7-11** Crank handle action (from Brand<sup>5</sup>, used with permission).

it is not possible to obtain full pulp-to-pulp pinch, a tip pinch should not be used and rather the patient should be trained to use a key pinch. This will not lead to a crank handle action on the thumb, but rather the index finger. This is not a significant problem and can be prevented by teaching key pinch with all fingers held together to support the index. Secondly, therapy must be aimed at pulp-to-pulp pinch and not pulp-to-side of thumb. Arthrodesis of the interphalangeal joint should be avoided if possible. In a patient with Froment's sign and a mobile interphalangeal joint there are better options such as metacarpophalangeal joint fusion. If the MCP joint is chronically flexed and causing problems again MCP arthrodesis should be considered. Finally, the EPL can be re-routed over the abductor pollicis longus as described above to eliminate its supinating moment.

### HIGH MEDIAN NERVE PALSY

In this situation all muscles in the flexor compartment of the forearm are paralyzed apart from the FCU and the profundi to the little and ring fingers. Flexion of the long finger is usually satisfactory although weak. Functionally flexion of the thumb and index interphalangeal joints are absent while flexion of the wrist and ulnar three fingers is present. In leprosy the ulnar nerve is also usually affected and therefore these too are usually paralyzed, leaving no functioning flexors below the elbow. This severe deficit is fortunately quite rare in leprosy. When present it may be associated with radial nerve palsy as well. The goals of surgery are to restore thumb flexion and opposition and finger flexion. Opposition can be restored by EPL re-routing or by EIP transfer as described above if the radial nerve is intact. Thumb flexion can be restored by brachioradialis transfer to the FPL (see below). Finger flexion can be restored by tenodesis of the ring and little FDP to those of the index and middle fin-

gers if the ulnar nerve is intact. This is accomplished by side to side suturing of all profundus tendons in the distal forearm. This will give index flexion but little strength. If strength is required the extensor carpi radialis longus (ECRL) can be transferred to the index FDP (see below). The transfer techniques described involve end-to-end anastomosis. If there is a chance of nerve recovery then end-to-side anastomosis should be performed. If the radial nerve is also involved options are severely limited, with all wrist and digit extensors also absent. In this situation brachioradialis can be used to power the finger flexors with stabilization of the wrist and thumb to provide some pinch function. In leprosy the pronator teres is often preserved, in which case pronator teres can be used to activate extensor carpi radialis brevis, with a tenodesis of the thumb to give thumb opposition/flexion on wrist extension (hinge hand procedure, see chapter 8).

### Brachioradialis to Flexor Pollicis Longus

#### Transfer<sup>8,11</sup>

An incision is made on the radial side of the volar forearm from the wrist crease to 8 cm distal to the elbow. The brachioradialis is then divided at its insertion. Muscle fibres are stripped off the deep fascia of the forearm to free the tendon up until well proximal to the musculo-tendinous junction. The whole distal aponeurosis must be divided, and this is then folded in on itself and approximated with a continuous fine nylon suture to decrease adhesion formation. Dissection of the muscle from its attachments proximally can increase excursion by more than 100%.<sup>5</sup> The dissection should be carried up to the proximal third of the forearm, releasing all attachments of tendon to investing fascia and radius. The tension is set so that the transfer will function at its maximal efficiency when the elbow is straight. With the wrist flexed 30 degrees the tension is set so that the thumb can be fully extended but will flex the thumb on wrist extension.

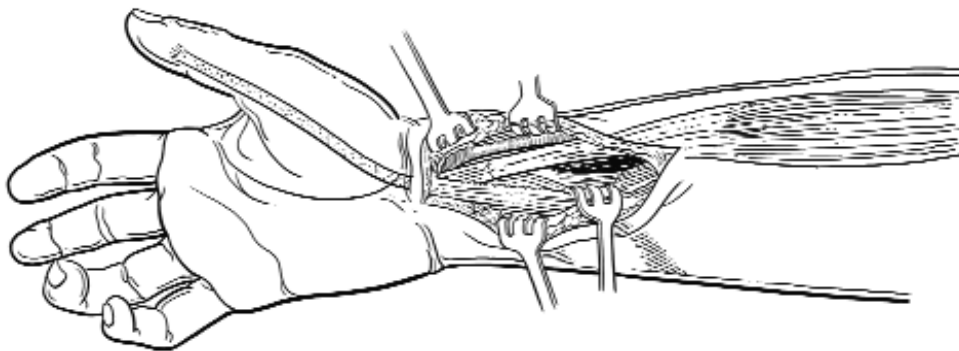


Excessive tension must be avoided, as otherwise the thumb will end up positioned uselessly across the palm. A Brand anastomosis is carried out between the brachioradialis and the FPL tendon, which has been divided 5 cm proximal to the wrist (Fig. 7-12). It is then immobilized in elbow, wrist and thumb flexion. As the brachioradialis is primarily an elbow flexor, the transfer will be weakened by elbow flexion. It should therefore be used in full elbow extension.

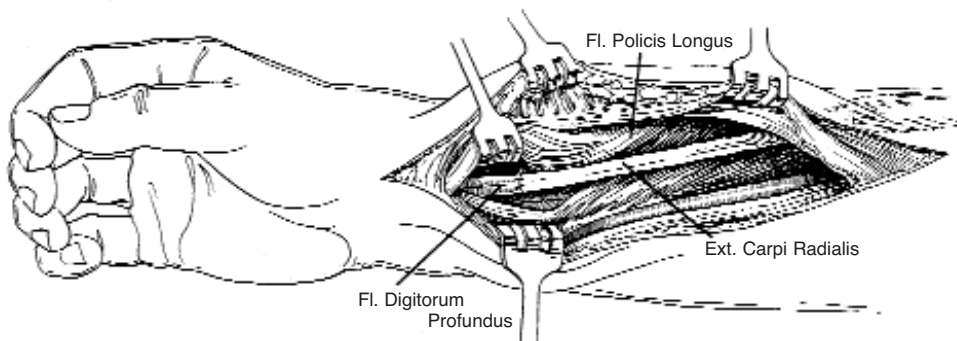
### Extensor Carpi Radialis Longus to Flexor Digitorum Profundus Transfer<sup>8,11</sup>

The ECRL is divided at its insertion<sup>8</sup> through a small transverse incision. An 8 cm incision is made on the radial side of the volar forearm

from the wrist crease extending proximally. The ECRL is then brought around the radial aspect of the radius. The FDP to the index and long fingers is divided 5 cm proximal to the wrist and a Brand anastomosis is carried out to the ECRL tendon (Fig. 7-13). If this is carried out in conjunction with the brachioradialis to EPL transfer these two anastomoses should be done at different levels to decrease the risk of adhesions. Setting the tension correctly is difficult but important. The excursion of the ECRL is only about 30 mm in comparison to about 50 mm for the profundus muscles. As such excessive tension on the transfer will lead to a flexion contracture of the fingers. The same problem holds for the brachioradialis to FPL transfer. For both transfers a “dynamic tenodesis”



**FIGURE 7-12** Brachioradialis to flexor pollicis longus transfer (from Davis and Barton,<sup>11</sup> used with permission).



**FIGURE 7-13** Extensor carpi radialis longus transfer to flexor digitorum profundus of long and index fingers (from Davis and Barton,<sup>11</sup> used with permission).

approach is used, using wrist motion to enhance the function of the transfer.<sup>8</sup> Full wrist volar flexion will allow full finger extension while full wrist extension will allow full finger closure. To check for correct tension, 30 degrees of wrist flexion should give full finger extension, while 30 degrees of wrist flexion should produce passive finger closure so that the transfer can then use its power with the fingers closed. Arthrodesis of the DIP joints can enhance the function of this transfer. The arm is immobilized in 30 degrees of wrist flexion with MCP joints flexed at 80 degrees and the interphalangeal joints straight.

## **CARPOMETACARPAL JOINT DISORDERS**

The thumb carpometacarpal (CMC) joint consists of two saddle shaped surfaces of trapezium and metacarpal bones with the axes of the two near perpendicular to each other. There is little bony stability, and stability depends on a strong volar plate with ligaments on the other sides. The dorsal ligament is reinforced by the abductor pollicis longus. There is normally minimal laxity. Adduction/ abduction occur along the length of the trapezial "saddle" while flexion/ extension occurs across the saddle. The small amount of true rotation at the CMC joint is due to incongruency of the radial and ulnar aspects of the trapezial joint surface. The CMC joint is where opposition of the thumb occurs, and it is therefore integral to the function of the thumb.

### ***Contracture of the Carpometacarpal Joint***

The most common disorder seen in the trapezio-metacarpal joint is contracture of the intermetacarpal ligaments. This is usually associated with longstanding ulnar-median nerve palsy where prolonged retroposition of the

thumb causes progressive ligament shortening, which in turn causes restriction of passive opposition. There is often associated web contracture and/or dorsal skin deficiency.

### **Treatment**

Prolonged therapy by web space stretching and CMC mobilization by forced opposition may be necessary. In established CMC joint contracture conservative measures will often not suffice. If full opposition is not obtained then surgical release is indicated. A webplasty is usually also required and the CMC release may be able to be accomplished through this incision. Otherwise a separate incision is necessary.

*Technique:* A 3 cm incision is made just medial to the extensor pollicis longus tendon. The joint capsule is opened in a longitudinal direction until full opposition is obtained. A fat graft may be placed to prevent recurrence. A K-wire may be required to maintain position. The thumb is placed in a spica for three weeks in full opposition after which full motion is allowed but night splinting is continued for three months. This may be combined with an opponensplasty.

### ***Carpometacarpal Dislocation***

This condition is often unrecognized, but is reported in 20% of ulnar-median nerve palsy hands.<sup>4</sup> If looked for it is easy to diagnose. The thumb is forcibly retroflexed using the metacarpal as a fulcrum and the joint can be seen to dislocate in a radial direction. Beine<sup>4</sup> felt that it is more common after MCP fusion or opponensplasty, but I have not noted this. With loss of adductor pollicis and the first dorsal interosseous, the extensor pollicis longus assumes the adductor role with the fulcrum at the tip of the thumb, causing radial stress at the

CMC joint. The flexor pollicis longus also causes radiovolar stress at the CMC joint when the thumb is retropositioned. The abductor pollicis longus as well causes radial stress as it attempts abduction of the thumb. All these stresses lead to attenuation of the intermetacarpal ligament and radiovolar subluxation. In most cases this creates no functional deficit. In about a third of patients it can prevent full opposition by locking of the CMC joint, and in these cases surgical intervention is warranted.<sup>4</sup>

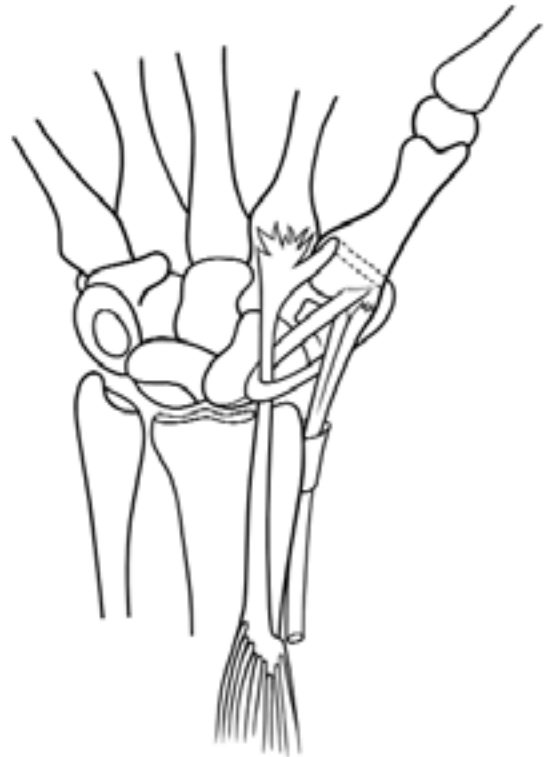
### 1) Joint Arthrodesis

Intracapsular arthrodesis such a performed in tetraplegia patients is technically difficult. A high non-union rate is reported in non-tetraplegic patients<sup>14</sup>, perhaps due to the increased hand power with resultant increased stress on the joint. Fritschi describes an intermetacarpal bone block.<sup>14</sup> However it is likely that an arthrodesis would cause a greater disability than the CMC dislocation and it is not recommended.

### 2) Capsular Reconstruction

In this procedure, described by Eaton<sup>12</sup>, the tendon of the flexor carpi radialis (FCR) is used to reinforce the weakened dorsal ligament and will only minimally restrict normal CMC movement.

**Technique:** An 'L' shaped incision is used with one limb along the thumb metacarpal and the other extending along the distal wrist crease (Fig. 7-14). The superficial radial artery and the branches of the dorsal sensory branch of the radial nerve must be preserved. The thenar muscles are elevated and the capsule excised. A subchondral (i.e. 5 mm distal to the metacarpal joint surface) channel is created in the metacarpal perpendicular to the thumbnail using a drill or gouge. The FCR tendon is exposed through a small transverse incision 8



**FIGURE 7-14** Reconstruction of thumb CMC joint using half flexor carpi radialis (FCR).

cm proximal to the wrist crease and the radial half mobilized proximally using one or two distal incisions until the radial strip is left attached only to the trapezium. This strip is then passed through the channel in the metacarpal base to emerge on the dorsal surface. This is facilitated with a wire or nylon suture. It is then sutured to the dorsal periosteum with the joint reduced and the thumb opposed under neutral tension. It is then passed under the insertion of the abductor pollicis longus on the metacarpal and sutured to reinforce the dorsal aspect of the joint. It is then passed under the insertion of the FCR and back onto the radial aspect of the joint capsule where it is again sutured to strengthen this aspect of the joint. It must not be sutured so tight as to restrict movement of the joint. The thenar muscles are reattached. Eaton uses a K-

wire to fix the MCP joint in 20° flexion.<sup>12</sup> The thumb is immobilized in opposition for four weeks after which gradual mobilization is commenced. Opponensplasty can be carried out within three months of surgery.

## SUMMARY

The balanced reconstruction of the thumb requires a good understanding of thumb anatomy and function to obtain good results. Each hand presents with its own unique impairments. These impairments and the patient's desires and expectations must all be taken into account while preparing a treatment program, which is unique for each patient. While the surgeon should not use a uniform procedure for all patients, he/she should use procedures that are familiar to both him/herself and the therapists on the team. With appropriate planning and good pre- and post-operative therapy results should be excellent for opponens reconstruction. In high median paralysis, transfers to provide extrinsic replacement will produce a functional hand satisfactory to the patient. The sensory deficit, while a significant disability, will not be a major obstacle in the use of the hand in a motivated and trained patient.

## REFERENCES

1. Anderson GA, Lee V, Sundararaj GD: Extensor indicis proprius opponensplasty. *J Hand Surg* 16B:334-338, 1991
2. Anderson GA, Lee V, Sundararaj GD: Opponensplasty by extensor indicis and flexor digitorum superficialis tendon transfer. *J Hand Surg* 17B:611-14, 1992
3. Antia NH, Enna, CD and Daver BM: *The Surgical Management of Deformities in Leprosy*. Oxford University Press, Bombay, 1992
4. Beine A: Abductor pollicis longus deviation graft operation: a new procedure on the thumb cum low median palsy for correction of subluxation of carpometacarpal (CMC) joint. *Ind J Lepr* 68:143-148, 1996
5. Brand PW. *Clinical Mechanics of the Hand*. CV Mosby, St. Louis, 1985
6. Bunnell S: Opposition of the thumb. *J Bone Joint Surg* 20:269-284, 1938
7. Burkhalter W, Christensen RC, Brown P: Extensor indicis proprius opponensplasty. *J Bone Joint Surg* 55A: 725-732, 1973
8. Burkhalter WE: Tendon transfer in median nerve paralysis. *Orthop Clin North Am*, 5: 271, 1974
9. Camitz H: Über die Behandlung der Oppositionslähmung. *Acta Chir Scand* 65:77-81, 1929
10. Cooney WP, Linscheid RL, An KN: Opposition of the thumb: An anatomical and biomechanical study of tendon transfers. *J Hand Surg* 9A:777-786, 1984
11. Davis TRC, Barton NC: Median Nerve Palsy. pp 1497-1525. In Green DP, Hotchkiss RN and Pederson WC (eds): *Operative Hand Surgery*. Churchill Livingstone, New York, 1993
12. Eaton RG, Lane LB, Littler JW, Keyser JJ: Ligament reconstruction for the painful thumb carpometacarpal joint. A long-term assessment. *J Hand Surg* 9A:692-699, 1984
13. Foucher G, Malizos C, Sammut D, Braun FM, Michon J: Primary palmaris longus transfer as an opponensplasty in carpal tunnel release. A series of 73 cases. *J Hand Surg* 16B:56-60, 1991
14. Fritschi, EP: *Surgical Reconstruction and Rehabilitation in Leprosy*. The Leprosy Mission, New Delhi, 1984
15. Jensen EG: Restoration of opposition of the thumb. *Hand* 10:161-167, 1978
16. Kleinman WB, Strickland JW: Thumb reconstruction. pp. 2068-2170. In Green DP, Hotchkiss RN and Pederson WC (eds): *Operative Hand Surgery*. Churchill Livingstone, New York, 1993
17. Malaviya GN, Husain S, Shantagunam P: Correction of "Z" pinch in ulnar paralysis of leprosy by transfer of flexor pollicis longus to extensor pollicis longus. *Eur J Plast Surg* 14:120-125, 1991
18. Mehta R, Malaviya GN, Husain S: Extensor indicis opposition transfer in the ulnar and median palsied thumb in leprosy. *J Hand Surg* 21B: 617-621, 1996

19. Mennen U: Extensor pollicis longus opposition transfer. *J Hand Surg* 17A:809-811, 1992
20. North ER, Littler JW: Transferring the flexor superficialis tendon: Technical considerations in the prevention of proximal interphalangeal joint instability. *J Hand Surg* 5:498-501, 1980
21. Omer GE Jr: Ulnar nerve palsy. pp. 1526-1541. In Green DP, Hotchkiss RN and Pederson WC (eds): *Operative Hand Surgery*. Churchill Livingstone, New York, 1993
22. Riley WB, Mann RJ, Burkhalter WE: Extensor pollicis longus opponensplasty. *J Hand Surg* 5:217-220, 1980
23. Riordan DC: Tendon transfers of the hand and wrist. *Curr Pract Orthop Surg* 5:217-220, 1980
24. Rowntree T: Anomalous innervation of the hand muscles. *J Bone and Joint Surg* 52A:178-179, 1970
25. Warren G: Tendon Transfers. pp. 215-222. In Conally WB (ed): *Atlas of Hand Surgery*. Churchill Livingstone, 1997
26. Zancolli EA, Cozzi EP: *Atlas of Surgical Anatomy of the Hand*. Churchill Livingstone, New York, 1992



## Radial Nerve Palsy

- R. SCHWARZ
- J. JOSHUA
- G. WARREN

### INTRODUCTION

Radial nerve palsy is a serious functional impairment, causing loss of wrist, finger and thumb extension. The loss of wrist extension causes wrist instability and forces the fingers to flex at a mechanical disadvantage due to the finger flexors commencing action in a shortened position. This greatly reduces the strength in power grip. The loss of finger and thumb extension deprives the hand of the ability to grasp large objects. In leprosy, radial nerve palsy is often associated with median and/or ulnar palsy, which greatly compounds the impairment and limits the number of tendons available for transfer. The usual combination seen is a high radial palsy, a high ulnar palsy and a low median palsy. Many combinations of transfers have been developed for the treatment of radial nerve palsy.<sup>2,3,8,9,18,21,26,31</sup> The actions that need to be restored are wrist extension, finger extension, and thumb extension-abduction. In triple nerve palsy thumb abduction and primary finger metacarpophalangeal flexion must be restored. The standard transfers that will be described in this chapter are shown in Table 8-2. While the standard transfers are very successful when performed correctly, Riordan correctly points out that "there is usually only one chance to obtain good restoration of function in such a paralyzed hand."<sup>28</sup> If the first procedure is not performed well, with excellent follow-up care, the chance of making a good functional hand is small.

The surgeon must have a good understanding of the three-dimensional anatomy of the

forearm and should review this prior to surgery. The principles of tendon transfer surgery as outlined in Chapter 1 must be followed carefully.

**TABLE 8-1:** List of abbreviations used in this chapter.

ECRB	Extensor carpi radialis brevis
ECRL	Extensor carpi radialis longus
ECU	Extensor carpi ulnaris
EDM	Extensor digiti minimi
EPL	Extensor pollicis longus
FCR	Flexor carpi radialis
FCU	Flexor carpi ulnaris
FDS	Flexor digitorum superficialis
PL	Palmaris longus
PT	Pronator teres

**TABLE 8-2:** Tendon transfer program for triple nerve palsy.

<b>First Stage</b>
PT to ECRB yoked to re-routed ERCL
FCR to EDC (and possible EPL)
PL to re-routed EPL
<b>Second Stage</b>
FDS (long) to lateral bands
FDS (ring) opponensplasty

The issues involving nerve repair, in case of trauma, will not be addressed here. The reader is referred to Green's discussion of this if desired.<sup>15</sup> While some advocate early transfer as a splint to prevent contracture. I would suggest that the therapy team should be able to prevent such problems during the time of potential nerve recovery.<sup>7,22</sup>

### **Pre-Operative Treatment**

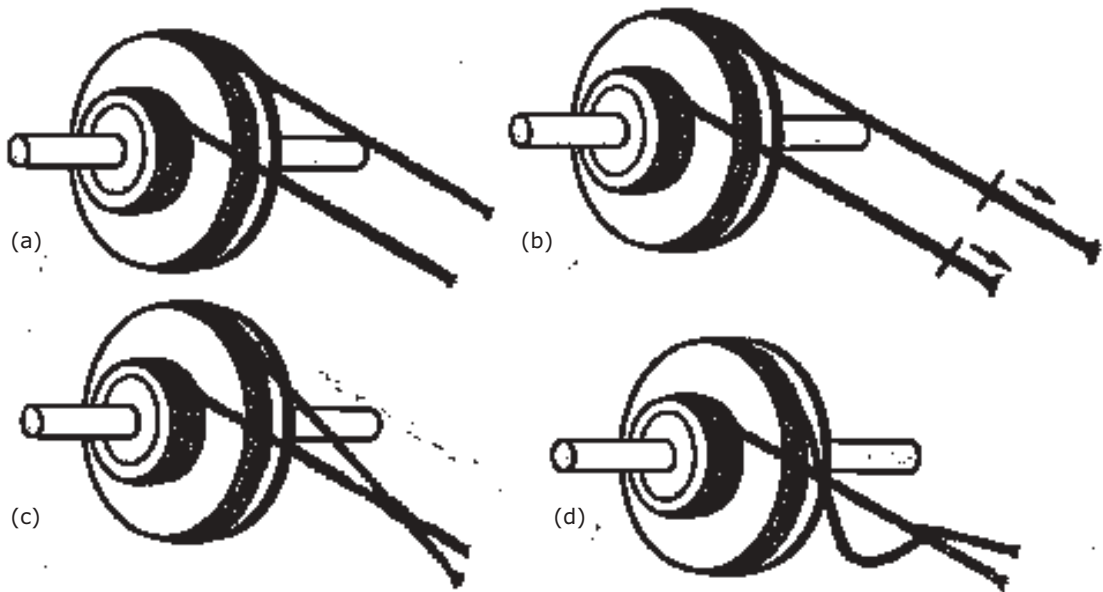
It is essential that the therapy team obtains and maintains joint mobility prior to tendon transfer and also to 'stretch' the long flexors out to full length. Thumb webspace contracture, if present, must also be corrected. Splinting is required, both to prevent contractures and to provide the mechanical advantage that wrist extension gives. Burkhalter notes that a simple cockup wrist splint can increase grip strength by three to five times.<sup>23</sup> More complex splints can be designed that provide dynamic extension of the thumb and fingers using outriggers with rubber bands that allow full flexion.<sup>12</sup> However these are very conspicuous and would probably only be used by those who will need to continue doing fine manual work prior to definitive surgery. Brand recommends that if only a cockup wrist splint is used then at night a splint that keeps the fingers also in extension should be used to prevent long flexor contractures.<sup>4</sup>

## **RECONSTRUCTION OF WRIST EXTENSION**

There have been many modifications of the basic Pronator Teres (PT) to Extensor Carpi Radialis Brevis (ECRB) transfer since Jones first described the procedure in 1916.<sup>18</sup> A few authors have advocated wrist arthrodesis.<sup>11,18</sup> However the advantages of active wrist extension are so strong and the results of an active tendon transfer are generally so good that there is little reason to do a wrist arthrodesis as a primary procedure unless there are inadequate muscle-tendon units available for transfer. Brand has extensively studied the moment arms for the muscle tendon groups of the hand and has devised a procedure which is a modification of Jones' original procedure.<sup>4</sup> We recommend this procedure as the most sound and most likely to function without complications.

### **Pronator Teres to Extensor Carpi Radialis Brevis Transfer**

The ECRB has a strong moment arm for wrist extension but it also has a moment arm for radial deviation. Therefore a simple PT to ECRB transfer may lead to the development of radial deviation of the wrist, which wastes the PT movement in a non-useful direction of movement. FCU (if present) can resist this but this will weaken wrist extension. Three of fourteen patients undergoing PT to ECRB surgery in our series developed radial deviation adversely affecting function<sup>21</sup>, and 5 of 40 patients in Chotigavanich's series developed radial deviation.<sup>9</sup> Some have also advocated yoking ECRB to ECRL.<sup>18</sup> ECRL has a greater moment arm for radial deviation than wrist extension, thereby further aggravating the problem. Brand has shown well, when two tendons are yoked together, the one with the smaller moment arm will be preferentially activated by the transfer (Fig. 8-1).<sup>4</sup> As ECRL has a shorter moment arm than ECRB for radial abduction, it will be the prime wrist mover, thereby pulling the hand into radial deviation following surgery. Brand tried yoking ECRB to ECU, but found that ECU had a small moment arm for wrist extension, and none when the wrist was pronated. He recommends yoking ECRB to ECRL, detaching ECRL from its insertion in the base of the second metacarpal and reinserting it into the base of the fourth metacarpal.<sup>4</sup> This insertion has the same moment arm for extension as the ECRB, and will therefore give balanced extension. Tubiana describes a similar procedure using the same rationale.<sup>31</sup> This transfer is the key to success of a rehabilitation program for someone with combined nerve palsies. Good wrist extension is necessary for effective finger flexion and will optimize the function of tendon grafts for intrinsic and opponens transfers. Interestingly, the muscle fibre excursion for the PT (25 mm) is only half that of the wrist extensors (59 mm). The fact that many patients undergoing PT



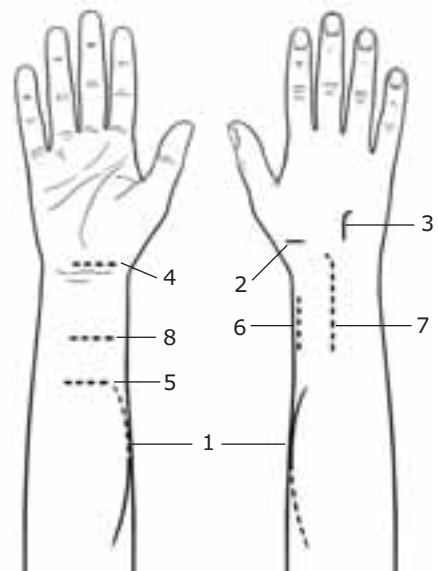
**FIGURE 8-1** **a.** Two pulley wheels fixed to a common axle. **b.** For a given amount of rotation, the larger rope releases a longer length of rope (tendon) **c.** Both ropes are fixed together, similar to a double tendon insertion. **d.** Pulling on common rope (tendon) causes the rope on the wheel with the larger moment arm to become slack. Only the smaller wheel is functional (from Brand<sup>4</sup>, used with permission).

transfers for wrist extension eventually achieve a full range of motion implies that the excursion of the pronator muscle actually increases following surgery.<sup>29</sup> Brand suggests that sarcomeres are added or removed in response to a change in the tension of a muscle at rest, but that this process is slow.<sup>5</sup>

**Technique:** The PT to ECRB transfer is usually combined with the FCR- to-EDC (Flexor Carpi Radialis to Extensor Digitorum Communis) transfer. Only the incisions for the wrist extension part of the procedure will be described here (Fig.8-2). An 8-10 cm curved incision (1) is made over the convex part of the middle of the radial border of the forearm to expose the insertion of the PT and the tendons of ECRB and ECRL. At this level the ECRB tendon is usually surrounded by muscle but the tendon is easily found inside.

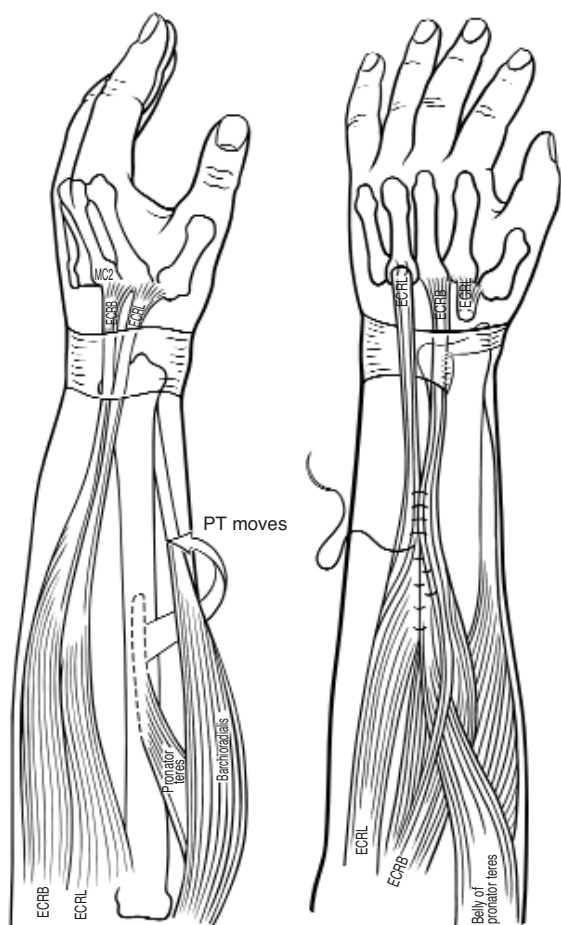
The insertion of PT is identified by following the muscle down to its fanlike insertion

onto the radius. The end is grasped and cut off the radius, taking care to include a 1-2 cm strip of periosteum with it to use for the anastomo-



**FIGURE 8-2** Incisions for PT to ECRB transfer (dark lines) and FCR to EDC transfer/ PL to EPL transfer (light lines). **a.** Volar aspect **b.** Dorsal aspect. Incisions are numbered as in text.

sis. It is easy to miss some of the upper attachments of PT to the radius. The PT is then brought around, superficial to the brachioradialis, to avoid adhesions to the radius (Fig. 8-3a). The wrist is put in a 45° extension splint. A small transverse incision (2) is then made over the insertion of ECRL, making sure it is not the extensor pollicis longus. The ECRL is detached and brought out through the proximal incision and then passed down superficial to deep fascia to a small incision (3) over the base of the fourth metacarpal (Fig. 8-3b). Attachments of



**FIGURE 8-3 a.** The PT is elevated with a strip of periosteum and transferred above the brachioradialis. **b.** ECRL is transferred to base of the ring metacarpal, ECRL is attached to ECRB and the PT is attached to ECRB (from Warren<sup>33</sup>, used with permission).

the ECRL to radius are freed to allow it to lie on the ulnar side of the ECRB. Here a distally based flap of periosteum is elevated and the end of the ECRL is fixed to periosteum with braided nylon suture. If finger and thumb extension transfers are being done in the same operation they are completed at this point.

The ECRB is then sutured side to side to the ECRL while applying equal tension on both tendons. The PT is passed through the joined ECRB/ECRL tendon as far distally as possible and sutured with braided nylon with moderate (1 cm) tension. The end is buried in the muscle and the anastomosis is covered with 6-0 monofilament nylon. The skin incisions are then closed. The wrist is immobilized in 45 degrees of extension for four weeks before mobilization is commenced (see Chapter 21 for specific therapy techniques).

## RECONSTRUCTION OF FINGER/ THUMB EXTENSION

### *Thumb extension*

Brand advocates the use of the palmaris longus (PL), when available, as the active tendon, to replace the extensor pollicis longus (EPL).<sup>4</sup> In the absence of the PL, the FCR is the tendon of his choice. The replacement of the abductor pollicis longus (APL) is also stressed by Brand, as it acts as an extensor of the metacarpal of the thumb, providing for a "circle" pinch. To achieve this, the preferred active muscle is the FCR. However in these instances, Brand is considering the radial paralysis alone with normally functioning intrinsic muscles.

However in cases of leprosy, we normally encounter a triple nerve paralysis, where the adductor pollicis and other intrinsic muscles of the hand are paralysed and consequently, the muscle imbalance is different. Moreover the number of active muscles available for the transfer is limited.

### **Finger Extension**

Many active muscles have been used in the replacement of finger extensors. Jones advocated the use of the FCU<sup>18</sup>, while Brand has used the FCR for four-finger extension.<sup>3,4</sup> Clezy,<sup>11</sup> and later Fritschi,<sup>13</sup> have advocated the use of the FCR for the restoration of four-finger and thumb extension. Goldner and Kelly<sup>14</sup> and later Boyes<sup>2</sup> and Chuinard,<sup>8</sup> have recommended the use of the FDS muscles of the ring and/or middle fingers for finger extension. However this is acceptable only if the radial nerve is the only paralysed nerve. If there is associated ulnar and median nerve palsy (triple nerve palsy), as is usually the case in leprosy, these tendons are needed for intrinsic muscle replacements.

#### *Advantages and disadvantages of various procedures*

The PL, if present, is an ideal muscle to use for thumb extension. The EPL tendon may be rerouted more radially to be attached to the PL to improve the direction of action.

The FCU as the extensor of the fingers has the advantage of being strong and well able to provide the necessary action. However, it lacks the excursion required to provide a complete range of motion. (Its ulnar side fibres are only 4 cms long). It is also too bulky and causes an unsightly bulge as it crosses over on the ulnar border of the wrist from the flexor to the extensor aspect. It is an important muscle in its own right, causing essential ulnar deviation in activities like hammering and cutting vegetables. Use of this muscle for the transfer deprives the wrist and hand of these effective actions.

The FCR has the advantage of having greater excursion than the FCU and therefore can cross more than one joint. It is also less bulky and therefore is not as unsightly on transfer. It has the disadvantage of having the scar of all tendon junctions at the region of the extensor retinaculum. This can cause problems with mobilization in the post-operative period due to adhesions.

The FDS muscles to the ring and middle fingers have the advantages of good length so that the tendon sutures lie well distal to the retinaculum reducing the risk of adhesions. The FDS has adequate excursion to allow full range and independent movement of the wrist and fingers. The relative disadvantage is that the FDS are antagonists to the movement they are required to produce making re-education more difficult.

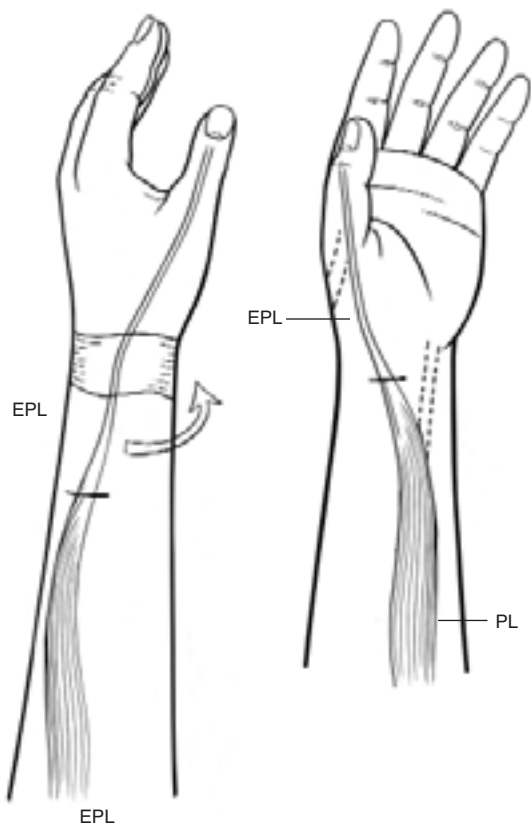
This transfer is usually done in combination with the previously described procedure for extension of the wrist; that is, in the same sitting it will follow Pronator Teres transfer to the ECRB.

### **Palmaris Longus to Extensor Pollicis Longus and Flexor Carpi Radialis to Extensor Digitorum Communis Transfer**

**Indication:** Radial nerve paralysis in isolation or in combination with a high ulnar and low median paralysis.

**Technique:** Following the PT to ECRB transfer, a small incision (4) (Fig. 8-2) is made over the wrist crease over the visible PL tendon. The tendon is identified, isolated and withdrawn in the forearm via incision 5, about 10 cms proximally. Through a longitudinal incision (7) just proximal to Lister's tubercle over the level of the extensor retinaculum, the EPL is identified and isolated. It is divided at its musculo-tendinous junction. This tendon is withdrawn distally, just proximal to the metacarpophalangeal joint of the thumb. It is tunneled subcutaneously to lie over the tendon of the APL. The PL tendon is then tunneled subcutaneously to meet the EPL at this point, incision 6. It will lie basically in line with the first metacarpal. The two tendons are sutured here with a short interlace, under high tension, with the thumb positioned in extension in the same plane as the palm (Fig. 8-4).



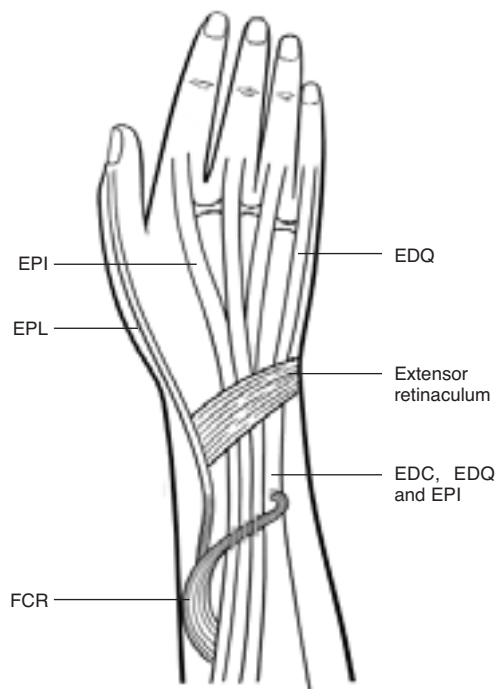


**FIGURE 8-4** Route of PL to EPL transfer. Moving the EPL tendon to the radial side of the wrist will produce both abduction and extension.

Through the same incision over the wrist crease, just proximal to the insertion of the FCR, the tendon is isolated and detached from its insertion and recovered in the forearm through a transverse incision (8) about 7 cm proximally. A longitudinal incision (7) is made on the midpoint of the dorsum of the wrist and the extensor retinaculum is cut along the same line to expose the EDC. The FCR is tunneled subcutaneously into this incision, finding the path of least resistance using a blunt instrument.<sup>4</sup> Setting the tension correctly is difficult, especially in triple nerve palsy. With the wrist in about 45 degrees extension, and the fingers extended fully at the metacarpophalangeal joints, the FCR tendon is passed through the

individual slips of the extensor digitorum as distally as possible after taking up the slack. It is sutured in such a manner as to incorporate all the tendons in the stitch (Fig. 8-5). Another method is to insert the FCR into the extensor tendons of the ring and middle fingers and then to attach the tendon of the index to that of the middle and the tendon of the little finger to that of the ring finger. Most authors do not include the EDM for fear of creating too much extension/abduction in the little finger.<sup>1</sup> Green suggests pulling on the EDC to assess the adequacy of little finger extension.<sup>15</sup> If there is an extensor lag of the little finger, the EDM is also included in the transfer.

The transfer should then be tested passively. Wrist flexion should produce MCP joint extension but not hyperextension. With the wrist extended it should be possible to achieve full



**FIGURE 8-5** FCR to EDC transfer. A single weave is carried out obliquely, and the unsatisfied end is buried in one of the extensor tendons. A similar join is carried out for an FDS transfer but comes either through the interosseous membrane around the ulnar border.

finger flexion. The tourniquet is now released, haemostasis achieved and the wounds closed.

In case the PL is absent, Brand advises the use of one of the FDS tendons for extension of the thumb.<sup>3</sup> This however can be done only if the paralysis is confined to the radial nerve, as the FDS tendons will be needed for intrinsic replacement procedures in a triple nerve palsy. Fritschi,<sup>14</sup> and McEvvitt and Schwarz<sup>21</sup> however, advocate the use of the FCR divided in two slips, one for thumb extension and the other for four-finger extension even when the palmaris longus is present. The EPL can be taken out of the dorsal retinaculum as shown in Fig. 8-5 to give more abduction. They advise leaving the palmaris longus in situ as a flexor of the wrist.

***Multiple Flexor Digitorum Superficialis to Extensor Pollicis Longus and Extensor Digitorum Communis Transfer***

***Indication:*** Isolated radial nerve paralysis

***Technique:*** The FDS of the ring finger and/or middle finger are detached from their insertions through incisions in the respective fingers and recovered in the mid forearm. Here they are tunneled through a window in the interosseous membrane passing on either side of the flexor tendon mass. The tendons are received in the dorsum and then tunneled subcutaneously to the dorsum of the wrist. The extensor retinaculum is opened. The EDC tendons and the EPL are identified. The middle finger superficialis is attached to the EDC and that of the ring finger is attached to the EPL. The postoperative immobilization regime is the same as that described for the FCR and PL transfers (see below), although specific therapy techniques will obviously differ.

When the PL is available for the thumb, the FDS of the middle finger alone can be used for the four fingers.

***Post-operatively:*** Place the arm in a full plaster from the fingertips to the upper arm, with the forearm fully pronated and the elbow at 90°. The wrist is kept at 45° of extension with the fingers kept fully extended. The plaster is bivalved at three weeks and cut off below the elbow. Gentle range of motion and transfer activation exercises are commenced. By seven weeks post-op a full unrestricted range of motion should be achieved (see Chapter 21). Physiotherapy should be continued until adequate wrist extension is achieved. Schreuders et al demonstrated continued improvement in active range of movement following a PT to ECRB transfer up to one year following the surgery.<sup>24</sup> This is probably because therapy not only trains the patient to effectively use the transfer, but also trains the muscle to increase its excursion as noted above. It appears to take some time for a muscle to increase its excursion.

***Wrist Arthrodesis:*** Arthrodesis of the wrist should be reserved as a last option, as loss of movement of the wrist adversely affects the functioning of the hand. Even with a triple palsy with a high median nerve involvement, a more functional hand can be obtained with the 'hinge hand' operation (see below) than with an arthrodesis. Weiss et al<sup>33</sup> report that efficiency of hand function decreases by only about 20% following wrist fusion, but it should be noted that these were patients with normal neurologic status. Patients with multiple nerve paralysis would be expected to have a greater negative impact on hand function from wrist arthrodesis.

***Indications:***

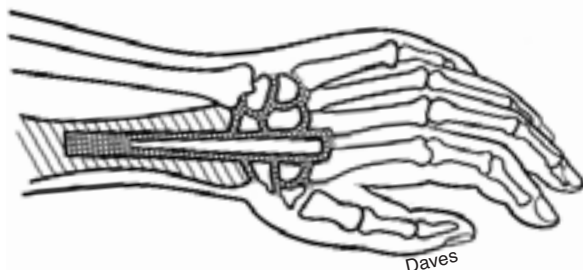
1. Wrist instability, subluxation or neuropathic degeneration.
2. Failed PT to ECRB transfer without hope of successful revision.
3. Triple nerve palsy with high median involvement (relative).

There are now several methods of internal fixation available, which can be used if the equipment is obtainable. Arbeitsgemeinschaft Osteosynthesefragen (AO) techniques of plating have reported non-union rates of 0-2%.<sup>17,33</sup> The following method requires only K-wire fixation, is easy to perform and has a very high success rate.<sup>13</sup> If tendon transfers are planned in the same hand, the arthrodesis should be carried out before the transfer to avoid disuse and further adhesions of the transfer. The ideal position of wrist fusion has not been determined. In one study common activities of daily living were found to use an arc between 10 degrees of flexion and 35 degrees of extension.<sup>6</sup> Most authors recommend a position of about 10 degrees of extension.<sup>16</sup> Pryce<sup>25</sup> reported that power grip was greatest in slight extension and ulnar deviation, and Kraft and Detels<sup>19</sup> found that grip strength was similar from 0-30 degrees of extension but was weakened in flexion. It would seem that a position of between 0 and 10 degrees would be ideal.

**Technique:** A lazy S incision is made from the base of the third metacarpal to a point 7 cm proximal to the tip of the radial styloid in the center point of the dorsal forearm. The skin is mobilized at the level of the deep fascia, preserving as many of the veins as possible. The deep fascia and retinaculum are then raised as an ulnar-based flap along the full length of the incision. This can be difficult to keep as one piece, especially over the distal radius. The extensor tendons are now exposed. The extensor digitorum tendons are retracted ulnarwards and the extensor pollicis longus tendon radially. The periosteum is then stripped off of the radius. A strip of bone graft is harvested from the distal end of radius by cutting a groove 5 cm long, 5 mm deep and 6 mm wide, tapering distally. An oscillating or circular saw is best for this, although I (RS) usually use osteotomes. The joint spaces of the

radioscaphoid, radiolunate, capitulunate joints are opened and the articular cartilage of each joint surface is removed with bone nibblers, saw or a gouge. Some also include the third CMC joint.

With the wrist held in 30° extension, the groove in the radius is extended through the lunate and scaphoid using a gouge or fine nibblers. This groove is then continued directly into the head of the capitate, gouging a hole with a gouge or a drill with the wrist in flexion (Fig. 8-6). This extends up into the base of the third metacarpal and must be wide enough to fit the bone graft. The distal end of the bone graft is then gently hammered into the hole, after which the wrist is slowly extended until the graft fits back into the groove. Cross K-wires are used to stabilize the wrist. Any remaining cancellous bone is used as bone graft. The periosteum is then sutured over the graft and the fascial flap sutured over the tendons and skin closed.



**FIGURE 8-6** Wrist arthrodesis. The bone graft is harvested from the distal dorsal radius and placed in the carpus and inserted into the base of the third metacarpal after creation of a groove through the lunate, scaphoid and capitate.

A plaster extending from the PIP joints to above the elbow is placed for 10 weeks total. A check X-ray must be taken prior to plaster removal. The plaster can be trimmed to allow finger movement at four weeks. If not buried the K-wires should be removed at one month.

The finger and thumb extension procedures can be carried out when there are 3 weeks remaining until plaster removal.

**Complications:** Infections and skin edge necrosis are unusual. The most common, and serious, complication is delayed or non-union. The rate of non-union has been reported at 5-18% using techniques not utilizing plates.<sup>10,16</sup> AO plate methods of fusion however have reported non-fusion rates of 0-2%.<sup>16</sup> Adhesions of extensor tendons can occur. Carpal tunnel syndrome has been reported in 4-10% of arthrodeses using the AO plate fixation.<sup>16</sup>

### COMBINED NERVE PALSIES

As mentioned, in leprosy radial nerve palsy is usually seen in combination with median and/or ulnar palsies. Combined nerve palsies may be seen in other peripheral neuropathies as well. A complete hand assessment is mandatory to determine which muscles are still available for transfer. In the presence of a low median/high ulnar palsy, the most usual presentation, the usual plan is a two or three stage reconstruction to carry out the procedures outlined in Table 8-2. In the first stage the wrist and finger/thumb extension replacement procedures are performed. There is concern that removing the PL would leave the wrist without a dedicated flexor. Zachary has demonstrated that the PL alone is not adequate to provide wrist flexion in a hand with a simple radial nerve palsy.<sup>34</sup> While it appears to be adequate in a triple nerve palsy hand, removing it will leave the wrist without an independent flexor. For this reason we usually use FCR to activate extension in both fingers and thumb. However the finger flexors will also stabilize the wrist in flexion. Therefore if independent thumb extension is needed the PL could be used in this situation. In the second stage a sublimus transfer (FDS to lateral bands, see Chapter 6) is carried out for intrinsic replacement, and an opponens replacement is performed using flexor digitorum superficialis (Chapter 7). It is important to avoid making the sublimus replacement so

tight that the finger extensor transfer is unable to extend the metacarpophalangeal joints.<sup>1</sup> It is best to do a Bunnell type transfer to the lateral bands as opposed to the flexor pulleys, as with the latter the finger extensors have to extend the interphalangeal joints on their own. Arthrodesis of the thumb metacarpophalangeal joint or a half flexor pollicis longus transfer would be appropriate for stabilizing the thumb (Chapter 6).

It should be noted that not all patients with a triple nerve palsy will be candidates for all procedures. In our study 18 of 21 patients undergoing reconstructive surgery for radial nerve palsy secondary to leprosy reactions had involvement of all three nerves.<sup>21</sup> Of these 18, only eight had intrinsic reconstruction and ten had opponens reconstruction. Reasons for this were partial nerve palsy, refusal of further surgery, or unsuitability for further reconstruction. Some patients presented with severe contractures or shortened digits and were not considered candidates for reconstruction of all functions.

In combined low median and high radial nerve palsy with an intact ulnar nerve, an FCR to EDC transfer should be carried out. The FCU will maintain wrist flexion. The PL should then be used with a re-routed EPL to provide thumb extension and abduction. This procedure may provide enough abduction that the patient may not desire to proceed with an opponensplasty. Combined high median and radial nerve palsy with intact ulnar nerve is virtually never seen in leprosy. If it does present, Omer recommends wrist arthrodesis, or PT to ECRB transfer if available, for wrist extension with the FCU transferred to EDC and EPL for finger/thumb extension.<sup>22,23</sup> A tenodesis of FDP tendons of the index and middle finger to FDP of ring and little fingers is carried out to give active finger flexion of all fingers. The thumb is stabilized by thumb MCP arthrodesis,

tenodesis of FPL across the IP joint and tenodesis of the APL tendon to the radius.

If the median nerve is intact with a combined radial/ulnar palsy then a Bunnell type sublimus transfer is carried out as second stage procedure. Again, arthrodesis of the thumb metacarpophalangeal joint or a half flexor pollicis longus transfer would be appropriate for stabilizing the thumb.

### The hinge hand procedure

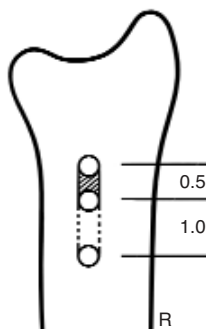
It is not uncommon to be requested to reactivate a hand in which there are very few muscles functioning. The patient desires appearance, social acceptability and as much function as possible. There are many options aimed at providing the maximum possible function and appearance. Transfers for tetraplegic patients are described elsewhere.<sup>16</sup> However there is a relatively simple procedure that often gives a satisfactory result in the severely motor deficient hand.

If there is only one muscle of reasonable strength that can be used in isolation, it can be used to activate wrist extension to provide a "hinge hand". The hand at rest should be in a normal posture and when the wrist is extended the fingers close for grasp. Patients do not have a lot of strength but there is usually enough stability to hold large light objects especially if they have a stem for easy holding. If this muscle can be used to provide a good wrist extension it is possible by tenodesis of the flexors to provide a hand that grasps, albeit weakly.

A normal strength ECRB or ECRL is usually adequate although the wrist extension may be stabilised by yoking one tendon to the 4th metacarpal base to give pure wrist extension. No other active transfer will be needed. If there is no active wrist extensor it is necessary to transfer some other muscle, yoked to give better wrist extension stability. Suitable muscles need to be relatively strong and they include brachioradialis, pronator teres, flexor carpi radialis and FDS.

It is desirable to tenodesise any extensor tendons at the same time as the active transfer is inserted. This allows a uniform tension to be achieved across all extensors. The technique described is similar to that of Zancolli.<sup>35</sup> The flexor tendons are tenodesised 3 months or longer before the extensors are dealt with so that they can be put in more tightly than would be possible if extensors were done first. A tenodesis of thumb opposition can also be performed, usually at the time of the flexor tenodesis. This will alter the ability to grasp objects of wide diameter but will improve the ability to hold something like a drinking glass with a narrow stem as the rim of the glass will be supported all around. Alternately, the abductor and long flexor of the thumb can be tenodesised.

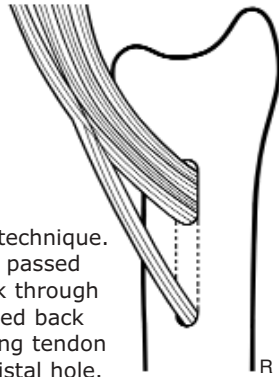
**Technique-flexors:** Initially the flexor side is operated on. The FDS tendons are located about 2-3 cm above the wrist on the radial side of the forearm, and sutured together, side by side, when the fingers are straight. For attachment to the radius, use a small 2-3 mm diameter drill or burr and drill a series of 3 small holes, the distal two being 0.5 cm apart and the third one some 1 cm proximal. The bridge of bone between these two distal holes is removed so a cavity down to the marrow is displayed (Fig. 8-7). The flexor tendons are identified and pulled tight with the fingers extended, and wrist straight or up to 10 degrees flexion.



**FIGURE 8-7** Tenodesis technique. Three holes are drilled in the distal radius. Then the bone between the distal two holes is nibbled to create a larger single hole. A sub-cortical tunnel is then created between these two holes through which a single tendon will then be passed.

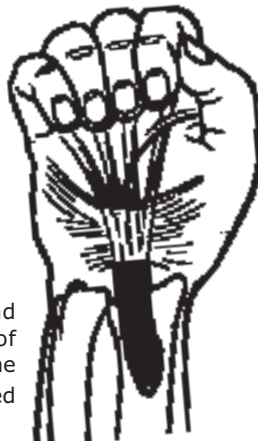

They are sutured together at the site of the distal hole. The long finger tendon is then cut and passed into the distal hole and out through the proximal hole. A strong Silk or braided nylon is used to pass this tendon into the distal cavity and out through the proximal hole so the tendon can be sutured back to itself, (Fig. 8-8). This means that only 3-4 weeks immobilisation is



**FIGURE 8-8** Tenodesis technique. A single flexor tendon is passed from the distal hole back through the proximal to be sutured back to itself and the remaining tendon ends are buried in the distal hole.

required for enough healing to start physiotherapy. If the tendon is inserted in bone via a Bunnell suture so that the tendon just ends in the bone a much longer immobilisation is required. This tenodesis ought to result in the fingers being flexed at the MCP and PIP joints when the wrist is extended (Fig. 8-9). The degree of flexion will depend on the position of the wrist when the tendon length is cut before suturing.



**FIGURE 8-9** Hinge hand procedure. Extension of wrist produces flexion of the fingers (from Warren<sup>33</sup>, used with permission).

The long extensor of the thumb can be attached similarly but it is often better to divide EPL and attach it to the insertion of FCR so that the thumb automatically pulls out straight and into abduction when the wrist extends. This should be done at the same time as the flexor tendon tenodesis. McDowell and House recommend stabilizing the thumb by carpometacarpal joint fusion, combined with a half flexor pollicis longus to extensor pollicis longus transfer to stabilize the interphalangeal joint.<sup>20</sup> After this procedure the arm is plastered with the wrist flexed, the fingers straight and the thumb fully opposed and abducted.

*Technique-extensor:* The methodology for transferring the basic active motor (PT or if absent brachioradialis) into ECRB is as described above.

For the finger extensors it is necessary to open the forearm for about 5 cm proximal to the wrist with an incision that allows dissection onto the ulna bone about 2-3 cm proximal to the wrist joint, where the tendons will be attached. The attachment technique is the same as for the FDS (Fig. 8-10). The tension for this suture is fixed at neutral when the fingers are straight and wrist extended about 10-15 degrees. This should allow the fingers to straighten when the wrist is allowed to drop towards flexion (Fig. 8-11), but to flex at the MCP and IP joints when the wrist is extended.



**FIGURE 8-10** Hinge hand procedure. Attachment of finger extensors to ulna (from Warren<sup>33</sup>, used with permission).



**FIGURE 8-11** Hinge hand procedure. Flexion of wrist produces finger extension and thumb extension and abduction (from Warren<sup>33</sup>, used with permission).

The exact tension that can be applied will depend on what the tension is in the flexor tendons. This can easily be tested on the table before final suturing and closure.

The arm is plastered with wrist fully extended and the fingers straight as is done for the pronator teres splint. If the thumb has also been operated on it will require to be held in abduction and opposition. The plaster ought to be above elbow especially if ECRB or BR is the used motor.

Physiotherapy is relatively easy. The cast is left on for 4 weeks and then the transferred wrist extensor is re-educated. The fingers will automatically activate so that when the wrist extends the fingers flex, and when the wrist flexes the fingers extend and the thumb is abducted and extended.

## SUMMARY

While radial nerve palsy, and especially combined nerve palsies, are a serious disability, surgery for these conditions is usually very rewarding. Careful attention to technique is essential to achieve correct balance, and skilled therapy is necessary to achieve a good result.

## REFERENCES

1. Beasley RW: Tendon transfers for radial nerve palsy. *Orthop Clin North Am* 1:439-445, 1970

2. Boyes JH: Tendon transfers for radial palsy. *Bull Hosp Joint Dis* 21:97-105, 1960
3. Brand PW: Tendon Transfer Reconstruction for Radial, Ulnar, Median and Combination Paralysis: Principles and Techniques. pp 4923-4965 In McCarthy.J.G: *Plastic Surgery*, Vol 8. WB Saunders Company, Philadelphia, 1990
4. Brand PW: Biomechanics of Tendon Transfer. pp 190-213. In Lamb DW (ed): *The Hand and Upper Limb*, Vol. 2. The Paralysed Hand. Churchill Livingstone, Edinburgh, 1987
5. Brand PW: Biomechanics of balance in the hand. *J Hand Ther* 6: 247-251, 1993
6. Brumfield RH, Champoux JA: A biomechanical study of normal functional wrist motion. *Clin Orthop* 187:23-25, 1984
7. Burkhalter WE: Early tendon transfer in upper extremity peripheral nerve injury. *Clin Orthop* 104:68-79, 1974
8. Chuinard RG, Boyes JH, Stark, HH et al: Tendon transfers for radial nerve palsy: use of superficialis tendons for digital extension. *J Hand Surg* 3: 560-570, 1990
9. Chotigavanich C: Tendon transfer for radial nerve palsy. *Bull Hosp Joint Dis* 50):1-10, 1990
10. Clendenin MB, Green DP: Arthrodesis of the wrist- complications and their management. *J Hand Surg* 6:253-257, 1981
11. Clezy JKA. Triple paralysis of the hand. pp 263-268 In McDowell F, Enna CD (eds): *Surgical rehabilitation in leprosy*. Williams and Wilkins, Baltimore, 1974
12. Colditz JC: Splinting for radial nerve palsy. *J Hand Ther* 1:18-23, 1987
13. Fritchi EP: *Surgical Reconstruction and Rehabilitation in Leprosy*. The Leprosy Mission, New Delhi, 1984
14. Goldner, JL, Kelly, JM: Radial nerve injuries. *South Med J*, 51:873,1958
15. Green DP: Radial nerve palsy. pp 1481-1496 . In Green DP, Hotchkiss RN and Pederson WC (eds): *Operative Hand Surgery*. Churchill Livingstone, New York, 1993
16. Hastings H: Wrist arthrodesis. pp 131-146. In Green DP, Hotchkiss RN and Pederson WC (eds): *Operative Hand Surgery*. Churchill Livingstone, New York, 1993
17. Hastings H: Arthrodesis of the Osteoarthritic Wrist. pp 345-360. In Gelberman RH (ed): *The Wrist*. Raven Press, New York, 1994
18. Jones R: Tendon transplantation in cases of musculospiral injuries not amenable to suture. *Am J Surg* 35:333-335, 1921

19. Kraft GH, Detels PE: Position of function of the wrist. *Arch Phys Med Rehabil* 53:272-275, 1972
20. McDowell CL, House JH: Tetraplegia. pp 1588-1606. In Green DP, Hotchkiss RN and Pederson WC (eds): *Operative Hand Surgery*. Churchill Livingstone, New York, 1993
21. McEvitt, Schwarz RJ: Tendon transfer for triple nerve palsy. *Lep Rev* 73: 319-322, 2002
22. Omer GE Jr : Tendon transfers for reconstruction of the forearm and hand following peripheral nerve injuries. pp 817-846. In Omer GE Jr, Spinner M (eds): *Management of Peripheral Nerve Problems*. WB Saunders, Philadelphia, 1980
23. Omer GE: Combined nerve palsies. pp 1542-1555. In Green DP, Hotchkiss RN and Pederson WC (eds): *Operative Hand Surgery*. Churchill Livingstone, New York, 1993
24. Parker D: Radial nerve paralysis treated by tendon transplant and arthrodesis of the wrist (abstract). *J Bone Joint Surg* 45B: 626, 1963
25. Pryce JC: The wrist position between neutral and ulnar deviation that facilitates the maximum power grip strength. *J Biomech* 13:505-511, 1980
26. Raskin KB, Wilgis EF: Flexor carpi ulnaris transfer for radial nerve palsy: functional testing of long term results. *J Hand Surg* 20:737-42, 1995
27. Reid RL. Radial nerve palsy. *Hand Clin* 4:179-85, 1988
28. Riordan DC: Tendon transfers in hand surgery. *J Hand Surg* 8:748-753, 1983
29. Schreuders TAR, Stam HJ, Hovius SER: Training of muscle excursion after tendon transfer. *J Hand Ther* 9:243-245, 1996
30. Sundararaj GD, Mani K: Surgical reconstruction of the hand with triple nerve palsy. *J Bone Joint Surg* 66B:260-4, 1984
31. Tubiana R, Miller HW, Reed S: Restoration of wrist extension after paralysis. *Hand Clin* 5:53-67, 1989
32. Warren G: Tendon Transfers for Radial Nerve Palsy. pp. 241-249. In Conally WB (ed): *Atlas of Hand Surgery*. Churchill Livingstone, 1997
33. Weiss APC, Hastings H: Wrist arthrodesis for traumatic conditions: A study of plate and local bone graft application. *J Hand Surg* 20A:50-56, 1995
34. Zachary RB: Tendon transplantation for radial paralysis. *Br J Surg* 23:358-364, 1946
35. Zancolli E: Surgery for the quadruplegic hand with active strong wrist extension preserved. A study of 97 cases. *Clin Orthop* 112:101-113, 1975

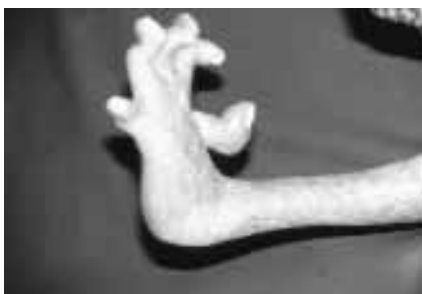## Management of Miscellaneous Conditions in the Paralysed Hand

• M. VIRMOND  
H. DA ROSA PEREIRA

### INTRODUCTION

Hand surgery in nerve injury aims to restore function and cosmesis. Undoubtedly, tendon transfers and nerve decompression are the most common and needed operations in a surgical program aiming to physically rehabilitate neuropathic hands. However, surgeons dealing with leprosy patients will be faced with a variety of conditions: from a preserved hand with just mobile clawed ulnar fingers to a grossly deformed and destroyed hand (Fig. 9-1). The first condition is easily resolved with a simple tendon transfer. The latter could lead surgeons to a feeling of frustration and hopelessness in the sense that nothing can be done for such conditions. The aim of this chapter is to present some suggestions for selected techniques devised to correct and/or ameliorate some of these deformities not covered elsewhere in the textbook.

The leading philosophy is that, in many



**FIGURE 9-1** A grossly deformed hand. Unattended acute reactions may lead to severe deformations in the hand due to myositis, arthritis, joint contractures and scarring of skin wounds after necrotizing erythema nodosum.

instances, something can be done to improve the function of a badly deformed hand. Sometimes, a minor arthrodesis may result in a dramatic improvement in the daily life activities of a patient. However, it is most important before the operation, to carefully examine the hand, select an adequate intervention and fully discuss with the patient the possible results and operate only if the patient understands and agrees with the procedure.

The cosmetic appearance of the hand should not be neglected. Some surgeons consider these aspects as non-priority. However, one should remember that this decision should be given to the patient and not to the surgeon. It is intriguing to realize that some patients with longstanding ulnar paralysis are, by far, more concerned with wasting of the first web than with clawed fingers. They can often overcome the functional disadvantage with a variety of tricks but hardly can conceal a depressed web other than keeping the hand in the pocket. This attitude may lead to socially embarrassing situations.

### Contractures

Collateral ligaments, volar plate and joint capsules are structures to provide a stable link that allows efficient transmission of muscular force across the joints. These structures are maintained in their optimal flexibility and length by a normal joint. Muscle weakness or palsy interferes greatly with this intricate mechanism and the final result can be soft tissues and joint contractures. Longstanding muscle palsy is com-

mon in leprosy and thus joint contractures are also frequent if preventive measures are not timely. The sensory loss may lead to wounds that may become infected, compromising deep structures and resulting in tendon, bone and joint involvement. There may be loss of insertion of the tendons, bone sequestra and joint destruction.

The end result may be shortened fingers with contracted joints that interfere with normal function of the hand. A careful analysis of each hand may lead to the indication of surgical techniques that can improve the function. It is important to note that these cases are of long-standing contractures and not recent conditions as we commonly see after trauma. For this reason, possibilities for surgical correction are very limited. In many cases the surgical techniques are restricted to release skin contractures and arthrodesis in order to simply improve the position of the finger and thereby improve hand function.

### Distal interphalangeal joint contractures

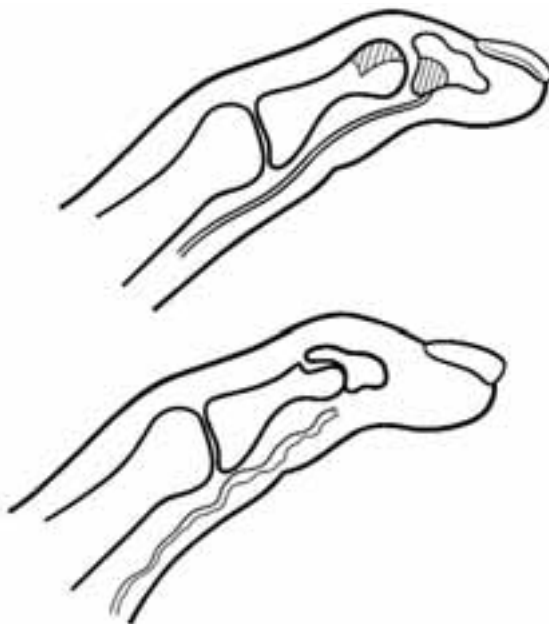
To the clawed fingers contractures of the distal interphalangeal joint (DIP) may cause additional difficulty for pinch and grasp. Arthrodesis of the DIP joint can improve the overall function of the hand (Fig. 9-2). Frequently in leprosy the amount of bone at the distal phalanx is not enough to allow adequate fusion. Therefore it is useful to shape the bone ends to increase the bony surface (Fig. 9-3).

**Operative technique:** After a wrist or finger anesthetic block, incise deeply and longitudinally in the dorsal aspect of the distal finger including the terminal slip of the extensor tendon. Preserve as much as possible the dorsal venous drainage. Expose the capsule and collateral ligaments and release these structures carefully with a #15 blade.

Fully expose both the articular facets and



**FIGURE 9-2** The contracted distal phalanx made grasping of objects difficult. A DIP arthrodesis has improved function of the hand.



**FIGURE 9-3** DIP arthrodesis with reshaping of the distal bone, which increased the surface contact between the remaining distal phalanx and the medial phalanx.

remove the cartilaginous tissue with a thin osteotome and shape the proximal end of the distal phalanx and the distal portion of the middle phalanx in order to obtain an angle of 15° to 20°. Carefully remove debris between the facets and firmly fix both phalanxes with two Kirschner wires keeping the bones compressed as the wires are inserted (Fig. 9-4).

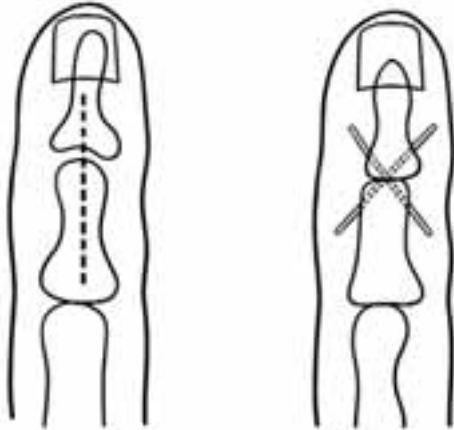
Proceed with hemostasis and close the



wound with separate sutures of nylon 6/0. Immobilize with a plaster cast, which should be removed after 4 weeks.

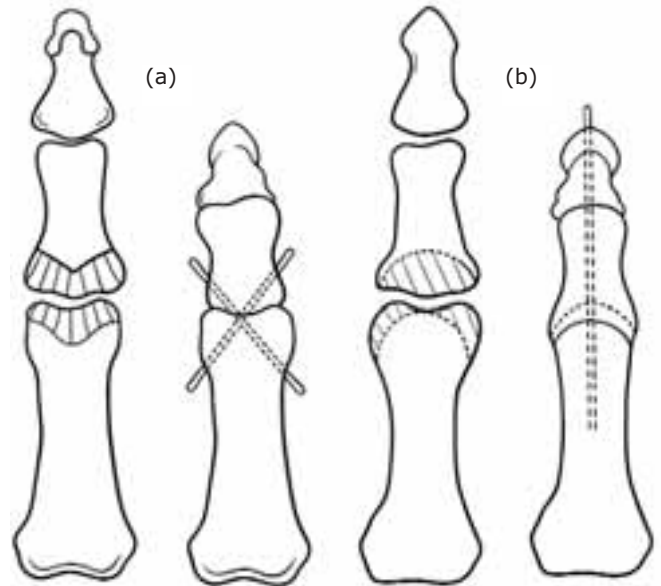
### Proximal interphalangeal joint contractures

Contractures of the PIP joint are the most com-



**FIGURE 9-4** DIP arthrodesis. If the distal phalanx has enough bone, a conventional two K-wire arthrodesis can be done. Bone parts should be kept under compression while inserting the wires.

mon in hands of patients affected by leprosy. Contractures following recent paralysis should be treated with adequate physical therapy and/or surgical release of ligaments and volar plate by conventional techniques.<sup>19</sup> It is also advisable to consider the use of distractors, which has the advantage of allowing progressive and slow lengthening of soft tissues and collateral vessels.<sup>14</sup> However, this section will describe only treatment for longstanding contractures in which most of the conventional techniques are not successful. The surgical technique is similar as that for DIP arthrodesis (Fig. 9-5a,b). Besides these standard techniques, others can be advocated depending on the experience of the surgeon.<sup>1,12,16</sup> However, it is important to stress that, due to the accompanying severe contracture of skin, the amount of bone to be removed to allow good positioning may severely shorten the finger. In order to avoid this problem it is advisable prior to



**FIGURE 9-5a,b** PIP arthrodesis. (A) Chevron-type technique. (B) Cup and cone type arthrodesis allows adequate bone-to-bone contact and, most of all, makes the final adjustment of the phalanx position before the fixation with K-wire easier.

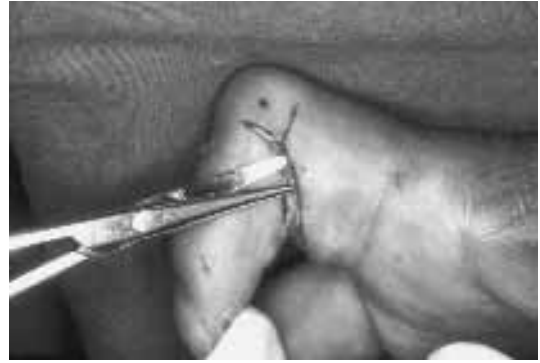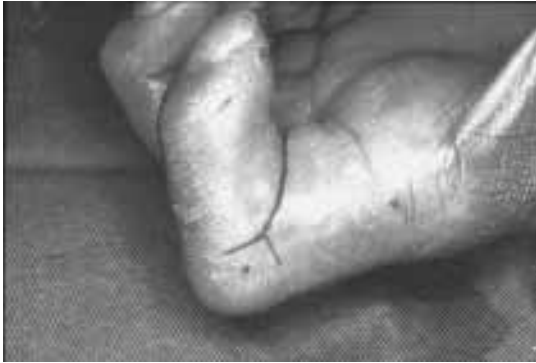arthrodesis to release soft tissue contractures. A good technique for this purpose is the one proposed by Fritschi described below (Fig. 9-6, 9-7 and 9-8).

### Operative technique

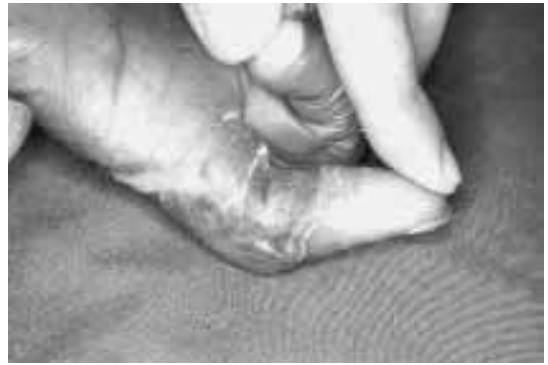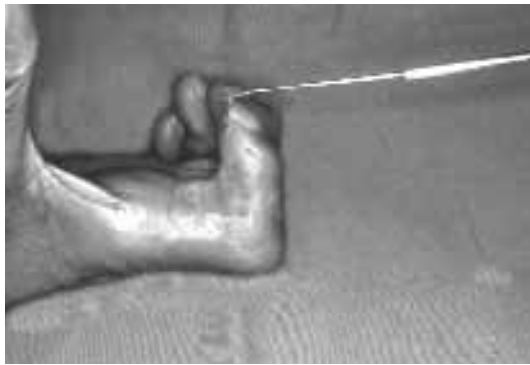With a marking pencil outline a "Y" in each side of the joint which legs should join at the volar aspect of the joint. Incise along the drawing and make sure to keep the knife superficial – do not incise deeply, that is, beyond the dermis.

With fine scissors, undermine distally and proximally to the volar incision in order to draw areolar tissue to your surgical wound to cover the flexor tendon sheath, which will be exposed along with the progressive release of the joint and skin contracture.

Through the "V" portion of the "Y" incision, release the collateral ligament on both sides and the volar synovial pouch if it is obliterated.



**FIGURE 9-6** Fritschi's Y technique for skin and joint contracture. **a.** The "Y" is marked in the skin. The dot is intended as the fulcrum of the PIP joint. **b.** A careful superficial undermining is made both distally and proximally releasing contracted tissue and drawing areolar tissue to the open surgical wound.



**FIGURE 9-7** Fritschi's Y technique for skin and joint contracture. **a.** Pre-operative view with passive extension. **b.** Passive opening of the finger after surgery.



**FIGURE 9-8** Fritschi's Y technique for skin and joint contracture. **a.** Pre-operative view – active extension. **b.** Postoperative view – active extension.

As the release proceeds, notice that the surgical wound becomes wider. This is actually the gain in the passive range of movement of the PIP and it also shows the amount of skin necessary to cover the gap.

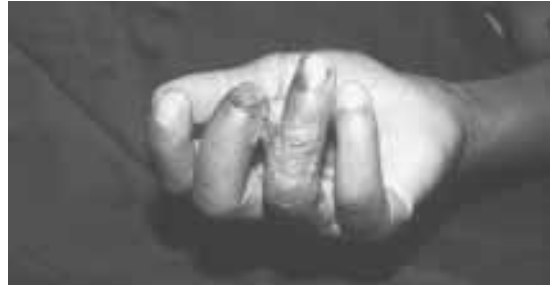Harvest the needed amount of full-thickness skin graft and apply the graft over the surgical wound at the volar aspect of the joint. Before suturing the skin graft, insert at least one Kirschner wire to effectively immobilize the joint while, in the post-operative period, the skin graft takes and retracts.

Full-thickness skin grafts are preferable to repair the surgical gap due to the smaller degree of contraction in the post-operative period and because the quality of skin is better than in split-skin grafts. For all skin grafting techniques in this chapter it is recommended to harvest the donor skin from the antecubital space. In this space it is possible to harvest a reasonably amount of good quality hairless skin yet allowing easy closure of the transverse defect. If there is need for a larger piece of skin, it must be harvested at the groin.

According to the severity of the contracture the surgical wound may prove to be inadequate for a skin graft. This happens when, after release, the joint becomes exposed and the amount of areolar tissue is not enough to provide a recipient bed for the graft. In this case a flap may be used. A cross finger flap is a satisfactory choice to cover the remaining defect (Fig. 9-9) and it is easy and safe to perform. The inconvenience is that the fingers must be kept immobilized for 2 weeks and there is need for a second operation to release the pedicle.

### Metacarpophalangeal joint contractures

Flexion contracture of the MP joints is seldom seen in leprosy. However, extension contractures may occur as a result of a severe and inadequately treated "reactional" hand. This is a challenging condition to the surgeon. The dorsal skin may become shiny, immobile and



**FIGURE 9-9** Fritschi's Y technique for skin and joint contracture. A cross-finger flap can be used to improve coverage of the surgical wound.

fragile with poor blood supply. The capsule is contracted as well as the extensor hood, which may additionally be laterally dislocated. The joint itself may be affected e.g. exostosis and compromise of the cartilaginous facets. Extension contractures of MP joints are highly dysfunctional since they prevent adequate grasping or pinching. If possible, release of skin and joint contracture should be undertaken to allow the distal joints to perform basic tasks of daily life activities.

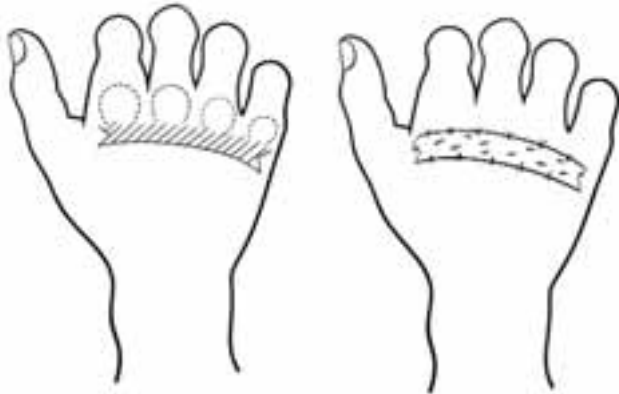
### Operative technique

Place a transverse incision at least 3 cm proximal to the knuckle of the MP joints. It is of utmost importance to preserve dorsal veins at this stage. Undermine carefully the distal border of the incision to expose the MP joint area. If necessary, complete the incision with an extended "V" in both radial and ulnar sides (Fig. 9-10).

Expose and incise the two collateral ligaments and release the volar plate pouch with a small curved elevator. If exostoses are present, remove them with a fine nibbler.

At this stage, sufficient flexion should be obtained (50°-60°). Immobilize the affected joints with a longitudinal Kirschner wire taking care to maintain the finger properly aligned on its longitudinal axis.

Apply a full-thickness graft to repair the widened dorsal surgical wound. Immobilize



**FIGURE 9-10** Technique for dorsal release. A skin graft is applied to cover the defect.

the hand with a volar plaster cast including a padded dressing in the dorsum to ensure mild compression over the skin graft.

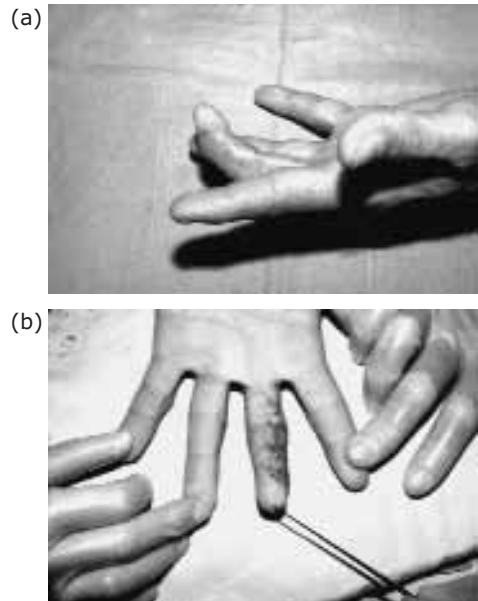
**Soft tissue contractures**

Soft tissue contractures can be severely limiting to the function of the hand in leprosy. These contractures can be treated by physical therapy. For finger contractures the choice treatment includes exercises, splinting and serial cylinder casting. The latter is particularly efficient to restore adequate range of movement (ROM), but requires a careful follow-up and complete patient compliance. However, in some longstanding contractures, surgical intervention is necessary.

Release of soft tissue contractures in the fingers can be treated by skin graft or pedicle flap and the various techniques have been previously discussed in this chapter. Skin contractures in others sites of the hand need a careful analysis and the surgical technique should be decided on each specific situation. Again, skin grafts are, in most cases, the preferable option after release of the contracture. Z-plasty is a good precious technique that should be considered whenever applicable (Fig.9-11a and b).

**Intrinsic plus deformity (Swan-neck)**

In this deformity there is hyper-extension of the PIP and some degree of flexion in the ter-



**FIGURE 9-11** Z-plasty for skin contracture release. **a.** pre-operative view. **b.** a multiple Z was done along the axis of the scarred tissue.

minal joint (Fig. 9-12).<sup>13,15</sup> Most frequently, the One cause for intrinsic plus deformity in leprosy is contracture of the intrinsic muscles due to myositis as a result of reactions. The degree of severity depends on the time elapsed without adequate treatment and the severity of the reaction. Sometimes it is possible to see “acute” swan neck during an acute reactional state due to spasm of the intrinsic muscles (lumbrical and interosseous).<sup>5</sup> On the other hand, following a severe reaction without proper treatment or with delayed attention (drugs, splinting and physical therapy), the fine structures of the dorsal expansion become contracted and fibrotic, the skin contracts and the joint develops stiffness. Contracture of the oblique retinacular ligament is also a common feature of longstanding intrinsic plus deformity. Another common cause for “intrinsic plus” deformity is the removal of the flexor sublimis for tendon transfer in the hand (sublimis-minus).<sup>2,13</sup> A



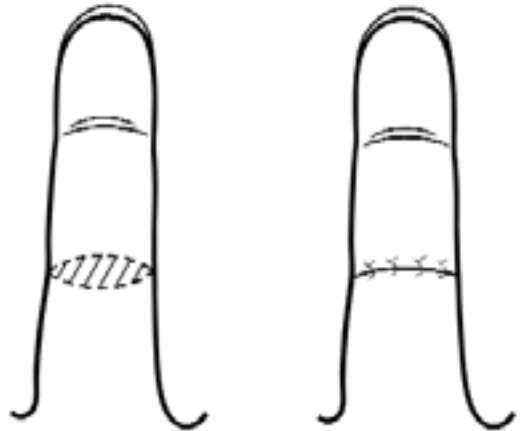
**FIGURE 9-12** Swan-neck deformity. Note the hyperextension of the PIP and flexion of the DIP joint.

third cause is following intrinsic replacement surgery in an excessively mobile hand. An alternative in these hands is to employ the Lasso technique of Zancolli<sup>19</sup>, which corrects the clawed fingers without direct attachment of tendon slips in the extensor apparatus, thereby greatly reducing the risk of swan-neck deformity.

In mild deformities where flexion of the PIP joint can be actively achieved and there is no gross contracture, there should be no need for surgical correction. If necessary, a simple dermadesis (Fig. 9-13) may be sufficient to reverse the deformity though the correction proves to be not longstanding in my experience.

### Correction of Swan-neck deformity

The traditional technique for correction of "intrinsic plus" was described by Littler.<sup>10</sup> He suggests excision of a triangle of the oblique fibers in the dorsal expansion at the level of the middle or proximal third of the proximal phalanx. This technique is indicated in those cases in which the flexion of the PIP is restrained (Fig. 9-14). Another possibility is an incision of the lateral band at the proximal third leaving the band attached to the distal end. The band is then rerouted volarly to the ligament of Cleland and sutured to the flexor tendon sheath. In this way, the tension on the band allows extension of the DIP and prevents hyperextension of the PIP (Fig. 9-15).



**FIGURE 9-13** Dermadesis at PIP joint. An elliptic skin resection is made. The incision should be placed in order that the final suture lies in the natural PIP volar crease.

Fritschi<sup>3,8</sup> recommended a longitudinal incision along the expansion, which divides the oblique fibers and continues distally dividing the lateral band (Fig. 9-16). After release of the hyperextension of the PIP, the lateral band is reattached to the oblique fiber in the new position.

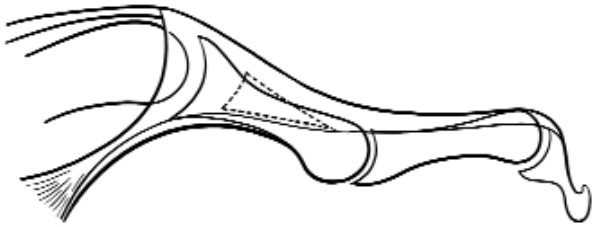
Tenodesis of the flexor sublimis is an alternative that may give good results.<sup>7</sup> A slip of the flexor sublimis is cut in the proximal end of the proximal phalanx. The slip is passed through a small opening made in the distal portion of the A2 pulley and sutured to itself (Fig. 9-17). This method prevents the hyperextension of the PIP.

In severe cases of intrinsic-plus deformity it may be necessary to release skin contracture with Z-plasty and reconstruction with flaps. The dorsal expansion should be released as well as the lateral band. Finally, the PIP is arthrodesed in slight flexion. This is almost a salvage procedure that should be fully discussed with the patient before operation.

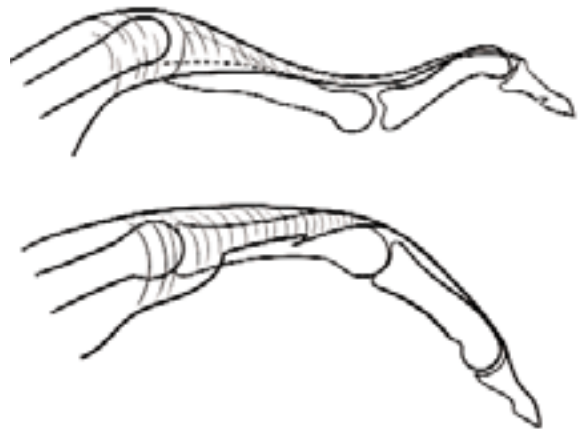
### Boutonniere deformity

The extensor apparatus of the finger is a fine

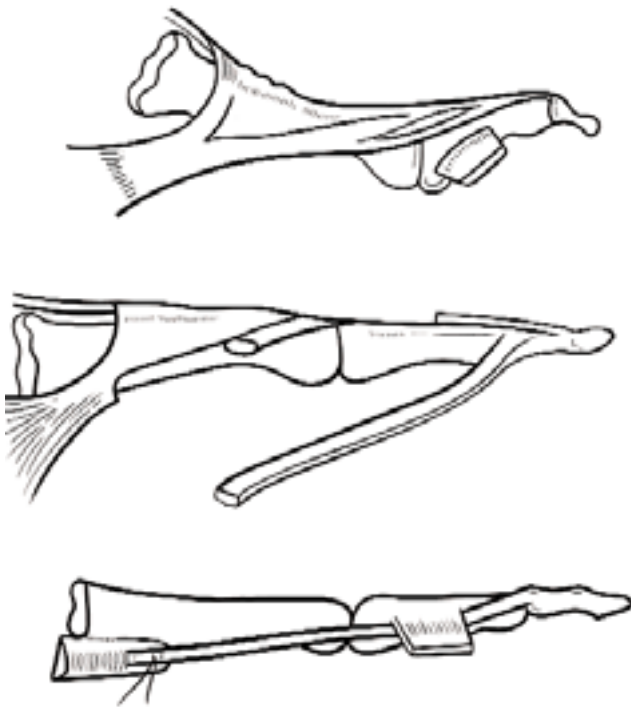




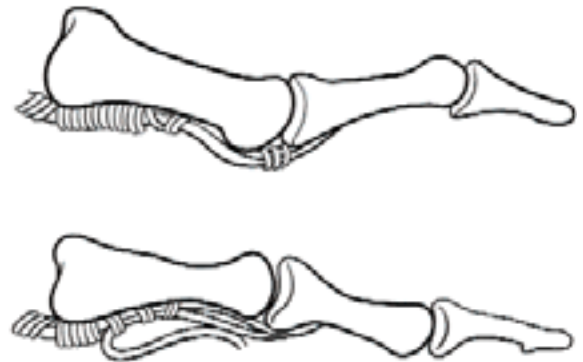
**FIGURE 9-14** Littler's technique for Swan-neck correction. Using a triangular resection, the lateral band and oblique fibers of the dorsal aponeurosis are removed at the level of the middle or proximal third of the proximal phalanx.



**FIGURE 9-16** Swan-neck correction. Fritschi's modification of Littler's operation. The lateral band is sectioned. The PIP joint is flexed at 60° and the lateral band is re-sutured to the cut oblique fibers in the new position.



**FIGURE 9-15** Swan-neck correction by rerouting of the lateral band. The lateral band is detached at the proximal end and reattached to the flexor sheath after having been threaded volarly through Cleland's ligament, which prevents its dorsal excursion. The new route of the lateral band avoids hyperextension of the PIP joint while still allowing extension of the DIP.



**FIGURE 9-17** Tenodesis for correction of Swan-neck deformity. A slip of the flexor sublimus is cut proximally to its insertion at the base of the medial phalanx. The slip is threaded through a small opening made in the distal part of A2 pulley and sutured to itself after flexing the PIP joint. During flexion of the fingers the slip becomes loose but as the finger attempts to extend, the slip becomes tight and prevents hyperextension of the joint beyond the adjusted angle of the PIP joint.

complex of bands, slips and ligaments that contributes to a smooth and coordinated movement of extension and flexion of the finger.

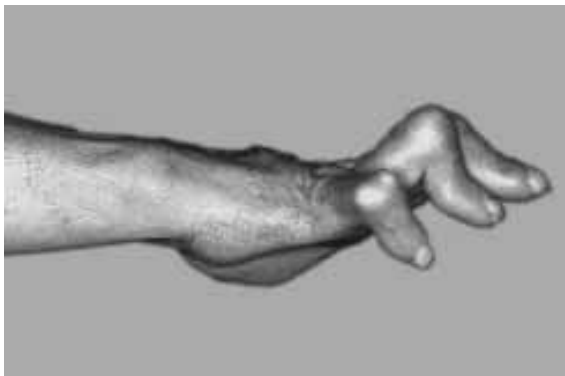Damage to any of its portions may induce severe imbalance in both movements.

Disruption of the integrity of the extensor apparatus at the level of the middle joint may result in a boutonniere (button-hole) deformity. Actually division of the central slip of the extensor tendon alone is not enough for a bou-

tonniere deformity to occur. Also required is some involvement of the retinacular component of the dorsal apparatus.<sup>3</sup> This concept should be borne in mind to understand the pathogenesis of the deformity in leprosy.

The most common cause of boutonniere in ulnar palsy is the chronic abnormal position of the various structures of the extensor apparatus as a result of longstanding clawed fingers. The lateral bands migrate volarly resulting in contracture of the oblique retinacular ligament of Landsmeer. Sometimes this is referred to as "hooding deformity". It is important to note that clawed fingers greatly expose the often insensitive skin of the knuckles of the finger to repetitive trauma which may lead to wounds that may become infected and destroy the tendon apparatus on the dorsum of the middle joint. In other instances, the granulomatous component of a reaction can also compromise these fine structures. As a result, the boutonniere (hooding) deformity in leprosy is basically characterized by volar displacement of the lateral bands and contracture of the oblique retinacular ligament. The final picture is flexion of the PIP joint with mild extension of the DIP joint (Fig. 9-18).

To assess contracture of the oblique retinacular ligament the PIP is passively extended and then the distal phalanx is flexed. In the pres-



**FIGURE 9-18** Severe Boutonniere deformity.

ence of a boutonniere deformity there will be marked resistance to flexion of the DIP. With the PIP flexed it will be easier to flex the DIP joint (Fig. 9-19). Before considering surgically correcting a recent boutonniere, the patient should be asked to actively flex the DIP while extending the PIP with the other hand.

Surgical treatment of boutonniere in leprosy depends on the severity of the case. Different from fresh or traumatic boutonniere<sup>9</sup> the deformity in leprosy is commonly chronic with intense residual fibrosis and disorganization of the fine extensor apparatus structures – therefore, results are often unrewarding.

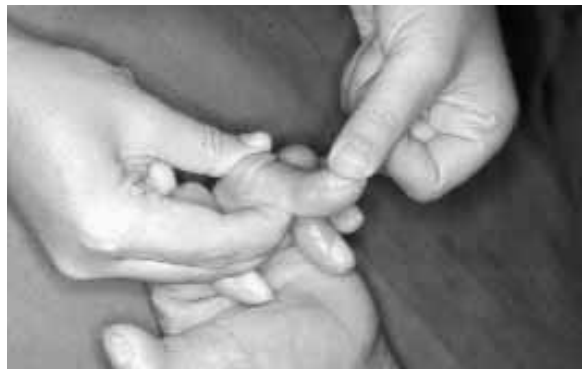### Central Slip Advancement

In mild cases with rupture of the central slip an advancement of this structure can be performed.

### Operative technique

After a wrist, or even a finger block, make an incision on the dorsal aspect of the middle and proximal phalanx, fully exposing the region of the PIP.

Identify and remove the fibrotic callus on the central slip over the PIP. Sometimes it is difficult to recognize the difference between the



**FIGURE 9-19** Restrained flexion of the DIP joint is a characteristic of advanced Boutonniere. The test should be made before any attempt for physical therapy or surgery treatment.

tendon (central slip) and the fibrotic tissue. The former has a shine pearl aspect and the latter is light gray and transparent.

While removing the fibrotic callus, leave a cuff of tissue attachment to the base of the middle phalanx, which will help later in the reattachment of the advanced central slip to the dorsum of the medial phalanx.

In order to advance the extensor tendon, make two lateral and parallel incisions in the central slip towards the MP joint. While incising, be careful not to harm the underlying tissues to prevent adhesion of the tendon to the bone phalanx.

Suture the lengthened central slip to the attachment in the base of the middle phalanx. If no attachment is present, fix the central slip to the periosteum of the middle phalanx. The finger should assume slightly the shape of a swan neck. Tenotomy of the distal tendon to release retinacular contracture is advocated by some authors and contraindicated by others.

A Kirschner wire may be inserted in the PIP to guarantee adequate immobilization of the joint. Immobilize the hand for 4 weeks and then start gentle physical therapy.

### Dorsal Fixation of Lateral Bands

In cases with a marked relaxation of the extensor structures but still with no fixed contractures, it is possible to reconstruct the extensor apparatus.

### Operative technique

Incise the skin in the dorsal aspect of the middle and proximal phalanx exposing the tendinous structures, including the displaced lateral bands.

If the central slip is loose it may be required to excise a few millimeters of the slip and reattach it distally in order to shorten the central slip.

The displaced lateral bands should be freed of attachments, including its connections with the oblique retinacular ligament. Thus, the bands are brought to their original physiological position and sutured to the central slip with 2 fine 6-0 nylon sutures (Fig. 9-20). If necessary, the triangular ligament should also be reconstructed.

Immobilize the PIP joint with a Kirschner wire for 4 weeks.

In severe long-standing boutonniere deformities with marked contractures and joint stiffness a PIP arthrodesis of the most contracted fingers can be performed using one of the standard techniques described elsewhere in this chapter.

A mild anterior displacement of the lateral bands without severe contracture of the oblique retinacular ligament is a common finding in hands with clawed finger. This displacement results in a poor extension of the distal phalanx after intrinsic replacement. It is important while correcting clawed finger by any of the flexor to extensor tendon transfer techniques to restore the lateral bands to their original position while performing the insertion of



**FIGURE 9-20** Mild Boutonniere. The central callus should be removed. The freed central slip is advanced and sutured in the base of the middle phalanx.

the transferred slip into the lateral bands.

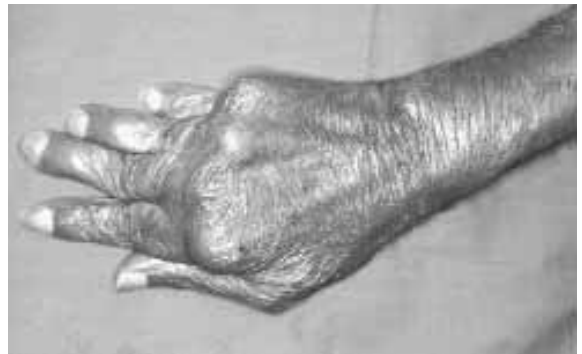Fritschi<sup>8</sup> has devised a simple procedure that aims to correct this problem (Fig. 9-21a) and consists in an additional step to the Stiles-Bunnel sublimis transfer, which can apply to any of the techniques involving insertion into the lateral bands. While suturing the tendon slip in each finger, one should pass the suturing needle through the central slip and then in the free border of the lateral band and finally in the tendon transfer slip (Fig. 9-21b). When the suture is concluded the lateral band will be brought dorsally to its original position allowing adequate extension of the finger. This is a simple procedure that should be kept in mind when performing intrinsic replacement for correcting clawed fingers with a mild hooding deformity.

### **Extensor Tendon Guttering**

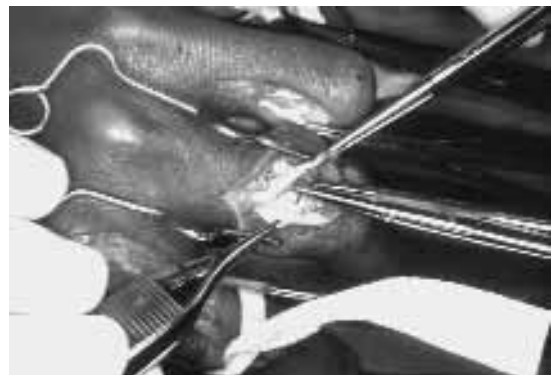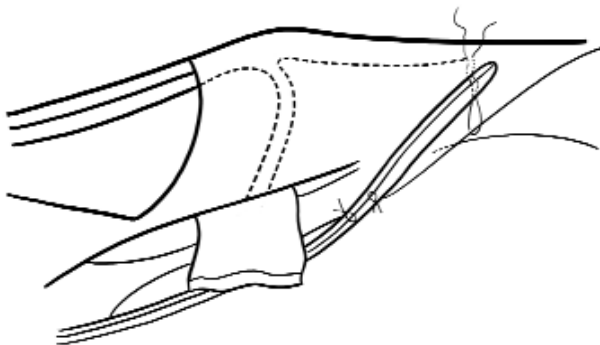
Guttering is the ulnarward subluxation of the extensor tendon of the fingers (Fig. 9-22). The extensor tendons lay in the gutter between the knuckles of two adjacent fingers. This is a common finding in hands with rheumatoid arthritis. In the normal hand fingers show more lateral mobility towards the ulnar than the radial side. The index finger normally tends to be ulnarly deviated at rest. Although common in

rheumatoid arthritis, guttering deformity in leprosy is seldom seen and also difficult to explain. It can occur due to spasm of the intrinsic muscles and thus there may be a connection with intrinsic-plus deformity. However, hypermobility of joints, looseness of the dorsal apparatus and flexion contracture of MP joints also seem to play an important role in the pathogenesis of this deformity.

As in rheumatoid arthritis, there are three degrees of ulnar deviation. When mild the patient can actively reduce the deformity. When more severe the deformity can only be passively reduced. Lastly, the guttering is not passively reducible.



**FIGURE 9-22** "Guttering" deformity of the fingers with marked ulnar deviation.



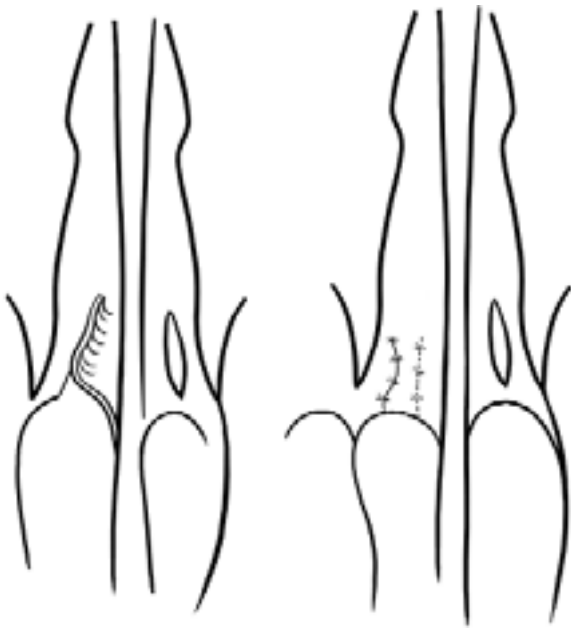
**FIGURE 9-21** Lateral band dorsal fixation: Fritschi's technique. In selected cases this procedure should be carried out during a Bunnell's flexor to extensor tendon transfer for claw hand correction. **a.** Drawing of the basic procedure proposed by Fritschi. **b.** The intra-operative photograph shows the lateral band being taken by the needle that has been previously passed through the central slip of the extensor tendon (dorsal). While fixing the suture the lateral band is moved dorsally.

### Guttering Repair

For mild guttering Boyes recommends a flap of the dorsal expansion aponeurosis at the ulnar side of the extensor tendon that is sutured to the same aponeurosis in the radial side.<sup>4</sup> This flap acts as a pulley that brings the extensor tendon back to its original position on the crest of the knuckle of the affected finger. This same procedure is advocated by Fritschi with a minor modification consisting of placing an individual longitudinal incision for each affected finger to prevent damage to the dorsal veins.<sup>8</sup> Milford proposes a different approach that is easy to perform and results are not disappointing for mild guttering (Fig. 9-23).<sup>12</sup>

#### Operative technique

Expose each affected extensor tendon through a single incision on the ulnar side of the MP joint of each finger and not a single transverse



**FIGURE 9-23** Technique for correction of mild guttering. (Left) An incision is made on the radial side of the hood and a small relaxing incision in the ulnar side. (Right) The relaxing incision permits repositioning of the extensor tendon. The radial side incision is then closed after its edges are overlapped.

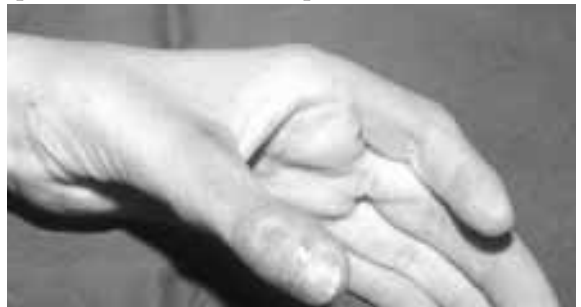incision. After incision, expose the extensor tendon and the extensor hood at the knuckle. Make a short and longitudinal incision at the radial side of the extensor hood and a relaxing incision in the ulnar side of the hood. Place the extensor tendon in its normal position on the crest of the knuckle and suture the radial incision with fine separate sutures of nylon 6/0. If necessary, overlap the edges of the radial side incision to better position the central tendon. The incision on the ulnar side should not be sutured.

Suture the skin incisions and apply a mild compressive dressing. The hand should be immobilized in a plaster cast with mild extension of the metacarpophalangeal joints.

### Correction of muscular wasting in the first web

Atrophy of the first dorsal interosseous and adductor pollicis muscles is common following ulnar nerve paralysis resulting in a shallow aspect of the first web. In many countries this deformity is considered as one of the most stigmatizing signs of leprosy (Fig. 9-24).

Many techniques have been described to restore the bulky contour of the first web space to correct the cosmetic problem. Dermal grafts, silicon rubber and fat graft have been used with results ranging from good to disappointing. These techniques have their own advantages and disadvantages. Dermal grafts are problematic due to complications such as der-



**FIGURE 9-24** Wasting of the first web is quite noticeable and recognized as a sign of leprosy.



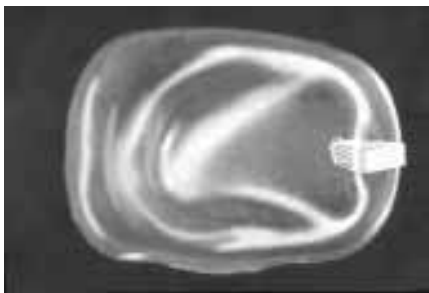
mal cysts and the need for a reasonable amount of dermis to adequately fill the web space. Fat grafts are likely to lose up to one half of their original bulk. Recently, it has been suggested to use fat graft harvested by liposuction that is injected in the web pocket. There are no reported data on its results although the idea seems interesting. The use of carvable silicon rubber implants has been recommended and results are promising although the consistency of the implant is harder than the normal muscle.<sup>6</sup> The encapsulated silicone gel implants are more appropriate for procedures such as testicular implants.<sup>18</sup>

### Silicone Implant Insertion

A special encapsulated silicone gel implant for the first web was designed by Dr. Adenaur M. Goes (unpublished data) from Brazil. The implant is commercially available in four sizes at an affordable price (Fig. 9-25).

#### Operative technique

Select the implant according to the size of the hand. Manufacturers provide a set of 4 samples for this purpose (7, 9, 11 and 13), #13 being the largest one. Implant # 9 is the most suitable for the average hand (manufacturer: SILIMED Inc.



**FIGURE 9-25** Encapsulated silicone gel implant.

Rua Figueiredo Rocha 374. Rio de Janeiro Brazil.

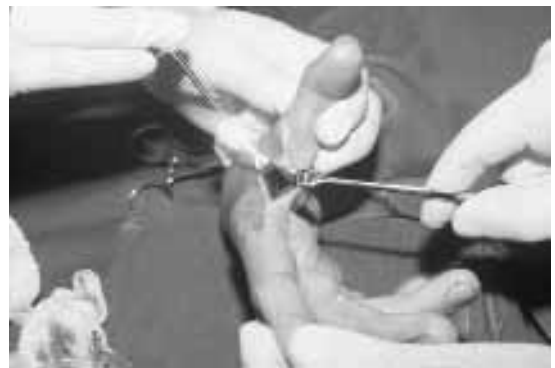Use local anesthesia. It is advisable to infiltrate the superficial branch of the radial nerve distal to the wrist. The procedure does not

require use of a tourniquet and, a bloodless field is not necessary nor desirable, since perfect hemostasis is mandatory before closing the incision.

Incise along the first web no longer than 4 cm following the interdigital line and close to the index finger (Fig 9-26).

Create a pocket through this incision by blunt dissection between the paralyzed fibers of the adductor pollicis and first dorsal interosseous muscles. The size of the pocket should be enough to receive the implant (Fig. 9-26 b). Proceed carefully while dissecting to prevent damage to vessel, particularly in the deep portion of the pocket and obtain hemostasis.

Rinse the implant and the pocket with saline. Introduce the implant deeply into the pocket. If necessary, introduce a guiding suture (nylon 3-0) from proximal to distal, pass the suture through the loop included in the implant and back to the proximal dorsal skin.



**FIGURE 9-26** Silicone gel implant. A short incision is made in the first web along the line separating the dorsal and palmar skin. After careful tissue dissection between the fibres of the first dorsal interosseous and the adductor pollicis, the pocket is ready to receive the implant.

This is seldom necessary.

Close the fascia with 2 to 3 sutures of nylon 6/0 and then suture the skin with 3 or 4 separated fine nylon stitches.

Apply a bulky padded dressing or a plaster cast to immobilize the first web for 2 weeks. Allow free movement after that period.

The main advantages of the encapsulated gel implant are the muscle-like consistency and readiness of the implant. There is no need for shaping. In a 12 month follow-up in a group of 14 cases results are good and no complications have been reported.<sup>6</sup> Patient's satisfaction is high (Fig. 9-27 a,b and Fig. 9-28).

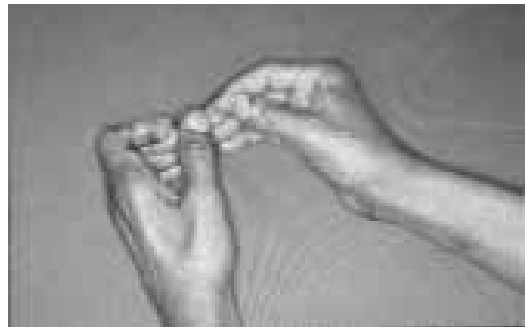**Conclusion**

The techniques described in this chapter should serve as a complement to the other chapters on hand surgery in this book to give the reconstructive surgeon a broad range of skills to re-enable the paralyzed hand. With the dramatic reduction of prevalence of leprosy worldwide as a result of MDT implementation, the number of disabled patients appears to be reducing. Many of the procedures described in this chapter apply to patients with nerve injury who present late with established secondary deformities. In developing countries these types of patients will continue to be seen, especially among patients affected by leprosy. As such these surgical skills will be needed for years to come. Fortunately, most of the procedures discussed in this chapter are related to a very limited number of patients. Patients in

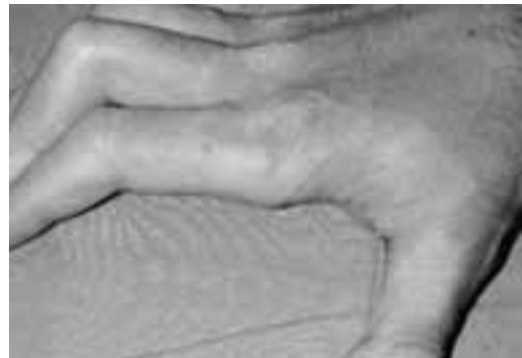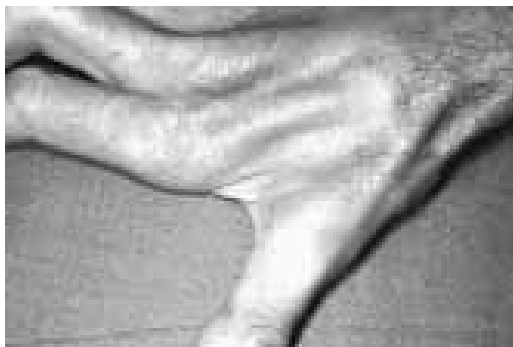need for these secondary techniques are those that could not have an early diagnosis, an adequate treatment, a careful follow-up and effective health education. Certainly we must be striving to prevent patients from developing such late severe disabilities. However when these patients present, surgeons should be prepared to cope with these situations in order to assist patients in improving the functional condition of their hands, aiming to restore dignity and self-respect to their life. It is to this purpose that this chapter has been included, to assist even those with severely disabled hands to regain some of the independence they had lost through their hand deformity.

**BIBLIOGRAPHIC REFERENCES**

1. Ayres JR, Goldstrohm GL, Miller GJ, Dell PC:



**FIGURE 9-28** Silicone gel implant. The left hand has not been operated. Compare with the right hand in which the implant was included.



**FIGURE 9.27** Silicone gel implant. **a.** preoperative view. **b.** postoperative view.

- Proximal interphalangeal joint arthrodesis with the Herbert screw. *J Hand Surg*; 13A: 600-603, 1988
2. Beine A: Prevention of post-operative "sublimis-minus" deformity by modified surgical procedure at the donor finger. *Ind J Lepr* 69: 33-41, 1997
  3. Boyer MI, Gelberman RH: Operative correction of swan-neck and boutonniere deformities in the rheumatoid hand. *J Am Acad Orthop Surg* 7:92-100, 1999
  4. Bunnell S: *Surgery of the Hand*, 5<sup>th</sup> ed. J.B. Lippincott, Philadelphia, 1970
  5. Carayon A, Bourrel P, Languillon J: Contracture of the intrinsic muscles. Pp. 139-147. In: *Surgery in Leprosy*. Paris, Masson et Cie. Éditeurs, 1964
  6. Duerksen F, Virmond M: Carvable silicon rubber implant for atrophy of the first web in the hand. *Lepr Rev* 61: 267-272, 1990
  7. Duerksen F, Virmond M: Cirurgia reparadora e reabilitação em Hanseníase. TALM ILEP, Bauru, 1997
  8. Fritschi EP: *Reconstructive Surgery in Leprosy*. John Wright & Sons Ltd., Bristol, 1971
  9. Le Belle Y, Loy S, Touam C, Alnot JY, Masmejean E: Traitement chirurgical de la déformation en boutonnière des doigts longs. Etude d'une série rétrospective de 47 patients. *Chir Main* 20:362-7, 2001
  10. Littler JW: Restoration of the oblique retinacular ligament for correcting hyperextension deformity of the proximal interphalangeal joints. Pp. 39-42. In *La Main rhumatoïde*. Groupe d'Etude de la Main Expansion Scientifique Français, Paris, 1968
  11. McClinn JT, Smith RA, Bougumill GP: Arthrodesis of small joints of the hand: A rapid and effective technique. *J Hand Surg* 13A: 595-599, 1988
  12. Milford L: The Hand. Pp. 331-333. In Edmonson AS, Crewshaw AH (eds): *Campbell's Operative Orthopaedics*, 6<sup>th</sup> ed. C.V. Mosby Co. St. Louis, 1980
  13. Palande DD: Surgical correction of intrinsic minus fingers. *Ind J Lepr* 58:537-542, 1986.
  14. Salafia A, Chauahn G: Joshi external stabilizing system (JESS) in proximal interphalangeal joint (PIP) contractures in leprosy. *Ind J Lepr* 69: 331-339, 1997
  15. Smrcka V, Dylevski I: Treatment of congenital swan neck deformity with dynamic tenodesis of proximal interphalangeal joint. *J Hand Surg* 26B:165-7, 2001
  16. Stern PJ, Gates NR, Jones TB: Tension band arthrodesis of small joints in the hand. *J Hand Surg* 18 A: 194-197, 1993
  17. Watson HK, Turkeltaub SH: Stiff Joints. Pp. 537-552. In Green DG (ed): *Green's Operative Hand Surgery*, 2nd edition. Churchill Livingstone, Melbourne, 1988
  18. Zacharia AG, Gelber RR: Silastic implant of the first dorsal interosseous space (correspondence). *Int J Lepr*, 53: 643-4, 1985
  19. Zancolli EA: *Structural and Dynamic Bases of Hand Surgery*. The C.V. Mosby Co. St. Louis, 1974

## Restoration of Function in a Mitten Hand

• G. MALAVIYA  
B. RICHARDS

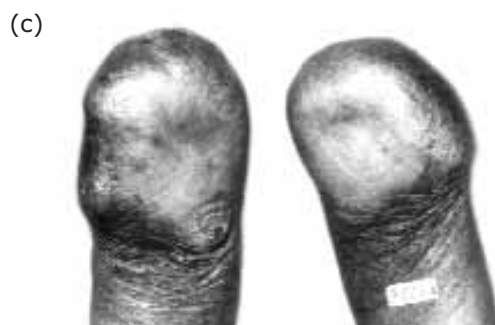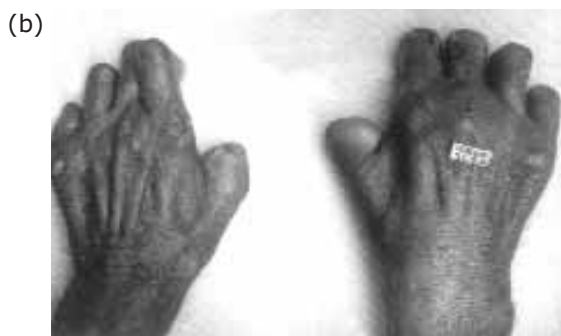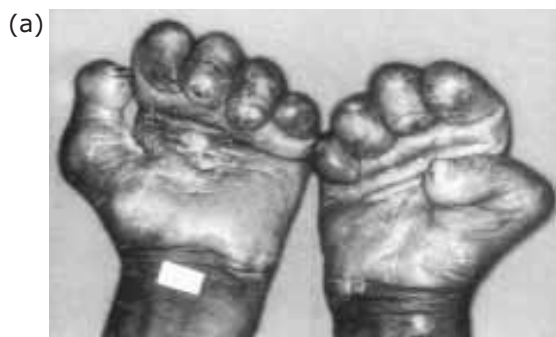### INTRODUCTION

A mitten is a glove to keep the hand warm. All the fingers are in one compartment and the thumb remains as a separate digit. Some persons affected by leprosy with a combined ulnar and median nerve palsy, have little ability or awareness to protect their digits from wounds and work strain causing soft tissue and bone infections that over several years may lead to the loss of digit length. They present with a shortened thumb, maybe down to the metacarpophalangeal (MCP) joint level and similar loss of the digits to the MCP joints. This is the so called "mitten hand" (Fig. 10-1 a-c). The process of ulceration with resultant deep infec-

tion that may lead to this digit attrition are inexorable and somewhat inevitable in those who have little concept of health education and do not understand why their fingers are becoming injured and infected. There is also often the absolute need to continue to use the injured hand for personal survival in the labour market. Our inability to restore sensation means that the individual who fails to comprehend the health education message of safety measures in work and cooking will only go on to destroy any surgical procedure performed to restore digit length and function.

Thus there is an imperative for the surgeon or health care worker to notice this 'self destructive behavior' at the early stage of digit loss and to invest the time to help the patient understand the aetiology of the problem and find alternative work, if possible, and advise on lifestyle changes. The surgeon should also spend time on preventative health education.

Many persons affected by leprosy have had sensory impairment with marked deformity for many years. Often these persons having few years left to their lives, have adjusted and



**FIGURE 10-1 a-c** Mitten hand.

are not very keen to have surgery. As long as some opposition of thumb and fingers is present, they can adapt to the basic functions of grasp, pinch and hook grip. They are often satisfied with being able to perform their activities of daily living and are able to care for themselves independently. Sometimes they do feel their incapacities and request surgical intervention for improvement of hand function.

### PREOPERATIVE EVALUATION OF HAND

Before contemplating any surgery, careful evaluation of both hands is essential. The greatest functional need is some form of pinch grip or pincer action for which at least two digits are necessary, hopefully in opposition to each other, i.e. a thumb and one finger. The mitten hand will have had multiple episodes of web and tendon sheath infection and will have dry calloused skin, both rendering the hand stiff. Assess remaining digit length, and mobility of the MCP and carpo-metacarpal (CMC) joints as any salvaged function requires mobility. Digits on the ulnar border of the hand may be more mobile due to the anatomical mobility of the 4th and 5th CMC joints for opposition. This makes excision of the 2nd and or 3rd metacarpals a good option to open a web space between any remaining thumb length and a mobile ulnar ray. There may also be fixed flex-

ion deformities of any remaining finger PIP joints in which an arthrodesis in a position of function may be useful (index 30, middle 40, ring 50 and little 60 degrees of flexion). Thorough evaluation of the needs, psychology and attitude, of the person is also important.

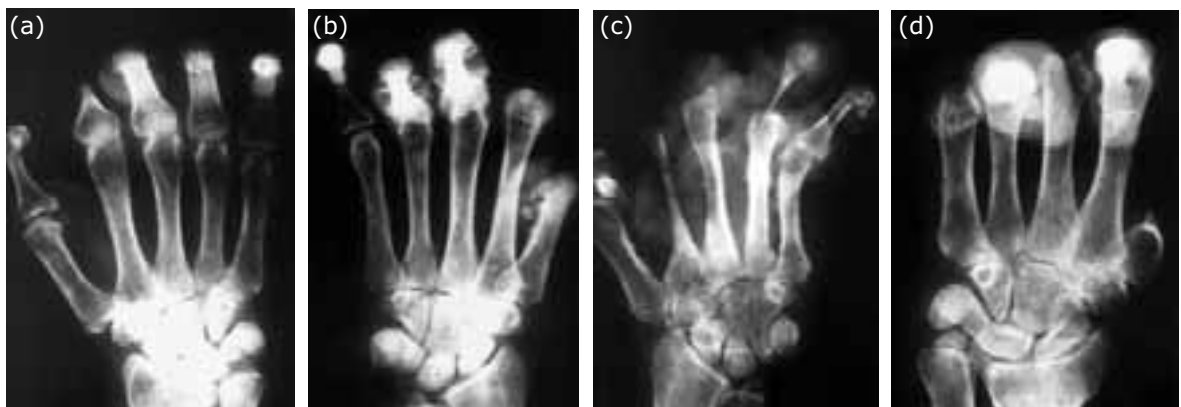A period of counseling regarding what surgery can achieve and the possible need for modified appliances is necessary to prevent future disappointments. Since these persons have long standing impairments the recovery of sensory functions is unlikely. However, protected use of the corrected hand may allow years of use of the hand. The hands can be classified into the following groups depending upon clinical and radiological findings:

**Group 1:** These persons have a minimum of 1.5 cm. long finger stumps with intact metacarpals. The thumb stump is also at least 1.5 cms. long (Fig. 10-1a, 10-2a, 10-3a).

**Group 2:** The thumb is predominantly affected. The finger stumps are greater than 1.5 cm. in length with intact metacarpals but the thumb stump is less than 1.5 cm (Fig. 10-2b, 10-3b).

**Group 2a:** The thumb metacarpal is intact.

**Group 2b:** Thumb metacarpal shows some absorption.



**FIGURE 10-2 a-d** Radiologic classification of Mitten hands.  
a) Group 1 b) Group 2 c) Group 3 d) Group 4



**Group 3:** The fingers predominantly affected. The thumb stump is at least 1.5 cm long but the finger stumps are less than 1.5 cm in length (Fig. 10-1b, 10-2c, 10-3c).

**Group 3a:** The finger metacarpals are intact.

**Group 3b:** The finger metacarpals show some absorption.

**Group 4:** The true mitten hand in which there are no finger or thumb stump.<sup>5</sup> (Fig. 10-1c, 10-2d, 10-3d)

**Group 4a:** There are no finger or thumb stumps but the metacarpals are intact.

**Group 4b:** There are no finger or thumb stumps and the metacarpals show some absorption.

The surgery is planned depending upon the condition of both hands and the available options which should be discussed with the person in detail. The affected person must participate in the decision making process.

### PREOPERATIVE PHYSIOTHERAPY

The skin of the hand is made soft and supple by soaking and oiling. The fissures and callosities are taken care of and any small ulcers in the hands should be healed before the operation. Septic foci and foot ulcers should also be clean.

The nails need to be trimmed but any residual nail spicules should not be uprooted because these can be of help in residual pinching mechanisms.

### OPERATIVE PROCEDURES

The most important component to restore in a mitten hand is thumb function because more than fifty percent of daily activities are performed with the thumb.<sup>16</sup> An opposable thumb is an essential asset for hand function and therefore takes priority over fingers when

restorative surgery is performed on such hands.

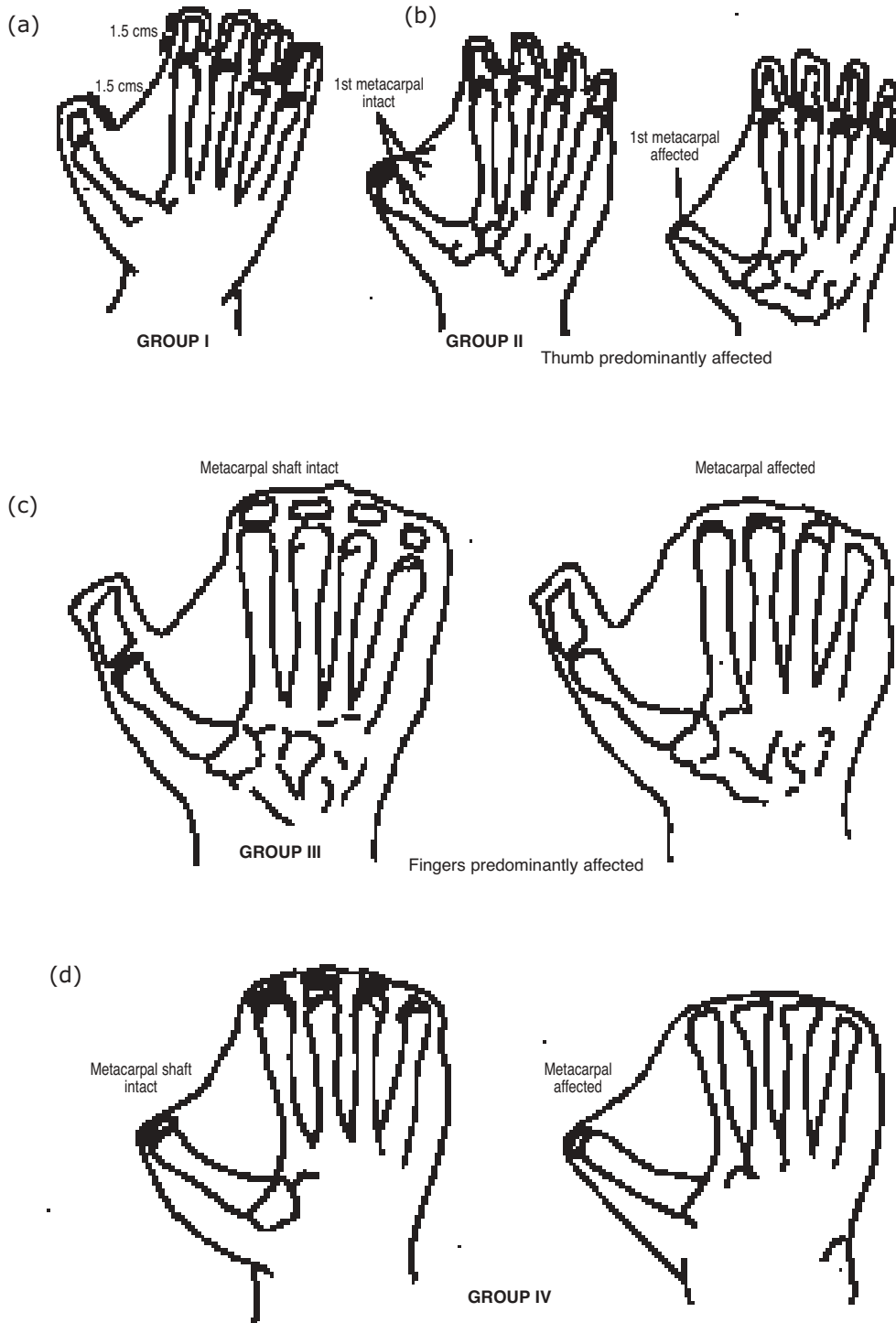
What is ideal in such situations is to restore the length of finger and thumb stumps to 2 - 2.5 cms with an adequate first web space so that prehensile capability is restored. The individual can then hold a spoon with modified handles and a glass of water.

### ***Restoration of thumb metacarpal mobility and widening of first web space***

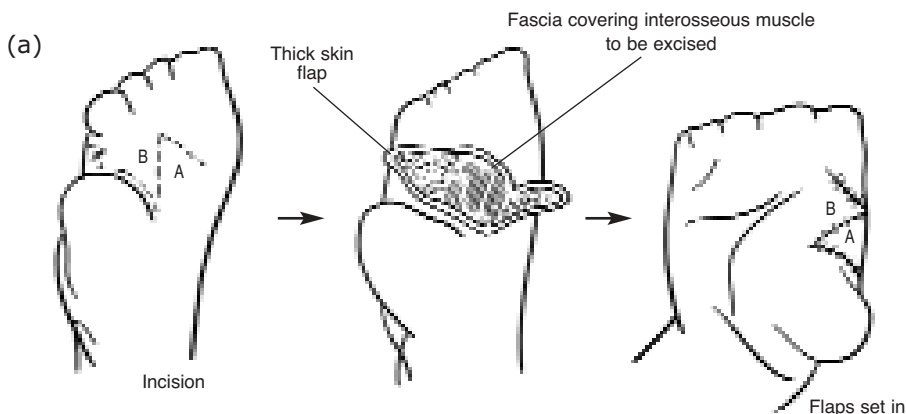
If the thumb metacarpal and part of the proximal phalanx remains satisfactory, thumb function can be achieved by procedures designed to deepen the first web space to create a wider thumb index interval. These procedures are called phalangization. They use techniques which deepen the inter-digital cleft so that the first metacarpal and remaining proximal phalanx are relatively lengthened.<sup>1,5,6,10</sup> These procedures therefore are suitable for group 1 cases where some length is available. The mobility of the thumb may be restricted because of an adduction contracture which may require release.

### **Z-plasty**

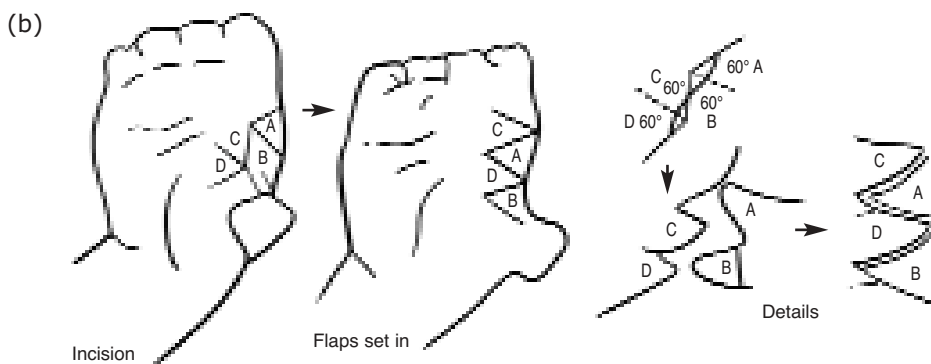
If the web skin is supple and healthy a simple "Z" plasty or a 4 flap "Z" plasty<sup>2,26</sup> is a good option (Fig. 10-4a and 10-4b). Thick skin flaps are dissected to ensure adequate vascularity. The covering fascia of muscles is divided or excised, and the mobility of the thumb tested. If the muscles are fibrotic they can also be resected. The wound is closed in a single layer with bulky dressings. The sutures are removed on the fifteenth day and a web spacer splint is used for another 3 to 6 months to overcome the tendency for recurrence. The gain in depth varies from 1.5 to 2 cms depending upon the extent of myofascial excision and provides a stump length to grasp large objects.



**FIGURE 10-3 a-d** Classification of Mitten hands.



**FIGURE 10-4a** Two flap Z-Plasty of thumb web.

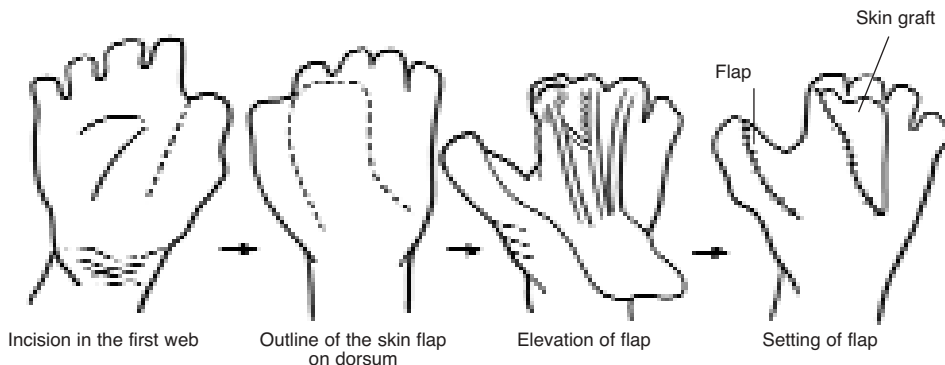


**FIGURE 10-4b** Four flap Z-Plasty of thumb web.

### Dorsal Flap Webplasty

If there is a severe web contracture or if the skin of the first web is scarred a proximally based dorsal rotation flap to provide cover to the web space is called for (Fig. 10-5). Several dorsal rotation flap techniques have proven effective in deepening the first web space and mobilising and resurfacing the thumb.<sup>6,7,9,17</sup> Skin can be raised quite safely from up to the proximal interphalangeal joint (PIP) joint of the index and middle finger as long as the proximal base of the flap includes the deep fascia of the first web space to ensure that the dorsal metacarpal artery is in the flap. The donor site is skin grafted. In certain cases, in addition to myofascial

excision, the trapeziometacarpal joint needs volar and dorsal capsulotomy to release the contractures. Post-operatively the web space may be retained by separating the first and second metacarpal with K-wires or external fixators. The wound is closed in a single layer with bulky dressings. The sutures are removed on the fifteenth day. The pins are removed after 4-6 weeks. A web spacer splint is then used for another 3 to 6 months to overcome the tendency for recurrence. If the skin on the dorsum of hand is scarred a cross arm flap or a groin flap can also be used. In cases where the thumb stump length is about 1 - 2 cm, excision of the second metacarpal will give enough skin to



**FIGURE 10-5** Dorsal rotation flap to cover web space of thumb after it has been released.

deepen the first web space and restore the thumb length by 1.5 to 3 cms so that it can be opposed to the finger metacarpal part of the palm.<sup>21,22</sup> Excision of the second metacarpal (and sometimes part of the third metacarpal) permits direct closure of the wound without skin grafting.<sup>23</sup>

### **Lengthening of thumb stump**

Several options are available to increase the length of thumb stump in group 2 and group 4 hands. Since the bones are osteoporotic, any bone transfer will need a relatively longer period of immobilisation with rigid internal fixation to provide strength until consolidation occurs.

### **Metacarpal transfer (pollicization)**

Transfer of the second metacarpal on to the first metacarpal stump<sup>13,25</sup> is performed when there is no thumb stump or the thumb metacarpal shows evidence of absorption. Pollicisation of the index or middle finger is a one stage procedure and provides a thumb with a mobile distal joint without creating significant deficit in an already deficient hand. If there are at least three remaining digits with a PIP joint and the thumb is lost down to the MCP level then one of the digits (the most radial is best) can be transferred as a pedicled digit to lengthen the

thumb. This is a pollicisation and requires careful dissection of the pedicle, ensuring an independent vascular supply without sacrificing the vascular supply to the adjacent ulnar digit. This may be difficult to dissect because of previous web space sepsis. Usually the transferred digit will be anaesthetic but is still an excellent method if available to the surgeon. The first web space is enhanced by excising the second metacarpal, part of which can be mobilised on its vascular pedicle to be attached to the thumb metacarpal, thereby increasing its length.

An incision is made in the palm in the area of thumb web. It is extended proximally along the length of the first metacarpal up to its base and distally up to the base of index finger in the proximal digital crease. The flaps are raised and the radial indicis artery is identified. The neurovascular bundle in the index-middle finger cleft is dissected to the bifurcation of the common digital artery. The digital artery to the radial side of the middle finger is ligated 1.5 cms distal to the site of bifurcation of the common digital vessel and divided. The ulnar neurovascular bundle to the index finger along with the flexor and extensor tendons are protected and the deep transverse intermetacarpal ligament is divided. The interossei are separated from the second metacarpal shaft by blunt dissection. The index metacarpal is

cleaned close to its base and divided subperiosteally. The index finger stump along with the metacarpal, now attached only with the tendons and neurovascular bundle, is moved towards the thumb and transposed to the cleaned freshened edges of the thumb metacarpal. While transposing, the length of the shaft of the metacarpal is adjusted by further resecting it so that the bone is fully covered with the skin flaps. The osteo-syntheses is preferably done by carving a peg and a socket in the proximal and distal bone stumps and supporting it further through oblique K-wires. Post-operative immobilisation has to be 3 months duration to ensure complete bone healing (Fig. 10-6).

In the absence of a suitable second metacarpal the third metacarpal can be transferred to the thumb metacarpal after excision of the second metacarpal stump so that a pincer function is restored.

### “Cocked Hat” Procedure

Skeletal lengthening of thumb metacarpal can be achieved by means of a short bone graft, 1.5 - 2 cms, which is fixed to the distal bone stump of the thumb.<sup>4</sup> Skin to cover the graft is borrowed from medial and lateral sides of the thumb. The skin is advanced from the sides of the base of thumb to cover the graft and the raw area so created is covered with full thickness or thick partial thickness skin graft - the so-called “Cocked hat” procedure<sup>14,15</sup> (Fig. 10-7).

The technique involves a curved incision across the radial side of the base of the thumb which is extended both volarly and dorsally as shown. The flap so outlined is undermined to expose the underlying first metacarpal and phalangeal remnants. The flap is further dissected dorsally leaving its web space attachments so as to gain a length of about 3 to 4 cms

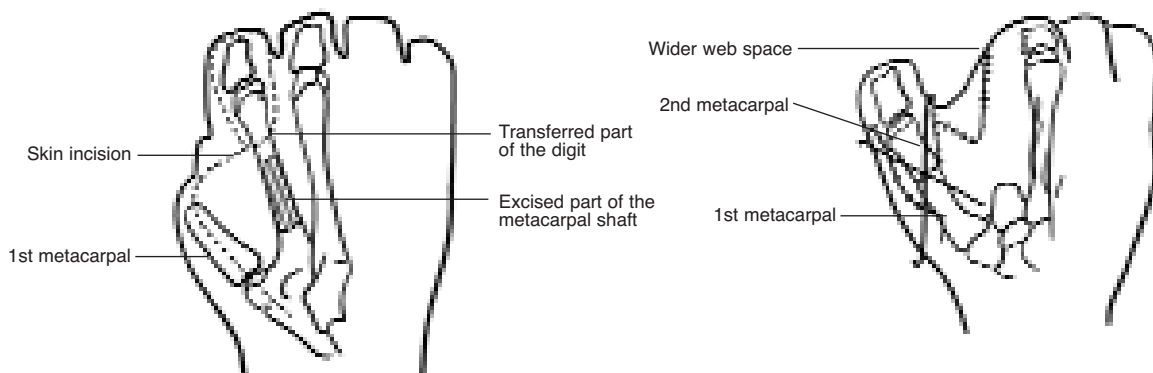


FIGURE 10-6 Pollicisation of index stump.

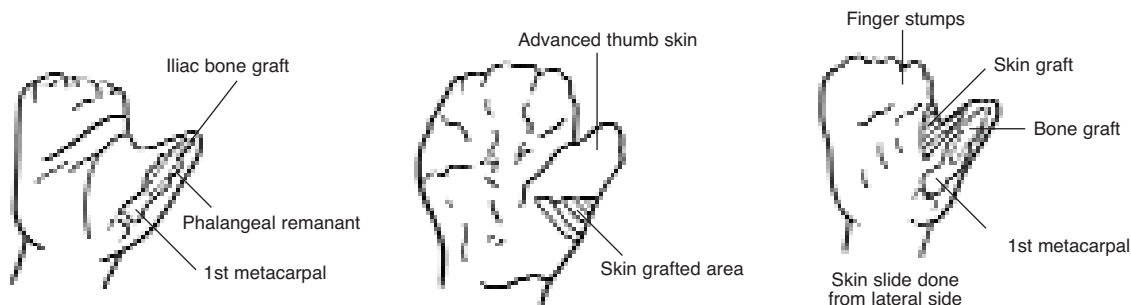


FIGURE 10-7 “Cocked hat” procedure.



depending upon the skin laxity. A 3 to 4 cms long bone graft is obtained from the iliac crest or toe (phalanx or metatarsal) and carved into a peg having 1-5 to 2 cms long stump. A cavity is made in the distal end of the thumb metacarpal to receive this peg snugly. The bone graft is then fixed to the metacarpal by compression. Oblique K-wires can be used if the stability is in doubt. The thumb skin flaps are draped over the graft and fixed to the fascia over the thenar area and the dorsum. The crescent like defect on the thumb is covered with a full thickness or thick partial thickness skin graft and tie over dressings are applied. The dressings are removed on the seventh day and a fitting plaster cast is applied for six weeks or more till the bony union is complete.

As an alternative procedure an osteotomy of the thumb metacarpal can be performed and a piece of bone graft, 1 - 1.5 cm inserted in between and retained with K-wires. Distraction lengthening of the thumb metacarpal is possible but is not preferred because of risks involved due to osteoporosis of the bones of the hand and sensory impairment.<sup>12</sup> There is a risk of excessive rotation of screws of the distractor by the persons due to anaesthesia, which can threaten the vascularity of the thumb stump. It is also time consuming.

Osteoplastic reconstructions of thumb using bone grafts from the iliac crests have been tried to increase the length of the thumb metacarpal. It is less traumatic to the remaining hand structure but it does not create a mobile articular thumb. Long term results have not been very encouraging because of gradual absorption of graft, possibly due to the denervated state of the hand or the poor graft bed.<sup>8</sup> Bone grafts from a toe phalanx have a lower absorption rate.

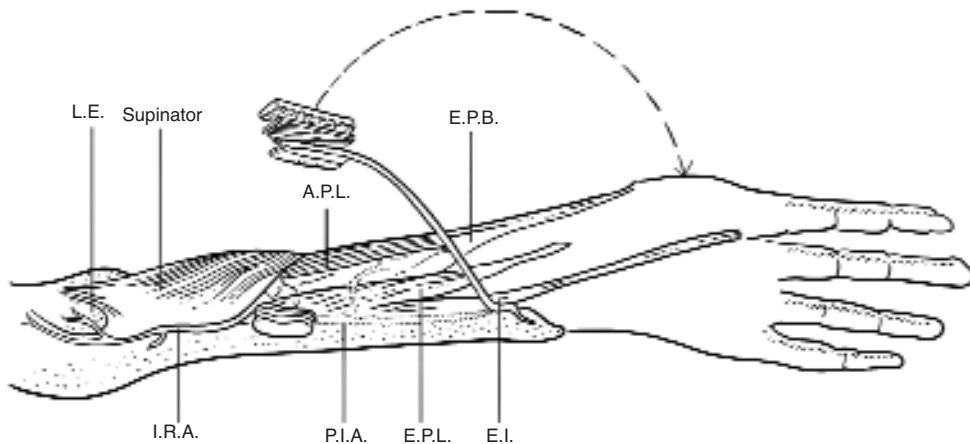
### Osseocutaneous Flaps

#### i) Radial Artery Forearm Flap.

A radial artery forearm island osseocutaneous flap includes a large longitudinal segment of radius to reconstruct the thumb.<sup>3,11</sup> The post-operative immobilisation of the hand and forearm unit is important to provide healing time for the radius to prevent a fracture.

#### ii) Distally Based Posterior Interosseous Fasciocutaneous Island Flap with Vascularized Ulnar Bone Graft (Fig. 10-8).<sup>20</sup>

The procedure can be performed under brachial plexus block. A tourniquet is used and this is inflated with the arm in elevation but, without compressive exanguination. This helps in the identification of the vessels within the

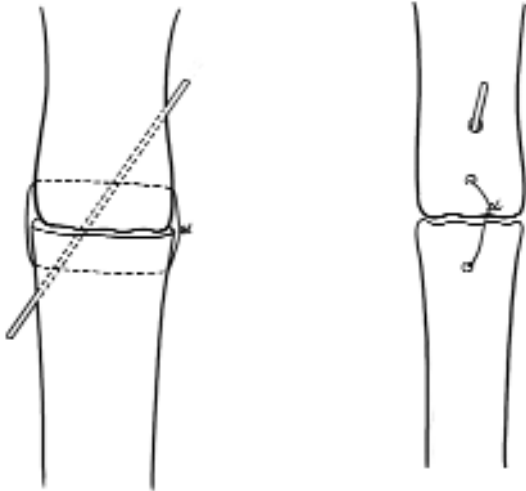


**FIGURE 10-8** Distally based interosseous fasciocutaneous island flap. PIA- posterior interosseous artery, APL- abductor pollicis longus, EPL- extensor pollicis longus, EPB- extensor pollicis brevis, EI- extensor indicis. Excision of second metacarpal and part of third metacarpal.

fascial septum during dissection. The surface marking axis of the posterior interosseous vessels lies along a line joining the lateral epicondyle and the ulnar styloid with the arm in full pronation. The pivot point of the vascular pedicle is the lower end of the ulna. From here, the reach of the flap and its dimensions can be planned on the forearm. A flap as large as 15 cm long and 9 cm wide can be raised. It is recommended that the procedure should commence with a distal forearm exploration between the tendons of extensor digiti minimi (EDM) and extensor carpi ulnaris (ECU) to locate and confirm that an anastomosis exists between the anterior and posterior interosseous arteries. A distal forearm incision is extended to the deep fascia and the septum between the EDM and ECU is identified. The deep fascia is incised on each side of the septum and the posterior interosseous artery identified. Working proximally the vascular pedicle and the delicate septum containing the cutaneous perforators, lying between EDM and ECU muscles, are then isolated and raised in a siege approach working from both sides of the septum in a subfascial plane. For increased safety, the epimysium of the muscles bordering the septum could be included within the deep fascia and if a sizable musculo-cutaneous perforator is encountered, that could be included within the flap pedicle with the sacrifice of only a few muscle fibres. It is important to avoid injury to the motor branches of the posterior interosseous nerve, both proximally (supplying ECU) and distally (supplying EDM), during the dissection of the vascular pedicle since the resulting muscle palsy will significantly worsen the disability. The origin of the interosseous recurrent artery is identified and a portion of this artery can be included in cases where a septocutaneous perforator for the skin in the flap is present. The outline of the skin paddle is completed by incising through the deep fascia to raise the fasciocutaneous

flap. When raising a compound flap to include a segment of the ulna, the proximal deep dissection should incorporate a cuff of the EPL (proximally) or ECU (more distally) muscle belly attached to the periosteum and adjacent interosseous membrane. The dissection goes behind the artery, through a cuff of muscle to the interosseous border of the ulna. The interosseous membrane is incised along the length of the bone to be harvested. A length of about 8cm of bone is stripped of a 0.5 cm swathe of periosteum. The bone segment is carefully raised with a hammer and chisel. If an oscillating saw is used, constant irrigation is necessary taking great care not to burn the bone or jeopardise its blood supply. A 1.5 cm length of bone segment at the distal end must be freed of all its muscle to act as the insertion peg into the bony remnant of the thumb after tranposition. Once the flap is completely raised, the tourniquet is released and the flap is allowed to perfuse for about ten minutes. Topical lignocaine, papaverine or verapamil are useful in overcoming spasm of the delicate vessels supplying the flap. After confirming that the perfusion of the flap is satisfactory, the flap is transferred to the previously prepared thumb or web space. This may be done by a tunneled route, but any tunnel for the passage of the flap must be generous and if there is any tendency for venous congestion in the flap after inserting it, the tunnel must be laid open and if necessary the pedicle covered by a skin graft. If it is a osseo-cutaneous transfer then the bone must now be fixed. A single Kirschner wire placed obliquely, combined with an interosseous wire fixation loop passed through drill holes made in the distal portion of the thumb remnant and proximally in the ulnar bone graft, will provide secure bone fixation (Fig. 10-8). Next the skin island is fashioned to create a neo-digit. Depending on the skin laxity, it maybe possible to close the donor defect directly. Direct closure of flaps up to 6 cm wide

is safe. However, it would be wise to skin graft the donor defect if the attempted primary closure appears too tight and could produce a tourniquet effect to the limb.



**FIGURE 10-9** Bone fixation method. Two transverse holes (1.0-1.2 mm) are drilled and wire inserted and twisted together, K-wire inserted.

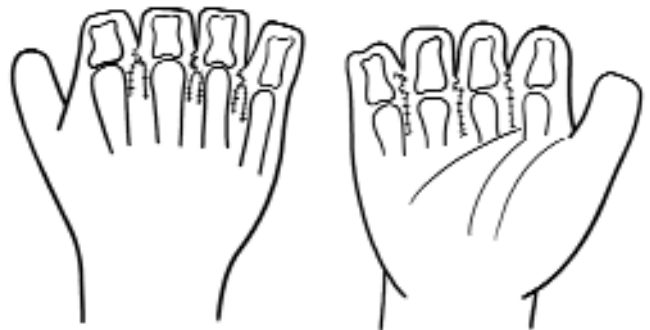Post-operative care includes elevation with vascular compromise observations for 2 days in a protective POP backslab and then protected for a further 4 weeks allowing gently active movement of the neo-digit. Remove the K-wire after 6 weeks.

**Lengthening of finger stumps**

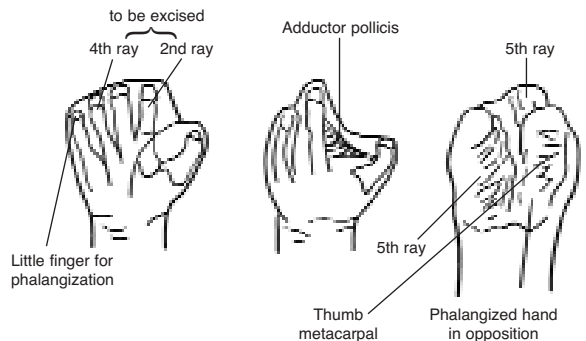
When digital remnants are present it may be possible to phalangise mobile metacarpal segments to accomplish crude pinch and grasp functions. It can therefore be attempted in suitable cases of group 1 and 2 where 1.5 to 2 cm long finger stumps are left. Digitalisation of phalangeal remnants by deepening the interdigital clefts with a "Z"-plasty or "W"-plasty, creating dorsal and volar flaps up to the metacarpal neck levels, can appreciably increase the length of finger stumps (Figure 10-10).

Distraction lengthening of metacarpals, though a theoretical possibility, is not advised because of existing osteoporosis and anaesthesia. However, it can be considered in experienced hands. The ulnar metacarpal (little finger) can be lengthened using this procedure to provide a larger span for the hand.

In some cases excision of 4th metacarpal can be done to create a cleft between the 3rd and 5th metacarpals so that an ulnar post is created to which thumb can be opposed (Fig. 10-11).<sup>24</sup> In other cases where a full and mobile first metacarpal exists with minimal lengths in adjacent metacarpals, an ulnar post can be reconstructed using osteoplastic procedures. A suitable combination of the above procedures can accomplish the desired goals of restoring crude prehensile functions. [ed. Note: The real functional gain from this procedure would appear to be minimal.] The results of these procedures



**FIGURE 10-10** Incisions for phalangisation of digits.



**FIGURE 10-11** Phalangization of metacarpals.

may prove disappointing if one can not ensure a satisfactory mid-ray space, opposable strength and motion of at least one ray. The functional abilities are reassessed periodically and additional surgery can be performed if needed.

### **Amputation**

In some cases below elbow amputation with immediate prosthetic fitting can sometimes offer a rapid return to activities of daily living but such a favorable situation is usually not possible. The amputation stump is often anaesthetic and can give rise to stump ulcers. Usually there is bilateral hand involvement so that putting on the prosthesis requires some assistance, creating a dependency on others. Attempts to provide upper extremity prosthesis may meet resistance and may not be used after discharge. Alternatively in rare cases a Krukenburg procedure (distal forearm amputation with separation of ulna and radius into two "digits") can be done. This will provide the patient with rudimentary grasp. It is generally only indicated in bilateral amputees who are either blind or cannot get good quality prostheses.

### **ADAPTED APPLIANCES**

To meet the ergonomic requirements of leprosy affected persons, grip aids have been developed. These grip aids not only provide insulation from heat to some extent but can also be molded into the shape of digits. Such molding enhances the contact area of the tools of daily use permitting better grip and reducing pressure on certain vulnerable sites. These sites vary from hand to hand depending upon the extent of deformities. These also support the grip so that the tools can be held more securely without applying much force.

Ideally the material used for making such grip aids should be insoluble, non-brittle, sta-

ble, non-toxic and easily available at an affordable price. Several materials have been used such as sodium alginate and epoxy resins. Of these, two products have been found suitable: "Modulan", marketed by Ciba-Geigy, and "M-Seal", (Mahindra Engineering and Chemical Products Limited, 145 Mumbai-Pune Road, Pune, India). Both Modulan and M-seal packs contain two semi-solid sticks in different colors one of which is resin and the other a hardener. Equal parts of both are mixed manually to give a uniformly colored putty which can be molded in different shapes. They harden in air in a few hours.

### **Preparation of grip aid**

The patient is observed in his or her daily activities to notice what tools are used and how they are held. The types of tools required and their technique of usage are discussed with the patient and the tools are selected on which the grip aid is to be applied. The handles, if smooth, are scraped a little with a metallic file to roughen them so that the putty can be held firmly on the handle when it hardens. The tool is then cleaned with spirit to remove any grease on the surface. The putty is prepared in an adequate amount by mixing the portions of resin and hardener. An adequate amount is then applied on the handle so that when the tool is grasped by a full grip appropriate indentations will be left on the putty.

A little cream is applied on the hand (this helps in freeing the hand from the tool after indenting the putty) and the patient is asked to hold the tool as if he or she were actually using it. If inadequate pressure is applied the indents will be too shallow to support the grip. If too much pressure is applied the indents will be too deep and free movement of digital stumps on the tool will not be possible. Use of the tool will cause friction, producing blisters and callosities. While the person is holding the grip aid, putty is displaced into all corners and the

gaps between the digits and the tool so that the contact area is increased. After a few minutes the person is asked to take his hand off the tool carefully without disturbing the ridges so created. The sharp edges and corners are smoothed and rounded off and the tool is allowed to dry for 8 to 12 hours. The tool can then be used.

Heat resistant handles can be made twisting thick PVC insulated wires and using Modulan on the handles. Multipurpose grip aids<sup>27</sup> can also be made for e.g. spoon, comb, and shaving razor by slitting the nozzle end of a 10 ml plastic syringe into which the handle of various articles can be fitted. Use of a syringe makes the grip aid lighter. Microcellular rubber can also be used in making such grip aids where the palmar side of the handle has MCR and the digital side the putty.

### Handling of adapted appliance and care

The person while using the tool has to adjust his grip in the indentations properly so that the tool can be properly held. The use of the aid is reassessed while the person is using it so that modifications can be done if required. The grip aids are checked periodically and remade if found damaged.

### CONCLUSIONS

Elementary pinch and grasp functions are restored by reconstructing the thumb and a medial pillar on which to oppose the thumb.

The decisions as to whether to operate and the choice of operative procedure are as important as the technique when one thinks of any surgical intervention. A person may be quite well adjusted to an impairment especially if it is on the nondominant side and of long duration. Each individual needs an individualised approach because of their different needs and expectations.

Factors which must be considered include length of stumps, condition of both hands, age, occupation, the person's psychological state and the presence or absence of protective and residual sensibility. Good results can be achieved in a well motivated, active and intelligent person who has set realistic goals and understands the limitations of such procedures. A combination of surgery and adapted appliances will be more useful than either alone. Since these persons have adjusted to a particular way of life, the operations should be performed in willing, well informed and well motivated persons. Acceptance of good hand practices, protected use of hand and adequate care will keep the operated hands useful for several years to come.

### REFERENCES

1. Arana GB: Phalangization of the first metacarpal. *Surg Gyn Obst* 40:859-862, 1925
2. Broadbent TR, and Woolf RM: Thumb reconstruction with contiguous skin bone pedicle graft. *Plast Rec Surg* 26:494-499, 1960
3. Biemer E, StockW: Total thumb reconstruction: a one stage procedure using an osteocutaneous forearm flap. *Br J Plast Surg* 36:52-55, 1983
4. Boyes JH: Reconstruction of thumb. pp502-518 In Bunnell's *Surgery of the Hand*. J. B. Lippincot, Philadelphia 1970
5. Brown H, Welling R, SigmanR, Flynn W, and Flynn JE: Phalangizing the first metacarpal. *Plast Rec Surg* 45:294-297, 1970
6. Chase A: The damaged index digit a source of components to restore the crippled hand. *J Bone Joint Surg* 50A:1152, 1968
7. Elsahy NI: Reverse pollicization for thumb reconstruction. *Hand* 6:233-235, 1974
8. Enna CD: Amputations in the hand. pp277-279 In: McDowell, F and Enna, CD. *Surgical Rehabilitation in Leprosy*. Williams and Wilkins, Baltimore 1974
9. Flatt AE, Wood VE: Multiple dorsal rotation flaps from the hand for thumb web contractures. *Plast Rec Surg* 45:258-262, 1970



10. Flynn JE, Burden CN: Reconstruction of thumb. *Arch Surg* 85:56-60, 1962
11. Foucher G, VanGenechten M, Merle M and Michon J: Single stage thumb reconstruction by a composite forearm island flap. *J Hand Surg* 9B: 245-248, 1984
12. Matev IB: Thumb reconstruction after amputation at the metacarpophalangeal joint by bone lengthening: A preliminary report of three cases. *J Bone Joint Surg* 57A: 957- 965, 1970
13. May JW, Donelan MB, Toth BA and Wall J: Thumb reconstruction in the burned hand by advancement pollicization of the second ray remnant. *J Hand Surg* 9A:484-489, 1984
14. Reid DAC: Reconstruction of the thumb. *J Bone Joint Surg* 42B: 444-465, 1960
15. Reid DAC: The Gillies thumb lengthening operation. *Hand* 12:123-129, 1980
16. Riordan DC: Surgical treatment of secondary hand deformities. pp 259-262. In McDowell, F. and Enna, CD. *Surgical Rehabilitation in Leprosy*. Williams and Wilkins, Baltimore, 1974
17. Sandzen SC: Dorsal pedicle flap for resurfacing a moderate thumb index web contracture release. *J Hand Surg* 7:21-24, 1982
18. Sharpe C: Tissue cover for the thumb web. *Arch Surg* 104:21-25, 1972
19. Spinner M: Fashioned transposition flap for soft tissue adduction contracture of the thumb. *Plast Rec Surg* 44:345-348, 1967
20. Teo TC, Richard BM: The distally based posterior interosseous fasciocutaneous island flap in reconstruction of the hand in leprosy. *Ind J Lepr* 69: 93-100, 1997
21. Tubiana R: Reconstruction for partial or total absence of the thumb. pp215-221. In McDowell F. and Enna CD (ed): *Surgical Rehabilitation in Leprosy*. Williams and Wilkins, Baltimore, 1974
22. Tubiana R, Stack G, Hakstian RW: Restoration of prehension after severe mutilations of the hand *J Bone Joint Surg* 48B:455-473, 1966
23. Tubiana R: Repair of bilateral hand mutilations. *Plast Rec Surg* 44:323-328, 1969
24. Tubiana R, Roux JP: Phalangization of the first and fifth metacarpals. *J Bone Joint Surg* 56A: 447- 457, 1974
25. Ward JW, Pensler JM, Parry SW: Pollicization for thumb reconstruction in severe paediatric hand burns. *Plast Rec Surg* 76:927-932, 1985
26. Woolf RM, Broadbent TR: The four flap "Z" plasty. *Plast Rec Surg* 49:48-50, 1972
27. Yawalkar SJ, Shah A, Ganapati R, Yan LB, Zhang GC, Chen H, Westmacott K, Osterwalder W: Modulon grip aid for leprosy patients. *Int J Lepr* 60:250-254, 1992

# Use of External Fixators in the Neuropathic Hand

• A. SALAFIA  
G. CHAUHAN

## INTRODUCTION

Deformities of hands and feet in leprosy pose a challenge to the surgeon as they are, usually, compounded by loss of sensation. The problem becomes complex when stiffness of small joints is present, especially. The proximal interphalangeal joints (PIP) which are often fixed in flexion contracture.

Thumbweb contractures are also quite common, while wrist joint stiffness and distal interphalangeal joints (DIP) flexion contractures are less common. Metacarpo-phalangeal (MP) joint stiffness is unusual. This chapter will discuss indications and techniques of surgical release of contracted joints/tissues.

### **Aetiology of Joint Stiffness**

The causes of stiffness are:

- 1) Disuse and / or lack of exercises following multiple nerve damage;
- 2) Trauma and
- 3) Septic arthritis.

Flexion deformities of PIP joints in leprosy are the result of:

1. Skin contractures, as sequelae of trauma, burns or long-standing flexion as in cases of neglected claw fingers deformity.<sup>1,2</sup>
2. Shortened tendons and muscles, both intrinsic and extrinsic, due to long-standing paralysis, trauma and infection.
3. Adhesions of the long flexors to their sheaths.<sup>3</sup>
4. Contracture of the volar capsule and retraction of the collateral ligaments,

which may occur in long-standing claw deformity.

5. Bony deformities, traumatic or exostotic, or ankylosis following septic arthritis.

We like to use a working classification of all forms of flexion deformities caused by soft tissue contracture. A *mild degree* of deformity is one in which the joint(s) can not be moved actively, but there is full passive range of motion. *Moderate*: a joint cannot be put through a full range of motion. *Severe*: the degree of movement is very limited and it is easy to mistake, clinically, this degree of contracture with joint fusion. In such cases radiography is necessary to clear the issue.

## MANAGEMENT

1. Assessment of the deformity both clinical and radiological.
2. Intervention: operative or non-operative.

Non operative management entails techniques such as splints, serial casting, and physiotherapy. None of the non-operative methods will be sufficient in most of the moderate and all the severe forms of contracture.

### **Operative Methods**

There are a number of conventional methods used for correction of moderate and severe degrees of PIP contractures; the choice of technique depends upon the causes of contracture, the patient's expectation and financial capabilities, and the surgeon's expertise.

The following techniques are available:

- 1) Release of contracture and free skin grafting using a full-thickness graft, known as Wolfe graft.<sup>12</sup>
- 2) Release of contracture and wound closure using local flaps (i.e. cross finger or flag flap, Z-plasty) in cases of PIP joint contractures<sup>6</sup>, while wrist and MP contracture, may, at times, require vascularised grafts (cutaneous, fascio-cutaneous).<sup>5</sup>
- 3) Release of contractures by resection of collateral ligaments, also known as capsulectomy of Curtis.<sup>4</sup>
- 4) Joint replacement.

All these surgical methods have some disadvantages.

### Free skin grafting

Though a relatively easy surgical procedure, this is not of great help in many cases. In moderate and severe contractures, the neurovascular bundle is also shortened so that an attempt at fully extending the finger in one stage would risk finger necrosis. To be effective, this procedure may have to be repeated at least twice and the finger extended gradually over a period of months. Moreover while attempting to extend the joint, the tendons may be exposed: A skin graft over a tendon does not take and even if it does, it would limit the movement of the finger.<sup>2</sup>

### Local Flaps

Only those who have a good training in hand surgery should do these procedures. In leprosy, a cross-finger flap appears to be the best choice in cases of PIP joint contracture, while a vascularised flap would require training in microsurgery and the necessary equipment to perform it.<sup>6</sup> However, a flap does have some of the disadvantages of a free skin graft. It does not

take care of the collateral ligaments and the volar plate, which are powerful contracting forces, so much so that one more surgery would be required to release these. Even by such combined surgery, full extension of the fingers is possible and advisable only if the dorsal skin is healthy and has a good venous drainage. Further, while a flag-flap is possible in theory for all fingers, cross-finger flaps cannot be done for all the fingers of the same hand.

### Capsulectomy

A capsulectomy can solve the problem of capsular contracture, but it is not an easy procedure, and alone is seldom sufficient to achieve full extension.

### External Fixators and Distractors

External fixators have been used for years in cases of fractures and arthrodesis as an alternative to intramedullary K-wires and Plaster of Paris (POP). Distractors along with external fixators are used in a variety of conditions: fractures and arthrodesis, tissue expansion, congenital deformities (ulnar and radial deviation, Epidermolysis Bullosa Dystrophica) (BB Joshi-personal communication) and for lengthening or shortening of bones.

External fixators have been used especially in America since the late 1800's. This design was modified by Mantero (Italy) in 1976.<sup>9</sup> In 1991 Joshi introduced the external fixators and distractors called JESS (Joshi External Stabilizing System).<sup>7</sup> Various modifications followed the first set of JESS.<sup>8</sup>

### Types of JESS

- a) The single JESS is composed of a rod, a static block and a distracting one. The earlier version had a nut at the end of the static block that, when in place, may touch the skin of the finger's web leading to necrosis; the later version, made of polycarbonate, eliminates this problem to a certain extent.

b) The axial JESS has a few versions. The one commonly used by us is the uni-axial version. This can be used in the correction of a variety of conditions.

### Advantages of JESS

1. All soft tissues, including volar capsule, can be gradually lengthened over a period of time. The vessels are also lengthened gradually so that the chances of vascular damage are minimized.
2. Skin grafts and flaps leave scars on the volar aspect of the fingers. This is a great disadvantage in the anesthetic hand because this may make the hand more prone to further damage. Any additional surgery of tendons could be compromised by the scars. K-wires, used along with JESS, leave tiny negligible scars on the lateral aspect of the fingers, which do not cause any problem surgically or otherwise.
3. The rate and amount of release is controlled.
4. It is an easy procedure and surgeons can perform it with minimal training.
5. Compared to capsulectomy and skin flaps, it is much easier to perform, and in one session the problem can be addressed. The time needed for each finger is only about 15 to 20 minutes, while the surgical time for the axial JESS is about 2 hours.
6. The compliance of the patients is very good. The patient is taught how and how much to turn the knob, or somebody else can do it for him.
7. When a single JESS is used, local infiltration of any suitable anesthetic agent is sufficient. When more than one finger is involved, regional anesthesia or even general anesthesia are advised, depending on the cooperation of the patient.
8. The operation can be repeated in case of failure.
9. No hospitalization is usually required.

10. Lastly, the JESS instrumentation is economical. This last statement needs to be qualified. European and American single distractors are rather costly, in the range of US \$ 300 each. This is the very reason that prevented us from using distractors prior to the introduction of the JESS. However, the single JESS costs around \$ 5-10 US each. Furthermore, the JESS is also reusable and adaptable to various conditions. An axial JESS costs about \$ 80 US.

The possible complications after this procedure are few and easily avoidable. They include:

1. **Mechanical:** misalignment of the K-wires. Possible complications, which we have not experienced yet, are: impalement of tendons and impalement of neurovascular bundle.
2. **Biological complications:** pin-track infection leading to extrusion. Pin track infection can occur in any surgery wherein K-wires are used.
3. Ulceration caused by the rubbing of JESS on adjacent skin.

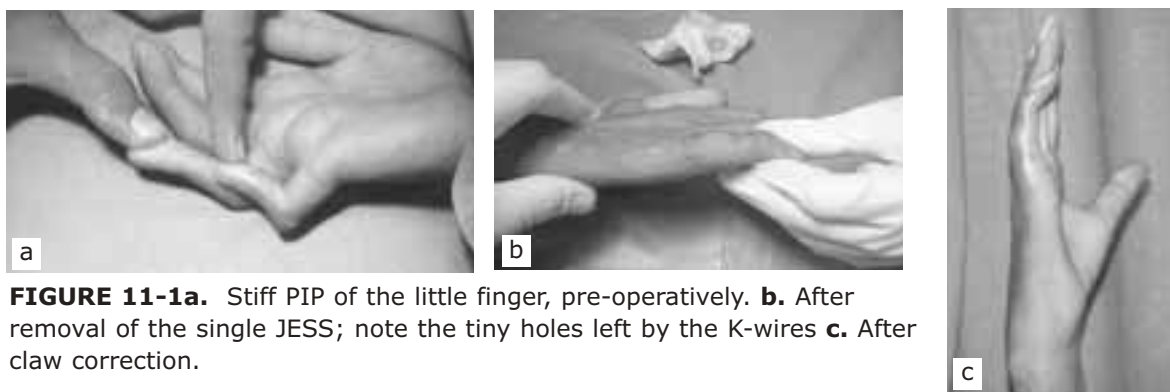
### Various uses of JESS in leprosy

A. **The single JESS** is used by us, with excellent results, in the following conditions<sup>10</sup>:

1. PIP joint stiffness, prior to claw hand correction (Fig. 11-1 a,b,c).
2. First web contractures; in cases of combined web contracture and opponens-plasty, we opt for a two-stage surgery. In the first stage, a 'Z' or 'W' plasty of the first web is carried out and the JESS is used to keep the thumb in opposition (Fig. 11-2 a,b). In the second stage, the JESS is removed and a tendon transfer is performed (Fig. 11-2c).

3. Skin contracture due to burns / scalds / trauma.
4. In cases of fractures; (the original use of distractors).
5. Arthrodesis, to keep the bony structures in the selected position and for compression and healing (Fig. 11-3).
6. Pollicization: the distractor helps in maintaining alignment.

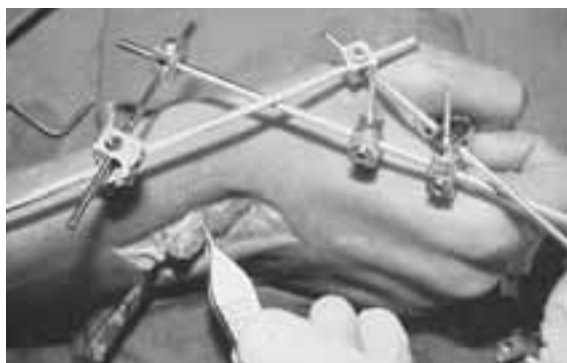**B. The axial distractor.** Whenever more than one finger is involved, the choice would be an axial distractor that allows distraction of all fingers at the same time. We use it regularly and in some cases we have combined an opponens plasty with distraction of the fingers. In such cases the thumb can also be anchored, by means of an elastic band, to the axial frame to maintain the desired position (Fig. 11-4 a-d).



**FIGURE 11-1a.** Stiff PIP of the little finger, pre-operatively. **b.** After removal of the single JESS; note the tiny holes left by the K-wires **c.** After claw correction.



**FIGURE 11-2** A case of long-standing median palsy with retropulsed thumb. **a.** Lateral view pre-operatively. **b.** Z-plasty of first web and application of JESS. JESS removed after 20 days, and opponensplasty done. **c.** Final result.



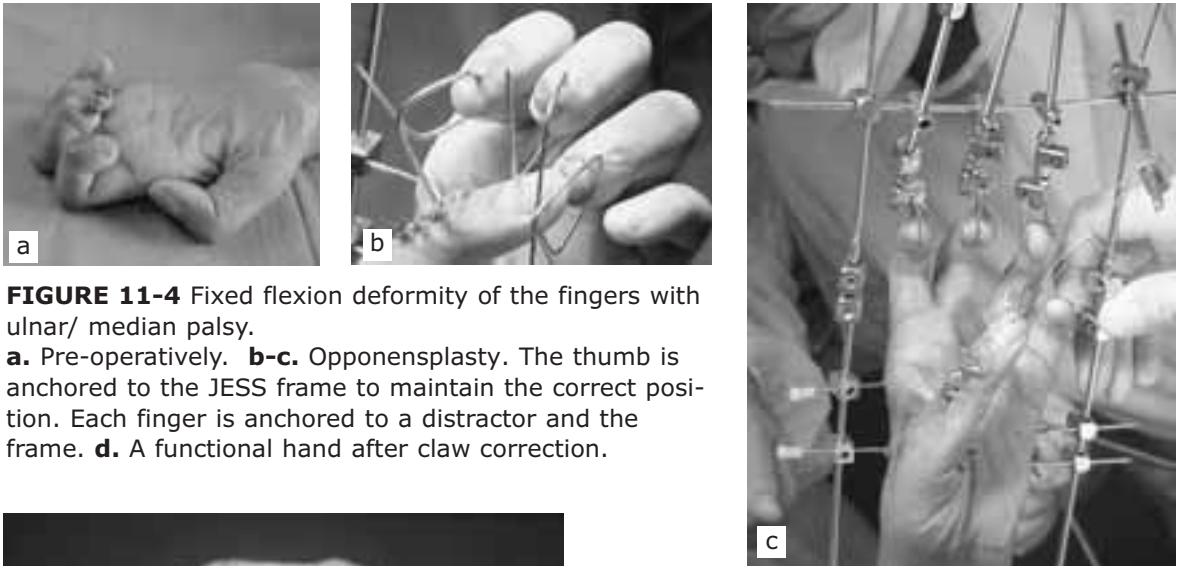
**FIGURE 11-3** A case of wrist drop. The JESS is used to stabilize the wrist after bone graft.

**Technique for single JESS**

Two K-wires (1.2 or 1.5 mm in size) are drilled at right angle to the long axis of the phalanx about 12 – 20 mm away from the joint. (Fig. 11-5). Ideally the K-wires should be parallel to each other.

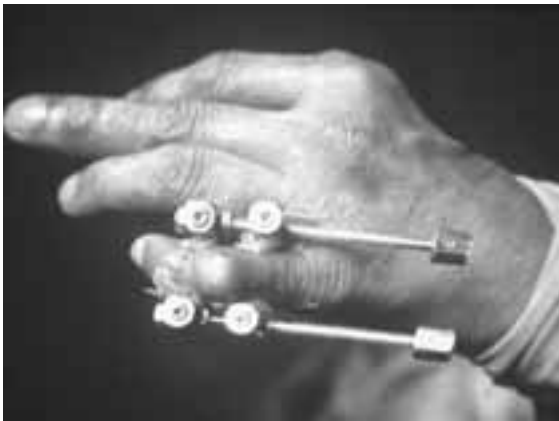A distractor of suitable length (generally 7.5 cm) is attached to the K-wires. Distraction is attempted immediately. Care should be taken not to overdo this. It is best, on the first day, to stop as soon as resistance is met. A full turn of the distractor’s knob will bring about a 0.5 mm





**FIGURE 11-4** Fixed flexion deformity of the fingers with ulnar/ median palsy.

**a.** Pre-operatively. **b-c.** Opponensplasty. The thumb is anchored to the JESS frame to maintain the correct position. Each finger is anchored to a distractor and the frame. **d.** A functional hand after claw correction.



**FIGURE 11-5** Bilateral single JESS.

lengthening. At this rate, a joint with a  $90^\circ$  flexion deformity, can be brought to  $180^\circ$  extension in approximately 20 days. Bilateral application of distractors will achieve better results and stability, however care must be taken to ensure that the distractor is not in touch with the web skin. Failure to do so may lead to necrosis of the skin.

#### Technique for the axial JESS

Select four K-wires of 2 mm, four K-wires of 1.5 mm and four K-wires of 1.0 mm each. All wires are inserted at right angles to the long axis.

Drill four K-wires of 2 mm each in this order: two wires in the mid-forearm and two proximal to the wrist joint. Two wires will be on the ulnar side and two on the radial side. Drill four K-wires of 1.5 mm in the hand. One is drilled distal to the base of the 2nd ray and one proximal to the head of the same. A similar procedure is used for the 5th ray. Rods are attached to each of these wires: this is the beginning of a frame. A 1.0 mm K-wire is passed at the base of each distal phalanx. On these wires the distractors are attached. Now a rod is passed through all four digital distractors and then the rod is anchored to the main frame. The frame is complete (Fig. 11-4c). A number of modifications can be carried out as needed.<sup>8</sup>

When the flexion deformity is mild, an elastic band can be used instead of the distractor. The rubber band will gradually distract the joint. In this case there will not be much control over the amount of distraction achieved. That is why we prefer the distractors over the rubber bands.

One of the many advantages of the axial distractor over the single JESS is that while distracting a PIP joint by a single JESS, the DIP joint is not distracted. On the contrary the axial distractor, because it is attached to the base of the distal phalanx, will extend every joint.

We advise to delay the actual distraction by a couple of days, because this type of surgery does give rise to a certain amount of edema of the hand and stress on the vessels. By waiting 2-3 days we can assess the vascularity of the fingers and decide on how much distraction to apply. It is better to adopt a slow pace in distraction than a fast one.

## CONCLUSION

We find the application of JESS very useful in neuropathic hands, especially in cases of long standing PIP joint contractures. In view of this, we have abandoned all other procedures like skin grafting, flaps and capsulectomy in favor of distractors which we find easier to use. With distractors we achieve better results than with flaps or capsulectomy.

## REFERENCE

1. Boyes JH: Skin and Contractures. pp 187-303. In Bunnell's Surgery of the Hand, 5th. ed. JB Lippincott, Philadelphia, 1970
2. Brand PW: Deformity in leprosy. pp. 447-464. In Cochrane RG (ed): Leprosy in Theory and Practice, 2nd ed. John Wright & Sons Ltd., Bristol, 1964
3. Brunelli G: Manuale di Chirurgia della Mano. pp. 203-207. Aulo Gaggi, Bologna, 1983
4. Curtis RM: Capsulectomy of the interphalangeal joints of the fingers. J Bone Joint Surg 36A:1219, 1954
5. Fritschi EP: Reconstructive Surgery in Leprosy. John Wright, Bristol, 1971
6. Glicenstein J, Leclercq C: Skin contractures in the hand. pp. 439-464. In Tubiana R (ed): The Hand, Vol. 2. WB Saunders, Philadelphia, 1985
7. Joshi BB: Lecture demonstration at the Anglo India Congress on Hand Surgery, Goa, Nov 1991
8. Joshi BB: Joshi External Stabilization System, Basic Techniques as applied to Hand and Wrist. JESS Research and Rehabilitation Centre, Bombay, 1999
9. Mantero R: Un apparecchio di Hoffman modificato per il trattamento delle lesioni della mano. Riv Chir Mano 13:134-150, 1976
10. Salafia A., Chauhan G. Joshi External Stabilizing System (JESS) in proximal interphalangeal joint (PIP) contractures in leprosy. Ind J Lepr, 69: 331-339, 1997
11. Tubiana R: Skin flaps. pp257-286. In Tubiana R (ed): The Hand (Vol. 2) WB Saunders, Philadelphia, 1985
12. Wolfe JR: A new method for performing plastic operations. Brit Med J, 2: 360, 1875

# Biomechanical Assessment of the Foot

• H. CROSS

## INTRODUCTION

This chapter discusses the biomechanics of the foot and in particular its relevance in relation to the pathogenesis of foot ulceration and deformity. The integrity of the foot is discussed mainly as it relates to foot function during the stance phase of gait. This is followed by a section that discusses major features that need to be taken into account when examining the foot. Orthotic treatment of 'dys' functioning feet is discussed in Chapter 17.

## MAINTAINING THE INTEGRITY OF THE FOOT

### *Stability in Stance*

During the stance phase of gait the skeleton of the foot is constantly in motion developing an adaptable dynamic structure to suit the demands of deceleration, support, equilibrium and acceleration.

### *Static Stance*

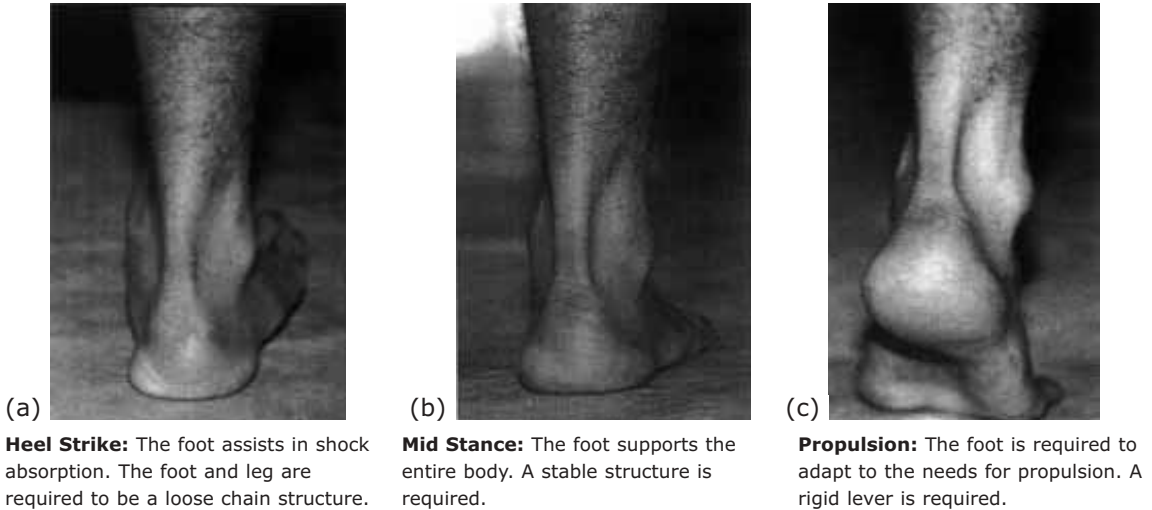
The subtalar joint (STJ) is immobilised by ground reaction forces during static stance. However, even during these apparently quiescent periods, a force applied by the gastrocnemius plantarflexes the foot, the only extrinsic muscle recorded to demonstrate activity during static stance, to effect tension forces at the other joints of the foot.<sup>6</sup> During this phase, passive ligamentous function maintains the integrity of the skeleton by resisting tension. In resistance to potential subluxation, the ligaments initially become taut but gradually stretch. Root et al. suggest that there is proba-

bly an elastic threshold at which proprioceptive innervation is activated.<sup>6</sup> Momentary muscle contractions are activated which reposition the bones and allow the ligaments to shorten, thereby continuously facilitating the passive protection of skeletal integrity.

It is during kinetic stance that the foot is particularly dynamic. The integrity of the foot is primarily dependent on safety information relating to current conditions of the substratum. The high density of Vater-Pacini corpuscles in the subcutaneous fat chambers provide an acute sense of deep pressure and vibration associated with high frequency shock and tissue displacement. Meisner's corpuscles register low frequency shock which also stimulates Ruffini endings, but at levels as deep as the capsules of diarthrodial joints.<sup>1</sup> It is, however, the mechanical integrity of the skeleton and efficiency of joint articulations during locomotion that is crucial if the effects of applied and reactional forces during locomotion are to be optimised and damage is to be avoided.

### *Joint Stability*

The stability of any joint is dependent on the component of force affecting it. During contact with the supporting surface, ground reaction forces interact with the resultant force of body mass, muscle tension and acceleration to exert linear and rotational forces on bones and joints respectively. Whereas linear forces tend to stabilise joints by compression of opposing bones, rotational forces promote instability at articulating surfaces.<sup>6</sup> Throughout most of the stance phase of gait the ideal functional position for



**FIGURE 12-1** Normal foot function.

any joint in the foot is achieved when the joint is able to function in a position which provides maximum potential for compressional forces with minimal influence of bending forces.\*

Root et al. suggested that it is the astatic instability of joints during kinetic stance that presents the primary cause of mechanical trauma to the foot.<sup>5</sup> They explained that as articulating bones are forced to respond to inadequately restricted rotational forces, joints respond by moving beyond their normal range of motion. They may alternatively move in planes of motion contrary to those dictated by their structure and position.<sup>6</sup> One effect is that the general deficiency of the foot will compromise the body by high energy demands to try to impose stability. A second effect is that if the demands exceed the functional capacity of soft tissue mechanisms, the dissipation of mechani-

cal energy may demand the destruction of solid structures.

When soft tissues of the foot are compressed, energy is stored within elastic elements until it is unloaded with decompression. During rapid decompression the viscous elements of soft tissue permit shock absorbency converting mechanical energy into thermal energy. Local heating is controlled by the dissipation of energy through the vascular system.

If the strain imposed by excessive deformation of soft tissue becomes too great to be accommodated within the normal ranges of tissue mouldability and elasticity, tissue may experience fatigue failure and damage may ensue. Fatigue describes the resistance to normal or shear stress displayed by any structure subjected to stress. As a general principle, fatigue failure is avoided as the fatigue period

\* Manter described a longitudinal loading axis from the centre of the trochlea to the second intermetatarsal space.<sup>5</sup> Where joints were angled away from a perpendicular relationship with the loading axis a decrease in compressional force was measured. He established that if a chain of bones was aligned so that all articulations were congruous and perpendicular to the direction of force, then the chain would be stabilised by compression. The skeleton of the foot is constantly shifting throughout stance and as it does so forces on the proximal bones will angle with reactive forces on distal bones. When the angle is small, compressional force will exceed rotational forces and the joint will be relatively stable. Assuming this ideal is achieved the most economical utilisation of energy will be accomplished.<sup>2</sup>

of soft tissue is such that it allows sufficient time for self-repair. Where strain has been excessive there is a degree of soft tissue relaxation on relief from load, but excessive demands may result in incomplete recovery. If the number of load cycles, or the magnitude of stress is such that demands for tissue recovery periods exceed the fatigue period, the tissue will experience fatigue failure and breakdown.

### ***The Action of the Rearfoot in Determining Joint Alignment***

It has been suggested that the motion of the ankle-subtalar joint complex is analogous with a universal joint mechanism.<sup>4</sup> Allowing for minor individual variations, the ankle joint axis runs through the inferior tips of the fibular and tibial malleoli. It has a slight lateral incline and is externally rotated in relation to the axis of the knee. The motion at the joint therefore is almost exclusively in the sagittal plane. Frontal plane and virtually all transverse plane motions are transmitted to the tarsus via the talus which, in concert with the calcaneus, cuboid and navicular, translates such forces into triplane motion. This mechanism has been the focus of much study. Current understanding of pedal mechanics, based predominantly on the theories of Manter and Elftman, indicates the pivotal role of the rear foot complex in determining the harmony between locomotion and the environment.<sup>3,4</sup>

Manter's hypothesis suggested that the mid tarsal joint (talar navicular and calcaneo cuboid complex) has two axes. The gross frontal plane motion of the forefoot rotates about a longitudinal axis, whilst an oblique axis allows a limited extent of sagittal motion. The extent and direction of motion available is dependent on tarsal midtarsal configuration.

## **NORMAL AND ABNORMAL FOOT FUNCTION**

### ***Normal Phasic Activity***

#### **Heel Strike**

When the heel strikes the ground the STJ is in a supinated position. On contact, the STJ pronates to enhance shock absorption (Fig. 12-1a). Pronation of the subtalar joint causes a reduction in the congruency of other joints distal to it. An effect is that the skeleton of the foot becomes a more open chain structure. As an open chain structure it assists in the dissipation of force at heel strike.

The STJ further enhances shock absorption by:

- Encouraging the tibia to rotate faster than the femur thus enhancing knee flexion
- Facilitating the “unlocking” of the mid-tarsal joint\*\* and all joints distal to it, thereby releasing tension in plantar soft tissues

#### **Mid Stance**

At mid-stance the foot is required to be a stable structure to support the body. During this phase the foot is also required to prepare for the demands of propulsion. Stability is facilitated if the STJ is in neutral position (neither pronated or supinated). In the neutral position the midtarsal joint is “locked” and the foot becomes a stable support (Fig. 12-1b).

If the STJ is in neutral position at mid-stance it should be able to rotate further into a supinated position for effective propulsion.

#### **Propulsion**

During the propulsive phase joint congruency is required to ensure that forces effect compression rather than rotation at joints. Compressional forces will protect joints and

---

\*\* Motion around the mid tarsal joint.



soft tissue during the application of forces which peak beneath the forefoot during this phase (Fig. 12-1c). A rigid foot is effected if the STJ is supinated. When the STJ is supinated the forefoot cannot evert around the longitudinal axis of the midtarsal joint (eversion at the MTJ is only possible if the STJ is pronated).

A further effect of STJ supination is that the height of the medial arch is maintained. The effects of a well maintained arch are:

- Peroneus longus has an increased angle of approach and a strong mechanical advantage to stabilise the first ray.
- The plantar fascia becomes an effective 'windlass' to help stabilise the hallux.

### Abnormal Phasic Activity

#### Aphasic STJ Pronation

A common problem is that the STJ compensates for other structural or functional abnormalities by pronating excessively at heel strike (Fig. 12-2). When this occurs the STJ is usually unable to "recover" to a neutral position at mid-stance and is often still in a pronated position during propulsion (Fig. 12-4b). The skeleton of the foot therefore remains as an "open chain" structure and responds to forces by allowing excessive rotation at joints. The most significant problems occur during the propulsive phase.

If the STJ is pronated during the propulsive phase, the foot will still be mobile. The arch will not have recovered by mid-stance and peroneus longus will not be able to effect stabilisation of the first ray. The plantar fascia will bow string causing further destabilisation of the hallux.

The effects for the foot are:

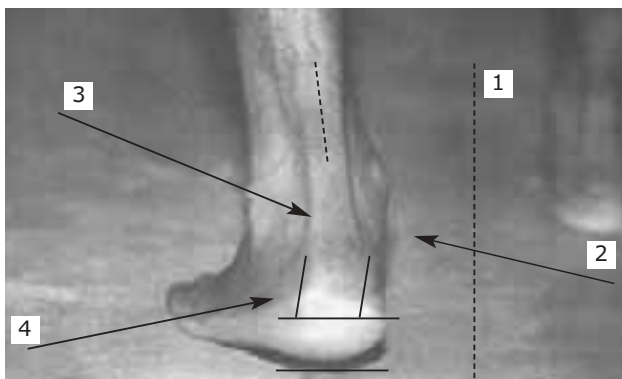
- The unstable 1st metatarsal will dorsiflex in response to ground reaction forces. It therefore becomes less competent leaving the 2nd or 3rd metatarsal to bear greater loads than they are designed for.

- In ideal gait, during propulsion, the hallux will dorsiflex around the 1st metatarsal head, but if the 1st metatarsal is incompetent this action cannot be facilitated. Instead of dorsiflexing around the 1st metatarsal head, the hallux impinges on the joint surface. If insufficient dorsiflexion for propulsion is not found at the MPJ dorsiflexion is forced at the hallux IPJ.

The most significant effects of propulsive forces when the subtalar joint is excessively pronated are:

- Tissue stress beneath the 2nd or 3rd metatarsal heads.
- Tissue stress beneath the IPJ of the hallux.
- Buckling of the toes.
- Hallux limitus (rigidus).
- Hallux abducto valgus.
- Plantar fasciitis.

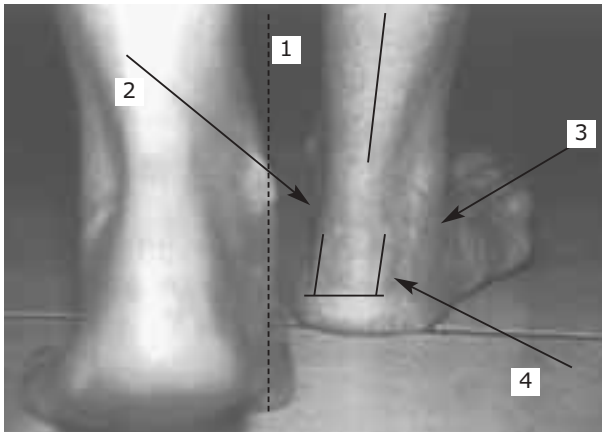
**Note:** Other problems, notably in the knee, are also excited or exacerbated by aphasitic STJ pronation.



**FIGURE 12-2** Abnormal Foot Function- Aphasitic STJ Pronation: If the STJ is still pronated during propulsion the foot will be too mobile to become a rigid lever. The metatarsals will not be stable. The first metatarsal cannot be plantarflexed effectively. 1. Mid line of the body, 2. Medial bulging and flattened medial arch, 3. Curve in the Tendon Achilles, and 4. Everted heel.

### Aphasic STJ Supination

Aphasic supination (Fig. 12-3, 14-4c) is a less common anomaly but when it does occur it is far more problematic. For the insensate foot the most serious problem is related to the early and sustained application of force beneath the fourth or fifth metatarsal heads. A further problem is that the first ray may become excessively plantarflexed (resulting in a cavus foot). In such circumstances the tissue beneath 1st metatarsal head is highly vulnerable. A hallux flexus deformity may also develop which exposes the distal aspect of the hallux to stress.

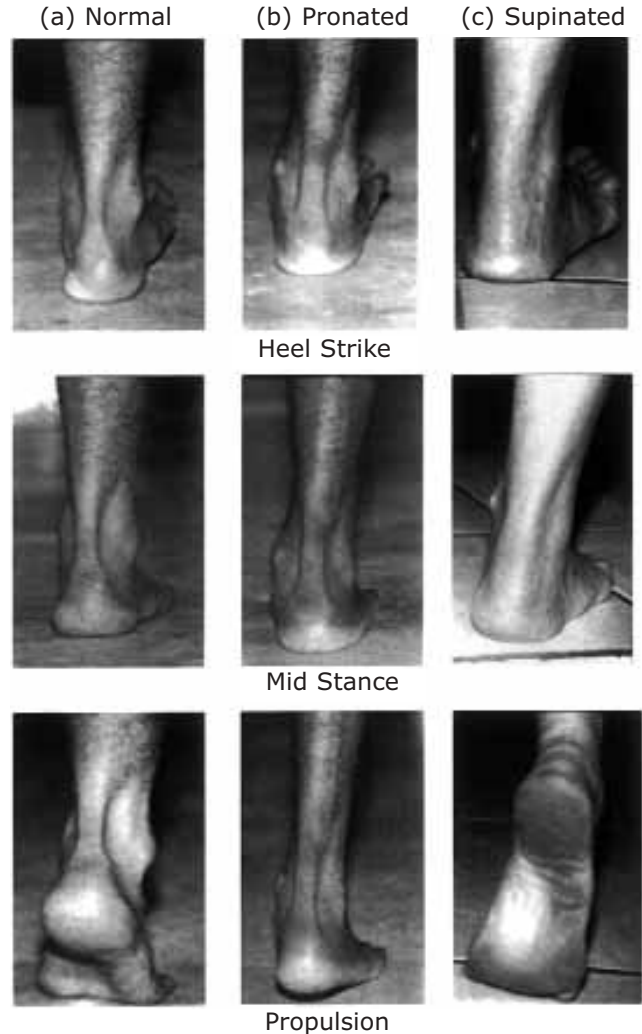


**FIGURE 12-3:** Abnormal Foot Function – Subtalar Joint Supination at Heel Strike: STJ supination at heel strike will result in poor shock absorption. It will also lead to Limited forefoot dorsiflexion and hence early loading of the forefoot. 1. Mid line of the body, 2. High medial arch, 3. Slight bulging beneath lateral malleolus, and 4. inverted heel.

### Factors That Cause Pathomechanical Foot Function

Compensatory STJ Pronation is commonly a result of:

- Tibial Varum
- Internal Tibial or Femoral Torsion
- Inequality of Limb Length



**FIGURE 12-4:** A comparison of normal foot function (a) with aphasic subtalar joint foot function (b and c)

(a) Normal Heel Strike: STJ pronates to allow shock absorption; Normal Mid Stance: STJ assumes neutral position to give stability and to prepare the foot for propulsion; Normal Propulsion: STJ supinates to allow sound propulsion.

- Forefoot Varus
- Plantarflexed 5th Metatarsal
- Ankle Equinus
- Tibial / Genu Valgum
- Obesity

**Aphasic Supination may result if the following abnormalities are not compensated:**

- Forefoot Valgus
- Rearfoot Varus
- Tibial Varum
- Internal Tibial or Femoral Torsion
- Forefoot adductus

**Aphasic Supination may also result if the following abnormalities are compensated:**

- Tibial / Genu Valgum

There are also abnormalities of a neuropathological origin that will result in aphasic supination of the STJ. Most notable is foot drop, a consequence of lateral popliteal dysfunction.

**Essential Features of Concern to be Excluded Through a Biomechanical Assessment:**

- Are there any structural abnormalities intrinsic or extrinsic to the foot that may affect foot function?
- Are there any restrictions or excesses in range of motion at significant joints?
- Is the timing of kinetic events during locomotion a reflection of the ideal model?

Analysis of the findings should give an understanding of the likely outcomes for a foot that does not meet ideal criteria. The insight thus gained provides the rationale for an appropriate orthotic intervention.

## **EXAMINE FOOT STRUCTURE**

### ***STJ Neutral Position – A Reference for Foot Examination***

When a foot is not bearing weight, and is relaxed, it will rest in plantarflexion and slight

inversion. This is not an appropriate reference position for examination because it is not a reflection of the position the foot assumes during weight bearing.

To be able to ascertain how the foot may interact with the supporting surface it is imperative to examine it from the ideal perspective: i.e. with the subtalar joint in neutral position. In an ideal foot that is not weight bearing, if the STJ is neutral it can be assumed that soft tissues will draw the sections of the foot into model alignment: i.e.

- The forefoot and the heel will be parallel in the frontal plane.
- The forefoot will be at 90° to the leg.

If the foot is passively held with the subtalar joint in its neutral position and it is found that the criteria given above are not as expected, it can be assumed that the foot is abnormal.

Having manipulated the foot into STJ neutral position:

### **Right Foot**

1. With the patient seated and the leg supported, straighten the leg so that the patella is horizontal with the ground.
2. Check the areas just beneath the malleoli. (There will probably be a slight bulge just beneath the lateral malleolus and a dip beneath the medial malleolus).
3. Using the left hand place the thumb over the fourth and fifth metatarsal heads.
4. Using the thumb of the left hand to control the foot, gently but firmly dorsiflex the foot until resistance is registered.
5. Slowly abduct and adduct the foot a few times noticing how the curves beneath the malleoli change. With abduction, a bulge will develop beneath the medial malleolus. As you adduct the foot, a bulge will develop beneath the lateral malleolus.

6. Slowly adjust the position of the foot until the curves under the malleoli are even: i.e. no bulge beneath either of the malleoli.

### Check

The leg is straight and the knee is neither internally or externally rotated.

The foot has been dorsiflexed to resistance.

There are no bulges beneath the malleoli.

If these criteria have been met, it is likely that the foot is in a position where the subtalar joint is neutral.

*The same procedure should be carried out for the left leg, but using the right hand to manoeuvre the foot.*

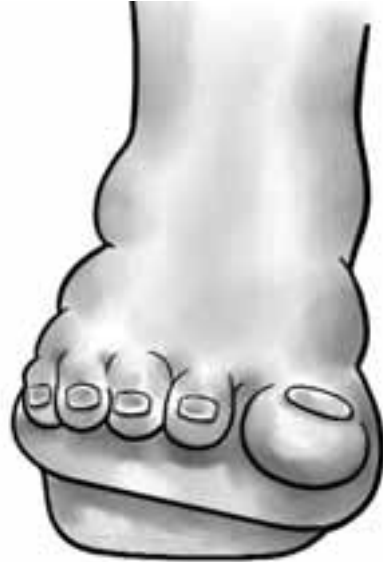## FOREFOOT ABNORMALITIES

With the thumb placed beneath the fifth and fourth metatarsal heads the foot can be held in subtalar neutral position.

- a. The foot should be viewed from the forefoot to the heel (frontal plane) to ascertain whether the plane in which the forefoot lies is parallel with that of the heel.
  1. If the forefoot and heel are parallel the indication is that the forefoot lies in the correct frontal plane position.
  2. If the forefoot appears everted, relative to the plane of the heel the indications are either:
    - Forefoot valgus deformity (Fig. 12-5) (a fixed osseous deformity of the mid tarsal joint)
    - Plantarflexed first ray (gives the appearance of an everted forefoot)

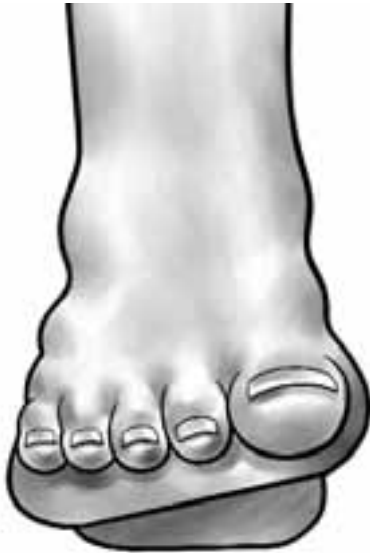An anaesthetic foot with an everted forefoot can be susceptible to the development of ulcers at:

- the first metatarsal head
- the toes

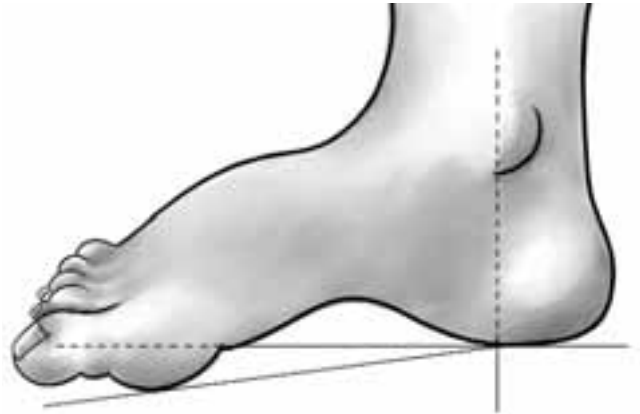


**FIGURE 12-5** Forefoot Valgus: A frontal plane abnormality where the forefoot is everted relative to the heel.

3. If the forefoot appears inverted relative to the plane of the heel, the indications are either:
    - Forefoot varus (Fig. 12-6) (a fixed osseous deformity of the mid tarsal joint).
      - Plantarflexed fifth ray (gives the impression of an inverted forefoot).
      - Supinatus (a soft tissue adaptation to stress imposed by aphasic STJ pronation).
- An anaesthetic foot with an inverted forefoot can be susceptible to the development of ulcers at:
- The lateral aspect of the forefoot (with forefoot varus).
  - The second or third metatarsal head (with supinatus).
  - The IPJ of the hallux (with supinatus).
  - The fifth metatarsal head (with plantarflexed fifth ray).
  - The toes.



**FIGURE 12-6** Forefoot Varus: A frontal plane abnormality where the forefoot is inverted relative to the heel.



**FIGURE 12-7** Forefoot Equinus: A sagittal plane abnormality where the forefoot is plantarflexed relative to the heel.

b. With the foot in subtalar neutral position it should be viewed from lateral side to ascertain whether the forefoot is plantarflexed relative to the heel.

1. If the forefoot and heel are positioned such that the forefoot is not plantarflexed (the fore foot should be at approximately  $90^\circ$  to the leg) the indication is that the foot is correctly aligned in the sagittal plane.
2. If the forefoot is plantarflexed relative to the heel (greater than  $90^\circ$  from the leg) the indication is that the foot has a forefoot equinus deformity (on weight bearing the foot will present with a noticeable high medial arch and claw toes) (Fig. 12-7).

An anaesthetic foot with a forefoot equinus is very vulnerable and is susceptible to the development of ulcers across the entire forefoot.

- c. With the foot in subtalar neutral position view the foot from the plantar aspect. If the entire forefoot inclines towards the centre line of the body, the abnormality is a forefoot adductus.

An anaesthetic foot with a forefoot adductus is susceptible to developing ulcers at:

- The hallux
- The first metatarsal head
- The styloid process

### JOINT EXAMINATION: GENERAL PRINCIPLES

- Localise the opposing bones that constitute the joint of interest.
- Firmly immobilise the proximal bone with one hand.
- With the other hand, manipulate the distal bone to establish the range and quality of movement.

Note whether the joint allows:

- Movement in the expected direction.
- Too much or too little movement in the expected direction.
- Smooth transition of the bones (no crepitus or obstruction).



### **The lesser Toes**

The most important function of the lesser toes is to stabilise the metatarsals during the propulsive phase of gait. If the toes are dorsiflexed and plantarflexion at the metatarsal phalangeal joints is not possible, the tissue around the metatarsal heads will be vulnerable to high pressure and shearing stress (if the toes are extended, the metatarsal heads will be forced into plantarflexion, the vulnerability will be exacerbated because the loss of toe function will leave the metatarsals unstable against reaction forces). If a toe is found to be hypermobile (due to dislocation or joint destruction) the metatarsal head that the toe articulates with will be vulnerable to the effects of shearing stress.

### **Method of examination**

With one hand stabilising each metatarsal in turn, the opposing proximal phalanx of each toe is firmly held and passively dorsiflexed.

All toes should demonstrate 90° of uninterrupted passive dorsiflexion.

### **The Hallux**

The function of the hallux affects the entire chain of kinematic events that determines human gait and posture. Its crucial role is reflected in the complexity of the anatomy that supports it. Although one of the major functions of the hallux is to stabilise the first metatarsal, it should never be considered to be merely a large toe. The function of the hallux is profoundly affected by the action of the STJ and the restricted movement that may be found on examination may suggest poor action at the STJ.

### **Method of examination**

With one hand stabilising the first metatarsal, the proximal phalanx of the hallux is firmly held and passively dorsiflexed.

Sixty degrees of uninterrupted passive dorsiflexion at the 1st MPJ is required for effective locomotion. A finding less than 60°, but more than no dorsiflexion indicates hallux limitus. Absence of dorsiflexion indicates hallux rigidus. Either condition indicates the necessity to conduct a functional examination of subtalar joint action.

### **The subtalar joint examination**

Because the STJ has an axis that extends through all three planes, the movement that the joint facilitates is triplanar (pronation and supination). The implication is that inversion and eversion of the foot (the most prominent components of STJ movement) must also be accompanied by movement in the other two planes simultaneously: i.e. if the foot is inverted it will also be slightly plantarflexed and adducted (STJ will be supinated) whilst eversion of the foot requires that the foot is also slightly dorsiflexed and abducted (STJ is pronated).

It has been established that 18° of motion around the STJ is required for efficient gait.<sup>5</sup> Studies have demonstrated that goniometric measurement of subtalar movement is not generally reliable because of poor repeatability. However, as a practical guide for joint examination, it should be noted that two thirds of the motion normally available at the STJ is in the direction of inversion with one third of the motion allowed for eversion (accepting that there will be movement in the other two planes simultaneously).

### **Method of examination**

With the subject seated and the leg supported (in neutral position), stabilise the leg at the ankle joint with one hand and grasp the calcaneus with the other. Evert and invert the calcaneus around its articulation with the talus.

Note the quality of movement (no crepitus) and whether the ratio of movement is as expected (2:1 in favour of inversion).

Also note the extent of movement: i.e. if the joint allows excessive motion (palpably more than 18°) or limited motion (stiff joint allowing very little frontal plane motion)

A STJ that allows excessive motion indicates that the foot will be hypermobile and may be unstable during gait. If the STJ allows limited motion the implication is that the foot will be rigid and may not be able to adapt adequately to challenging terrain or compensate for any distal structural abnormalities.

Generally, a rigid foot is vulnerable at sites where foci of high pressure cause tissue breakdown (usually on the lateral aspect of the foot). A hypermobile foot can be vulnerable to shearing stress and skeletal incompetence leading to a poor distribution of forces (see the Weight Bearing Foot).

### **The Ankle joint**

With the axis of the ankle joint lying parallel to the transverse plane and almost parallel to the frontal plane, the only clinically important movement available at the joint is dorsiflexion and plantarflexion. The functional requirement of the ankle joint is that it should allow at least 10° of dorsiflexion to facilitate efficient gait.

### **Method of Examination**

With the subject seated and the leg supported (in neutral position), stabilise the leg with one hand and position the ball of the hand under the forefoot. Move the foot through dorsiflexion and plantarflexion to check the quality of movement. Although it is possible to measure the range of motion at the joint with the limb non-weight bearing the method is not advised. The reasons are:

- The gastrocnemius may counter any force to dorsiflex the foot. It is a very

powerful muscle and the examiner may not be able to overpower it sufficiently to record the actual extent of dorsiflexion available.

- There is also some dorsiflexion available at the midtarsal joint which is made possible if the forefoot is inverted. It is difficult to avoid inverting the forefoot whilst dorsiflexing the foot at the ankle joint. There is a danger therefore of recording dorsiflexion that is greater than that actually available at the ankle joint in isolation.

Dorsiflexion is measured as a reduction in the angle between the leg and the foot and is therefore measured from a lateral perspective. A point is marked on the mid point of the head of the fibula and another on the mid point of the lateral malleolus, a line is drawn joining these two points.

The subject is then asked to stand approximately 2 feet from a wall with feet apart (approximately 12 inches between malleoli) and slightly adducted. With the knees, hips extended and the back straight, the subject is directed to rest against the wall, supported by extended arms. Then bending the arms, but keeping the knees and hips extended and the back straight, the subject is directed to lean toward the wall. The point where the heel starts to lift indicates maximum dorsiflexion of the ankle.

With the short arm of a tractograph on the floor, the other arm is aligned parallel to the fibula bisection. The angle measured at the position immediately before the heel lifts is noted as maximum dorsiflexion.

### **THE WEIGHT BEARING FOOT**

It is not sufficient to limit an examination of the foot to a non-weight bearing examination because foot function can be compromised by

extrinsic factors. Extrinsic factors can subtly affect the manner in which the foot interacts with the ground. Although such subtle affects do not usually make the foot vulnerable to acute damage they can have a profound effect on the distribution of forces. When the mechanics of the foot are compromised mild but unrelenting repetitive stress can lead to tissue fatigue and breakdown.

A principle objective is to gauge an impression of the typical alignment of the subtalar joint at mid stance. Ideally the subtalar joint should be neutral at mid stance, if it is pronated, or supinated, the indication is that the foot is not functioning as it ought.

If the STJ is very pronated the foot will be unstable (see Aphasic STJ Pronation) if the STJ is very supinated the foot will be compromised through rigidity (see Aphasic STJ Supination).

### **How Much Is "Very Pronated" Or "Very Supinated"?**

As a general rule, if just by viewing the subtalar joint is obviously pronated then it is most likely that it is, in fact, very pronated. Likewise, if the foot looks as though the subtalar joint is obviously supinated, then it is most likely to be supinated further than it should be.

*(See Figure 12-4: A Comparison of Normal Foot Function with Aphasic Subtalar Joint Foot Function).*

### **Method of Examination**

Establish the approximate alignment of the STJ at mid stance:

- 1 Direct the subject to walk on the spot.
- 2 After 10 seconds ask the subject to stop.
- 3 Suggest the subject should relax and look straight ahead with arms hanging loosely at his/her sides.

(The examiner should take care to ensure that curious subjects do not turn their heads to observe the examiner. Rotations

of the trunk will cause one STJ to pronate whilst the other supinates).

4. The examiner takes a position behind the subject and examines the foot for indications of either pronation or supination.

### **The Pronated Subtalar Joint**

#### **Main Signs**

1. The heel will be everted.
2. There will be a "bulge" under the medial malleolus.
3. There will be a "dip" under the lateral malleolus.
4. The Achilles tendon may be bowed.
5. The medial arch will be flattened.
6. The feet will probably be abducted.

*(See Figure 12-2: Abnormal Foot Function – Aphasic STJ Pronation)*

A subject with an obviously pronated STJ is vulnerable to ulceration beneath:

- The second or third metatarsal head.
- The IPJ of the hallux.
- The lesser toes.

Calcaneal spurs and fasciitis are have also been attributed to aphasic STJ pronation an effect of which is strain on the plantar aponeurosis.

### **The Supinated Subtalar Joint**

#### **Main Signs**

1. The heel will be inverted.
2. There will be a slight "bulge" under the lateral malleolus.
3. There will be a "dip" under the medial malleolus.
4. The medial arch will be high.
5. The feet may be adducted.

*(See Figure 3: Abnormal Foot Function – Aphasic STJ Supination)*

A subject with an obviously supinated STJ is vulnerable to ulceration beneath:

- The fourth or fifth metatarsal head.
- The styloid process.
- The apex of the hallux.

Subjects demonstrating STJ supination are also vulnerable to lateral ankle sprains.

## FOOT FUNCTION AS A COMPONENT OF GAIT ANALYSIS

Although a reasonably good impression can be gained by a static examination of a weight-bearing subject, it is only really by observing gait that the extent and timing of phasic activity can be assessed. (The normal phasic activity of the STJ was described earlier - see Normal and Abnormal Foot Function).

### Ankle Joint

The essential feature to note is the timing of plantarflexion. The weight-bearing foot should only start to plantarflex after the contralateral foot has swung passed the stance leg. Plantarflexion at any other phase will compromise the foot.

The two major conditions that will result in aphasic plantarflexion are:

- Foot drop (due to lack of anterior / lateral muscle activity the foot is unable to dorsiflex).
- Equinus (In normal gait the heel will only lift as the contralateral foot passes the stance foot. If the triceps surae is tight, or the tendo Achilles is contracted, stretch receptors in the TA will activate muscle contractions early in the stance phase of gait. The effect can be seen as an early heel lift as the foot responds to a plantarflexion force imposed by the triceps surae.)

The loading pattern of the “dropped foot” predisposes it primarily to damage on the lateral border of the foot.

The early heel lift caused by ankle equinus causes the foot to be vulnerable to excessive shearing stress across the forefoot. The damaging affects of early heel lift are often compounded by STJ pronation.

### Subtalar Joint

The essential features to note are the positions of the STJ:

- at heel strike (STJ should pronate on contact with the ground, not before)
- at mid stance (STJ should not be pronated or supinated)
- at propulsion (STJ should be supinated)

*(See Figure 12-4: A Comparison of Normal Foot Function with Aphasic Subtalar Joint Foot Function).*

## CONCLUSION

- If the STJ is pronated at any time other than immediately after heel strike the foot will be compromised through instability.
- If the STJ is supinated at heel strike and does not pronate the foot will be compromised through rigidity and early forefoot loading.
- Primary abnormalities of foot structure may also compromise the integrity of the foot.
- A biomechanical examination of the structure and function of the foot may enhance treatment decisions.

**Abduction:** Moving the foot away from the mid-line of the body.

**Adduction:** Moving the foot toward the mid-line of the body.

**Inversion:** Tilting the foot so that the plantar surface faces toward the mid-line of the body.

**Eversion:** Tilting the foot so that the plantar surface of the foot faces away from the mid-line of the body.

**Pronation:** Movement including eversion, abduction and dorsiflexion of the foot. Results in the flattening of the arch and elongation of the foot.

**Supination:** Movement including inversion, adduction and plantar flexion.

Results in heightening of the arch and shortening of the foot.

## REFERENCES

1. Bøsjen-Møller F. and Jorgensen U: The plantar soft tissues: Functional and clinical applications. In Jahhs, M.H (Ed.) Disorders of the foot. WB Saunders and Co, Philadelphia, 1982
2. Dananberg HJ: Gait cycle as an aetiology to chronic postural pain. Part 1 Functional hallux limitus J Am Pod Med Ass 83:433-441, 1993
3. Elftman H: The transverse tarsal joint and its control. Clin Orthop 16:41-45, 1960
4. Mann RA: Overview of foot and ankle biomechanics. In Johhs MH: Disorders of the Foot. WB Saunders, Philadelphia, 1991
5. Manter JT, Distribution of compression forces in the joints of the human foot. Anatom Rec 96 313-321, 1946
6. Root ML, Orien WP, Weed JH: Abnormal Function of the Foot. Clinical Biomechanics Vol. 2. Clinical Biomechanics Corporation, Los Angeles, 1977
7. Thomson CE, Campbell RH, Wood AR, Rendall GC: Adult Foot Disorders. In Lorimer, D (Ed) Disorders of the Foot. Churchill Livingstone, Edinburgh, 2002



## Neuropathic Feet

• G. WARREN

*“Without pain we destroy ourselves. Pain is the most important natural therapeutic. ....Pain makes us rest and protect the affected area, allowing healing to occur”.*<sup>14</sup> Hilton, 1863

### INTRODUCTION

Neuropathic feet can be defined as feet with secondary impairments due to motor, sensory or autonomic nerve function impairment.<sup>7</sup> The main secondary impairments are plantar ulceration and neuropathic bone disintegration. The primary and secondary impairments may be clinically obvious, or, as yet unsuspected by patient or health care professional. The patient with neuropathy is often unaware of trauma because pain, the natural protective mechanism, is absent. Pain is an unlikely cause of presentation for diagnosis or treatment. Many clinicians do not take seriously complaints of pins and needles or burning sensations that these patients sometimes report. These are often the patients' only means of voicing that there might be a problem as these patients rarely complain of pain. The numbness, 'heaviness' or 'deadness' of an anaesthetic hand or foot, however, can be a real discomfort.

Symptoms that 'alert' the patients' minds are: 1) 'paraesthesia', indicating a change in nerve function or an early warning of a pending ulcer. 2) motor impairment such as weakness in dorsiflexion of the foot or the development of claw toes. Patients are unlikely to report any impairment associated with autonomic nerve function impairment.

### **At the Time of Diagnosis**

Often patients with leprosy and diabetes are first diagnosed with the disease or a neuropathy when there is said to be sensory loss or a 'non-healing' ulcer.<sup>10</sup> Learn to observe patients as they walk into the clinic. If there is a normal gait in the presence of an ulcer it is obvious that sensory impairment is present. If the foot is very cold to touch there is probably also autonomic dysfunction. Once the nature of the neuropathy is known it should be determined if any therapy is indicated to slow down or reverse the neuropathy.

Patients with multiple deformities who have obvious loss of pain perception may well be labelled 'leprosy' in leprosy endemic countries. It is essential that (para) medical workers know about the medical conditions that may result in neuropathic limbs. The only satisfactory method of long term help for patients with diminished pain perception of limbs is to involve the patient in 'self care' and injury prevention. This is best commenced at diagnosis.

For social reasons a clinician in a leprosy endemic country may deliberately not want to tell the diagnosis or he may not have been taught to make a diagnosis. This may result in inadequate treatment till obvious deformity or irreversible neuropathy occurs. Some patients may only report symptoms that will not reveal leprosy as a cause.

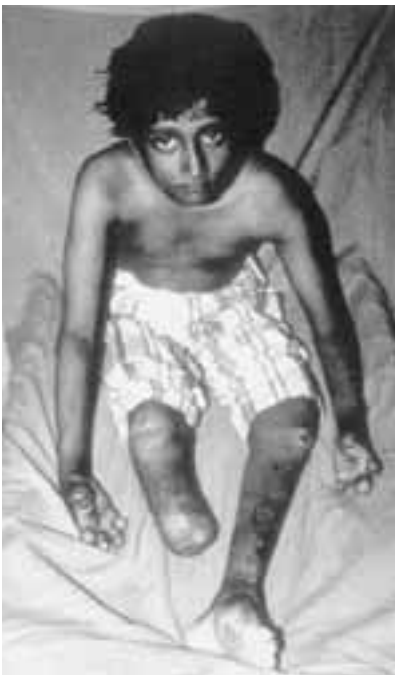Neuropathy is not uncommon, but is frequently not recognised and hence the patient may receive inadequate treatment. Some people are born with a neurological impairment that may not become obvious for many years.

## 148 Surgical Reconstruction & Rehabilitation in Leprosy

Others develop neuropathy as the first sign of a disease like diabetes or secondary to diseases such as acute infection or malignancy. In leprosy, neuropathy may be a presenting sign or it may develop during or after treatment.<sup>20</sup>

### **Presentation of Neuropathy**

A motor impairment often attracts immediate attention. The patient may have a drop foot or clawed toes, which results in an altered gait. There may also be ulceration, or thick callus that causes no discomfort because of the sensory impairment. The patient may have paralysis or loss of sensation in some other area of the body, with the foot not previously presenting a problem. Be aware of shortened fingers or toes. Look also for burns scars or signs of trauma on all limbs. These impairments (when painless) in leprosy endemic countries are often accepted as leprosy. Be aware of the possibility of congenital indifference to pain (Fig. 13-1).<sup>16</sup>



**FIGURE 13-1**  
Young boy  
with congenital  
absence of  
pain.

Patients are not likely to present for treatment with autonomic impairments only, though dry cracking skin, lack of hair growth, and capillary lability may be present especially in patients with signs of neuropathy affecting motor or sensory nerves.

### **EXAMINATION AND RECORDING OF NEURAL FUNCTION**

It is recommended that at the time of diagnosis a full neurological examination be done to assess the extent and severity of neural impairment (see appendices A-B). This should at least include a basic *clinical* motor and sensory assessment.<sup>7</sup> Many patients with diabetes have already some reduction in nerve conduction velocity at diagnosis.<sup>12</sup> Clinical testing should be repeated at regular intervals, the frequency depending on the aetiology and expected course of the disease. The standard instrument of choice for testing sensory impairment is nylon monofilaments.<sup>2,5</sup> This tests only one modality and while a useful tool for recording touch perception, it may not be related to impaired pain or thermal perception. In one study monofilaments were supplied to patients with diabetes for them to assess the sensory status of their feet.<sup>4</sup> Sensory loss, previously undetected by providers, was reported by 23 out of 145 subjects. Self-administered tests, whenever feasible, provide patients an opportunity to share in the responsibility for preventing foot problems, but should not replace routine evaluation by a professional.<sup>4</sup>

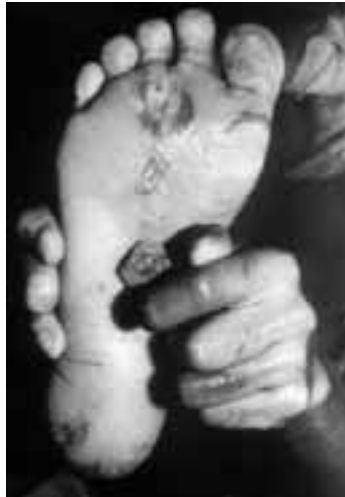### **Skin Care—Self Care (see also Appendix C)**

Because of the *lack of pain perception*, the limbs are prone to injury and trauma. To prevent permanent impairments a patient should practice self-care. The time of diagnosis is the time to start self-care. Skin care is important in the pre-

vention of (re) ulceration and includes the trimming of scar tissue and callus. A daily routine should include inspection of the skin for abrasions, blisters, swelling and redness (Figs. 13-2-4). Hydration of the autonomically deprived skin (soaking) and oiling is important to maintain skin suppleness. Persons 'at risk', with sensory impairment, that have remained ulcer free



**FIGURE 13-2** Self-care: Foot inspection.



**FIGURE 13-3** Deformed hands can still 'care' for anaesthetic feet.

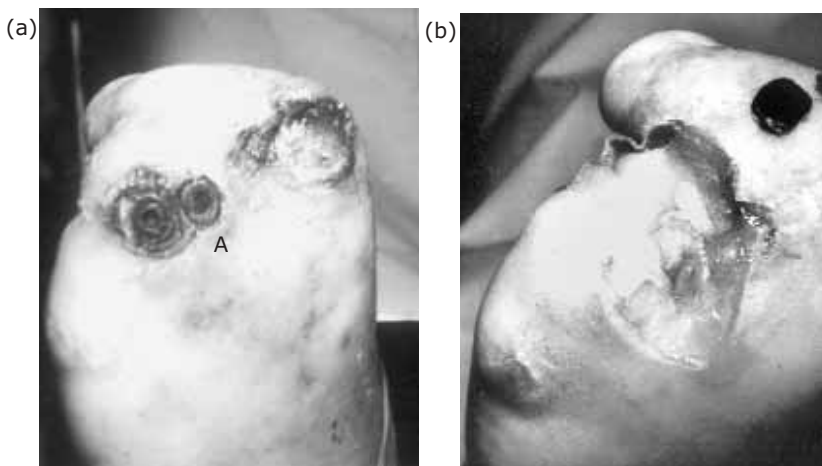
for a long time are usually the best facilitators for patients that need to learn and understand about skin care.

'Hot-spots' are localised areas of increased temperature, indicating an underlying problem, which needs to be addressed. They can be detected by the patient.<sup>15</sup> Hot-spots are of such significance in the pathogenesis of Neuropathic Bone Disintegration (NBD) that a few paragraphs will be devoted to this topic.

**Hot spots:** warning sign of 'break-down'.

A neuropathic limb may feel cold but still has the ability to become hyperaemic after trauma or infection. Areas of localised heat and swelling are known as 'Hot-spots'. Once neuropathy has developed the A-V shunt may become more pronounced over a period of months or years. The foot feels cold but the veins may be engorged. This is not due to poor circulation but to the absence of the neurological control of the capillary lability. Patients should learn how to look for hot spots and understand that their presence indicates that something needs to be done *now!*

The natural physiologic responses to trauma are pain, heat, swelling and redness. When neuropathy compromises pain perception the other three signs become more important. A 'Hot Spot' is an easily detected sign of deep tissue trauma. Most people can detect temperature differences of 2 degrees centigrade, and with training 1.0-1.5 degrees C. Often 'Hot Spots' will show a difference of 3-4 degrees when compared to other parts of the foot or preferably the same area on the contralateral foot.



**Figure 13-4** **a.** The patient arrived in the clinic saying his feet were "no problem". On examination a hard plaque of callous was found (marked A). **b.** After a thorough soak and scrape the plaque of callous was placed on the clean foot beside the ulcer which had occurred under the callous and first became obvious when the callous was removed.

Swelling may not be prominent and swelling alone without heat may be due to vascular problems. If a patient had an ulcer or has a bone deformity there may be excessive pressures on these areas. The patient needs to learn to monitor these sites each day, preferably at night before going to bed.

### NEUROPATHIC BONE DISINTEGRATION

In the sensate foot any trauma will cause the person to alter the use of the foot, or make the person rest the foot.<sup>14</sup> This may be just enough to protect the limb and allow the tissues to heal. If there is a fracture, pain attracts the attention to prevent any displacement of bones. However, in the foot with reduced pain sensation the discomfort may not be great enough to encourage protection (Fig. 13-5).

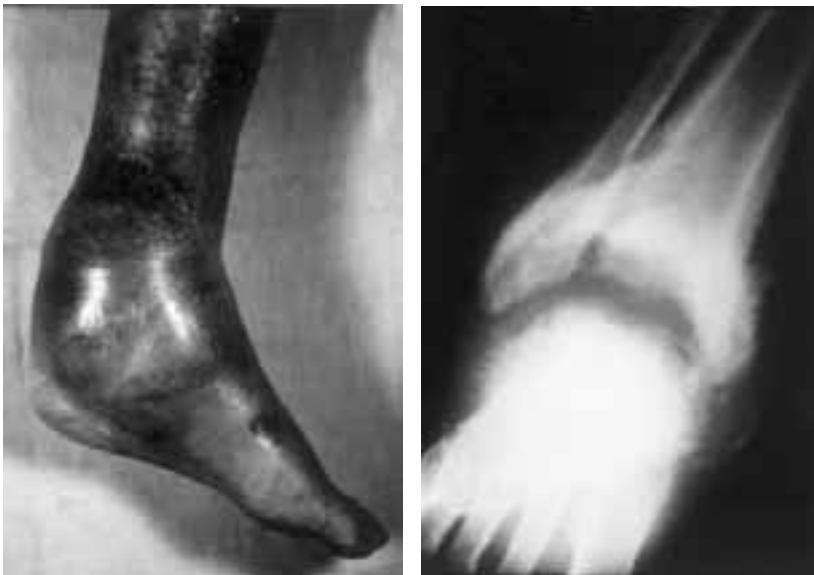As the bones decalcify they are more liable to further trauma. Commonly the decalcified bones rub on each other till they literally frag-

ment. This is termed *Neuropathic Bone Disintegration or Disorganisation (NBD)*. Alternately, the softened bones impact during weightbearing and the body weight rests on relatively small localised osteopaenic areas, such as the talo-navicular or Lisfranc areas during take off (Fig. 13-6). This is still neuropathic bone *disintegration* but as fragments of bone are not seen some clinicians prefer to call it *disorganisation*.

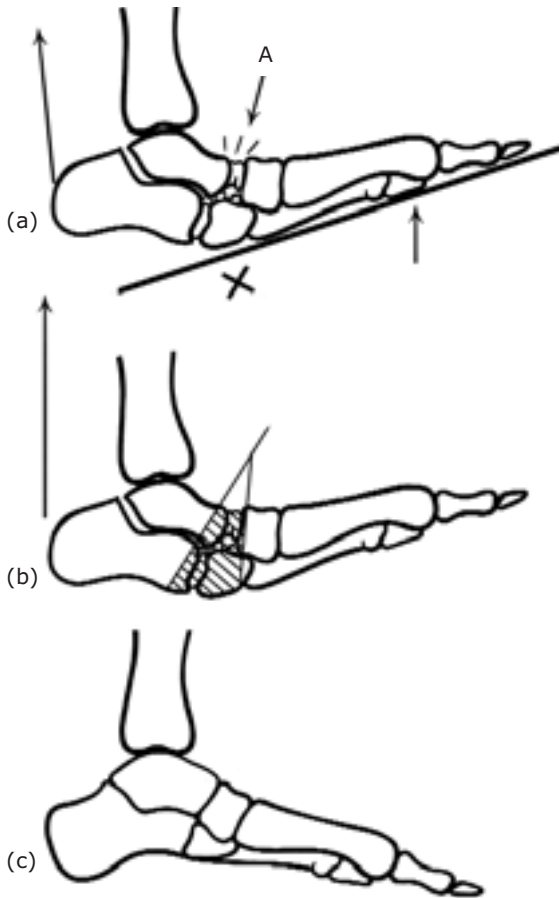
Often this is called 'Charcot foot' which unfortunately, through tradition, usually conveys the message that treatment is not effective. This is a pity when it is just a neglected fracture that has not been given the chance to heal. Figure 13-7 shows a foot in which the bone fractures were in the cuneiform area. The bone has now deformed and partly disintegrated but will still heal, in whatever shape it is maintained in the cast, if immobilised for an adequate length of time. Neuropathic feet often feel cold but a fractured area will become warmer than normal. This shows that the blood supply is adequate, when needed, for tissue maintenance and repair.

### Clinical Findings in Neuropathic Bone Disintegration

Clinically there may be very few findings in NBD. There may be swelling, heat and redness but usually no pain. The end result is often deformity but by that time the heat and swelling may have gone. A cool non-swollen foot may present with a deformity, that may be fixed or hypermobile, indicating that

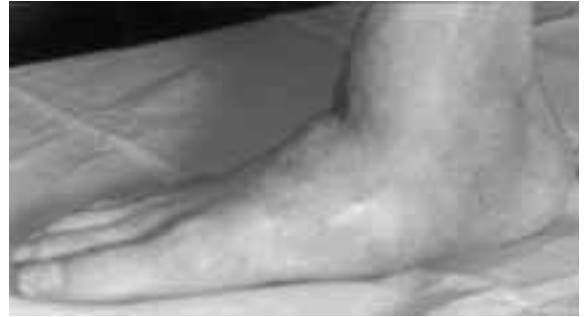

**FIGURE 13-5 a.** This hot, swollen, painless foot was diagnosed as an abscess. **b.** The radiograph showed it as a well-advanced disintegrating bone lesion. Attempt to drain an abscess was made before the first radiograph was taken. An advanced neuropathic disintegrating ankle joint on which the patient was walking without problems!



**FIGURE 13-6** Diagrams to show how damaged bones on the dorsum of the foot may be impacted by the force of walking, producing a plantar deformity, or 'boat shaped' foot. **a.** The impacted navicular is indicated (A). The stress of walking has caused mid-foot flexion producing a boat-shaped foot. **b.** A wedge is removed as indicated by the broken lines and on fusing this has produced the functional foot shown in **c.**

fracture and deformity has occurred, but that the bone is now healed and that it will not progress further. In many leprosy programmes radiographic examination is not available or affordable. Feet with NBD can be managed clinically, without radiographic control. If these lesions are treated with a Total Contact Cast (TCC) the patient can continue to walk while



**FIGURE 13-7** A plantar bulge deformity frequently seen in diabetes. This is usually due to bone disintegration.

the fractures and any associated disintegration, or other tissue pathology, heals. If the patient continues to walk without a cast there is likely to be progressive disintegration and deformity. The hot spot usually occurs in association with some osteopaenia and to continue to walk on a hot swollen foot is asking for a stress fracture to occur.

*If a (suspected) neuropathic foot has a persistent hot spot it should be treated as bone disintegration till proven otherwise.*

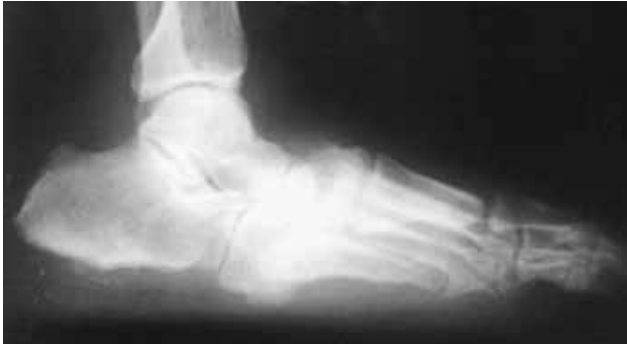### **The Stages in Neuropathic Bone Disintegration**

There are three distinct presentations in NBD.

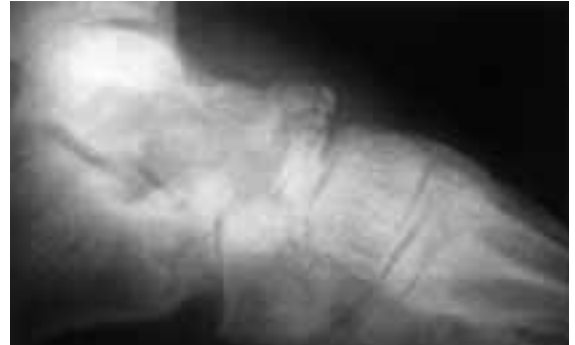**First stage:** There may be a slight degree of heat and swelling. The patient may be unaware of a problem. A radiograph may sometimes show a fracture, a disintegrating bone lesion, or a stress fracture (Fig. 13-8, 13-9). These may only be visible 6-10 weeks following the 'traumatic' event. The situation may persist for weeks or months until the heat and swelling are more obvious or deformity and/or instability develops (Fig. 13-5).

Sometimes, after a lengthy period of heat and swelling, the radiograph may show areas of sclerosis and lucency but no obvious disintegration (Fig. 13-10). This patient had a fracture





**FIGURE 13-8** Radiograph showing a fracture dislocation of the cuneiform area that would produce a similar external appearance to Fig. 13-7. Note bulge on plantar surface.



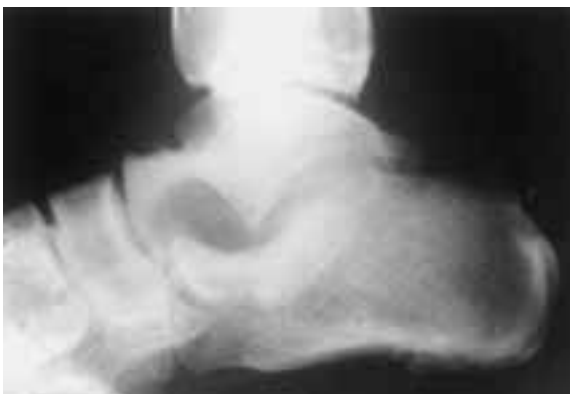**figure 13-9** Early disintegrating lesion of navicular; clinically only mild heat and swelling present.

in the body of the talus, which was not recognised. The patient was allowed to continue to walk, while given repeated doses of antibiotics. The bone slowly deformed and in a few months the talus had collapsed (Fig. 13-11). Treatment for 'osteomyelitis' was continued till 5 years later there was no ankle joint left (Fig. 13-12). Then it was reported that the patient had a 'Charcot joint' requiring amputation. However, the application of a TCC resulted in full bone healing.

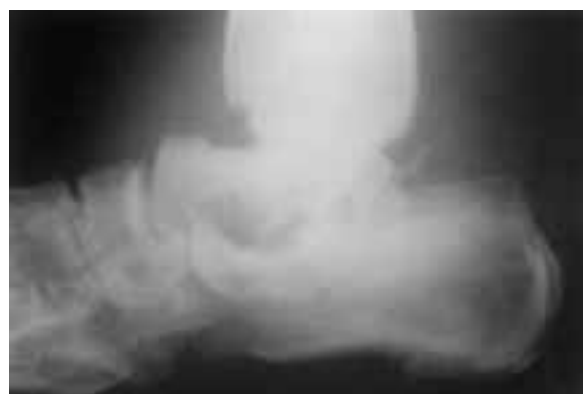**Second stage:** The foot has developed deformity and demonstrates signs of inflammation and

ongoing destruction. The foot may become hypermobile. Marked disintegration and progressive deformity of the talus is shown in Figure 13-13a. Radiographic examination may show very osteopaenic bones. The decalcification may be gross – the skeleton appearing as a mere shadow of itself (Fig. 13-13, 13-14).

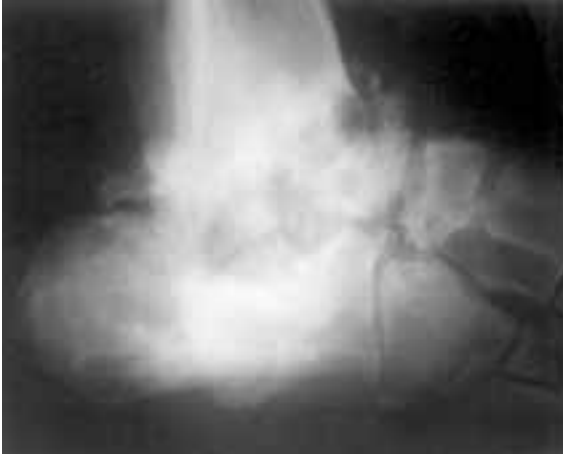The deformity that occurs predisposes to local ulceration, which can result in infection. This is often a complication of the deformed neuropathic foot. Midfoot deformity and osteopaenia are shown in Fig. 13-15. It is difficult to tell how much of the deformity is the result of infection and how much due to



**FIGURE 13-10** A hot swollen painless foot of a patient with diabetes. The swelling had persisted for two years. This radiograph shows increased sclerosis and lucency.



**FIGURE 13-11** The same foot (Fig. 13-10) 18 months later after long treatment with antibiotics but no restriction on walking. The foot was still hot and swollen.

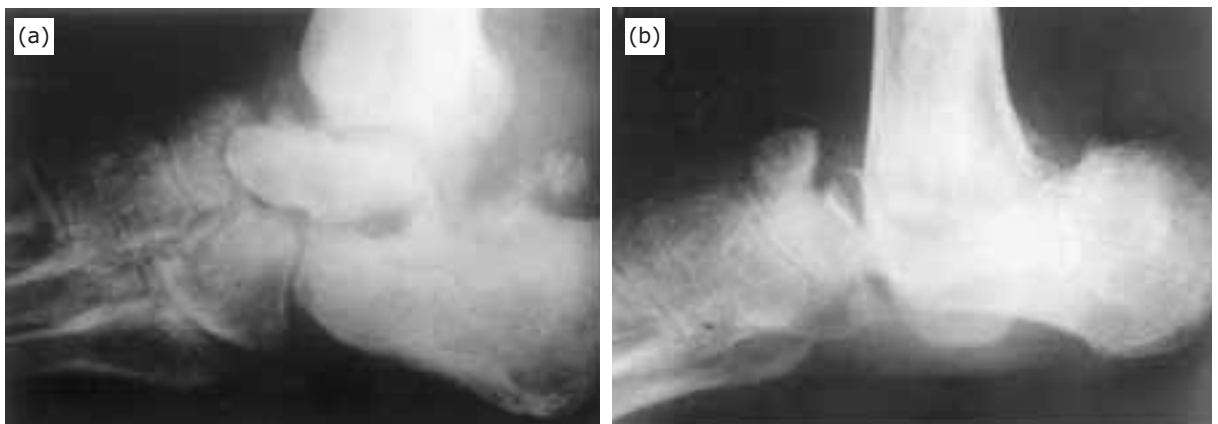


**FIGURE 13-12** The same foot 5 years later.

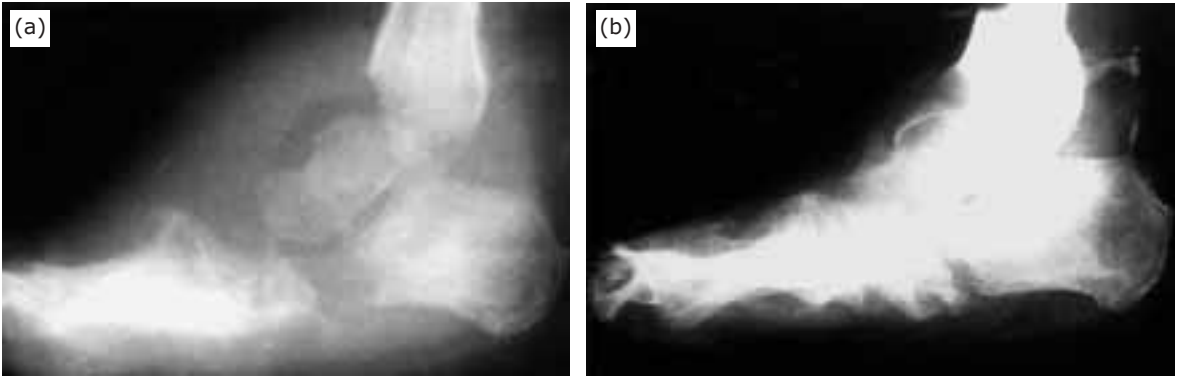
osteopaenia and disintegration. Normal anatomy no longer exists, yet, a functional shape can still be achieved by adequate treatment. This second stage indicates that softened bone has been deformed and/or has disintegrated until the normal anatomy is no longer present. Along the fractured edges the bone will appear hazy (Fig. 13-13a). Sometimes the cortical bone is hazy and 'breaks' in continuity can be detected. Continued use will increase the bone

destruction and deformity- but adequate immobilisation will result in healing in the position the bones are held in the cast. Once the bones have fully healed they are usually sclerotic and strong enough to stand up to the normal stresses of daily use (Fig. 13-16).

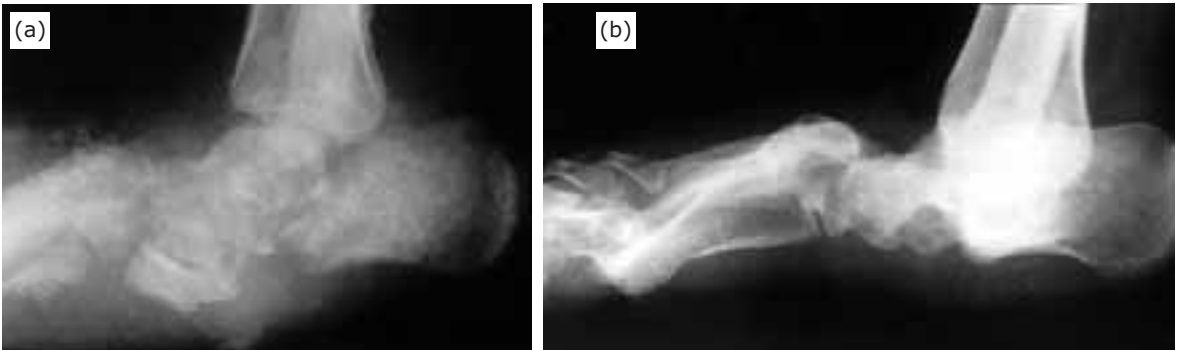
**Third Stage: consolidated stage.** The foot will no longer be warm or hot. It will, however, often be cold due to neuropathy, and may be deformed. The bone edges will once more be clear cut lines as seen in Fig. 13-16. It may have consolidated in a position that is basically normal (Fig. 13-17). There may be some degree of deformity that is compatible with normal usage (Fig. 13-18). It may be unstable and/or hypermobile. Radiographic examination will often show that the bones have recalcified (Figs. 13-14b, 13-15b). The fractures may be healed in a deformed position or, if not fused, the bone edges may show firm lines indicating healed bone, compared to earlier haziness and irregularity. If there is deformity the foot may re-ulcerate and secondary infection may determine the final outcome. The foot that initially had only a minimal fracture, neglected because



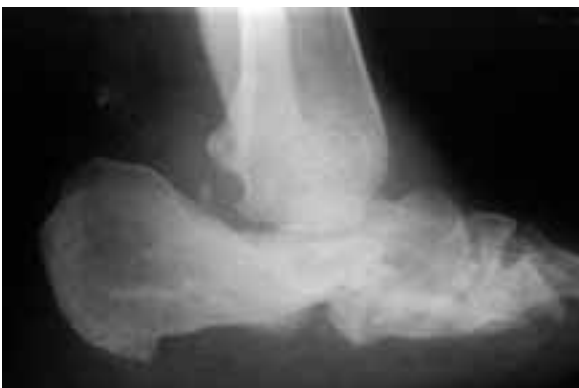**FIGURE 13-13 a.** The disintegration of the talus resulted from a minor trauma. **b.** Without treatment it progressed till the tibia had gone through the calcaneus and the foot was amputated. The foot was not treated because it had been stated that a 'Charcot' foot could not be "cured".



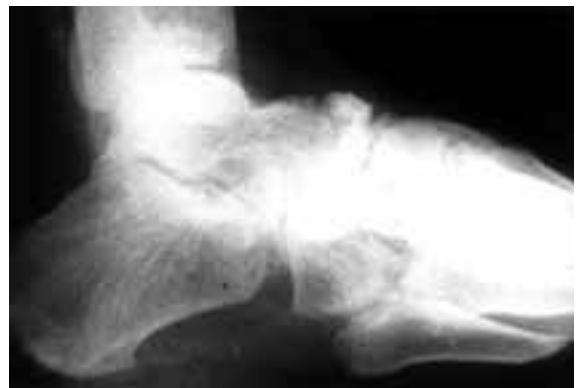**FIGURE 13-14 a.** Markedly osteopaenic bones but no obvious infection. The bones went with to re-calcification on adequate rest and protection. **b.** Twelve months later showing the recalcified bones.



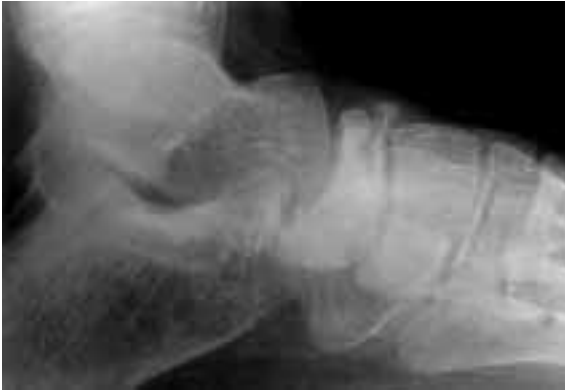**FIGURE 13-15 a.** Osteopaenic disintegrating bone with marked midfoot deformity. There is obvious infection that has gained entry through ulcer sites. **b.** Twelve months later the bone is sclerotic and healed.



**FIGURE 13-16** Healed bones. Same foot as in Figure 13-5, after 12 months of healing in a TCC. Note well-calcified and firm edges of all bones.



**FIGURE 13-17** Healed navicular bone after 8 months in plaster cast. Same foot as in Figure 13-9.



**Figure 13-18** Slightly deformed navicular that is obviously healing without requiring any special therapy.

of *lack of pain*, may become increasingly deformed, and a chronic liability.

## **Diagnosis of Neuropathic Bone Disintegration**

### **“Hot Spot”**

*A hot spot in a sensory impaired foot should be regarded as a sign of a bone lesion, until proven otherwise.* It may be a fracture that, if neglected, may develop into a so-called ‘Charcot’ joint or foot. The term *neuropathic bone disintegration* (NBD) is preferable, as often the joints are not involved, at least initially. It is rare to see a typical ‘Charcot’ foot as originally described by Charcot (Fig. 13-5).

### **Hot spots may also be due to:**

1. Minor infections.
2. Sprains and strains.
3. Burns, including friction burns on the feet.
4. A recent fracture, which has not yet disintegrated. Stress fractures may not be visible on radiographs for 6-8 weeks and are often missed. Such fractures should heal as well as a fracture in a sensate foot if it is immobilised for an adequate length of time.

The patient with neuropathy and reduced pain perception does not realise the presence of a fracture and continues weight bearing. Movement of the broken bones causes fragments to be rubbed off the bones until disintegration or disorganisation becomes obvious.

The search for the cause of the hot spot is often assisted by white cell counts, full blood counts and ESR tests. These tests are sometimes supplemented by radiological scans, which will confirm the hot spot but are not informative about the cause. A scan confirms what your hand has already told you. It may say which tissues are hyperaemic but not why. Hetherington discusses tests to determine the cause of the hyperaemia but warns about relying too greatly on such tests. He recommends a bone biopsy. However, if the skin is intact a biopsy may often be negative, possibly because the wrong tissue is taken. If there is a hot spot in a neuropathic foot without an ulcer it is unlikely to be septic osteomyelitis. For diagnosis, therefore, radiography is not essential, not reliable and in many places not available or affordable.

*Clinical testing for hot spots is the most effective and cheapest.*

Most ‘hot spots’ are distal to the ankle. The patient is given complete rest of the affected part- preferably complete bed rest. The foot is elevated and rested in a splint that will prevent movement of the ankle and toes. If the heat and swelling are due to a fracture they will settle in a few days but rapidly return as soon as the patient resumes walking. If the heat and swelling are due to infection they will not subside quickly unless the patient is given antibiotics. Once settled it should not return quickly when walking is resumed. When in doubt, especially in a patient with marked neuropathy and/or diabetes, it is best to give appropriate antibiotics for a prolonged period, rest till the swelling has subsided and then use a Total

## 156 Surgical Reconstruction & Rehabilitation in Leprosy

Contact Cast (TCC) for 6 to 12 weeks (appendix D). At that time any fracture should be seen on an X-ray, and may already have healed without displacement. Any infection will probably be completely eliminated, especially if antibiotics have been given.

### Radiography

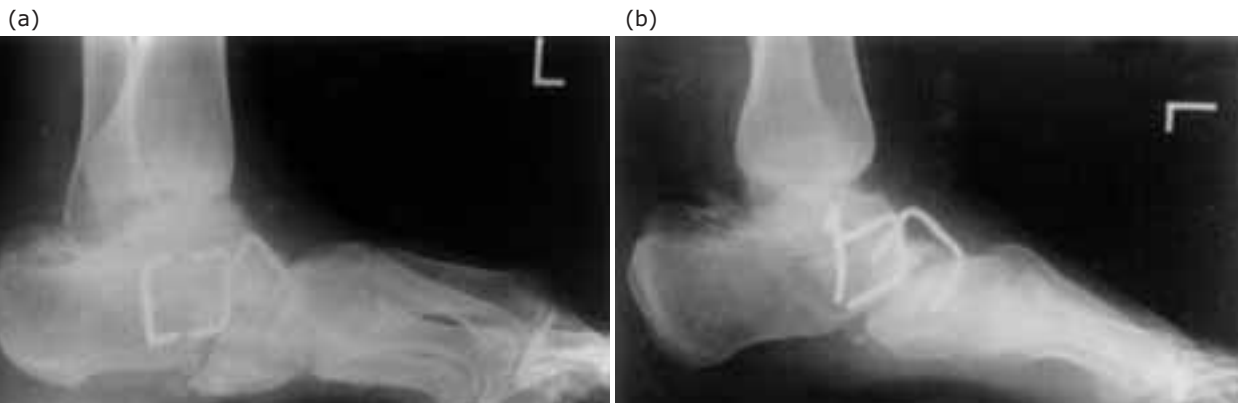Ideally every neuropathic foot should, for future reference, have routine radiographs taken at diagnosis.<sup>26,27</sup> The best radiographic views are:

A. True standing lateral from toes to heel (Fig. 13-19).

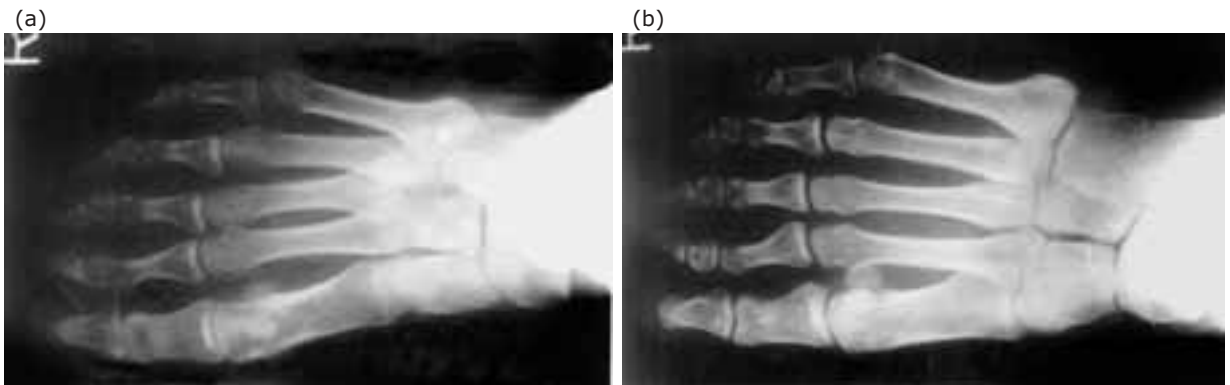
B. Antero-posterior view of the forefoot taken with 15 degrees of obliquity from the vertical. (APO view; Fig. 13-20b). This will show the metatarsal bases more clearly than the standard AP view (Fig. 13-20a).

These two views are cost effective and if radiographs are routinely taken in these positions it will facilitate comparison when a lesion is suspected. Any suspect lesions should be further investigated by other views if necessary.

Early signs of bone lesions may include chips, cracks (Fig. 13-21), haziness (Fig. 13-22), obvious disintegration and lucidity (Fig. 13-10), increased calcification (sclerosis), impaction

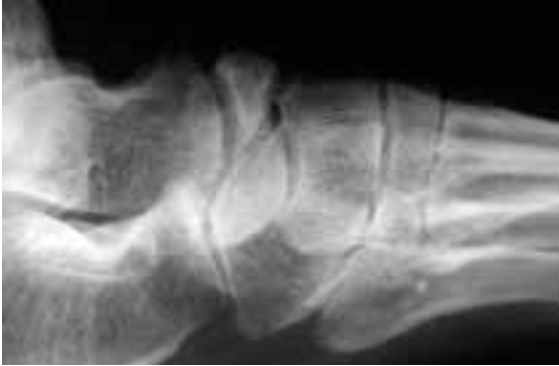

**FIGURE 13-19** **a.** Standing lateral view. **b.** Compare with non-standing lateral view of the same foot which may give a wrong impression of stability.

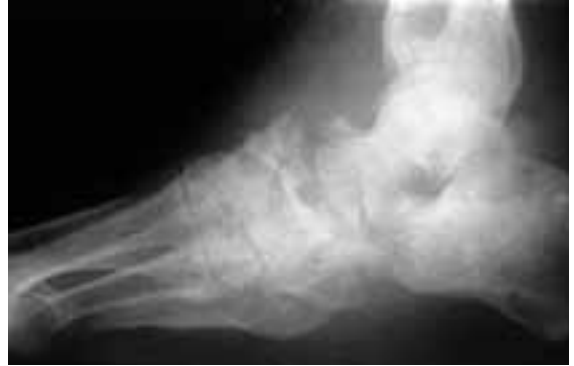

**FIGURE 13-20** **a.** Standard AP view. **b.** Oblique (APO) view that gives a much better view of the bases of the metatarsals.



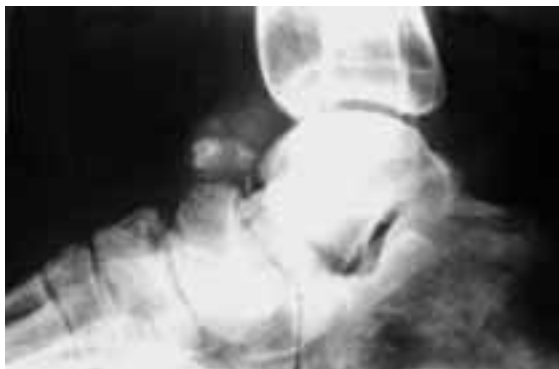

**FIGURE 13-21** Large crack through navicular.



**FIGURE 13-22** Mid-tarsal fracture showing haziness and disintegration along the fracture line.

(Fig. 13-18) and decalcification (Fig. 13-14a). Impaction may be associated with loose fragments of extruded bone lying free beside damaged bone (Fig. 13-23). There may be obvious fractures with disintegration (Fig. 13-9), fragmentation and general haziness of the bone edges (Fig. 13-13a), loss of trabeculae and irregularity of cortical bone. The foot in which the radiograph suggests abnormality should, if possible, be further examined by different radiographic projections. A neuropathic limb that shows a suspicious change on a radiographic examination should be treated as if there is NBD. A radiologist who knows that the patient has a neuropathic foot may report any bone lesion as a 'Charcot' joint. The most common



**Figure 13-23** The head of the talus has been fractured, impacted, and partially displaced. The cortex of the navicular is irregular and may be disintegrating.

early lesions are simple fractures and if the limb is adequately immobilised these should heal as well as they would in a sensate foot. When the lesions have healed, their edges will appear clean cut and no longer hazy or fuzzy. NBD usually starts as a fracture, not a joint lesion. The joint may be involved when a fracture extends into the joint or when the subarticular cartilage collapses.

### ***Other Factors Affecting the Development of Neuropathic Bone Disintegration***

Harris and Brand presented a new concept on the basis of analysing the patterns of NBD lesions, and stated that lesions will heal if adequately protected.<sup>13</sup> Before that time it was believed that the neuropathy was the cause of NBD. Brand summarised their findings by saying: "We have been looking for weakness of the tissues when we should have been looking outward to prevent excessive forces and high temperatures". Delbridge also stresses the mechanical factors that predispose to ulceration in patients with diabetes.<sup>10</sup>

Brand states that although leprosy may render an insensate foot more vulnerable to mechanical forces, the denervated tissues are only marginally less competent in wound healing. The 'misuse' of the limb due to reduced

pain perception is the main factor in prevention of healing and hence the development of the so-called non-healing ulcer and 'Charcot' foot. If special care is given, the anaesthetic limb need not develop perforating ulcers and loss of digits. The basic problem is one of mechanics, not medicine. The principles of care for insensate feet in leprosy are equally applicable to other neuropathies such as diabetes, familial motor sensory neuropathy and spina bifida.<sup>3,23</sup> Coleman and Brand discuss the acute care of neuropathic feet including osteomyelitis and fractures.<sup>8</sup> They point out that the key to treating the fractures is early diagnosis. They emphasise the use of the TCC, and the extra time required for healing of neuropathic bones.

Hetherington states that there are definite osseous changes associated with neuropathy and that these include radiographic osteoporosis, atrophy, destruction and disappearance of bone structure. It has been observed that the neuropathic foot with chronic ulceration becomes more and more osteoporotic due largely to the hyperaemia, which itself causes increasing osteoporosis. Osteoporotic bone is more prone to stress fractures. One study showed that 10% of patients who had a walking cast for 6 weeks or who were otherwise immobilised developed a stress fracture if allowed to resume unrestricted walking at the end of this time.<sup>25</sup>

Borssen recommends the use of plaster casts in treating neuropathic diabetic foot lesions.<sup>6</sup>

TCC's are excellent for healing neuropathic, ulcer or bone, lesions. Shaw has shown that the weight is spread over the foot with some 40% being carried through the inner shell of the cast.<sup>22</sup> This means that the pressures on the leg and foot are relatively low. Movement inside the cast is eliminated so any tissue trauma, bone or soft tissue has a chance to heal without being constantly disrupted by movement.

However, many clinicians, especially diabetologists are very hesitant to leave a neuro-

pathic limb in a TCC. They feel that the risk of pressure ulcers and necrosis within the cast outweighs the advantages of the casts. I have great success treating ulceration of diabetic feet with TCC, especially when it is associated with bone involvement. This has resulted in prevention of amputation in many patients with diabetes.<sup>11,17,19,21</sup> Because of the reticence of some clinicians for a TCC a modified *bivalved* TCC has been devised. This cast can be removed to check the skin for rubs or pressure areas and to treat any ulceration that is present. It is replaced with Velcro and therefore is still virtually total contact when correctly applied (Appendix D). The main problem with its use is compliance. Patients have to learn that they do not take the cast off, except when instructed by the physician. By using a TCC, an ulcer of about 2-3 cm will usually heal within 6 weeks. Where there is a bone lesion the time will be much longer. When the cast is discarded it is important to ensure that trial walking (graded weight bearing) is started (Appendix E). Ulceration has been included here because of its intimate association with the development of osteoporosis and the complications that may result from it.

### **Osteopaenia and Osteoporosis**

The degree of osteopaenia is one of the main factors in the development of NBD. Osteoporosis is not uncommon, especially in the older age group in whom stress fractures frequently occur. There are other factors that are important in the aetiology and management of NBD.

1. Acute neuropathy in itself may lead to osteoporosis. This may happen in Type I leprosy reactions. Osteoporosis can predispose to a stress fracture, especially in patients with an unstable gait.
2. Reduced activity such as prolonged bed rest. The use of a TCC instead of bed rest

for foot ulceration helps reduce the severity of osteopaenia.

3. The use of plaster casts. One study reports that 10% of patients with neuropathy, who wore a walking plaster cast for 6 weeks or longer, developed a stress fracture when allowed to return to unrestricted walking the day the cast was removed.<sup>25</sup>
4. The use of corticosteroids.
5. Poor nutrition, especially in combination with hormonal factors, or in growing children.
6. Cigarette smoking and excessive use of alcohol.
7. Osteoporosis is also found when there is long standing hyperaemia, such as occurs in chronic infection, fracture or trauma (Fig. 13-14).
8. Age. The development of osteoporosis in older age groups is well accepted.

Initially the stress fracture does not show on an X-ray. As a first step towards healing the body removes the calcium from the edges of the fracture until it becomes possible to visualise the fracture on an X-ray. After 6-8 weeks it is usually possible to see a stress fracture. The fracture makes the bones initially softer and they are therefore more prone to deformity. The edges of the bones may 'impact' during walking. If the area is mobile the edges may wear each other away. Heat and swelling persist until the bones are united, that is when removal of calcium ceases and deposition of new bone and calcium occur. This may take several months of immobilisation. If a decalcified limb is not adequately protected it may continue to exhibit a low degree of activity for many months slowly changing its shape while adapting to the stress of use. The patient should not undertake unprotected walking when there is still heat or swelling. All patients

should undergo trial walking when returning to unprotected walking (Appendix E).

Once osteoporosis is present it is not likely for the bone density to return to the pre-trauma level without medication. Immobilisation in a TCC does cause osteopaenia but such immobilisation is essential for bone healing. At best, healing may occur in association with increasing deformity. Once healed the patient can walk without the cast, in suitable footwear and this will encourage further re-calcification provided the amount of walking is 'guarded'.

### **Management of Neuropathic Bone Disintegration**

If a disintegrating bone is not immobilised, the disintegration may continue (Fig. 13-13) but if adequately immobilised healing will occur. Healing can occur spontaneously in lesions that are not subject to marked movement. If the bone edges are already well defined at diagnosis it is unlikely that fusion of the fragments will occur. Even with lesions that are grossly decalcified or disintegrated, healing is possible, though in severe cases it may require 12 months or more, of total immobilisation. (Figs. 13-14, 15)

Disintegrating bone requires immobilisation for a prolonged period to ensure that healing will be complete. There is no reason to believe that neuropathic bone takes longer to heal than bone that is innervated. However, bone with reduced sensory perception is more prone to injury than normal bone. If normally sensate newly healed bone is subject to excess stress, pain will protect the foot. If pain perception is reduced the patient may not be warned of impending trauma and continues 'stressing' the healing bone until a new fracture may occur. Hence, the rule that a neuropathic bone lesion is immobilised for 2-3 times as long as would be required for the same lesion in a sensate foot.

### **Basic Routine Management of NBD**

Following examination and recording:

1. Rest in a splint, foot elevated. Not one step! Complete bed rest if possible. Foot elevated on pillows or frame with the knee bent. Many patients already have weak dorsiflexion and shortening of the Achilles tendon is NOT wanted. Advise the patient about toileting etc. One step on the foot may nullify the good done by the previous 24 hours.
2. After 5-7 days, earlier if all swelling has subsided, check mobility and, if mobile, mould foot into optimal functional position.
3. Apply Total Contact Cast (TCC) to maintain optimum position. (See appendix D)
4. After 3-6 weeks, if the cast becomes loose, remould the foot and replace the cast.
5. Patient should be encouraged to walk in the cast as this helps to stimulate recalcification. It also helps to maintain the strength of the muscles of the affected leg.
6. Immobilise for full length of time according to schedule.

Initially, review the cast weekly. Some choose to delay the first complete cast, (during which time the patient does not walk on the foot), for about a month in the hope that all swelling will have subsided before the cast is applied. Then there will be no need of a new cast in a few weeks. If this is done the foot should be adequately splinted so the ankle and toes are not easily moved or bumped. When the diagnosis of bone disintegration is not certain at cast application, it is advisable to re X-ray the foot about 8 weeks after the initial cast is applied.

The bones will heal in the position in which they are immobilised. Therefore, an attempt should be made to manually reshape the foot before the TCC is applied. It is not advisable to try to mould the foot into a functional position

once the first layers of plaster of Paris are applied. When a better position is achieved by moulding, and the TCC is applied, excessive pressures should not result. If the foot is moulded after cast application there are likely to be pressure points where ulceration may occur. Many clinicians working with neuropathic feet of patients with diabetes are reluctant to apply a TCC due to fear of pressure sores. This fear is unwarranted provided proper cast application has been done and the patient is well informed.

By careful application of TCC it is often possible to obtain a functional foot without the need of surgery. In some patients the initial degree of deformity is so great - or increases as the swelling subsides that the healed position is not functional to ensure ulcer free walking. In these patients some form of wedge osteotomy, or other bony surgery, may be indicated to restore the foot to a shape that is functional and near normal. The object of the reshaping of the foot is to produce a functional unit, not to restore original anatomy. When a patient presents with a grossly osteopaenic deformed bone try and mould it to a better shape and then after 3-4 months in a plaster cast review with an X-ray. If the bone is no longer disintegrating and showing defined, albeit osteopaenic bone but the anatomical shape is obviously incompatible with ulcer free walking, surgery should be contemplated (Figs. 13-14b, 13-15b, 13-16, 13-17).

### **Healing Time for NBD**

The time required for healing depends on the site and extent of the bone lesion(s). The times suggested below were determined by 'trial and error' and use of trial walking on a large group of leprosy patients over a 15-year period.

1. The patient who presents early, with a hot swollen foot in whom there is no evidence of bone lesions on the radiograph should

wear a TCC for 6-8 weeks. A new X-ray should be taken at that time. If there was a stress fracture the bone lesion should then be visible. If there was no lesion, start trial walking to test if there is other pathology. Immobilise for 3-4 months if no X-ray can be made before reviewing the clinical condition. The patient should not continue trial walking (TW) if the foot repeatedly becomes warm and swollen.

2. Patients *who show minimal fractures (excl. tarsal bones) without obvious disintegration* require 3-4 months in TCC. Phalangeal fractures or disintegration of metatarsal heads or phalanxes need at least 3 months in the cast.
3. Patients with *major fractures of tarsal bones but no disintegration* need 5-6 months in TCC. If in doubt *give 7-9 months TCC*. If only mild disintegration but no gross fracture or marked displacement, trial walking can be started in 6-8 months.
4. Patients with definite mid-foot fracture/disintegration require 8-9 months. Most lesions occur in the talo-navicular-cuneiform area.<sup>25</sup> The Lisfranc area also requires 8-9 months immobilisation.
5. Metatarsal osteotomies or disintegration need 6-9 months. If they involve the Lisfranc area they need 8-9 months.
6. Gross disintegration involving many bones or large areas may need 12-18 months in a TCC.

If the patient with NBD requires tendon transfer these can be done towards the end of the bone healing time. This is 4-6 weeks prior to ending the TCC. However, return to locomotion by TW and a split TCC should be slower than normal for a tendon transfer.

Many have used callipers, braces and moulded footwear to encourage healing of NBD. This may be effective in minor lesions. However, if the appliance allows any move-

ment it is unlikely that the optimum functional position will be achieved. Healing will be slower than if completely immobilised in a cast.

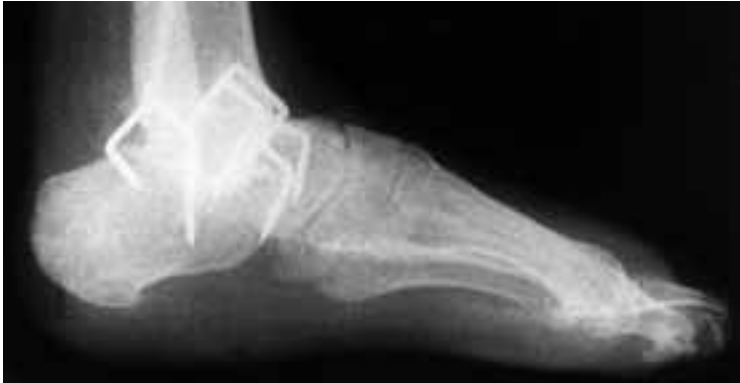## RECONSTRUCTION OF THE DEFORMED NEUROPATHIC FOOT

Because of reduced pain perception many NBD lesions result in deformity that may not be compatible with ulcer free usage. Minor deformities can be 'accommodated' in footwear or with orthotic appliances to prevent ulcers. However, the provision of footwear-devices is not practical, and costly for the patient. Walking without shoes, even for a short period may undo all the good achieved by special footwear. In addition other questions are relevant. Where does the patient bathe? In the river? Does he need to remove the shoes for this? If he has to take off his shoes for these reasons then these are valid reasons to consider reconstruction of the foot in such a way that barefoot walking for short periods is tolerated.

### ***The Badly Deformed and/or Ulcerated Foot***

Some patients have had a dropped foot for many years and the lateral border is 'worn away' through recurrent ulceration. If a foot drop correction is not appropriate and it is not possible to passively place the ankle in a functional position it may be best to do an ankle arthrodesis (Fig. 13-24). Patients can walk well when the ankle is arthrodesed if there is adequate dorsiflexion (5-10 degrees). If there is too much dorsiflexion the patient may need to stand with the knees slightly bent to get the soles flat on the ground. This is not a real disability and often improves stability as extensor and flexor muscles of the hips and knees are firing all the time. The ankle arthrodesis may be combined with a midtarsal wedge if there is





**FIGURE 13-24** Pan-talar fusion of grossly deformed ankle.

providing a new pair of shoes every 6-12 months for a lifetime, then costs favour a reconstruction. Years ago it was generally accepted that healing after reconstruction of neuropathic bones would not occur. However, it has now been shown that it does occur.<sup>24</sup> Banks has reviewed various techniques but emphasised the need for adequate fixation.<sup>1</sup>

rotation of the midfoot or turning in of the forefoot. Alternately, a modified triple arthrodesis may correct the basic deformities of the hind and midfoot but this will not provide ankle stability if a foot drop is present.

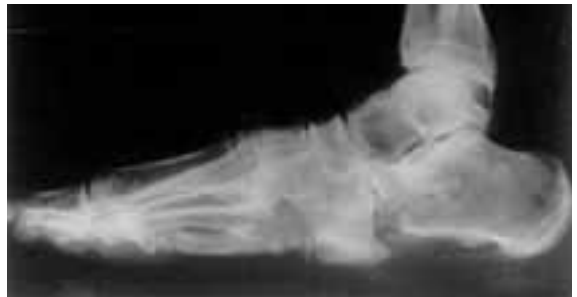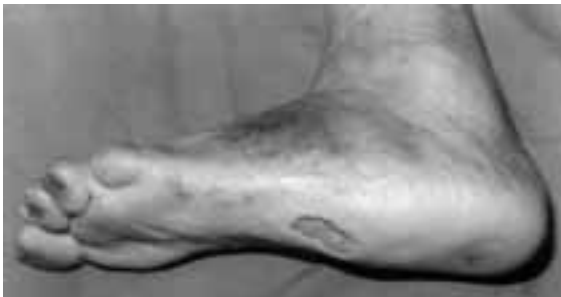There are also patients with a fixed inversion of the heel in whom a foot drop correction will not produce a good result. These patients do well if a sub-talar fusion is combined with a tendon transfer to correct the foot drop.

For patients with marked deformities it is often more effective to reconstruct the foot so that special footwear or orthotic devices are not needed. Patients can then use regular footwear with a microcellular insole to provide extra resilience. The surgical alternative is often major surgery, requiring good hospital facilities and prolonged periods in a TCC. When the cost of such procedure is compared with that of

### Osteo-Ectomies

After neuropathic bone has healed there will be some degree of deformity. In many patients this is a slight deformity and compatible with function especially if the patient wears suitable footwear. A common deformity is a prominence on the planto-medial surface of the longitudinal arch, usually at the talo-navicular joint or the Lisfranc area (Fig. 13-8). This 'bump' often ulcerates. It is possible to do a 'bumpectomy' (an osteo-ectomy) to remove the prominence but it is essential to know that adequate 'healthy' bone is present (Fig. 13-25).

An oste-ectomy for removal of a deformity resulting from major disintegration is best done after about 6-7 months in a TCC. By that time the position is stabilised and handling the foot on the operation table is not likely to increase the deformity. Bone should be ossified



**FIGURE 13-25 a.** Typical plantar ulcer caused by a deformed cuboid. **b.** Radiograph of the same foot.

enough to be able to assess where trimming is necessary. The 'bump' is usually approached from the lateral or medial side of the foot. The incision is made on, or a little above the level of the plantar surface of the bone. The plantar tissues are peeled back at the periosteal level and the 'bump' is chiselled off and rasped smooth. If possible, saucerise the area so that the actual bump becomes a depression roughly the shape of a saucer, created under the old scar so that the patient's weight is carried mainly on the edge of the saucerised area. The scar will then not be subjected to as much pressure as would happen if the bone were trimmed flat. Be careful to remove any rough or irregular periosteum and bone fragments as these may otherwise recalcify and cause new problems. Do not plan the 'bumpectomy' through a plantar ulcer, as that will require a much larger incision and will leave a poor scar line. After removal, the scar should be closed with everting deep mattress sutures of large (0 or 2x0) monofilament nylon to produce a good quality surgical scar. The surgical approach scar is left open except for one or two mattress sutures at each end, as a relieving incision, that provides drainage, can be packed open and allowed to heal by secondary intention. If there has been an ulceration that has left poor quality skin it is advisable to excise that skin, by an elliptical incision, at the same time as the bump is flattened. In that case the incision to approach the 'bump' should be dorsally, high enough to ensure survival of the bridge of tissue left between the definitive surgical incision and the original scar (ulcer).

Following surgery the patient can start walking in 5-14 days, using a bivalved TCC. A windowed cast is not recommended if the wound is on a weight-bearing surface. Scars on the weight-bearing surface should be avoided except when:

- a) There is poor quality skin on the weight-bearing surface that is likely to break

down again. The scar can be excised and closed to leave better quality skin. The cavity left after removal of the bump is loosely packed with a layer of Vaseline gauze padded out by saline soaked gauze. The relieving incision should be long. This pack is not changed for 5-6 days, when it will be determined if there is any residual infection. The pack can be changed once or twice a week till the wound has fully healed from the bottom. The granulation tissue will help to increase the depth of plantar tissue. The patient should be on bed rest, in a cast or back slab, for the first week or two and then may have a bivalved TCC which can be removed, usually weekly, for dressings. Do not allow the skin edges of such a cavity to heal before the bottom is fully granulated. Do not allow the cut edges to invert so that the wound heals as a deep crack.

- b) a periosteal irregularity on the plantar surface that keeps causing ulceration. These can often be managed by orthotics and regular removal of callosities but for long-term care it is often better to do a 'bone trimming'.<sup>9</sup>

Sometimes a roughened metatarsal head that is prominent is best approached through the dorsum. Let the wound heal by secondary intention. It is advisable to excise the scar that was under the head and close it with deep mattress sutures to improve the quality of skin. The small decrease in plantar weight bearing area is offset by improved quality of skin. This is especially the case if it is possible to bring the toe(s) down. In some patients it will be an advantage to shorten the prominent head so that no one head is taking excessive stress during take off. Ideally, all the metatarsal heads ought to be in a

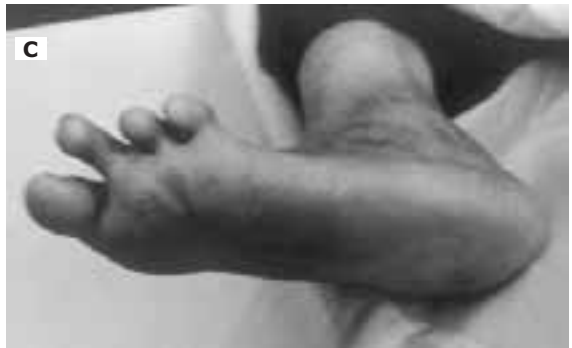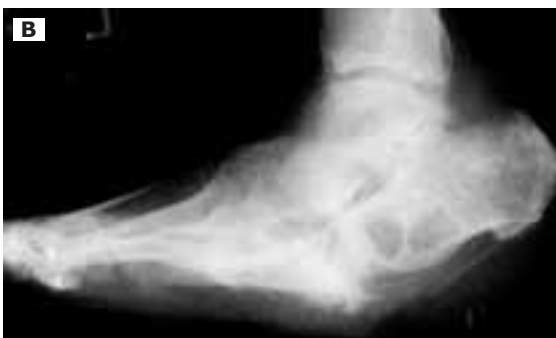curved or straight line so that no one is prominent.

After these procedures the patient should continue to use the bivalved cast for a total of 6-10 weeks or two full weeks after all the scabs on the long lateral incision have come off by themselves (which ever is the longer period). There is no practical way of assessing the healing of deeper tissues. If bone has been cut or trimmed it may be better to use the cast for 3-4 months especially if the bone was osteoporotic or infected before surgery. Radiographs will not indicate if healing is complete. Once the patient goes on to trial walking he will require another 2-4 weeks of guarded walking. The patient should keep the cast and use it when 'at risk' e.g. on trips where the foot will be in use for a long period. The cast should be worn if heat and swelling occurs.

**WEDGE OSTEOTOMIES & ARTHRODESSES**

For a marked deformity moulded footwear is often recommended. However, it is possible to reconstruct the foot by wedge osteotomies or an arthrodesis that could make the foot less prone to 'break-down' and the patient less dependent on custom made footwear. The common osteotomies or arthrodeses are in the sub-talar, ankle, midtarsal or metatarso-tarsal areas (Fig. 13-26 a-c). A flat foot is perfectly acceptable as long as the patient does not have plantar prominences, or hyperextended clawed toes that can be corrected by Girdlestone tendon transfers (Chapter 14).

In some patients with flat feet it is possible to do one or more small wedges e.g. talo-navicular or naviculo-cuneiform to correct over pronation. Pandy's osteotomy is a helpful procedure to correct over pronation.<sup>18</sup> The plantar part of the calcaneum is shifted laterally to assist in preventing inversion of the calcaneum. If necessary, the forefoot can be rotated on the hind foot. It is usually more practical to do one big wedge osteotomy across the midfoot and use internal fixation to ensure the position is maintained. With good internal fixation the patient can walk in a TCC 10-14 days after surgery, when the post-operative swelling has



**FIGURE 13-26** a. A chronic ulcer present for over 5 years. b. The radiograph indicating there had been neuropathic bone disintegration with impaction that had caused a boat foot. c. The sole 5 years after wedge osteotomy to remove the bony prominence of the sole.

subsided. I would not bivalve this cast, especially if the patient is going home. I do not recommend Charnleys clamps or similar external fixateurs because their removal means that there is no longer internal fixation maintaining the position. Even when covered by casting material there is an increased risk of soft tissue infection or osteomyelitis.

Wedge osteotomies can be done to reshape a badly deformed foot after NBD once the bone appears to be healing. This could be at 3-6 months after TCC. If a wedge osteotomy is attempted early, in the acute stage of the disintegration, the bone is so osteopaenic it can be cut with a scalpel and any fixation will not hold. Some have tried to insert bone grafts to restore the foot to normal size. This is effective only if a small area is involved and the foot is maintained in a TCC for 9-12 months. However, it is usually safer to slightly reduce the plantar area of the foot and fuse without a graft as the addition of a graft may cause excessive stretch on the already damaged dorsal skin. After the osteotomy the TCC is used for a further 7-9 months before trial walking is used to test the integrity of the structures. If the toes are clawed, or not making good ground contact, they should also be corrected before trial walking commences.

### **Mid Tarsal Wedge Osteotomy**

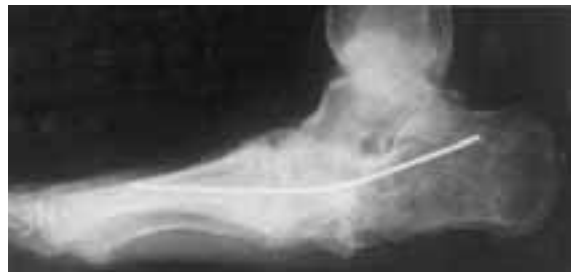A wedge osteotomy of the midfoot can correct a boat shaped foot, a medial displacement of the forefoot or other obvious deformity of the plantar surface (Fig. 13-6). The external shape of the foot has to be considered and the type of wedging, size and direction determined, bearing in mind that the internal anatomy may be completely abnormal. There will be no arthrodesis of existing joints. Following severe NBD there may be complete loss of all joints and sometimes the whole foot fuses into a solid structure.

### **Technique**

The approach is through an incision that curves up from the cubo-calcaneal joint area across the dorsum to about mid dorsum. Sometimes a second incision is advisable on the medial side over the talo-navicular area.

The most common wedges are transverse through the talo-navicular, naviculo-cuneiform, or through the Lisfranc area with the widest part of the wedge plantar grade to re-create an arch.

The osteotomies are best fixed with long crossed screws, or K-wires, that extend from the base of the first and the fourth metatarsals so the heads can be counter sunk but the ends of the screws reach to the cortex of the calcaneum. Blount's staples can also be used. This type of wedge will be subject to great stresses during weight bearing and postoperatively the TCC must be well moulded to fit the new arch for at least 8-9 months (Fig. 13-27). The principle behind the arthrodesis or osteotomy is that the patient can go straight into normal, or custom-made, footwear, eliminating the need for orthopaedic appliances.

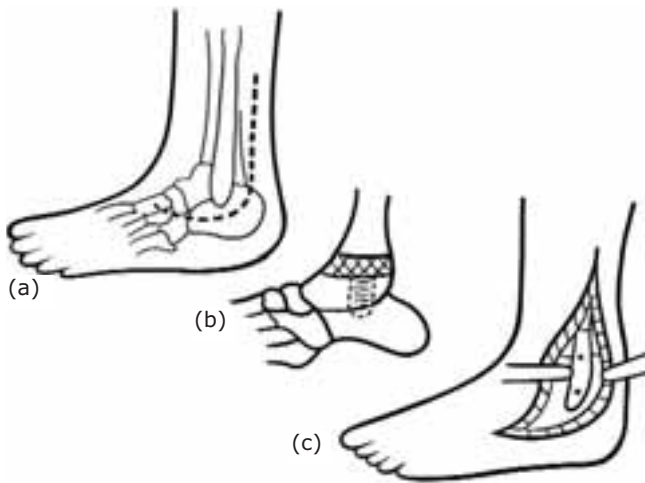


**FIGURE 13-27** Post midtarsal wedge osteotomy. Patient walked without protection before healing was complete. This caused the wire to bend with resultant loss of some position.

### **Ankle Arthrodesis**

In the deformed, often plantar flexed ankle it is convenient to perform an ankle arthrodesis through a transfibular approach (Fig. 13-28).

Elevation of the lower part of the fibula provides an excellent view of the ankle joint. By fixing the fibula to the tibia and talus and/or calcaneum there is no need to use extra bone chips. An alternative approach is anterior, either mid-ankle or with an incision on each side just anterior to the malleolus. With both of these approaches it may be difficult to remove the cartilage from the inside of the malleoli and certainly in the plantar flexed foot it is difficult to free the posterior surface to obtain good dorsiflexion and remove enough cartilage. If the talus is deformed it may be very difficult to get good opposing surfaces. If a bone graft needs to be inserted, then a midline anterior approach may be easiest. It is probably better to arthrodesis without a graft. With the transfibular approach it is easy to obtain good apposition and fixation by wires and screws.



**FIGURE 13-28** Diagrams of the transfibular approach to an ankle fusion.

**a.** Line of skin incision. **b.** The area to be removed is cross-hatched. Lines mark the site where the fibula will be replaced. **c.** The finished fusion. The fibula is held with two screws; one may be adequate or none needed.

### Technique

For an ankle fusion I recommend the transfibular approach. The surgery is easiest if the

patient is lying on his side with the ankle to be operated on uppermost and the other leg flexed at the knee and hip. A sandbag can be placed under the upper leg. A tourniquet on the thigh is advisable.

The incision is made just behind the fibula starting about 10 cm above the lower end of the fibula and turning at the lower pole of the fibula to run parallel to the sole for a further 10 cm. This will allow a flap to be raised. The tendon sheath of the peroneal muscles may need to be opened to give a good approach to the back of the fibula. A gigli saw- or electric saw is used to section the fibula about 8 cm up its shaft. A chisel is then inserted behind the lower end of the fibula to free the fibula from the tibia. The fibula is then lifted forward still attached to the skin and deep tissues to expose the ankle joint. This exposure gives excellent access to the ankle in any degree of dorsi-plantar flexion. It allows section of the posterior capsule if that is needed and lengthening or sectioning of the Achilles tendon. It also allows removal of the posterior cartilage of the talus and tibia easier than by the standard anterior approach. The operator can easily determine the cuts needed to put the foot in a suitable slightly dorsiflexed position. It is always better to provide slight dorsiflexion. Walking with a dorsi-flexed foot is preferred to walking with a foot in plantar flexion. The cartilage of the tibial surface of the ankle joint is removed and then the talus is trimmed to fit the space. If necessary, part of the medial malleolus can be removed to wedge the upper section of the remains of the talus into the tibial malleolus. If the foot is badly deformed it may be advisable to do a subtalar fusion at the same time or a pantalar fusion. Using this approach it is easy to use Blount's staples, tibio-talar and talo-calcaneal to hold the bones in the desired position. Alternately, screws or K-wires can be used but they require separate incisions for insertion. If there is difficulty holding a position, a Steinmans pin or



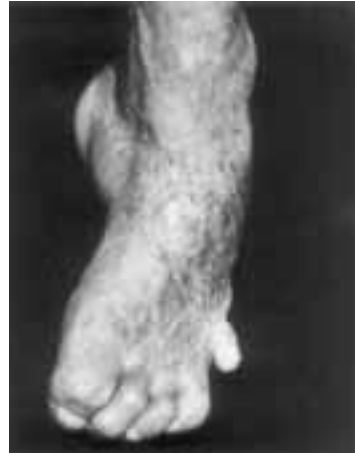2.0-mm K-wire can be inserted vertically through the calcaneum into the tibia. Once the ankle is in a satisfactory position the fibula is split by removal of the cortex so that there is cancellous bone adjacent to the tibia. The tibia is also roughened and the fibula placed as an onlay graft and held by staples, K-wires or screws to the talus or calcaneum. This provides a good lateral strut to help ensure stability of the arthrodesis. Bone chips are not needed if the talus has been cut but could be added either before or after the fibula is attached. If pieces from the fibula are used to add chips make sure it is cancellous and not cortical bone. A drain is inserted into the main cavity and the skin closed with interrupted everting mattress sutures. A plaster is applied to hold the foot in the desired position without undue pressure on the incision area.

Remember that the neuropathic patient may not have any real pain sensation and so it is important to ensure the new arthrodesis is not stressed before the TCC is made. Post operatively it is best to insist on complete bed rest—no toilet privileges for 3 full days till most of the swelling has subsided. The drain can be removed about 48 hours after surgery. A walking TCC can be made at day 6 and the patient can be discharged at day 10. If nylon sutures are used there is no need to remove them before the cast comes off. The plaster can be changed, when it becomes loose. The cast will be on for 6 full months and then bi-valved when trial walking is started. Because of the fibula overlay with internal fixation there is usually excellent lateral stability. There is no need to radiograph the foot. Radiography will never tell if the fusion is complete. That must be tested clinically by trial walking.

### **Subtalar Wedge Osteotomy**

A wedge osteotomy of the subtalar joint may result in a better functional foot than an ankle fusion when the ankle joint range of motion is

compatible with walking but the heel inverts at the sub-talar joint (Fig. 13-29).



**FIGURE 13-29** Typical inverted foot in which the deformity occurred at the subtalar joint. The ankle movement was functional.

### **Technique**

The patient lies on his side, prepared as for an ankle fusion. The incision passes from just behind the lateral malleolus along the lateral border of the foot to the calcaneo-cuboid junction and then up towards the dorsum. Direct approach to the bone should display the subtalar joint (STJ) with minimal disturbance of the ligaments of the ankle joint. Wedges are cut from the joint surfaces to achieve the desired degree of eversion. This will not be one straight wedge the whole length of the STJ. If the inversion is very marked it may be necessary to do further wedges of adjacent joints (see triple arthrodesis). Blount's staples are very convenient and after 3 days elevation and removal of the drain (at 48 hours) the patient can have a walking TCC cast applied at day 10. Total immobilisation needs to be only 3 months as walking impacts the bones.

In young children such fusion is not recommended. A similar result can be obtained by a Grice operation designed as an extra-articular

arthrodesis of the subtalar joint to stabilise the unstable STJ without sacrificing growth plates (Fig. 31-30). The block of bone (B) is taken from the iliac crest (A) and driven in to the subtalar joint (C) to stabilise the position. It can be combined with an Achilles lengthening to provide a stable plantar grade foot in talipes equinovagis or planovalgus. It may be of use in the child with early loss of anterior tibial function that tends to go into pronation but that cannot be adequately corrected by Tibialis Posterior transfer.

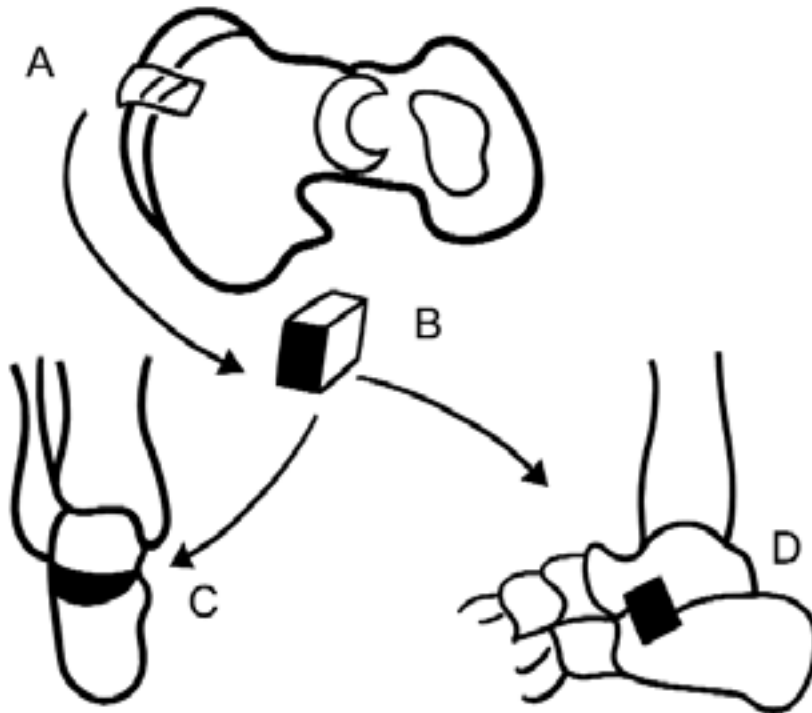
**Triple Arthrodesis and other Midtarsal Wedge osteotomies and Arthrodeses**

Triple arthrodesis is recommended for uncorrectable severe flexible pes planus with heel valgus. There are many variations in technique. It is essential that the deformity of each joint be considered. Various degrees of wedges are

removed from each joint to create a solid heel block that passively plantar-flexes and dorsiflexes at the ankle to provide a functional stable unit.

**Technique**

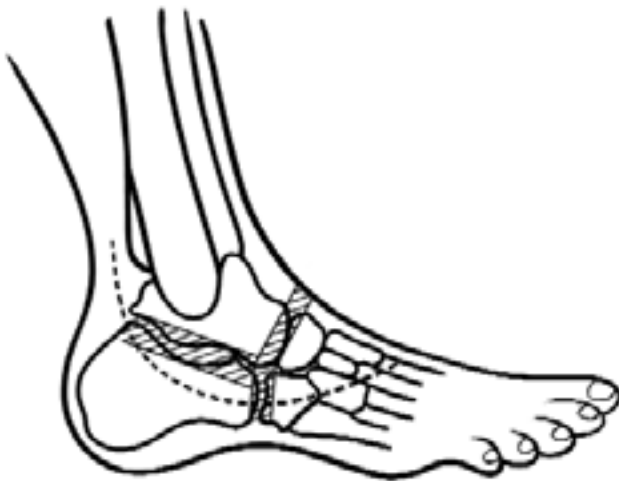Place the patient on his side as described for ankle fusion. The incision commences behind the fibula, about 2-3 cm above the lower pole of the fibula and swinging round well below the lower pole of the fibula parallel to the sole of the foot to reach the calcaneo-cuboid area when it can turn up towards the dorsum. Cut deeply directly onto bone and elevate the flap. Do not damage the ligaments of the ankle itself. The subtalar joint is easily accessible without moving the fibula if the talus has not collapsed. The cartilage is removed from the subtalar joint and a wedge is removed from the upper surface of the calcaneum to evert the calcaneum to stop



**FIGURE 13-30** A piece of iliac crest graft can be inserted according to the Grice technique to stabilise the subtalar joint without damaging the growth plates.

any tendency to inversion of the foot at the subtalar joint. This is especially so with a badly inverted heel. The talo-navicular joint is usually arthrodesed and this joint can also be wedged to improve the functional shape of the foot. The cartilaginous surfaces of the calcaneocuboid joint are removed and this joint can be wedged to improve the shape and function of the foot. This means that there can be complete arthrodesis through the midfoot at the site of the talonavicular joint. Those cuts can provide a wedging to reshape the arch or correct the turning in of the foot (Fig. 13-31).

Staples or screws can hold the arthrodeses.



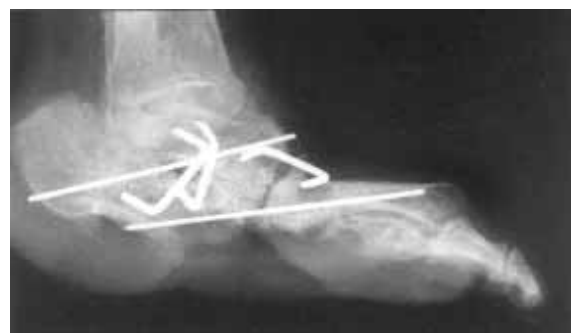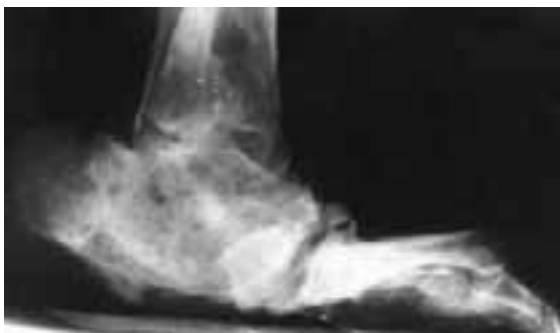**FIGURE 13-31** Diagram shows skin incision (broken line) for triple arthrodesis and the hatched areas that may need to be resected.

In grossly deformed feet it is sometimes advisable to use many K-wires (Fig. 13-32). Note that the midsole area that was initially the ulcer site over the peak of the boat is now a depressed area so that in standing the weight will not be on the scar tissue. After drainage and closure the foot is placed in a cast. Postoperative care is the same as for the ankle arthrodesis. If there is a marked arthrodesis right across the midtarsal area it is advisable to keep these patients in a TCC for 9 months before trial walking. Figure 13-33 shows a left foot with a reasonably normal ankle but twisted midfoot. Triple arthrodesis followed by a Tibialis tendon transfer produced a satisfactory foot with near normal gait.

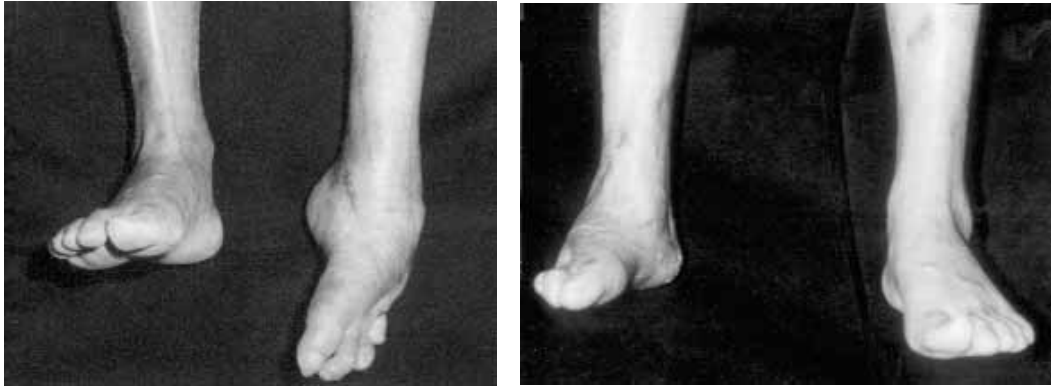
Closed wedge osteotomies of the midfoot require 7-9 months in TCC.

### **Management of the Shortened Equinovarus Foot**

Many patients when first seen may have a deformed forefoot. This is often due to a motor deficit of the anterior tibial muscles. Much can be done surgically to treat the ulceration of the forefoot, in addition to a footdrop correction. However, this is not always practical because of the shortness of the dorsum of the foot, which may be shortened as far back as the head of the talus. A tendon transfer to provide dorsiflexion is difficult to attach and would have little mechanical advantage against the strong



**FIGURE 13-32 a-b** Pre and postoperative radiographs of the gross deformity of the foot that has had many fractures and much disintegration. This foot has been reconstructed by multiple osteotomies requiring many wires and staples for stabilization.



**FIGURE 13-33** Pre and postoperative photographs of a deformed left foot, corrected by triple arthrodesis and tibialis posterior transfer.

plantar flexors.

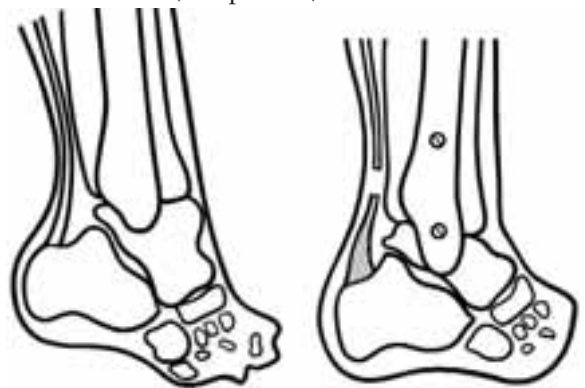
#### Technique of Salvage of the Short Foot

If the tissues of the heel pad are still reasonable, the best long-term results will be obtained by stabilisation of the hind foot. Trim the scar off the front of the foot for shoe fitting and see to it that new surgical scars are not as prone to trauma as the irregular scars left by ulceration. The basic procedure is an arthrodesis of the ankle to provide stability and removal of any prominent bumps on the plantar surface that may cause increased pressures during walking (Fig. 13-34 a-b). In some patients there is no need to do the arthrodesis. It may be enough to cut the Achilles tendon, remove part of it, to prevent plantar flexion and trim the front of the plantar surface so the stump is virtually a nice short rocker bottom. In some patients it may be better to tenotomise the tibialis posterior tendon if it is not practical to do a tibialis posterior transfer. In many patients there is no need of prosthesis as the malleoli are still present. They will be stable in a high lacing canvas boot if tied onto the stump. The foot would need 6 months in a TCC to obtain full healing. The patient should have minimal further problems as long as he maintains skin care and wears suitable footwear. If a prosthetic workshop is available

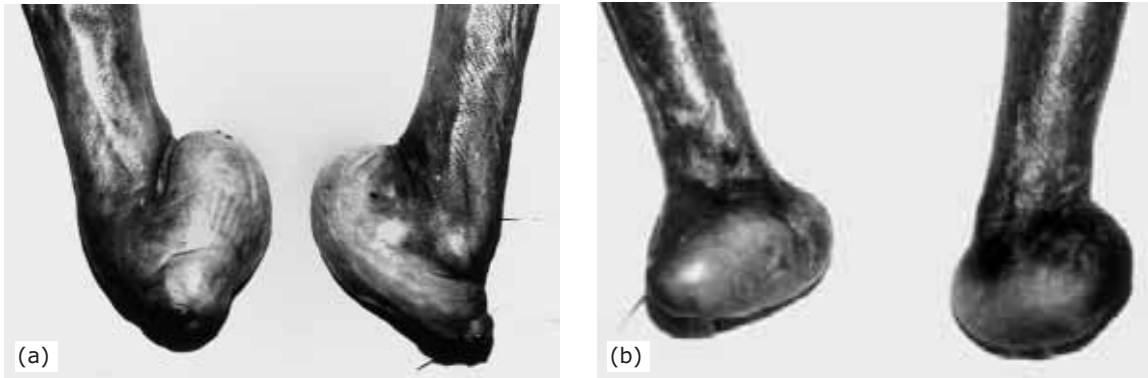a prosthesis can be made to fit the stump and provide a toe filler so the shoe does not crease. This type of reconstruction reduces the plantar surface up to about 50% of its original size but is very practical when the patient has already lost most of the forefoot (Figs. 13-35 a-b).

#### *Pirrogoffs procedure*

There will be many feet in which the loss of the plantar surface is so great that the above adaptations are not adequate. These feet may benefit from a Pirrogoff procedure or the Boyd modification (Chapter 18).



**FIGURE 13-34** Diagram of a typically destroyed forefoot with odd fragments of bone that cause repeated ulcerating. At ankle fusion good dorsiflexion needs to be achieved and the worst scars on the forefoot can be tidied up, if needed, to leave a practical stump as seen in Fig. 35.



**FIGURE 13-35 a.** Deformed feet on which an almost blind patient could walk without ulcerating. **b.** After realignment he managed very well.

### **Forefoot Reconstructions**

There are many surgical procedures to improve the foot function by removing the worst of the ulcerated forefoot, or reconstructing what is left so that the maximum amount of weight bearing tissues are preserved. The bones of the tarso-metatarsal (Lisfranc) area are often deformed and displaced downward into the plantar area and this becomes the site of frequent ulcers and scars. It is often the aftermath of major fractures or infections of that area but the toes and even most of the metatarsals escape. Often it is possible to do a wedge osteotomy right across the area and re-align the bones as described under wedge osteotomies, preserving the toes and whatever remains of the metatarsals. This provides a more socially acceptable foot than a Lisfranc or trans-metatarsal amputation, and preserves a larger amount of weight bearing surface.

An alternative management is to trim (ostectomy) the under surface of the Lisfranc area and correct the clawing of the toes (as by the Girdlestone procedure) so that the toe pulps become weight bearing again. This will help to reduce the pressure on the trauma prone Lisfranc area or metatarsal heads. The bones are frequently badly deformed and cause

ulceration because of pressure from inside the foot. In this way it is possible to use the toe pulps to help protect the scarred area of the foot and so prolong the life of the foot, provided the patient takes adequate care of the foot and wears suitable shoes and resilient insoles. In some patients it is obvious that a trans-metatarsal or Lisfranc amputation is necessary (Chapter 18). In some patients if the plantar surface is trimmed to remove bony irregularities a pedicle skin graft may solve the problem of chronic ulceration.

### **Metatarsal Head Resection**

It is not uncommon for an ulcer under the head of the great toe to result in osteomyelitis. Frequently this results in removal of the first ray, in part or entirely. In the neuropathic foot the removal of the first metatarsal head frequently results in ulceration and then removal of the adjacent metatarsal head and a domino effect results. To preserve as much weight bearing surface as possible and keep the second metatarsal head for as much length of time as possible it is advisable to remove the infected metatarsal head through a dorsal or dorso-medial incision. Ensure that the plantar surface of the remains of the metatarsal is bevelled to



prevent undue pressure during walking. At the same time excise and close any tracks connecting the ulcer to the bone and any plantar ulcer as described in the section on osteotomies. After removal of the infected bone the cavity is packed open and the foot elevated for about a week. Then a TCC is applied that ensures that the great toe is correctly placed for suitable function after healing. The TCC should have a window on the dorsal or medial side through which the cavity can be packed as frequently as necessary to encourage healing from the bottom. It will take about 6-8 weeks for the dorsal incision to fully heal from the bottom and during that time the plantar ulcer scar should also fully heal. However, as it was infected bone it is advisable for the patient to use the TCC for at least 3 months after surgery. The proximal end of the proximal phalanx of the great toe is often unaffected and can be the basis for a pseudarthrosis ensuring that arthrodesis does not occur. If the phalanx is also affected it is best removed completely but the toe tip and pulp can still be preserved. The great toe will be displaced proximally, perhaps until it is occupying the place where the head of the first metatarsal was. However, even in this situation the pulp of the toe should still take weight during walking. If it is not plantar grade enough then a Girdlestone type transfer of the FHL should be done to assist. This will prevent plantar flexion of the great toe IP joint and assist the great toe pulp to absorb some of the stresses of walking, and hence help to protect the second metatarsal head. If possible Girdlestone procedures on all the toes will assist in spreading the weight better and help to maintain a functional ulcer free unit.

Even in a foot with badly affected metatarsal heads it is often possible to preserve the toe tips or pulps and have them in suitable position to help spread the weight of the forefoot. If the metatarsals are rough or prominent they can often be removed while the toes are

preserved. The use of the Girdlestone procedure will frequently enable the surgeon to bring the toe tips down till they are weight bearing, even after the metatarsal heads are removed. However, when a few metatarsal heads are affected make sure that one head is not left protruding distally beyond the others. It may be better to trim a little off each head so that the remaining metatarsals end in an almost straight line to eliminate a prominent head that will almost certainly become the seat of an ulcer in the future.

### ***Return to Free Walking***

Whenever a patient following surgery and a TCC returns to walking it is advisable to institute a program of 'trial walking' to test the integrity of the tissues. For example, a newly healed ulcer will leave a scar on the sole of the foot. By 'trial walking', the stability of that scar is monitored. We allow the patient to increase the duration of walking at regular intervals, watching after each walk to check if there is any evidence of skin breakdown that would indicate that the newly healed tissues were not strong enough for weight bearing. If there is any evidence of tissue damage during a trial walking period the correct course of action would be to rest the limb in the cast again, till the hot spot settles and then the trial walking is again instituted. Recurrence of hot spots is best managed by use of a TCC walking cast, for a few weeks, or months, depending on the initial pathology. The cast can be bivalved, so it can be replaced after each test walk, until the foot has proved itself suitable for prolonged use.

**Acknowledgements:** The author wishes to thank Dr. Fritschi for the use of some figures from his book (now out of print). Ron Dawes of the Leprosy Mission drew the diagrams.

## REFERENCES

1. Banks AS: Elective Diabetic Foot Surgery. In: Comprehensive Textbook of Foot Surgery. William & Wilkins, 1992
2. Birke JA, Sims DS: Plantar sensory threshold in the ulcerative foot. *Lepr Rev* 57:261-267, 1986
3. Birke JA, Novick A, Patout CA, Coleman WC: Healing rates of plantar ulcers in leprosy and diabetes. *Lepr Rev* 63:365-374, 1992
4. Birke JA, Rolfsen RJ. Evaluation of a self-administered sensory testing tool to identify patients at risk of diabetes-related foot problems. *Diabetes Care* 21:23-25, 1998
5. Birke JA, Brandsma JW, Schreuders TAR, Piefer A: Sensory testing with monofilaments in Hansen's disease and normal control subjects. *Int J Lepr* 68:291-298, 2000
6. Borsen B, Lithner F: Plaster casts in the management of advanced ischaemic and neuropathic diabetic foot lesions. *Diab Med* 6:720-723, 1989
7. Brandsma JW, Macdonald MRC, Warren AG, et al: Assessment and examination of the neurologically impaired foot. *Lepr Rev* 72:254-262, 2001
8. Coleman WC, Brand PW: The Diabetic Foot. pp 1159-1181. In Ellenberg M, Rifkin H, (eds): *Diabetes Mellitus*. Appleton and Lange, Stanford, 1997
9. Cross H, Sane S, Dey A, Kulkarni VN: The efficacy of podiatric orthoses as an adjunct to the treatment of plantar ulceration in leprosy. *Lepr Rev* 66:144-157, 1995
10. Delbridge L, Ctercteko G, Fowler C, Reeve TS, Le Quesne LP: The aetiology of diabetic neuropathic ulceration of the foot. *Brit J Surg* 72:1-6, 1985
11. Doucette MM, Fylling C, Knighton DR: Amputation prevention in a high-risk population through comprehensive wound-healing protocol. *Arch Phys Med Rehab* 70:780-785, 1989
12. Fraser DM, Campbell IW, Ewing DJ, Murray A, Neilson JMM, Clarke BF: Peripheral and autonomic nerve function in newly diagnosed diabetes mellitus. *Diabetes* 26: 546-550, 1977
13. Harris JR, Brand PW: Patterns of disintegration of the tarsus in the anaesthetic foot. *J Bone Joint Surg* 48B:4-16, 1962
14. Hilton J: On the influence of mechanical and physiological rest in the treatment of accidents and surgical diseases and the diagnostic value of pain. London: Graham Bell, 1863
15. Hoeksma AF, Faber WR: Assessment of skin temperature by palpation in leprosy patients: interobserver reliability and correlation with infrared thermometry. *Int J Lepr* 68: 65-67, 2000
16. Krishnamoorthy KV: Congenital absence of sensation. *Lepr India* 54: 499-504, 1982
17. Levin ME. Preventing amputation in the patient with diabetes. *Diabetes Care* 8: 1383-1389, 1995
18. Pandey S, Jha SS, Pandey AK: T-osteotomy of the calcaneum. *Intern Orthop* 4: 219-224, 1980
19. Patout CA, Birke JA, Horswell R: Effectiveness of a comprehensive diabetes lower-extremity amputation prevention program in a predominantly low-income African-American population. *Diabetes Care* 23: 1339-1342, 2000
20. Richardus JH, Finlay KM, Croft RP, Smith WCS: Nerve function impairment in leprosy at diagnosis and at completion of MDT: a retrospective cohort study of 786 patients in Bangladesh. *Lepr Rev* 67: 297-305, 1996
21. Rith-Najarian SJ, Branchaud C, Beaulieu O, etl.: Reducing lower extremity amputations due to diabetes: application of the staged diabetes management approach in a primary care setting. *J Fam Pract* 47:127-132, 1998
22. Shaw ES, Hsi WL, Ulbrech JS, Norkitis A, Becker MB, Cavanagh PR. The mechanism of plantar unloading in Total Contact Casts: implications for design and clinical use. *Foot Ankle* 18: 809-816, 1997
23. Walker SC, Helm PA, Pullium G: Total contact cast casting and chronic diabetic neuropathic foot ulcerations: healing rates by wound location. *Arch Phys Med Rehab* 68: 217-221, 1987
24. Warren AG: Tarsal bone disintegration in leprosy. *J Bone Joint Surg* 53B: 668-679, 1971
25. Warren AG: Patterns of tarsal bone disintegration in leprosy patients. University of Sydney. MSc Thesis, 1972
26. Warren AG: Radiographic examination of the feet. *Lepr Rev* 44:131-138, 1973
27. Warren AG, Nade S: *The Care of Neuropathic Limbs: a practical manual*. Parthenon Publishing, New York, London, 1999

**Additional Reading**

Armstrong DG, Stacpoole-Shea S: Total Contact Casts and removable Cast Walkers. *J Am Pod Med Ass* 89: 50-53, 1999

## 174 Surgical Reconstruction & Rehabilitation in Leprosy

- Birke JA, Sims DS, Buford WL: Walking casts: effect on plantar foot pressures. *J Reh Res Devel* 22:18-22, 1985
- Birke JA, Novick A, Patout CA, Coleman WC: Healing rates of plantar ulcers in leprosy and diabetes. *Lepr Rev* 63: 365-374, 1992
- Birke JA, Patout CA: The Contact Cast: an update and case report. *Wounds* 12: 26-31, 2000
- Coleman WC, Brand PW, Birke JA: The Total Contact Cast. A therapy for plantar ulceration on insensitive feet. *J Am Pod Med Ass* 74: 548-552, 1984
- Ebenezer M, Parthebarajan S, Soloman S: Long-term follow-up of joint stabilization procedures in the treatment of fixed deformities of feet in leprosy. *Lepr Rev* 67:126-134, 1996
- Hetherington VJ: *The Neuropathic Foot*, William & Wilkins, 1992
- Johnson JTH: Neuropathic fractures and joint injuries. *J Bone Joint Surg* 49A-1:1-29, 1967
- Kornberg M: Neuropathic arthropathy. *Ortho Rev* 12(4):45-50, 1983
- Maas M, Slim EJ, Akkerman EM, Faber WR: MRI in clinically asymptomatic neuropathic leprosy feet: a baseline study. *Int J Lepr* 69: 219-224, 2001
- Macdonald MRC, Brandsma JW, Warren AG, et al.: Complications and management of the neurologically impaired foot. *Lepr Rev* 72: 263-275, 2001
- Meijer JWG, Links TP, Groothoff JW, Eisma WH: Evaluation of a screening and prevention programme for foot diabetic complications. *Prosth Orth Int* 25: 132-138, 2001
- Papa J, Myerson M, Girard P: Salvage, with arthrodesis, in intactable diabetic neuropathic arthropathy of the foot and ankle. *J Bone Joint Surg* 75-A (7):1056-1066, 1993
- Patout CA, Birke JA, Horswell R: Effectiveness of a comprehensive diabetes lower-extremity amputation prevention program in a predominantly low-income African-American population. *Diab Care* 23:1339-1342, 2000
- Patout CA, Birke JA, Wilbright WA, Coleman WC, Mathews RE: A decision pathway for the staged management of foot problems in Diabetes Mellitus. *Arch Phys Med Reh* 82:1724-1728, 2001
- Sinacore DR, Mueller MJ, Diamond JE: Diabetic plantar ulcers treated by total contact casting. *Phys Ther* 67:1543-1549, 1987
- Shibata T, TadaK, Hashizume C: The results of arthrodesis of the ankle for lepromatic neuroarthropathy. *J Bone Joint Surg* 72-A: 749-756, 1990
- Stuart MJS, Morrey BF: Arthrodesis of the neuropathic ankle joint. *Clin Orth Rel Research* 253: 209-211, 1990
- Warren AG: The management of tarsal bone disintegration. *Lepr Rev* 43:137-147, 1972
- Warren AG: The Surgical conservation of the neuropathic limb. *Ann Royal Coll Surg* 71: 236-242, 1989

## Common Peroneal and Posterior Tibial Nerve Paralysis

• M.R.C. MACDONALD

### INTRODUCTION

Loss of common peroneal function leading to paralysis of the anterior and lateral compartment muscle groups in the leg is common in leprosy.<sup>27</sup> The resultant foot drop leads to an abnormal compensatory high stepping gait and risk of ulceration to the (lateral) forefoot if there is concurrent sensory loss to the sole of the foot.<sup>13</sup> Brand described the anterior transposition of the tibialis posterior tendon (TPT) to the intermediate cuneiform, via a circumtibial approach.<sup>7</sup> Gunn and Molesworth reported fifty-six cases in which the tendon was taken via the interosseous route with insertion into the tarsal bones.<sup>14</sup> They reported good results in 49 cases but failed to describe the criteria for their results. Andersen published two papers in which five different procedures were described, including the interosseous route.<sup>2,3</sup> Thangaraj reported 50 cases using an interosseous approach with the transferred tendon inserted into extensor digitorum longus (EDC) and extensor hallucis longus (EHL).<sup>26</sup> Results were favourable, but it was noted that there was a decrease in range of movement compared to the Brand study. The focus at that time appears to be on resting position and range of movement rather than restoration of normal gait.

Srinivasan, in 1968, published a series with two aims:<sup>25</sup>

- a) to simplify and attempt standardisation of the procedure and
- b) develop criteria for assessing results.

He established standard criteria for measuring active dorsiflexion and range of movement. This was not correlated to function. Results showed improved dorsiflexion with concurrent Achilles tendon lengthening. Warren supported these similar findings in the same journal.<sup>27</sup> Warren also described the common post-operative problem of claw toes, which she attributed to compensatory tightening of flexor digitorum longus. She also described the problem of excess pronation in the immature foot following removal of tibialis posterior.

Carayon et al, reported on 23 cases in which a double transfer of tibialis posterior to tibialis anterior and flexor hallucis longus to EDC and EHL was done, both via the interosseous route.<sup>9</sup>

Warren reported complications such as osteopenia, leading to fracture and disintegration, and reaction with tendon to bone anastomosis.<sup>27</sup> Because of this complication a number of tendon to tendon insertions were described. Nowadays it is accepted that the first choice for correction of foot drop in leprosy and other peripheral neuropathies, is a tibialis posterior transfer via either the interosseous (IO) or circumtibial (CT) approach. A number of different tendon to tendon anastomosis are described. With isolated nerve loss to the anterior compartment of the lower leg and loss of the long toe extensors, the toes often lie plantar flexed. If these are mobile, they result in toe drop and this is usually corrected by routine TPT with insertion to EDC.

In addition to common peroneal nerve paralysis there is often function associated loss

of posterior tibial nerve function leading to loss of the intrinsic muscles of the foot. This paralysis leads to hyperflexion at the distal and proximal interphalangeal joints (claw toes), which may remain after TPT. In some cases a transfer of flexor to extensor tendon in the toe maybe required or if there is fixed non-correctable damage to the joints of the toe, fusion is indicated.

In the case of isolated posterior tibial nerve loss where the toe extensors are still functioning there is a tendency for the extensors to pull up the toes dorsally, while the intrinsics and other soft tissue structures contract and pull the toes plantar ward. This can lead to retracted toes.

## COMMON PERONEAL NERVE PARALYSIS

### *Surgery versus Conservative Treatment*

Surgical options and alternatives in common peroneal nerve impairment:

- 1) Untreated foot drop may result in contracture and the development of secondary deformities and ulceration. Therefore, if surgery is available, this should be the first choice.
- 2) **Steroids:** Multiple large studies have shown an improved rate of recovery of peroneal nerve palsy following a short-term course of steroids e.g. twelve weeks.<sup>10</sup> Success depends on the duration of the nerve involvement and whether it is complete or incomplete. Some studies have shown recovery with lesions up to one year. Greater likelihood of nerve recovery is in the partially impaired nerve, especially if the history of footdrop is less than twelve months.
- 3) Surgical decompression of the common

peroneal (lateral popliteal) nerve: Some authors have recommended nerve decompression with the addition of steroids in early lesions. There is no clear evidence of the benefit of surgery in addition to steroids alone. However, benefit may be gained particularly when there is persistent nerve pain. (Chapter 3)

- 4) **Orthotics:** The use of orthotics helps to prevent contractures and secondary deformity and will facilitate normal gait. The use of a splint such as an ankle foot orthosis (AFO) prevents shortening of the Achilles tendon. Dynamic splints whether long (below knee) or short (ankle cuff) assist gait and maintain mobility pre operation (Fig. 14-1). There is also some evidence suggesting that there is improved recovery of the nerve if the foot is maintained in a normal position.<sup>13</sup>

**Purpose of surgery:** The main purpose of corrective foot drop surgery is to restore normal gait.<sup>16,17</sup> It is important, therefore, to view the affected foot in terms of disrupted biomechanics. If concurrent to the motor loss, there is



**FIGURE 14-1** Dynamic foot drop splint.



diminished protective sensation to the sole, the foot is at increased risk of developing ulcers. In footdrop with a plantar grade foot and a tendency to equinovarus there is increased pressure loading on the lateral border and forefoot. Following corrective surgery heel strike is restored and the loading is changed, which will result in decreased lateral border and forefoot ulceration. Some authors have suggested that surgery does not affect the frequency of ulceration merely the distribution.

### **Functional Anatomy**

#### **Nerve supply**

The muscles of the anterior and lateral compartments of the leg are supplied by the common peroneal (lateral popliteal) nerve. The nerve passes down obliquely through the lateral side of the popliteal fossa, travels between the tendon of biceps femoris and the lateral head of gastrocnemius then wraps around the fibular neck before dividing into deep and superficial branches. Rarely (1%) the nerve divides into its two branches proximal to the fibular neck. Adkison found that the course of the superficial peroneal nerve is more variable than commonly thought.<sup>1</sup>

The superficial branch supplies the peroneus longus (PL) and brevis (PB) then the skin over the lateral aspect of the lower leg onto the dorsum of the foot, except the 1st web space. Paralysis of this branch causes weakness of eversion of the foot and sensory loss.

The deep branch supplies the anterior muscle groups, Tibialis Anterior (TA), Extensor Hallucis Longus (EHL), Extensor Digitorum Communis (EDC) and Peroneus Tertius (PT), dividing into medial and lateral branches before finishing in a terminal branch supplying sensation to the first web space on the dorsum of the foot. Paralysis leads to lack of dorsiflexion of the ankle and minor sensory loss. The nerve also supplies the dorsal intrinsic muscles

of the foot: extensor hallucis brevis and extensor digitorum brevis.

#### **Muscle actions**

The anterior muscle group passes in front of the axis of the ankle joint and dorsiflexes the ankle. The prime mover of dorsiflexion in a neutral plane is tibialis anterior. Extensor hallucis longus and EDC act as secondary dorsiflexors of the ankle. Peroneus tertius has the additional role of everting the foot and acts with the peroneal group to prevent forced inversion of the forefoot on dorsiflexion. This helps the foot to maintain its normal gait pattern without striking excessively on the lateral boarder. The range of movement and power of dorsiflexion depends on the length of the moment arm and excursion. Tibialis anterior and EHL have a short moment arm and long excursion (3 to 5 cm).<sup>22</sup> This compares to the tibialis posterior with an excursion of 2 cm. There is an inverse relationship between moment arm and excursion. A long moment arm gives a smaller excursion or range of movement but more power.<sup>8</sup>

#### **Tibialis Posterior Muscle**

The Tibialis Posterior arises from both the tibia and fibula and the interosseous membrane between flexor digitorum longus (FDL) and flexor hallucis longus. It passes deep to these muscles in the lower leg sharing a common groove with FDL behind the medial malleolus but in a separate sheath. It then passes inferior to calcaneo-navicular ligament contains a sesamoid bone and then divides into two slips. The larger, superficial and medial division, inserts into the tuberosity of the navicular and medial cuneiform. The smaller, deeper and lateral division gives tendinous slips to the intermediate cuneiform and base of the 2nd, 3rd and 4th metatarsals.

### **Biomechanical considerations**

A full biomechanical understanding of the normal foot is important to understand stability of the foot in standing and the transfer of forces during gait phase (Chapter 12). Biomechanical considerations are required in understanding changes that occur with nerve involvement e.g. foot drop and the alteration occurring from tendon transfer e.g. hind foot instability from tibialis posterior detachment.

### ***Pathogenesis of nerve damage***

Damage of the common peroneal nerve in leprosy may result in paralysis of all the muscles in the anterior and peroneal compartments. The paralysis leads to loss of ankle dorsiflexion, foot eversion and toe extension and produces footdrop, toe drop and a tendency toward equinovarus deformity. Most commonly, both the superficial (peroneal compartment) and deep (anterior compartment) are involved. However, either branch can be spared particularly where there is variable anatomy. If a single branch is involved this is most commonly the deep branch, leading to isolated paralysis of the ankle dorsiflexors with intact inversion and eversion.<sup>21</sup> Less commonly the superficial branch can be singularly involved maintaining dorsiflexion with weakness of eversion. Antia describes the pattern as beginning distally with involvement of the great toe extensor then the lateral four toes.<sup>4</sup> This progresses proximally to affect the prime dorsiflexor of the ankle. Fritschi describes a small residual group where the pattern is variable and extensor hallucis longus may be spared leading to weak dorsiflexion of the ankle as a secondary action to the prime movement of hyperextension of the great toe.<sup>12</sup>

### ***Structure and Function loss***

#### **Primary deformity**

Loss of the common peroneal nerve in leprosy leads to loss of dorsiflexion resulting in foot

drop. The resting position of the foot is plantar flexed and inverted. Where the superficial branch is not affected the muscles of the lateral compartment, peroneus longus and brevis, are spared maintaining eversion. Losses of the long extensors of the toes, EHL and EDC, results in drop toes. The affect of this paralytic deformity is an alteration of gait, characterised by exaggerated ankle equinus and increased hip and knee flexion during the swing phase of the walking cycle.<sup>21</sup> The function of the anterior muscles is to dorsiflex the foot allowing clearance of the forefoot and normal heel strike. With these muscles paralysed the foot hangs down in normal gait and to compensate the person exaggerates the lift, as in climbing steps, to avoid tripping over the forefoot. This is known as a "high stepping" gait. With the foot inverted and plantar flexed, strike tends to occur on the lateral border making it susceptible to damage. There is also instability around the ankle and subtalar joints, on weight bearing, as the contralateral leg moves through its swing phase.

#### **Secondary deformity**

Secondary shortening of the Achilles tendon can occur as a result of longstanding untreated foot drop. Early intervention with mobilisation, active splint (e.g. footdrop spring) and stretching can prevent this. If left, the foot will tend into plantar flexion and inversion. This may result in a stiff foot with an equino-varus deformity. Long standing plantar flexion leads to contracture of the intrinsic muscles of the foot. If this is associated with posterior tibial nerve loss then clawing of the toes can occur. In these situations clawing needs to be addressed, as well as restoring active dorsi-flexion of the ankle.

#### ***Inclusion criteria for Tibialis Posterior Transfer***

Listed are consensus guidelines for suitability of a limb for TPT, in addition to the standard

criteria for tendon transfer surgery as outlined in Chapter 1.

**1. Ankle joint:** Following preoperative physiotherapy, a minimum of 10 degrees of dorsiflexion from neutral with the knee flexed is required. Due to the post operative loss of resting position of an average of 10 degrees over the first year following surgery, a minimum passive dorsiflexion is required.<sup>16</sup> This is measured with the knee bent to eliminate the effect of gastrocnemius tightening.

**2. Neuropathic foot:** No evidence of active neuropathic bone disintegration (NBD) for a minimum of three months following the completion of trial walking.<sup>16</sup> The stress of surgery can lead to a flare up of any unresolved NBD. Postoperative immobilisation in a cast can lead to osteopenia and precipitate NBD.

**3. Dorsiflexor weakness:** Dorsiflexor or everter weakness MRC 0-2. Grade 3 or more can lead to a functional gait.

**4. Use of crutches:** Able to mobilise with crutches or a walking frame. This is critical to successful postoperative re-training.

**5. Self-care:** Demonstrated ability to look after skin of affected limb. In a limb with anaesthetic sole, patient directed self care of the limb must continue postoperatively for life.

### ***Pre-operative Physiotherapy***

The success of the TPT procedure is critically dependent on quality pre- and postoperative physiotherapy. The physiotherapist role in management and as part of the surgical team in decision making such as timing of surgery and discharge is essential. An extensive description of physiotherapy management and assessment is not possible here (see chapter 21). Presented are key features specific to TPT. All the exercis-

es should be taught to the patient to facilitate these on an ongoing basis.

**1. Assessment:** Assessment should include both the patients and surgeons perspective. It is important to determine whether the patients' requirement is one of appearance or function and how this affects the activities of daily living or a particular occupation.

**2. Flexor tendon tightening** of the long flexors of the toes can result in clawing and these need to be assessed and treated (see claw toes).

**3. Isolation of transfer:** Tibialis Posterior needs to be isolated and 'strengthened'. This will facilitate postoperative re-education.

**4. Balance exercises:** This improves proprioception and stability of the subtalar joint.

**5. Use of crutches:** Demonstration of the use of crutches and modification when there is concurrent hand disability speeds the postoperative recovery.

**6. Footwear:** Measurement for any special footwear needed post operatively.

### ***Achilles Tendon Lengthening (TAL)***

**Introduction:** Achilles tendon tightening is a common feature of persistent foot drop. The indications for Achilles tendon lengthening in the literature are not clear. Early literature recommended lengthening where there was more than residual restriction to passive dorsiflexion after pre operative stretching.<sup>25</sup> Review of failure and recommendations by the group involved in the neurologically impaired foot workshop suggested that one of the most common contributors to a poor result is failure to adequately lengthen the Achilles tendon.<sup>16</sup> They recommended that TAL should be routinely done with all TPT's.

**Closed versus open:** Two techniques are available to the surgeon for TAL. They are 1) Closed or percutaneous method and 2) Open or commonly called Z-lengthening. No long-term studies comparing these two methods have been published. The closed approach is relatively simple, quick and has low associated morbidity. The advantage of the open technique is that maximum passive dorsiflexion can be guaranteed. However, there is increased morbidity associated with a surgical wound in the paratendon Achilles region due to poor blood supply. Using a closed technique up to 30-40 degrees of passive dorsiflexion with the knee flexed should be achieved following surgical release.

**Closed technique:** Closed technique consists of a sliding lengthening. Under anaesthetic with the knee straight and the foot held in forced dorsiflexion resting on the surgeon's hip a percutaneous Achilles tendon lengthening is made. Using a size 11 or 15 blade a stab incision is made in the distal medial half of the tendon 1 cm above its insertion into the calcaneum. A second proximal lateral stab incision is made at the musculo-tendinous junction. With continued forced dorsiflexion the fibres of the Achilles tendon are allowed to slide. This results in a passive dorsiflexion of at least 30 to 40 degrees from neutral. The tendon is palpated externally to ensure continuity proximally and distally. The principle of this procedure is to allow a slide of the fibres within the tendon sheath without complete rupture of the tendon. This procedure is well described in children with spasticity in the Achilles tendon due to e.g. Cerebral Palsy.<sup>5,23</sup>

**Open technique:** When there remains posterior capsular tightening after exercises or maximum length needs to be ensured, then a standard open Z-lengthening can be performed. Careful placement of a concave curved incision

posterior medial above the medial malleolus can allow both access to the Achilles tendon and retrieval of tibialis posterior for tendon transfer. As per the closed technique after opening the tendon sheath the Achilles tendon is divided through half its bulk both proximal-lateral and distal-medial and then split down its length.<sup>23</sup> The two ends are then sutured side to side for one to three cms.

### **Tibialis Posterior Transfer: technique**

**Interosseous route:** Under spinal or general anaesthetic the patient is placed in a supine position and an above knee tourniquet is applied. An Achilles tendon lengthening procedure is first performed. If an open lengthening is done then the same incision can be extended, curved proximally and medially to allow for both delivery of the tibialis posterior tendon, and access to the interosseous space. An 8 cm curved or straight incision is made starting one to two finger breadths proximal to the medial malleolus in the line of the tendon. The tibialis posterior tendon is exposed lying deep to the tendon of flexor digitorum longus. Care is taken not to damage the long saphenous vein or the saphenous nerve. A skin crease incision is made just proximal to the tibialis posterior insertion to the navicular on the anterior-medial aspect of the ankle. At this level it is easily palpable. The tendon insertion is exposed and an artery forceps placed across the tendon with the foot adducted. The correct tendon is confirmed by pulling on it above the malleolus. The tendon is then divided at its insertion, freeing both superficial and deep attachments to maintain length. In the incision proximal to the medial malleolus, a digit or blunt instrument is placed under the tibialis posterior tendon just distal to the musculo-tendinous junction and the tendon is delivered into the wound. It is important to try and avoid stripping the distal

muscle fibres directly off the tendon. By blunt dissection the tibialis posterior tendon and its muscle unit is stripped off its origin from the tibia in the middle third of the calf, mobilising the complete unit. The adequacy of the interosseous space can often be determined at this stage. An eight cm longitudinal incision is made over the anterior aspect of tibialis anterior 1-cm posterior to the prominence of the anterior tibial border in the distal half of the middle third of the calf (Fig. 14-2). Using a pair of long dissecting scissors a complete fasciotomy is performed. By blunt dissection and a right-angled retractor the muscle of tibialis anterior is retracted to expose the interosseous membrane. Care is needed not to tear the deep veins as haemostasis is difficult and subsequent bleeding can lead to adhesions as the tendon passes through the interosseous space. A small incision is made in the membrane, and this is extended by blunt dissection as far proximal as possible. At this stage it is important to confirm the suitability of the interosseous space for the transfer. The space narrows distally and can sometimes be irregular on its tibial surface. The tip of a little finger should pass easily through this space. Some authors advocate a pre operative X-ray of this space as a guide, but this has not been standardised. Should there be excess irregularity or the space very narrow then the interosseous approach should be changed to a circumtibial at this stage.

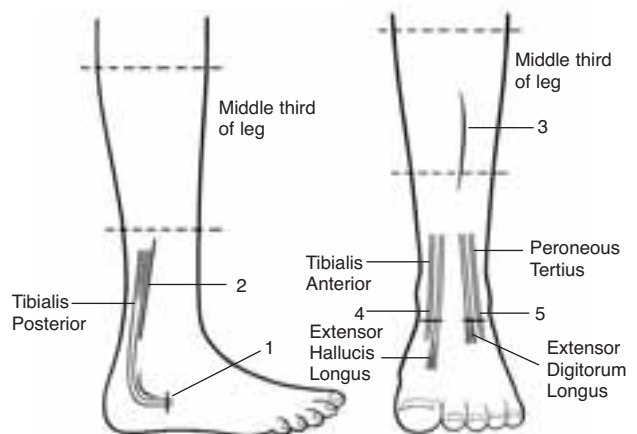
A large curved Anderson tendon tunneler is passed through the interosseous space and around the posterior aspect of the tibia. The tibialis posterior tendon is then brought into the anterior compartment and under tibialis anterior to lie lateral to it. This decreases the possibility of adherence between the raw muscle fibres of tibialis posterior and the surface of the tibia. At this stage it is useful to check that there is sufficient length to reach the tendons over the anterior aspect of the ankle. If insufficient length is present then further stripping of the

muscle of tibialis posterior from its bony origin may be required. The wounds on the medial aspect of the leg are irrigated and closed.

Transverse skin crease incisions are made over the distal portion of the anterior aspect of the ankle after palpating the tendons (Fig. 14-2). A number of options of insertion exist. The author's preferred method is a two-slip tendon to tendon anastomosis, the medial slip to TA and EHL with the lateral slip to EDC and PT. The tendons are identified by sharp dissection, and a stay loop or towel clip is passed around the tendons.

The tendon of tibialis posterior is split longitudinally to the point where the distal muscle fibres insert. A buried suture is placed inside the base of these two slips. This stops the slips from separating further during the attachment or at the time of mobilisation thus maintaining the tension on the slips.

A subcutaneous tunnel is made superficial to the extensor retinaculum using long blunt tendon tunnellers. With care to avoid twisting the two slips they are passed using tendon tunnelers to the two distal incisions over the ankle. It is important to check that these tunnels are free from restrictions and the tendon slips move freely. This can be done by blunt digital dissection from proximally to distal.



**FIGURE 14-2** Skin incisions for TPT.



With the knee flexed the ankle is held in at least 20 degrees dorsiflexion, (by an assistant or using a Fritschi splint) the tendons are anastomosed using a double weave technique (Fig. 14-3). The lateral slip is weaved through Peroneus Tertius and EDC from lateral to medial to lateral. This should be done with the tension on Peroneus Tertius initially and then to EDC at neutral tension. This should utilize the transmitted force to dorsiflex the ankle rather than extending the toes, which can increase the clawing deformity. The two weaves should be in different planes, preferably at right angles to stop the weave becoming single. The lateral slip is pulled through and sutured at maximum tension using a 2/0 suture. The medial slip of tibialis posterior is then sutured in neutral tension after double weaving through tibialis anterior and EHL (medial to lateral to medial). This helps to keep the two slips divergent and increases the mechanical balance acting on the foot. The ends of the tendon slips are then buried under the extensor retinaculum.



**FIGURE 14-3** Footdrop splint.

With the knee flexed the foot is released and its position checked. Richard reported a loss of 10 degrees between splint and release angle.<sup>22</sup> A further loss of 10 degrees in the first year

post operative suggests there should be a resting position of at least 20 degrees dorsiflexion.<sup>16</sup> The foot should also be in neutral or mild eversion. If the position is not satisfactory then the slips should be adjusted on the table.

The wounds are dressed and a below knee cast applied with the foot in neutral and 15 to 20 degrees of dorsiflexion for 3-4 weeks, after which physiotherapy is commenced (see Chapter 21).

**Circumtibial route:** The principle of the circumtibial approach is the same as the interosseous except the tibialis posterior tendon doesn't pass through the interosseous canal into the anterior compartment. It is critically important to maximise vertically the angle the tendon takes into the foot to mechanically mimic the action of the anterior group of muscles. The operation proceeds as per interosseous approach with an Achilles tendon lengthening and the Tibialis Posterior tendon released from its insertion to the navicular. Incisions and stripping of the Tibialis Posterior are as described for the interosseous approach, except that the lateral calf incision is not used. A subcutaneous tunnel around the anterior-medial aspect of the lower tibia is made, superficial to tibialis anterior and the extensor retinaculum to the dorsum of the ankle. This must reach the midline at least 5 cm above the ankle to ensure a good angle of pull. The tendon is then split into two slips and passed separately or split after passing to the ankle. The procedure then continues as per interosseous route. Some authors have found a tendency to delayed inversion deformity.<sup>24</sup> This can be avoided by careful tunnelling from as high as possible and attention to the tension of the slips while suturing the anastomosis.

### Insertion

**1. Single versus Double:** Antia recommended the use of a single slip passed either via

interosseous or circumtibial route. Insertion was into the soft tissues over the tarsus, where pulling on these tissues with forceps brings the foot into neutral.<sup>4</sup> This is difficult to balance and can lead to an inversion or eversion deformity. Srinivasan described a high division of tibialis posterior into two slips, feeding them through separate subcutaneous tunnels and inserting into EHL and EDC.<sup>25</sup> Thangaraj recommended a division more distally with insertion into tibialis anterior and laterally to EDC.<sup>26</sup>

**2. Moment arm:** The moment arm of a tendon crossing a joint determines the range of movement and the power that tendon can generate.<sup>22</sup> In essence the more distal the attachment of tendon into the dorsum of the foot the longer the moment arm resulting in increased power but decreased range of movement.

**3. Strength of insertion:** It is now well accepted that a double weave technique, as described by Pulvertaft, leads to a strong tendon to tendon anastomosis and this is recommended.

**4. Range of movement:** Range of movement is determined by the excursion of the tendon, moment arm, and mobility of the ankle joint. Ankle joint movement is affected by lengthening of the Achilles tendon, ankle capsular tightness and joint surfaces.

**5. Options:** Multiple authors have described insertion of tendon slips into all the extensors over the dorsum of the foot. Consistently a slip is inserted into tibialis anterior and variably also extensor hallucis longus to provide medial pull, and extensor digitorum communis (EDC) variably including peroneus tertius to provide lateral pull. The involvement of peroneus tertius may counteract the tendency to the post-operative clawing seen where EDC alone is used. Some authors have advocated a slip to peroneus brevis to counteract any tendency to

inversion.<sup>24,27</sup> This can if overcorrected produce the opposite eversion deformity. Both inversion and eversion should be avoided. The individual choice of insertion should result in a balanced foot dorsiflexing in a neutral plane, with adequate range of movement and no secondary effects e.g. cocked great toe.

**6. Tendon-tendon versus bone:** Initially to gain rigid attachment the transferred tendon was inserted through a hole in the middle cuneiform. Harris and Brand reported that this could lead to osteopenia and predispose to neuropathic degeneration.<sup>15</sup> Post-operative immobilization time is also prolonged. As a result tendon to tendon anastomosis is strongly recommended.

Brand describes tendon-tendon anastomosis are strong enough for careful movement at 3 weeks, reasonable at 4 weeks and against resistance at six. Where there is inadequate or inexperienced physiotherapy or poor patient compliance, it may be beneficial to leave the initial cast on for six weeks to ensure strong fibrosis at the anastomosis. The balance between strong anastomosis, to prevent rupture, and early movement, to prevent adhesions, needs to be judged.

### **Management of Complications**

**Lack of dorsiflexion:** The restoration of normal gait is related to the resting position of the foot and the range of movement. The larger the range of movement, provided this allows for dorsiflexion above neutral, the better the gait. However even a small range of movement (5 degrees) can be functional. It has been suggested that active dorsiflexion post transfer of a minimum of 5 degrees above neutral is required. Allowing for a 10 to 15 degree drop in the first post operative year if there is not active dorsiflexion to 5 degrees above neutral then

either a heel raise on the shoe or a further procedure should be considered.<sup>22</sup> A significant contributor is contraction of the Achilles tendon. This should be considered to be lengthened routinely.<sup>16,21,22</sup> Options where the tibialis posterior tendon slips appear long include a) Reefing the tendon. This allows for shortening without dividing the tendon, b) reinsertion of the tendon taking up any residual slack, c) shifting the anastomosis distally.

**Residual inversion/eversion:** Both inversion and eversion should be avoided.<sup>12,13</sup> However inversion is a more common complication and can lead to excess pressure on the lateral boarder of the foot and increased incidence of ulceration. In the first instance it is simplest to rebalance the foot with reefing or reinsertion of the lateral slip or shifting the single slip more laterally. Soares found that this complication was more common in circumtibial procedures.<sup>24</sup> Other authors have not supported this and it may be a result of the tibialis posterior tendon wrapping around the tibia too distally with the line of pull medially rather than vertically. If rebalancing is insufficient Soares recommends an extra graft from the lateral slip to the insertion of peroneal brevis.<sup>24</sup> Warren describes dividing peroneus brevis just proximal to the lateral malleolus leaving its insertion attached, re-routing it to the dorsum of the ankle, weaving it through the tibialis posterior tendon where it is inserted into extensor digitorum communis and attaching it again distally to the periosteum over the neck of the 5th metatarsal (personal communication). This effectively acts as a sling to help evert the lateral aspect of the foot.

**Lack of Range of movement:** Minimal range of movement can be due to

- a) Adhesions
- b) Poor patient motivation
- c) Decrease in muscle power.

Adhesions between the interosseous space and tibialis posterior muscle can be minimised by ensuring haemostasis during operation to minimise haematoma, by ensuring adequate space by intra operative assessment and not taking the muscle through the narrow space distally. The most common places for the tendon to adhere is in the interosseous space, if passed low, or in the subcutaneous tunnels. These need to be adequate with no fibrous septae and a long fasciotomy. Should adhesions occur early, active mobilisation or friction therapy are indicated. If they occur late then they may require surgical release.

Poor gliding is often found around the ankle. Tunnelling superficial to the extensor retinaculum will decrease this. Some authors have noticed bowstringing, but this is generally cosmetically acceptable.

Again a full superficial fasciotomy proximally and distally is required. Oomen describes the rare event of paralysis of the transferred muscle due to precipitation of acute neuritis of the medial popliteal nerve (tibial nerve) following surgery.<sup>21</sup>

**Poor gait:** A small proportion of patients neglect to use the transferred tendon and persist with a high stepping gait. In this case a period of intense retraining with the knee straight and particularly focusing on gait is useful.

**Secondary claw toes:** It is important to assess the degree of clawing pre-operatively (see section on claw toes) Restoring dorsiflexion with pre-existing tightness of the intrinsic muscles of the foot and shortening of the long flexors will increase the degree of clawing. Marked clawing whether passively correctable or not should be corrected at the time of TPT. Mild clawing is usually not symptomatic. Moderate clawing commonly requires correction, which can be done at the time of TPT or delayed until assessment following the TPT.

**Hind foot instability:** The detachment of the Tibialis Posterior tendon from the site of insertion deprives the foot of pronatory action and support of the medial longitudinal arch. This can potentially lead to hind foot instability. Cross, suggests that a medial stabilizing orthosis (or 'Hati' pad) may be beneficial.<sup>11</sup>

**Reverse Metatarsal arch:** Reversed metatarsal arch can result in hyper-extended metatarsophalangeal joints, increasing the risk of ulceration under the metatarsal heads. Srinivasan has advocated proximal shifting of EDL to the metatarsal neck, sometimes combined with fusion of PIP joints, and shaving off the plantar aspect of the head of the metatarsal.<sup>16</sup> This he recommends as an alternative to metatarsal head resection.

## POSTERIOR TIBIALIS PARALYSIS

Rarely in leprosy the posterior tibialis is paralyzed. This is more common in polio or trauma. If all muscles below the knee are paralysed, the result is a flail foot, which tends to flap on walking. Hypermobility of the foot leads to a) compensatory high stepping gait, b) risk of plantar ulceration consequent to abnormal strike during gait and c) instability of the ankle during weight bearing. Treatment ranges from conservative splinting to permanent arthrodesis.

### Orthotics

The two keys of orthotic or splinting management are control of the unstable ankle and subtalar joints. Instability is much greater when the gastrocnemius is also paralysed. There is a tendency for marked pronation of the hind foot and this can be limited by the use of a medial stabilising pad such as a "Hati" pad (Chapter 17). However this is seldom sufficient and the support of a calliper or a fixed ankle brace will

usually be required (Chapter 23). Ankle instability requires a minimum of an ankle foot orthosis (AFO). This simply acts as a fixed back slab and helps prevent tightening of the Achilles tendon. However, this too is generally insufficient and the addition of a stable above ankle boot is required. If despite a stable boot and AFO there is continual tendency for the hind foot to roll into pronation then a fixed ankle brace is recommended.

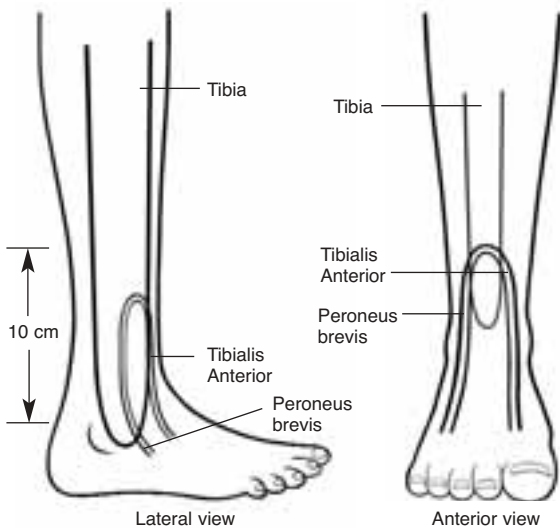
### Tenodesis

Stability to control the degree of passive dorsi- and plantar flexion of the foot at the ankle can be achieved by tenodesis. Tenodesis maintains ankle flexion while preventing toe drag during the swing through phase of gait. It also helps stabilise the hind foot giving increased stability on weight bearing and during heel strike.

The principle of this surgery is to give the foot two sets of guy ropes to hold the foot plantar grade at rest but allow passive dorsi- and plantar flexion during gait.

**Technique:** An open Z-plasty of the Achilles tendon is performed with the addition of a posterior ankle capsulotomy if required to allow passive dorsiflexion to 15 – 20 degrees. The tendons of tibialis anterior and peroneus brevis are divided at their musculotendinous junctions in the middle third of the leg and brought out at the point of their insertions in the foot. They are then tunnelled subcutaneously and superficial to the extensor retinaculum to the tibia at the junction of the middle and lower thirds. The tendon of tibialis anterior is passed medial to lateral through a transverse drill hole in the tibia. It is then double weaved through the tendon of peroneus brevis with the foot held at 15 degrees of dorsiflexion (Fig. 14-4). The tendon is further sutured to the tibial periosteum on both sides to encourage adhesions. An initial padded cast subsequently

changed to a total contact cast is applied for a total of eight weeks. Following the removal of the cast the patient is mobilised with crutches until stable and safe during walking. Minimal physiotherapy is generally required. The foot should be protected in a resilient shoe and the posterior half of the cast used for three months at night to prevent passive stretching.



**FIGURE 14-4** Tibialis anterior/ peroneus brevis tenodesis for foot drop.

This procedure seems to work best when there is no gross ankle instability. When the gastrocnemius is still functional it will tend to stretch significantly with time. When the ankle is grossly unstable a tenodesis alone is unlikely to provide long-lasting stability to the foot.

### **Half gastrocnemius split**

Where there is marked paralysis of the lower limb, the gastrocnemius/soleus group frequently remains the only functional muscle for tenodesis. Transfer of one head of gastrocnemius balances the muscle function across the ankle. Warren describes a modification of the Caldwell procedure (personal communication).<sup>28</sup> It is also described for patients with gastrocnemius paralysis, but it would be likely

to stretch significantly with time in this situation.

**Technique:** The medial half of gastrocnemius/soleus complex is split down to its calcaneal insertion. It is then transferred by a circumtibial route through the tibialis anterior tendon and attached to the peroneal brevis tendon after division at the ankle and re-routing back to the dorsum of the ankle. A lengthening Z-plasty is performed on the remaining half of the Achilles tendon, to allow a minimum of 15 degrees of dorsiflexion from neutral. There is a tendency to secondary development of clawing of the toes and a flexor to extensor transfer (Girdlestone) is advised to be performed concurrently. If there remains marked equinovarus deformity of the hind foot Wolf et al advised a concurrent Dwyer calcaneal osteotomy.<sup>28</sup> The procedure acts as an ankle stabilizer. Actual control of the ankle will be minimal. A period of eight weeks in a cast with the foot dorsiflexed is advised to ensure adequate fibrosis.

### **Arthrodesis**

In some patients following a tenodesis there will be persistent instability of the subtalar and ankle joint. In others bony or joint destruction limits the passive range of movement even after Achilles tendon lengthening and capsulotomy. In these cases a more extensive procedure is required. A triple fusion may be adequate, possibly combined with a tenodesis. This stabilises the subtalar joint (preventing excessive pronation) the talar-navicular and calcaneal-cuboid joints. Barr advocated a tendon sling using tibialis anterior and peroneus longus combined with a triple arthrodesis to prevent inversion.<sup>6</sup> In leprosy it is common to have collapse at the midtarsal level with abduction or adduction of the forefoot. Corrective osteotomy of the talar-navicular joint and calcaneal-cuboid joints corrects this, giving stability of the forefoot on weight bear-



ing and making the wearing of footwear easier. The triple fusion leaves the ankle joint free and assists walking. X-rays with the foot in full forced varus and valgus will help determine whether the instability is principally in the subtalar or ankle joint. Especially in early onset neuropathy such as polio the instability can be principally in the ankle joint. In this situation or where there is additional significant destruction of the ankle joint, the ankle joint can be fused as a pan-talar fusion (Chapter 13).

## TOE DEFORMITY IN NEUROPATHY

### Pathogenesis

The Posterior Tibial nerve and plantar nerves are commonly damaged in leprosy.<sup>21</sup> It is vulnerable posterior to the medial malleolus where being superficial, it is susceptible to repetitive trauma and constriction within the Tarsal tunnel. This leads to plantar anaesthesia and “clawing” of the toes. Early clawing is

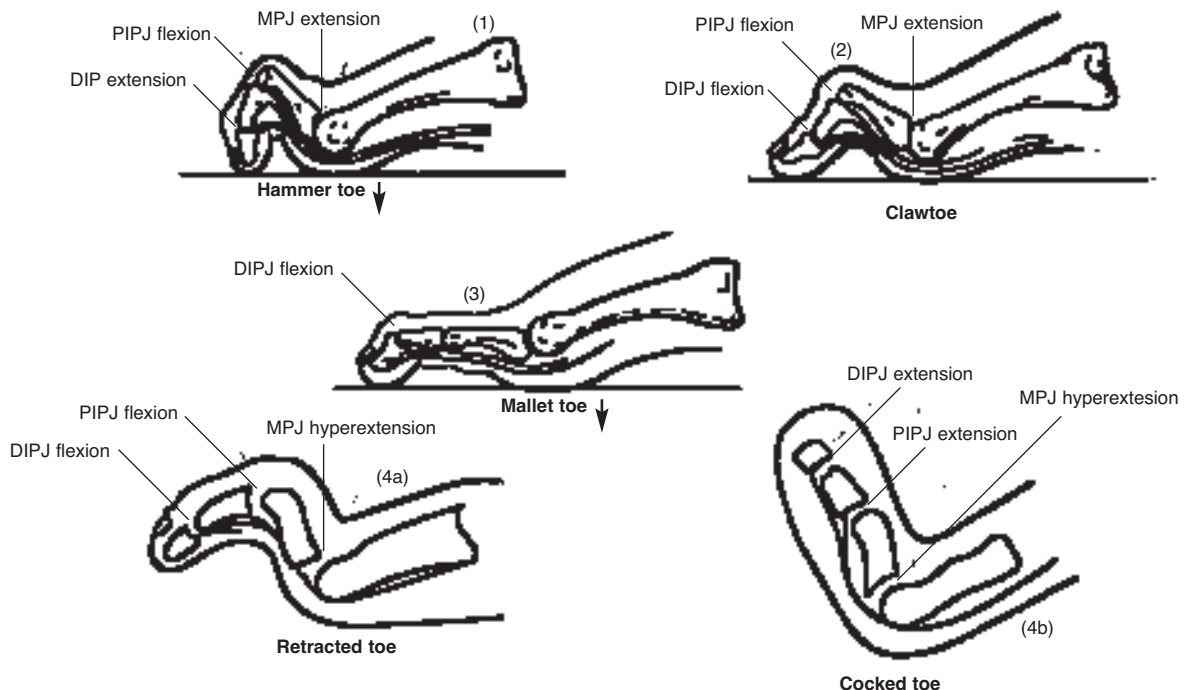
often unrecognised and neglected. Late fixed clawing alters the normal biomechanics of the forefoot increasing the risk of ulceration. Where there is concurrently lateral popliteal nerve palsy with drop toes there is a tendency to more severe clawing due to contracture of the intrinsic muscles of the foot. Early mobile clawing can be treated conservatively with good foot care. A Kelikian push-up test helps assess the flexibility of a lesser toe deformity.<sup>19</sup> More extensive involvement requires surgical intervention.

### Classification

Classification is based on either anatomical appearance or pathologic progression.

#### Anatomical Appearance

- 1 Hammer toe:** Dorsiflexion of the proximal phalanx at the metatarsal phalangeal joint (MTPJ) with the proximal interphalangeal joint (PIPJ) in neutral or plantar flexion and dorsiflexion of the distal interpha-



**FIGURE 14-5** Classification based on anatomical variance.

langeal joint (DIPJ) with the pulp of the tip on the ground (uncommon in leprosy).

- 2 **Claw toe:** As per hammer toe but the DIPJ is plantar flexed with the nail tip on the ground.
- 3 **Mallet toe:** Plantar flexion of the DIPJ only with rest in neutral (uncommon in leprosy).
- 4 a) **Retracted toe:** As per claw toe but the tip does not touch the ground during weight-bearing due to excessive dorsiflexion at the MTP joints.  
 b) **Cocked toe:** If the DIP joint is dorsiflexed this is sometimes called a cocked toe.

**Pathologic progression**

Antia describes three progressive stages from normal.<sup>4</sup> (Fig. 14-6 )

- a) **1st stage:** Dorsiflexion at the MTP joints; plantar flexion PIP joints and DIP joints with the tip of the toe on the ground during weight bearing. This can lead to an ulcer on the tip.
- b) **2nd stage:** Increased dorsiflexion of MTP joints and plantar flexion of PIP joints. The DIP joints may be in neutral. The tip usual-

ly does not touch the ground during weight bearing and there is risk of ulceration over the dorsum of the PIP joints.

- c) **3rd stage:** Hyperextension at the MTP joints thinning the soft tissues and increasing pressure over the plantar aspect of the MTP head resulting in an ulcer.

**Management**

**Orthotics**

For more information on orthotic devices that can be useful in correction of paralytic deformity and management and prevention of plantar ulceration see chapters 17 and 23.

**Surgery**

The appropriate surgery depends upon the type of deformity.

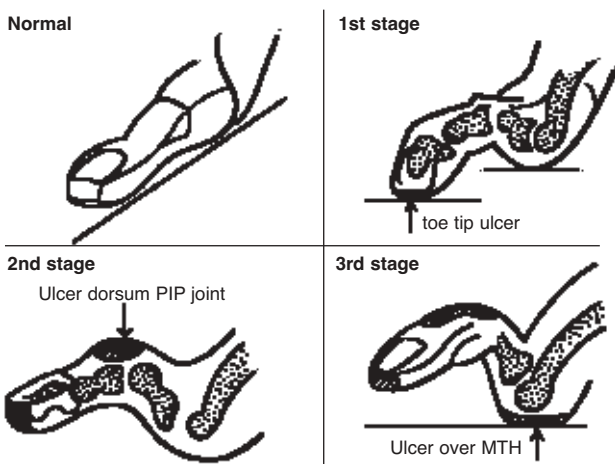
**Correction of hammer toe**

- 1) In mild deformity where there is no concurrent joint contracture a flexor to extensor transfer (Girdlestone procedure) is recommended.
- 2) In moderate deformity where there is limitation of the PIP joint a resection of the distal half of the proximal phalanx is advised. In addition a percutaneous tenotomy of extensor digitorum longus may be required.
- 3) In severe deformity where there is limitation of the PIP joint and often contracture and hyperdorsiflexion of the MTP joint, a resection of the distal end of the proximal phalanx or a PIP joint fusion is required. In addition soft tissue and joint contractures require release as well as tenotomy or lengthening of extensor digitorum longus.

**Correction of Claw Toes**

**Flexor to extensor transfer**

Flexor to extensor transfer, or Girdlestone procedure, is indicated for mobile claw toes. If

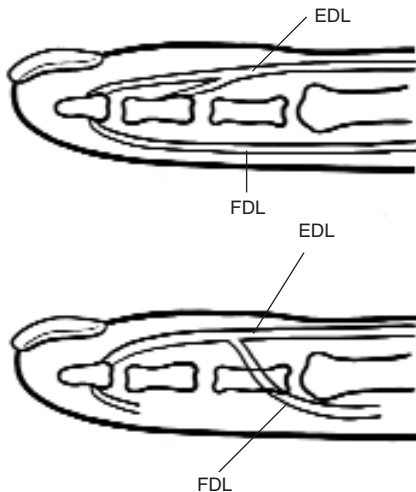


**FIGURE 14-6** Progressive stages from normal in claw toe deformity (modified from Antia<sup>4</sup>).

there is joint capsule tightness this can be released at the same time to mobilise the PIP joints.

### Technique

Under anaesthesia a curved S-shaped incision is made over the dorsum of the proximal phalanx extended distally over the lateral aspect of the toe to just past the DIP joint. The tendon of flexor digitorum longus is detached from its insertion and reinserted into the extensor tendon over the proximal phalanx with the toe held in neutral (Fig. 14-7).



**FIGURE 14-7 a.** Showing pre-operative anatomy. **b.** FPL has been divided and transferred to dorsum of toes and sutured to EPL.

Any restriction to extension of the PIP or DIP joints should be corrected by soft tissue release or capsulotomy. Often vigorous forced manipulation is sufficient to achieve this. The effect is to flex the metatarsal phalangeal joint and extend the PIPJ. Immobilisation can be achieved by a temporary fine longitudinal K-wire, a hypodermic needle placed longitudinally in the soft tissues, or a plaster cast for three weeks.

The patient is mobilised with heel walking for three weeks then footwear with micro cellular rubber insole should be used to distribute the weight bearing over the distal forefoot.

### Arthrotomy/Tenotomy

Some authors have recommended simple tenotomy of the flexor tendons with arthrotomy via capsular release to mobilise the PIP joints. This is recommended in flexor tightness leading to hammering of the toe. In leprosy, however, with an anaesthetic sole it can lead to cocking of the toe and increased pressure under the metatarsal head.

### Arthrodesis

Where there is longstanding deformity or subluxation, joint damage can occur. This leads to both restriction in the passive or active range of movement in the IP joints of the toe. Secondary joint capsular contracture further impedes the mobility. Where there is significant damage to the articular surfaces, an X-ray is useful, improvement following active tendon transfer is limited. Fusion of both interphalangeal joints to correct plantar flexion is useful in this situation.

### Technique

A straight or curved incision is made over the dorsum of the IP joints. The extensor tendon is split longitudinally or retracted to expose the joint capsule. The collateral ligaments are divided and the joint opened. The articular surfaces of the phalanges are removed and the surface opposed with fixation using one or two longitudinal K-wires. Cancellous bone chips can be inserted from the excised articular surfaces. The extensor tendon is repaired, the skin closed and a plaster applied for six weeks. K-wires are removed between four to six weeks.

### **Correction of Mallet Toe**

For correction of mallet toe, surgical options include:

- 1) Flexor tenotomy at the DIP joint.
- 2) Partial or total resection of the middle phalanges.
- 3) Amputation of the tip of the toe or fusion of the DIP joint.

### **Correction of Cocked toe/ retracted toe**

Where there is marked dorsiflexion of the MTP joints, fusion of the IP joints of the toe worsens the cosmetic deformity and fails to address the primary deformity. This is usually most prominent at the first MTP joint. Fritschi advocates metatarsal head resections through multiple dorsal incisions, to avoid recurrent ulceration over the plantar surface of the metatarsal heads.<sup>13</sup> MTP joint fusion corrects the cosmetic deformity but changes the biomechanics of the forefoot during the push off phase of gait. Where mobility exists at the MTP joints several options are available.

- 1) Transverse incision dorsally over the crease of the MTP joints with extensor tenotomy and split skin grafting of the skin deficit.
- 2) A dorsal longitudinal incision over the MTP joints with Z-lengthening of the extensor tendon and capsulotomy.<sup>20</sup>
- 3) A flexor to extensor transfer (Girdlestone) with division of the extensor tendon just proximal to the MTP joints.
- 4) Metatarsal head resection with extensor tenotomy or Z-lengthening.

### **SUMMARY**

Successful footdrop correction depends on the contribution of surgeon, physiotherapist and

patient. Patients' understanding and motivation is key to a successful outcome particularly after the patient has left the hospital. Regular follow up following surgery reinforces activities learnt. Maintenance of normal gait is important to long term success.

Toe deformities often are a contributing factor to (re) ulceration. Orthotic devices, in addition to surgery, can play an important role in management and prevention of (re) ulceration in the foot that is at risk because of altered biomechanics and impaired sensation.

### **REFERENCES**

1. Adkison DP, Bosse MJ, Gaccione DR, Gabriel KR: Anatomical variations in the course of the superficial peroneal nerve. *J Bone Joint Surg* 73A:112-114, 1991
2. Andersen JG. Foot drop in leprosy and its surgical correction. *Acta Orthop Scand* 33:151-160, 1963
3. Andersen JG: Foot drop in leprosy. *Lepr Rev* 1964;35:41, 1964
4. Antia NH, Enna CD, Daver BM: Deformities of the Foot. Pp 100-112. In: *The Surgical Management of Deformities in Leprosy*. Oxford University Press, New York, 1992
5. Arora A, Kumar S: Cerebral Palsy. Pp. 3498-3559. In Kulkarni GS (ed): *Indian Textbook of Orthopaedics*. Jaypee Brothers Medical Publishers, New Delhi, 1999
6. Barr JS: The management of poliomyelitis: the late stage. *First International Poliomyelitis Congress*, Lippincott JB, Philadelphia, 1949
7. Brand PW: The value of surgical and physiotherapeutic measures in leprosy. *Lepr India* 27:131, 1955
8. Brand PW: Biomechanics of tendon transfer. *Orthop Clin North Am* 5:205-230, 1974
9. Carayon A: Dual transfer of the posterior tibial and flexor digitorum longus tendons for drop-foot. *J Bone Joint Surg* 49A:144-8, 1967
10. Croft RP, Richardus JH, Nicholls PG, Smith WCS: Nerve function impairment in leprosy: design methodology, and intake status of a prospective cohort study of 2664 new leprosy cases in Bangladesh. *Lepr Rev* 70:140-159, 1999

11. Cross H, Sane S, Dey A, Kulkarni VN: The efficacy of podiatric orthoses as an adjunct to the treatment of plantar ulceration in leprosy. *Lepr Rev* 66:144-157, 1995
12. Fritschi EP: The Intrinsic Minus Foot and its Sequelae. pp 342-349. In McDowell F, Enna CD (eds): *Surgical Rehabilitation in Leprosy*. Williams and Wilkins Company, Baltimore, 1994
13. Fritschi EP: *Surgical Reconstruction and Rehabilitation in Leprosy*. The Leprosy Mission, New Delhi, 1984
14. Gunn DR, Molesworth BD: The use of tibialis posterior as dorsiflexor. *J Bone Joint Surg* 39:674-678, 1957
15. Harris JR, Brand PW: Patterns of disintegration of the tarsus in the anaesthetic foot. *J Bone Joint Surg* 48B:4-16, 1962
16. Macdonald MRC, Brandsma JW, Warren AG, et al: Complications and management of the neurologically impaired foot. *Lepr Rev* 72:263-275, 2001
17. Malaviya GN: Surgery of foot drop in leprosy by tibialis posterior transfer. *Lepr India* 53:360-368, 1981
18. Wolf EW: Surgical Patients with Special medical Considerations. Pp 357-362. In McGlamry ED (ed): *Fundamentals of Foot Surgery*. Williams and Wilkins, 1987
19. Cooper PS: Disorders and deformities of the Lesser Toes. Pp 311-358. In: Myerson MS (ed): *Foot and Ankle Disorders*. WB Saunders, London, 2000
20. Banks AS, McGlamry ED: Digital Surgery. Pp 309-326. In Neale D, Adams IM(eds): *Common Foot Disorders*, 3rd ed. Churchill Livingstone, Philadelphia, 1989
21. Oomen PK: Paralytic Deformities of the Foot in Leprosy. pp 744-758. In Kulkarni GS (ed): *Indian Textbook of Orthopaedics and Trauma*. Jaypee Brothers Medical Publishers, New Delhi, 1999
22. Richard BM: Interosseus transfer of tibialis posterior for common peroneal nerve palsy. *J Bone Joint Surg* 71B:834-837, 1989
23. Sage FP: Cerebral Palsy. Pp 2287-2382. In Crenshaw AH (ed): *Campbell's Operative Orthopaedics*, 8th ed. Mosby Co., Missouri, 1992
24. Soares D: Tibialis posterior transfer for the correction of foot drop in leprosy: long term outcome. *J Bone Joint Surg* 78B:61-62, 1996
25. Srinivasan H: Two-tailed transfer of tibialis posterior for correction of drop-foot in leprosy. *J Bone Joint Surg* 50B:623-628, 1968
26. Thangaraj RH: Reconstructive surgery in the treatment and prevention of ulcers of the foot. *Lepr Rev* 37:35-7, 1966
27. Warren AG: The correction of foot drop in leprosy. *J Bone Joint Surg* 50B:629-634, 1968
28. Wolf A J, Har-zvi RH: Modified Caldwell procedure for correction of iatrogenic equinospinus deformity. *J Foot Surg* 21: 211-6, 1982



# Management of Ulcers in Neurologically Impaired Feet in Leprosy Affected Persons

• H. SRINIVASAN

## INTRODUCTION

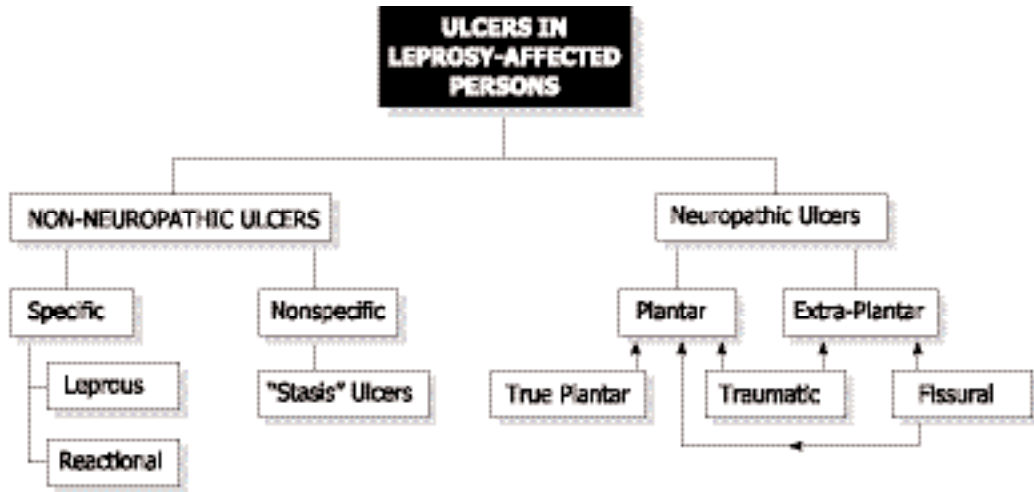
If one is asked to visualise a 'typical leprosy patient', it is almost certain that the imagined figure will be a beggar, having a deformed hand – most probably crooked and shortened fingers – and a bandaged foot. This shows the extent leprosy is identified in the mind of the public with debilitation, deformity and ulcers. Despite the fact that hardly 10% of leprosy-affected persons have ulcers at any one time, one cannot imagine a leprosy patient without them. Of the two, deformities and ulcers, the latter, especially ulcers in the feet, are of the greatest importance because impaired mobility is a very serious 'handicap' for leading a normal life in society. In addition, frequent episodes of acute infection may interfere with work and smelling ulcers make the affected person an object fit for ostracisation. Ultimately, the patient may end up as a 'scarred' individual with mutilated or amputated feet, an object of pity dependent on others both physically and economically. Ulceration of the feet is the single most common cause of morbidity and debilitation of leprosy-affected persons. In view of this, it should be evident that any worthwhile leprosy project must have a planned programme for managing, i.e., treating and preventing, ulcers in leprosy-affected persons. The fact that most leprosy projects do not have such a programme only exposes their lopsided priorities, dictated more by preoccupation with 'public health' than concern for patients' welfare.

## *Different kinds of Ulcers*

Leprosy-affected persons develop ulcers for a variety of reasons and the characteristics of the ulcers such as their location and clinical features vary accordingly. Broadly speaking, the ulcers may be classified into two groups, based on whether pre-existing nerve damage is a predisposing cause, as 'neuropathic' and 'non-neuropathic' ulcers. Unlike non-neuropathic ulcers, which may occur anywhere in the body, neuropathic ulcers occur only in sites having partial or total sensory nerve function deficit, which also come into physical contact with the external world. Neuropathic ulcers are thus mostly found on the soles of the feet. Accordingly, they can be classified as 'plantar' or 'extra-plantar' ulcers. Non-neuropathic ulcers may be "specific" or "non-specific" depending on whether ulceration was part of the disease process (Fig. 15-1). Of the different types of ulcers, neuropathic plantar ulcers are the most important clinically. They will be discussed in greater detail in this chapter.

## *Non-neuropathic Ulcers*

The non-neuropathic ulcers group, as the name implies, are not due to nerve function impairment. They may be divided into specific or non-specific depending on the aetiology. Specific ulcers occur as part of the disease process and clinical picture of leprosy. Non-specific ulcers are not related to leprosy pathology. The non-specific ulcers in leprosy-affected persons are usually stasis ulcers.



**FIGURE 15.1** Ulcers in leprosy affected persons.

### Specific Ulcers

Specific ulcers occur in the tissue background of leprosy pathology. Specific ulcers are of two types: leprosy or reactional. The former are seen in advanced cases of lepromatous leprosy while the latter are found in association with severe leprosy reaction, usually Erythema Nodosum Leprosum (ENL).

Leprosy ulcers occur because of skin breakdown over rapidly expanding lepromatous nodules. They are seen in patients with untreated, advanced, lepromatous leprosy. They are now uncommon indicating early case detection and good patient coverage under national leprosy programmes. Leprosy ulcers are found in sites of heavy infiltration and nodulation such as the face, elbows, dorsum of hands, and inside of the nose. The ulcers occur because the stretched skin over the nodule gives way exposing the leprosy granuloma underneath, which appears as pale granulation in the floor of the ulcer. The ulcer discharge is heavily laden with leprosy bacilli. These ulcers will heal rapidly once multidrug therapy is started. The ulcers need to be kept clean and covered with a bland dressing. There is no evidence to suggest that topical use of anti-leprosy drugs

like rifampicin or dapsone is necessary for healing these ulcers.

Reactional ulcers occur as part of the clinical picture of severe leprosy reaction, usually ENL but sometimes reversal reaction (RR). The ENL lesions develop into vesicles and pustules, or intense inflammation in coalesced ENL lesions or erythema multiforme-like lesions develop into large blisters that break open to expose large raw areas. In other cases of severe reaction, because of the intensity of inflammation, which in very severe cases may be compounded by arteriitis, there is tissue necrosis and breakdown, resulting in ulceration. Reactional ulcers are mainly seen on the extensor surfaces of the limbs and trunk. As they are part of the reactional process, aggressive treatment of the reaction with sufficiently high doses of steroids and adequate supportive therapy are needed for healing. Keeping the ulcer clean and covering them with a bland dressing is sufficient.

Like leprosy ulcers, reactional ulcers are usually superficial, often in the level of epidermis, with scarring only of the skin. Often the scars are hyperpigmented, occasionally vitiliginous. Ulcers on the fingers, especially over the proximal interphalangeal joints, may some-

times pose difficult therapeutic problems. In cases of severe reaction, there may be necrosis of the full thickness of the skin overlying the joint. In such cases, there is a great danger of the finger becoming stiff in a straight or flexed position. In such cases, the fingers need to be splinted in the functional position so that if they become stiff, they would still be of some use. Treatment of reactional ulcers involving the hand may pose problems to the therapist for, in order to achieve early resolution of inflammation the part needs to be rested, whereas the hand has to be kept mobile to prevent it becoming stiff. In severe cases, there is also a danger of necrosis of the tissue overlying the joint, due to associated arteriitis. That would expose the joint to secondary infection. These possibilities must be anticipated and treatment of high quality under the daily guidance of an experienced physiotherapist or technician is needed to prevent such outcomes.

### Non-specific Ulcers

The most common chronic, non-neuropathic, non-specific ulcers are those similar in appearance to stasis ulcers. These ulcers are usually seen in middle aged or elderly persons, treated earlier for long-standing lepromatous leprosy. The ulcer, often located in front of the ankle and extending up the leg, is usually quite large. It occurs on the background of pachydermatous skin that may also exhibit varicose changes. The skin of the lower leg may be atrophic, thin and shiny. The ulcer frequently extends over the region of the medial or lateral malleolus. There is usually a history of some trivial injury preceding ulceration and the ulcer progressively enlarging instead of healing until it has attained the present large size.

The floor of the ulcer is sclerotic and covered with thin, pale granulation that may be easily scraped off without causing much bleeding. There is copious serous or sero-sanguinous discharge oozing from the ulcer, which is usu-

ally not positive for acid-fast bacilli. The bed of the ulcer is densely scarred and feels hard. A vitiliginous area indicating the past extent of ulceration often surrounds the ulcerated area. In their location, appearance and clinical behaviour these ulcers resemble the stasis ulcers seen in persons with incompetent venous valves or blocked lymphatics due to frequent attacks of lymphangitis and consequent blood or lymphatic stasis. No information is available in the published literature to show whether vascular or lymph stasis is actually present in these cases and, if so, their aetiology.

These ulcers are very refractory to treatment, healing is very tardy, tentative and often temporary. Skin grafts, even split-thickness grafts, often fail to take. Clinical experience suggests that keeping the ulcer clinically and bacteriologically clean and using occlusive, compression dressing coupled with exercises to improve drainage of blood and tissue fluid from the lower limb might assist healing. However, none of these treatments have been well studied.

### NEUROPATHIC ULCERS

Neuropathic ulcers occur in a part of the body as sequelae of a pre-existing sensory deficit. These ulcers are found in those denervated parts of the body which come into contact with the external world. That happens because denervation has made the part vulnerable to the events and stresses that occur at that interface, initially at the time of their occurrence or subsequently. The foot is constantly in contact with the ground carrying the weight of the body in the course of its activities like walking and running. The soles of the feet are, therefore, the most frequent sites to develop neuropathic ulcers and these ulcers are known as '(neuropathic) plantar ulcers'. These ulcers cause maximum discomfort to the patients and in view of their importance they are discussed in some

detail below. Ulcers occurring in other denervated sites, such as the dorsum and lateral malleolar region of the foot and the hands are described under '(neuropathic) extra-plantar ulcers'. Neuropathic plantar ulcers are usually referred to simply as 'plantar ulcers'. They are also commonly known as 'trophic ulcers' and less commonly as 'perforating ulcers', 'penetrating ulcers', or 'mal perforans'.

### ***Concepts of Causation of Plantar Ulcers: A Historical Review***

It is worth recapitulating briefly the evolution of our concepts of the causation of plantar ulcers since all of them still persist to a varying extent, among the affected persons and health workers alike, thereby impacting treatment and outcome, sometimes adversely.

#### **Leprosy is the cause**

Till about the last decade of the 19th century it was the general belief that leprosy "devitalized" tissues, depriving them of their ability to survive and withstand stresses. It was believed that tissues rotted and dropped off (e.g., shortening of fingers and toes). The additional stress of carrying the body weight and the resulting pressure caused the "devitalized" bones and other tissues of the foot to undergo necrosis. Ulceration was seen as the means by which the body attempted to get rid of the dead tissue. Finding pieces of dead bone in the depths of these ulcers coupled with the observation that removal of those pieces and resting the foot usually healed the ulcer were considered as providing proof of this view.<sup>17</sup> Thus, leprosy was considered to be directly responsible for these ulcers. For that reason, these ulcers were considered highly infectious and thought to be a serious way the disease spread in the community. Many lay people and even some leprosy workers still subscribe to this view. Hence, the advocacy and use of topical anti-leprosy drugs, ranging from hydnocarpus oil to

rifampicin, by some people even today for healing these ulcers.

#### **Neuropathy is the cause**

By the last few decades of the 19th century it had been established that the nervous system controlled the functioning of most if not all of the organs of the body. It was then postulated that there ought to be 'trophic' nerves that regulated cell metabolism in order to maintain the integrity of cells and tissues against 'wear and tear'. In patients with leprosy and other neuropathies it was presumed that the 'trophic nerves' would also be damaged in due course, and that this would cause 'devitalization' of cells, tissues and organs. Thus denervation and particularly damage to the hypothetical "trophic nerves" was presumed to be the primary cause of 'devitalization' of tissues which then broke down under conditions of normal use or abnormal stress. These ulcers were therefore called 'trophic ulcers', a term that is still in use widely.

#### **Trauma is the cause**

According to this line of thinking unperceived injuries to the foot and neglect of those injuries were considered to lead to the formation and maintenance of ulcers. Both lack of perception of the injury initially and neglect of the injured part subsequently were explained as being due to insensitivity and consequent lack of feeling of pain, because of damage to the peripheral nerves. The fact that these ulcers always occurred in feet with loss of protective sensation, and the not infrequent finding in their depths of foreign bodies like stones, were taken as proof for this view. This situation continued till the middle of the 20th century.

#### **Ischemia is the cause**

Around 1950, Paul Brand and a band of young orthopaedic surgeons under his leadership

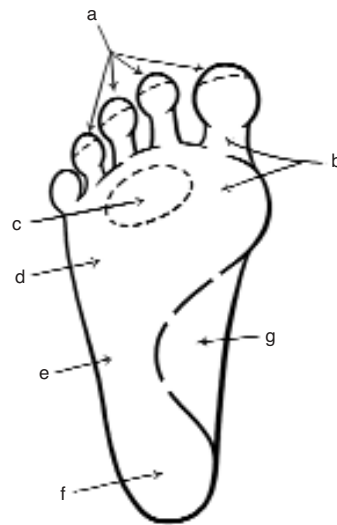
started taking interest in the problems of leprosy-affected persons. They were struck by the fact that there was great damage to deeper tissues and that the ulcers occurred almost exclusively in the weight-bearing areas. This suggested that these ulcers might be pressure sores, somewhat like bedsores. Simple measurements, of the area of weight-bearing surface and the load on that area, assuming that 50% of the weight was borne by the heel and the other 50% by the ball of the foot, showed very clearly that pressures in the sole during standing would far exceed the blood pressure, blocking entry of blood to the compressed part of the sole. It was evident that continued standing without relieving the sole of the foot, by frequent shifting of weight from one foot to the other, would cause severe ischemia. That would be sufficient to lead to ischemic necrosis of the subcutaneous tissue and then of the overlying skin causing ulceration. Persons with insensitive feet would not feel the ischemic pain and so (it was postulated) would not shift the weight from their feet periodically as healthy individuals do, thus allowing development of ulcers. On this basis patients were instructed not to stand for 'prolonged periods'.<sup>13</sup>

While the logic of this hypothesis was sound, the basic premise that one could stand for "prolonged" periods (for four to five hours or longer! - which is what "prolonged" means in the present context) without swaying, continuously loading the sole, was not realistic for two reasons. Firstly, people rarely, if ever, stand like that.<sup>7</sup> Secondly, the body cannot stand still even for a few seconds, as the living body is constantly swaying, mostly forwards and backwards, as the muscles are constantly pulling the body in one direction or the other to prevent it from falling. Thus, standing is an act of dynamic equilibrium and one cannot stand 'absolutely still' even for a minute, let alone for the hours required to produce ischemic necrosis and ulceration of the sole.

### Walking is the cause

Price, a surgeon working in Nigeria, published in 1959 three papers on plantar ulcers in leprosy which gave us a new insight into the causation of ulcers.<sup>33-35</sup> It was Price who introduced the term 'plantar ulcer', instead of the then popular 'trophic ulcer'. Price made three important observations:

a) The ulcers were not randomly distributed in the weight-bearing area of the sole; instead, there was a bias for the ulcers to be located under the metatarsal heads. About 70% of the ulcers occurred in this part of the sole, with 10% occurring in the heel, and a further 10% in the midlateral part of the sole. The risk of ulceration of the forepart of the sole of the foot was therefore about seven times greater than that of the heel. This pattern of preferential ulceration of the ball of the foot was confirmed soon after in South India, at Karigiri and Chingleput (Fig. 15-2).<sup>41,44</sup>



**FIGURE 15-2** Frequency of distribution of ulcers in sole of the foot a) tips of toes <5%; b) big toe region 30-50%; c) central toe region; 2nd-5th metatarsal heads 20-30%; d) Metatarsal head region 15-20%; e) mid lateral border of the foot (base of 5th metatarsal) 15-20%; f) heel 5-10%; g) instep <1%.



b) The ulcers started as blisters over areas of necrosis. There was an initial area of deep inflammation followed by necrosis of the subcutaneous tissue, which was followed by the development of the 'necrosis blister'. While the blister usually lay over the area of necrosis, the blister fluid sometimes tracked along paths of 'least resistance' and surfaced at a distance.

c) The ulcers developed in one of three ways:

1. through infection of a (usually penetrating) wound giving rise to a traumatic ulcer;
2. through infection of a deep skin crack, frequently found in the anhidrotic soles of these patients, or, infection of a 'bursa' deep to a callosity/corn through a fine crack giving rise to a fissural ulcer or,
3. more commonly, because of the stresses and strains on the tissues of the sole during walking giving rise to a 'true' plantar ulcer. Price pointed out that the stresses and strains of walking lead to ulceration and that this explains the special vulnerability of the ball of the foot for ulceration. According to Price, only the last type of ulcers would qualify to be called 'plantar ulcers'. However, it is common experience that these ulcers, once they have developed, behave the same way and have to be managed the same way irrespective of their initial cause, be it trauma, fissure or walking. Probably for this reason and also because patients are rarely seen at the initial stage, no distinction is now made between 'true' and other types of plantar ulcers and all are referred to simply as 'plantar ulcers'.

Price did not, however, explain why walking strains should cause ulceration in insensitive feet only. Brand has advocated the idea that leprosy patients with insensitive feet walked 'excessively'. He has shown experimentally that even a small rise in stress when

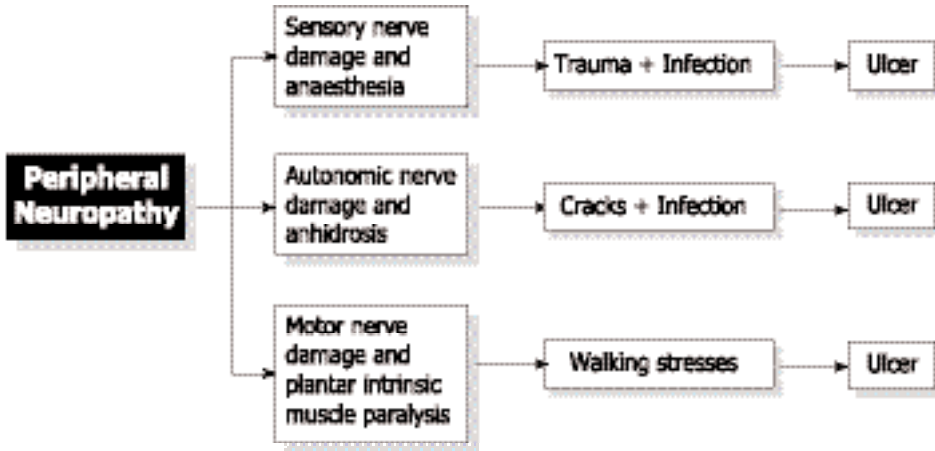
repeated innumerable times causes aseptic inflammation at that site and that the inflamed sites then break down easily.<sup>6</sup> Patients were, therefore, advised not to walk 'too much' and to rest their feet at periodic intervals if they had to walk 'long distances'. Srinivasan found that a history of prolonged walking preceded the initial development of ulcers in only a few cases. His study showed that insensitivity of the sole introduced a risk of ulceration (ca. 6% in his patients) and that the risk increased (12-72%) when there was associated paralysis of the plantar intrinsic muscles.<sup>45</sup> This study further showed that paralysis of muscles or muscle groups rendered particular sites more vulnerable.

That observation would further support the thesis that paralysis of the plantar intrinsic muscles increases the risk of ulceration in the ball of the foot.

### ***Current View of Causation of Plantar Ulcers (Fig. 15-3)***

The currently held view is as follows. A minority of ulcers (ca. 10%) arise from perceived or unperceived injuries with neglect of these injuries resulting in infection and tissue damage. Another small proportion (ca. 5 %) arise from neglect of deep cracks in the dry (anhidrotic) and hyperkeratotic skin of the sole, or, from infection of 'bursae' underlying callosities or corns, through fine cracks. The majority of plantar ulcers arise from breakdown of plantar subcutaneous tissue due to the stresses and strains of normal walking.

All plantar intrinsic muscles exert their effect in the region of the metatarso-phalangeal joints. When these muscles are paralysed, the compression and shearing forces are increased, even during normal walking. The plantar intrinsic muscles are maximally active during the "push off" stage of walking when the fore part of the foot pushes the ground backward in



**FIGURE 15-3** Current concept of plantar ulceration.

order to propel the body forward.<sup>1</sup> Their contraction creates a thrust that will counter the compressive, shearing and distracting forces at the metatarso-phalangeal joint region that are normally generated at this stage of walking. When the plantar intrinsic muscles are paralysed, this protective effect is lost, and the toes get clawed during the “push off ” stage of walking, causing momentary increases in stresses and strains in the region of the metatarso-phalangeal joint at each step. Brand has shown that even small increases in stresses

can lead to breakdown of tissue if repeated long enough, causing ulceration.<sup>6</sup> Similarly, paralysis of long muscles also increases the risk of ulceration at specific sites due to momentary increases in stresses at those sites as shown below (Fig. 15-4).

**Other causes of plantar ulceration**

While most plantar ulcers arise in the manner described above, other (known or not yet known) causes may be operating occasionally

<b>Muscle Group Paralysed</b>	<b>Site Made Vulnerable</b>
Plantar intrinsics	Ball of the foot
Abd. hallucis group	I Metatarsal head region
Interossei-lumbricals	II, III, & IV Metatarsal head region
Abd. dig. minimi group	V Metatarsal head region
Fl. dig.brevis / interossei & lumbricals	Tips of toes
Foot dorsiflexors	Heel
Peronei (evertors)	Head / Base of V metatarsal
Calf muscles (plantar flexors)	Heel

**FIGURE 15-4** Sites rendered vulnerable to ulceration by particular muscle paralysis.\*

\* The reader is advised to also study chapter 12 for additional insights into the pathogenesis of plantar ulceration (eds.).

to give rise to an ulcer. Thus obvious or occult anatomical anomalies and variations, improper or ill-fitting footwear, vascular insufficiency or rare fungal or bacterial infections may lead to ulceration of different parts of the foot. These factors, however, usually determine the site of an ulcer rather than initiate one.

### STAGES OF ULCERATION

The pathogenesis of plantar ulcers may be described in terms of three 'stages' namely the stage of 'threatened' ulcer, the stage of 'concealed' ulcer and the final stage of 'overt' or open ulcer.

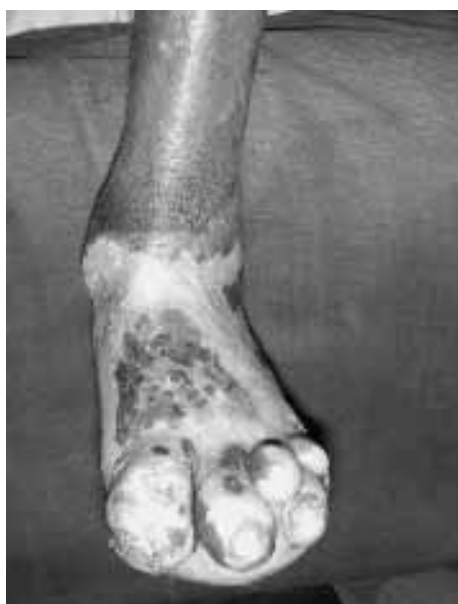#### Stage of threatened ulcer

In terms of pathology, this stage may be called "pre-ulcerative stage of aseptic inflammation". Increased stress repeated over a period of time gives rise to a focus of traumatic (aseptic) inflammation in the region of the subcutaneous layer of the sole of the foot, which is most vulnerable to mechanical stress. This occurs at the site of increased stress, usually under a joint or a bony prominence, very often just distal to the head of a metatarsal. The affected site is oedematous. This is seen as mild or obvious splaying of a toe, which stands apart from its neighbour to a greater or lesser extent.<sup>33-35</sup> The affected site is often tender to deep digital pressure. Clinicians do not often get to see feet in this stage since patients rarely report at this stage.

#### Stage of concealed ulceration

This is the stage of "necrosis blister". The inflamed site undergoes necrosis on continued subjection to stress, by walking, with the subcutaneous tissue undergoing colliquative necrosis. The liquefied tissue mixed with some blood is forced to the surface by continued walking to present as a blister. This is the so-called 'necrosis blister'. This blister usually directly overlies the area of necrosis, but some-

times, when the overlying tissue is too tough, it may track along a path of least resistance and emerge to the surface at a distance, at the side of the toe or in the interdigital web.<sup>33-35</sup> This stage also often goes unnoticed. Even when noticed, patients may mislead the physician by attributing the blister to (an unperceived) burn as, in their experience, burns cause blisters (Fig. 15-5). Only close questioning will reveal that 'the burn' was an assumption or an inference and not a fact or direct observation.



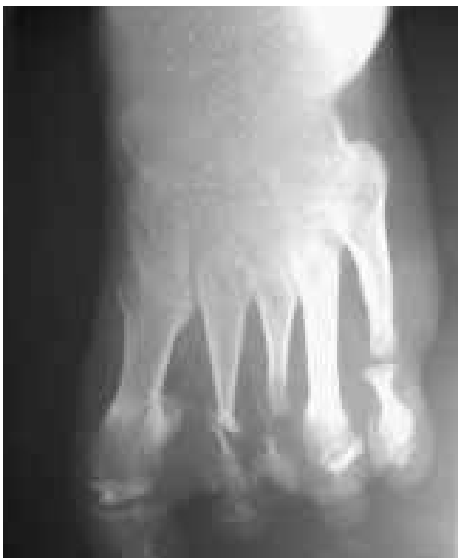**FIGURE 15-5** Burn in a newly diagnosed leprosy patient; patient presented with the burn.

#### Stage of overt ulceration

With the formation of the necrosis blister the essential process of ulcer formation namely, destruction of the subcutaneous tissue, is complete except that the "ulcer" is not seen or obvious as it is still covered with skin. When the skin overlying the blister breaks open, the ulcer site becomes exteriorised, the necrotic area becomes exposed to the external world and there is an obvious ulcer.

## PROGRESSION OF PLANTAR ULCER

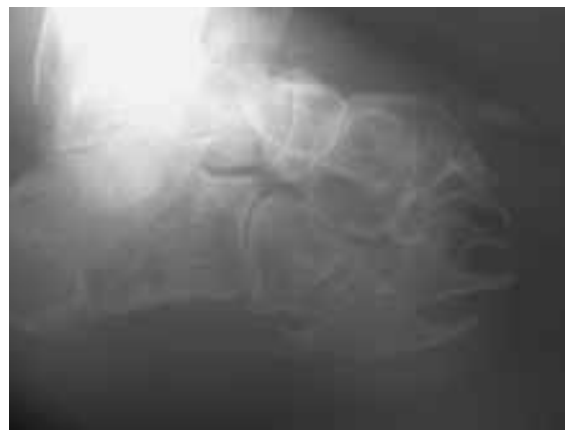An ulcer does not usually bother the patient except for its nuisance, as there is usually no accompanying pain. It may enlarge to some extent and continue like that, without healing, for some weeks or a few months. Sooner or later it can become acutely infected with 'street organisms' like *Staph. aureus*, *E. coli*, or *B. proteus*.<sup>9,11,14,31</sup> The part becomes swollen, the oedema showing up prominently over the dorsum even when the infected site is in the sole, and the edges of the ulcer are also swollen. There is copious discharge of pus or sero-sanious fluid, which may be foul smelling. The floor of the ulcer is often covered with necrotic tissue. There may be associated groin adenitis, lymphangitis and fever, depending on the severity and extent of localization of infection. Examination of the blood shows polymorphonuclear leukocytosis. The ulcer presenting in this fashion, with acute inflammation, is often referred to as an 'acute ulcer'. Initially, the infection and inflammation are confined to the subcutaneous tissue and plane, without it extending to deeper tissue or structures like bones, joints or tendon sheaths. In that case



**FIGURE 15-6** Early digit/metatarsal bone loss secondary to ulceration.

they are also called 'simple ulcers' or 'uncomplicated ulcers'. Usually, the patient seeks relief at the stage of acute inflammation and with treatment the inflammation subsides, and the ulcer may also heal. Or, after improving for some time, the ulcer may remain unchanged and continues to be present as a small raw area. The acute ulcer has become quiescent and has entered the chronic stage. From now on it is referred to as a 'chronic ulcer'.

The chronic ulcer, as the name suggests, remains unchanged and unhealed for some time and then may flare up again as an acute ulcer. With treatment the acute inflammation subsides and the ulcer reverts to the chronic status once more. Over the course of years, this cycle (chronic ulcer → acute ulcer → chronic ulcer) may be repeated (Figs. 15-6,7). During any one of the acute episodes the infection may break through the natural barriers and extend to one or more deeper structures such as an underlying joint or bone or an adjacent tendon sheath or, a 'plantar space'. Ulcers in the midlateral border of the foot are dangerously close to cubo-metatarsal and calcaneo-cuboid joints to which infection may easily spread and from there to the other tarsal joints. Such extension of infection to deeper structures converts the 'simple ulcer' into a 'complicated ulcer'. In this



**FIGURE 15-7** Advanced bone loss secondary to ulceration.

manner, the plantar ulcer may result in additional complications like osteomyelitis, septic arthritis or tenosynovitis. These complications may result in fixed deformities of toes or foot, loss of bone and flail or disorganised joints. It is not anymore a plantar ulcer, but a sinus with deep ramifications associated with profound structural changes in the foot, with corresponding functional consequences. The term 'penetrating ulcer' is sometimes used to refer to an ulcer that extends deeply into a tarsal bone, like the calcaneus. Sometimes, the sinus finds its way through the full thickness of the foot and opens out in the dorsum of the foot. Such an ulcer, which perforates the foot through and through, is called a '*perforating ulcer*' or *mal perforans*. Severe and repeated infection causes extensive tissue necrosis with replacement of the dead tissue with scar tissue. Scar tissue cannot withstand the stresses and strains generated in the foot during walking and, sooner or later it may break down and the ulcer that healed with great difficulty breaks open readily. These ulcers, which recur readily, with little provocation and despite taking proper care and adequate protective precautions including the use of appropriate footwear, are referred to as 'recurrent ulcers' in which the recurrence of the ulcer itself is the main complication.

### CONSEQUENCES OF REPEATED ULCERATION

Each episode of recurrent ulceration is associated with additional tissue damage and further scarring at the site making the part more vulnerable to ulceration. Further, soft tissue loss, scar contraction, pathological fractures and bone loss associated with chronic osteomyelitis, and destruction of an underlying joint often cause development of fixed deformities, abnormal bony prominences and functional abnormalities. During walking and even during standing, these abnormalities can cause

increased pressures and other stresses and strains on the already vulnerable scar leading to the breakdown of the scar even more readily. A vicious spiral is set up in this manner leading to progressive and extensive destruction and mutilation of the foot. The plantar ulcer may rarely develop some other complications such as life-threatening clostridial infections (tetanus, gas gangrene), or, septicæmia. Occasionally, long standing ulcers may undergo malignant or premalignant degeneration developing into a 'cauliflower growth' that may be squamous-cell carcinoma or identical-looking pseudo-epitheliomatous hyperplasia.<sup>49</sup> The natural history of plantar ulcers is shown in Fig. 15-8.

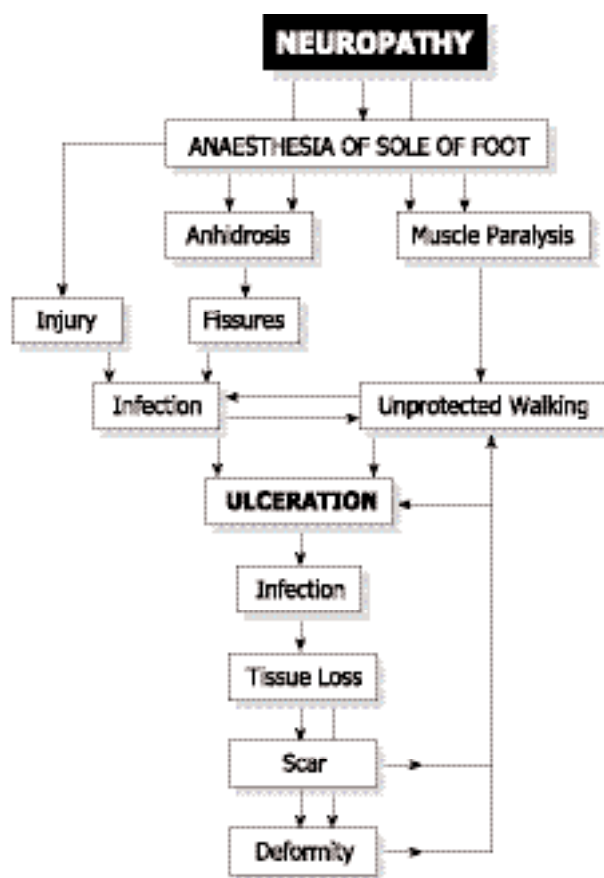
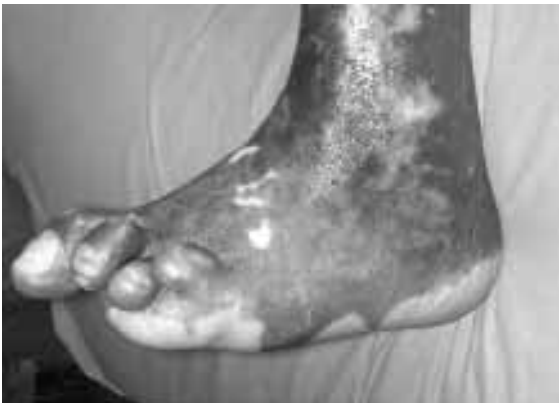

FIGURE 15-8 Natural history of plantar ulceration.



## LOCATION OF PLANTAR ULCERS

As pointed out by Price, plantar ulcers are not distributed randomly in the sole of the foot, but are found more often at some sites than others. Thus, the forefoot is the most favoured site, accounting for 70% to 80% of the ulcers. Srinivasan showed that even in the ball of the foot, the frequency of ulceration progressively increased from the lateral to the medial part, the first metatarsal head region being the most common site (Figs. 15-2 and 9).<sup>46</sup> Ulcers are least common in the region of the medial arch (instep) of the foot. The frequency of ulceration increases progressively in the following order: tips of one or more toes, pulps of one or more toes, heel, mid lateral border of the foot (base of 5th metatarsal), region of the 5th metatarsophalangeal (MTP) joint, region of central three MTP joints and the region of the MTP joint of the big toe being the most common sites. Although the last three sites are commonly referred to as being 'under a metatarsal head' (MTH region), the ulcer is usually located just distal to and not right under the metatarsal head. The toes are webbed to a much greater extent than the fingers and the metatarsal heads are not located as far forward in the ball of the foot as commonly imagined. The exact location of an ulcer is determined by a number of factors. A traumatic ulcer may occur any-



**FIGURE 15-9** Forefoot deformity secondary to plantar ulceration.

where in the sole of the foot, since a thorn, nail, or a sharp stone will penetrate any part of the foot with which it comes into contact. Fissures, and fissural ulcers, on the other hand, occur around the margin of weight-bearing areas in the sole.

## NEUROPATHIC EXTRA-PLANTAR ULCERS

### Extra-Plantar Foot Ulcers

Neuropathic ulcers may also be found in sites other than the sole of the foot. These are known as extra-plantar ulcers. Thus in the foot, extra-plantar neuropathic ulcers are seen on the dorsum or over the lateral malleolus. The ulcers over the dorsum of the toes are due to rubbing of the toe (usually the second toe) by an ill-fitting strap of the sandal or the upper of the shoe. In these cases, the toe is usually deformed, having a fixed or mobile claw deformity. Sometimes, a flail little toe develops ulceration over its dorsum, again due to frictional trauma from the shoe or sandal.

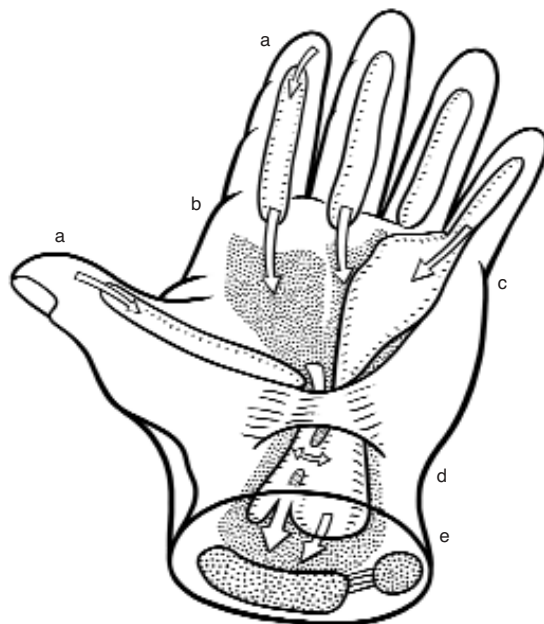
Ulcers over the lateral malleolus arise from pressure and friction due to cross-legged sitting. The tissues over the lateral malleolus get caught between the ground and the underlying bone. Repeated and continuous compression causes the skin over the lateral malleolus to be thickened and hyperkeratotic and a corn develops in that area. The corn increases the compression and shear stresses, causing an adventitious bursa to develop between the corn and the underlying lateral malleolus. The bursa becomes chronically inflamed with thickening of its walls, because of repeated trauma from sitting. At some stage, fine cracks develop in the skin overlying the bursa. The bursa may get infected, a collar stud abscess develops, bursts open discharging pus leaving behind a chronic sinus communicating with the infected bursa underneath. The skin overlying the infected bursa may slough off and a large indolent ulcer

extending over the entire lateral malleolar area develops. If not treated properly and promptly the bone may also become involved. With continued neglect, the infection may spread further to involve the ankle joint with disastrous consequences. Instances are not unknown in which the entire talus had been extruded as a sequestrum in cases of sepsis of the ankle.

### **Extra-Plantar Hand Ulcers**

Neuropathic ulcers occur also in the hand. In fact, hand ulcers are at least as common as plantar ulcers but they usually heal quicker as, unlike the feet, wound healing in the hands is not complicated by having to bear the weight of the body. Ulcers in the hand are mostly 'traumatic' in origin and are caused by burns (cooking, cigarettes), cuts and abrasions. The digital pads, palmar and dorsal aspects of fingers and hypothenar eminence are most often affected. Sometimes, vermin like rats chew up the insensitive fingers or toes of the patient during sleep. To prevent this happening Brand advised patients to keep a dog or a cat as pet to keep the area vermin free. Because they are not painful the wounds are neglected and not allowed to heal by treating them properly, rest. As a result, they continue to remain as festering sores. Often, digital pad infection is allowed to extend deeper and progresses into osteomyelitis of the terminal phalanx, and loss of its distal parts through sequestration. Fingers in leprosy-affected persons get shortened progressively in this manner, sometimes to mere stubs. The infection may also spread proximally, to the flexor synovial sheath and through that involve the spaces of the palm, or, even Parona's space in distal 1/4th of the front of forearm (Fig. 15-10).

Infection of the synovial sheath may also lead to necrosis and loss of flexor tendons of the finger, leaving behind a stiff and straight finger, reducing hand function. Besides the traumatic ulcers, fissural ulcers are also not



**FIGURE 15-10** Spread of infection in the hand: a) from pulp of finger to flexor synovial sheath. b) from flexor sheath to palmar spaces. c) flexor sheath to ulnar bursa. d) from radial bursa to ulnar bursa and vice versa. e) from palmar space (white arrows) and flexor sheath (black arrows) to Parona's space.

uncommon in the hand. Persons doing hard manual labour develop areas of hyperkeratosis in the region of digital creases and the thickened dry skin will crack when the finger is passively straightened during the course of work. In this manner a fissure develops, usually at the site of the middle digital crease or at the proximal digital crease located at the base of the finger. These fissures are initially shallow but in course of time may become quite deep to expose the subcutaneous tissue and even the flexor tendon or its sheath. The fissure is surrounded by grossly hyperkeratotic skin and frequent movement keeps the fissure open and prevents its healing. Secondary infection may enter through the fissure to involve underlying structures with consequences similar to those mentioned earlier.

Pressure and friction sores are also seen in the hand. Friction sores may occur over the dorsum of a finger at the PIP joint level due to rubbing away of the skin and deeper tissues during activities like soaping a garment over a stone. Pressure or friction sores in the hands are seen in persons who habitually use their hands to push the ground down (for getting up), or, downwards and backwards (in order to move forwards). Tips of claw fingers become sclerotic and the sclerotic tissue gets worn out in course of time due to the use of great force used during gripping objects, presenting a small circular sore. Pressure sores in the hand typically occur over the 'heel' (proximal medial (ulnar) corner, i.e., base of hypothenar eminence) of the palm, over the pisiform bone. Infection may spread from an ulcer at this site to the bone underneath and, with continued neglect, spread to the other carpal bones and intercarpal joints, which may result in carpal disorganisation.

## MANAGEMENT OF NEUROPATHIC ULCERS

It would be evident from the foregoing discussion that we should aim at achieving three goals: 1. healing of ulcer(s) already present, 2. prevention of recurrence of ulcers that have healed and, 3. prevention of ulceration in individuals with sensory neuropathy, if they are at risk of developing neuropathic plantar or extra-plantar ulcers.

When there is a plantar ulcer, our primary aim is to get the ulcer healed. As the first step, the feet should be carefully examined. Ask the patient whether there is impairment or loss of sensibility in feet and hands, including the affected foot. Although patients' statements in this regard are fairly reliable, it is better to assess sensation.<sup>28</sup> People are often not aware of sensory impairment of insidious onset.

*Examining the foot with plantar ulcer.* Ask for a history of impaired sensibility in the affected foot as well as the other foot and hands, its extent and duration. Use a few explanatory queries such as "Does the ground feel normal while walking? Do you feel the small stones or the hot ground under your feet during walking? Does it hurt when you step on a pebble?" This will confirm that you and the patient have understood each other correctly. Next, even in cases of recurrent ulceration, ask for the details of how the ulcer started originally and what happened subsequently. In the patient's replies, try to identify actual observations from inferences: the patient may say that he had a 'burn' whereas he is not aware of any episode of the burn and had actually noticed only a blister; the patient may say he had an abscess, but only blood stained thin fluid, not pus, drained from the 'abscess'. When asking a leading question such as "Did you have a wound? Did you walk a long distance?" always explain what you mean by the terms used in your question. The terms 'wound' and 'long distance' may not mean the same to the patient as it does to you. The primary aim of examination is to assess the state of the ulcer, whether it is an acute, simple chronic, complicated chronic or a 'recurrent ulcer', in order to determine the line of treatment.

Take time to examine the affected foot with care. In addition, always examine the other foot, and in leprosy affected persons, both hands and both eyes. Look at the affected foot carefully for signs of infection, inflammation, swelling and deformity. Feel the skin for areas of increased temperature ('hot spots'); palpate the bones for thickening and tenderness; move the joints looking for instability and stiffness, and examine the posterior tibial neurovascular bundle, behind the ankle, for tenderness. Pain and tenderness at this site in a patient with a plantar ulcer, but no active leprosy, often indicates chronic inflammation of lymphatics run-

ning along with the posterior tibial vessels and nerve rather than posterior tibial neuritis due to leprosy. Elicit the story of each and every scar. Finally, do not fail to examine the draining regional lymph nodes.

When you notice a deformity in the foot or toes, ascertain whether that was a consequence of previous episodes of ulceration. Find out whether the patient wears any footwear, its type and when she/he uses them. Many patients in rural areas use footwear only on some specific social occasions, like coming to a hospital. Have a good look at the footwear, check its pattern of wear and verify its fit and whether the footwear itself could have caused any damage to the foot.

Carefully examine the ulcer. Note the characteristics like its edges (e.g., scarred / hyperkeratotic / heaped up / rolled out / sloping and healing etc.), the floor (for the presence of slough, nature of the granulation - whether it appears normal, hypertrophic, very pale etc.), openings of sinuses and extent of fibrosis

around the ulcer. Note the nature of the discharge from the ulcer, whether it is copious or scanty, thick or thin, purulent or serous etc. Ask, and look for the presence of fine grains of bone ('bone sand') in the discharge. If sinuses are identified, probe them to identify their track and the presence of any sequestrars in their depths. Finally, note whether the regional lymph nodes are enlarged and tender. The aim and details of management depend upon the type and the condition of the ulcer as identified by clinical examination. Figure 15-11 summarises the aims of management and the principles of treatment of the different types of plantar ulcers.

### **Management of acute ulcer**

The goal of management at this stage is to control the effects of and limit the damage caused by acute infection and inflammation and convert the acute ulcer into a healing ulcer. The acutely inflamed ulcer with oedematous edges and dirty slough-covered floor copiously dis-

Type of Ulcer	Aims and Principles of Treatment
<b>1. Acute Ulcer</b>	Control acute inflammation and convert acute ulcer into a "healing" ulcer and treat it as such, using elevation, cleansing, dressing and, if necessary, antibiotics.
<b>2. Chronic Simple, or, Healing Ulcer</b>	Allow the ulcer to heal, by providing appropriate dressing, and protecting from physical or chemical injury.
<b>3. Chronic Complicated Ulcer</b>	Eliminate complication and convert complicated into a "healing" ulcer and treat it as such.
<b>4. "Recurrent" Ulcer</b>	Identify the cause of recurrence of each ulcer and work out methods to eliminate it. Usually involves scar revision and / or abatement of load on the scar tissue plus special protective footwear.

**FIGURE 15-11** Aims and principles of treatment of different types of plantar ulcers.

charging smelling pus is changed to a clean ulcer having thin sloping margins, and its floor covered with healthy granulation, scantily discharging somewhat gummy serous fluid indicating that the ulcer has entered the healing phase. This aim is achieved by: (1) elevating the part, (2) cleansing the ulcer, (3) establishing proper drainage, and, where necessary, (4) using suitable antibiotics. In order to apply the above, the patient with an acutely infected and inflamed (plantar or extra-plantar) ulcer should be admitted as an in-patient in a medical facility, put to bed and prohibited from walking. Minimal necessary investigations would include estimation of hæmoglobin getting a radiograph of the affected part for assessing the possible presence and extent of bone involvement. Other investigations, like estimation of blood sugar, blood culture and culture from the ulcer for identifying the pathogen are done when indicated.

### **Elevating the part**

An essential first step in the management of acute ulcers is elevation of the affected part. Elevation improves venous and lymphatic drainage and reduces œdema. Hanging the limb down adds to tissue tension (and pain) by gravitational effect. Persistent inflammatory œdema leads to fibrosis and contractures of the joints of hand or foot.

### **Cleansing the ulcer**

Cleansing procedures aim at physically eliminating all necrotic tissue and particulate matter, foreign bodies like grit and other detritus as well as floating debris of dead tissue from the ulcer. Soaking the foot daily for about twenty minutes and then irrigating the ulcer with warm normal saline or a mild antiseptic solution will achieve this aim in a few days. Soaking and irrigation are done as often as necessary, twice or thrice a day if need be, depend-

ing on the amount of discharge from the ulcer. Whirlpool baths providing vigorous agitation are very effective in mechanically cleansing acute ulcers. In between sessions of soaking-irrigation, the ulcer is covered with moist dressings, pieces of gauze soaked in a mild antiseptic solution. Deep ulcers, and those communicating with cavities, are loosely packed with a ribbon of gauze soaked in the cleansing agent. "Eusol" (Edinburgh University Solution) containing 1.25 parts each of chlorinated lime (calcium hypochlorite or bleaching powder) and boric acid for 100 parts (w/v) of clean, not necessarily sterile, water is very useful for cleansing purposes, for soaking, irrigation as well as dressing.<sup>4</sup> Eusol is an effective antiseptic and deodorant and is also much less expensive to make than the other antiseptic agents sold in the market. Eusol has a necrolytic action and the liberated nascent chlorine functions as a mild antiseptic even in the presence of necrotic organic matter.<sup>63</sup> Compared with the other buffered hypochlorite solutions like Dakin's and Milton's solutions, Eusol has a lower pH (7.5 to 8.5 cf 9.5 and 10.5 to 11.2) and is therefore less irritating to tissues, although it is not as tissue-friendly as the more modern but much more expensive preparations like hydro-gels and hydro-colloids.<sup>10,20</sup> Eusol should be freshly made, preferably daily; in any case at intervals of not more than once a week. Non-buffered hypochlorite solutions (e.g., chlorosol) are far more stable than the buffered ones and provide greater available chlorine (about 0.4% cf about 0.25%) but are highly irritating to the tissues as they have very high pH (about 11.5) and so are not used.

Other agents commonly used in moist dressing of plantar ulcers are: concentrated magnesium sulphate, glycerine-magsulphate paste, acriflavine, mercurochrome and hydrogen peroxide. The first two are absorptive dressings as the chemicals used are hypertonic / hygroscopic. They absorb water from the




wound and thus maintain a moist environment congenial for autolytic debridement and wound healing. Hypertonic saline dressings would be equally effective. Acriflavine and Mercurochrome are used mainly for their antiseptic properties, but, except for being colourful and so impressive to the patient and others, they are virtually useless for that purpose as organic matter such as necrotic tissue inactivates them. The nascent oxygen liberated by hydrogen peroxide has an antiseptic effect but one should avoid using hydrogen peroxide for irrigating closed cavities for fear of complications like life-threatening oxygen embolism.<sup>2,43</sup> Cetrimide BP and chlorhexidine (Savlon™ is a combination of both) are efficient cleansing and antiseptic agents, effective in even low concentrations, and so quite useful as cleansing agents. But, in view of their deleterious effect *in vitro* on fibroblasts, they are better avoided for repeated use in clean ulcers as they may interfere with fibroblast activity essential for wound contraction and healing.

A variety of other cleansing agents and dressing materials such as polyvinyl film (permeable to O<sub>2</sub> and moisture but not to bacteria), hydro-colloids and hydro-gels, honey, sugar paste, Debrisan™ (a proprietary preparation of micro fine plastic granules that keeps the wound moist by capillary action), collagen sheets and a host of others have been tried in recent times in plantar ulcers of leprosy patients, persons with bed sores, burn wounds and foot ulcers in diabetic subjects.<sup>15,29,39,64</sup> All of them have been found to be 'effective' in obtaining 'early' wound healing. Even if the claims are valid, it is difficult to say at present how important a place they have in the routine management of ulcers in leprosy, especially in the field. It is also worth noting that a meta-analysis of 47 reports of 35 randomised controlled trials comparing the usefulness of a variety of cleansing agents in chronic wounds concluded "there was insufficient evidence to

promote one ... agent over another".<sup>5</sup> We must also remember that, in many cases, plantar ulcers in leprosy-affected persons remain unhealed not because some particular dressing agent has not been applied but because they have been neglected and not rested.<sup>56</sup>

### Establishing drainage

An important factor in the persistence of infection is damming up of pus in deeper tissues and spaces. Prompt draining away of the infected exudates without allowing them to accumulate is necessary for rapid elimination of infection. Ensuring proper drainage is achieved by surgery. However, extensive surgery involving wide opening up of tissue planes and spaces is contraindicated during the acute stage of the ulcer. Surgery is therefore confined to minimal necessary drainage procedures like incision and release of pent up pockets of pus, making counter incisions in non weight bearing areas for better drainage of deep cavities, removal of loosely lying slough and pieces of dead bone too large to be flushed out by irrigation and loosely packing the wound with gauze ribbon soaked in Eusol. In forefoot ulcers, with acute osteomyelitis of a metatarsal, a 5-cm long dorsal longitudinal counter incision over the maximally affected point to drain the infected site is a useful procedure. The ulcer is dressed from then on through this wound, to promote healing from below. After about two to three weeks of treatment along the above lines, when acute inflammation has subsided, surgical debridement is done (see later) and under antibiotic cover, it may be possible in carefully selected cases to close the plantar wound by sutures (if judged feasible) and continue dressing from the dorsum (Fig. 15-12). The ulcer is thus allowed to heal from the sole upwards. By this procedure one may be able to minimise the scar in the sole. Otherwise, it is treated as a 'chronic/healing ulcer'.



**FIGURE 15-12** Diagram of dorsal drainage procedure. **a.** Transverse section showing the extent of joint excision (hatched) and the dorsal corrugated drain. **b.** Elliptical excision of plantar ulcer, sutures in place but not tied (from Fritschi<sup>13</sup>, used with permission).

### Use of antibiotics

In the management of acute ulcers, the first general rule is “Do not use antibiotics as a routine”. The second general rule is “Do not fail to use appropriate antibiotics when needed”. The two rules are complementary and not contradictory.

Neuropathic ulceration in general is a chronic condition in the sense that episodes of ulceration and acute inflammation tend to occur repeatedly in many persons. The body defences are adequate to meet the situation and localise the infection in most instances. One can usually obtain control of inflammation, elimination of infection and healing of the ulcer with cleansing, drainage, dressing and debridement procedures alone, without the use of antibiotics. Routine and indiscriminate use of antibiotics randomly, especially in the absence of identification of the offending organism by culture and sensitivity studies, is sure to promote colonisation of the ulcer with antibiotic-resistant bacteria rendering the antibiotics useless when they may be needed urgently. Hence the injunction against routine use of antibiotics.

Notwithstanding the above, appropriate antibiotics must be used when they are indicated. The stress is on ‘appropriate’ and ‘when indicated’. There are ‘absolute’ and ‘relative’ indications for using antibiotics. Absolute indications include life-threatening infective conditions like septicæmia, infection with highly virulent staphylococci and streptococci (necrotising fasciitis), and infection with clostridia. These conditions are medical emergencies in which aggressive antibiotic therapy is indicated for saving the life of the patient. The ‘relative’ indications are the presence of complications indicative of failure of localisation of infection like cellulitis, acute adenopathy of regional lymph nodes and systemic toxæmia. Antibiotics may also be needed in cases of involvement of deeper structures like underlying bones, joints or tendon sheaths. In these cases, the decision to use antibiotics depends on the extent, duration and severity of the local condition.

Plantar ulcers are often contaminated with ‘street organisms’ such as *Staph. aureus* and *E. coli*. That does not mean that they are necessar-

ily the cause of the clinical condition. Culture-sensitivity results from surface swabs of the ulcer are, therefore, not very reliable guides for selecting the suitable antibiotic agent and so have limited value. To get more reliable information, one should culture the needle aspirate from the ulcer bed or from the biopsied tissue from the ulcer. The few reports in the literature on the bacterial flora in plantar ulcers do not always clearly mention whether the source of the culture material was from acute or non-acute ulcers, whether the ulcer was a recurrent one or a first occurrence and whether the swabs had been taken from deep inside the ulcer.<sup>9,11,14,31,61,66</sup> Therefore, the pattern of bacterial flora in different types of ulcer is generally unknown.

Where the facility is available, one should always attempt to identify the causative pathogen in acute infections by culture of material taken from the depths of the ulcer and its antibiotic sensitivity and administer an appropriate antibiotic or combination of antibiotics. When not available one should use a newer broad-spectrum antibiotic such as the newer penicillin derivatives, quinolones, or a combination of antibiotics, to cover both gram positive and negative organisms.

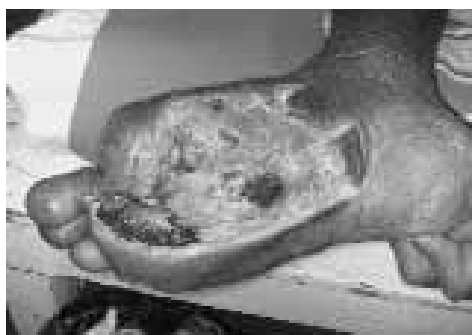The acute ulcer will become a 'healing ulcer' in two to three weeks of treatment. All the signs of acute inflammation will have subsided; the discharge will have diminished to scanty, gummy, serous ooze; the floor of the ulcer, now free of all slough, will consist of pink, healthy granulation tissue; and the edges of the ulcer, from being oedematous and inflamed, will have become sloping with bluish epithelium creeping over healthy granulation tissue. Management of a 'healing ulcer' is almost the same as that of 'Chronic (simple) ulcer', except that we need not scrape the ulcer. If any of the above signs are not found, i.e., if inflammation persists, or, purulent discharge continues, or, there is no evidence of healing,

then this suggests the presence of an underlying complication hindering healing. In that case, the ulcer is to be re-evaluated and treated as a "complicated ulcer".

### **Management of Chronic (Simple) Ulcer**

A chronic ulcer, as its name indicates, is one that does not heal easily and even if it heals, it may take a long time to do so (Fig. 15-13). Broadly speaking, there are two reasons for the ulcer not to heal. The ulcer may not heal because of the presence of a complication that interferes with healing, like persistent infection (usually in a deep structure like a bone or a joint), in which case it should be seen as a 'complicated ulcer', or, the ulcer has not been allowed to heal. These, chronic 'simple' ulcers, do not heal because they have been prevented from healing by absence of rest and unprotected walking. Under those conditions, the delicate epithelium growing over the granulation tissue is physically ground down and destroyed by the stresses generated during walking.

'Chronic simple ulcers' are quiescent ulcers



**FIGURE 15-13** Late stage of a plantar ulcer.

(i.e., not acutely inflamed), which are also usually superficial. They are usually painless, a few millimetres deep, have punched out appearance, with heaped up hyperkeratotic margins, and have a floor of pale granulation covered with whitish film of fibrin or a thin layer of greyish necrotic tissue. Florid or exu-

berant granulation tissue, protruding from the ulcer ('proud flesh'), indicates the presence of sequestra or foreign bodies deep inside the ulcer. The ulcer bed feels hard because of heavy scarring due to previous episodes of ulceration. There is little discharge from the ulcer, just a spotting of slightly turbid sticky fluid or slight blood staining of the dressing. Pedal pulses are normal. Absent pedal pulses, very pale granulations and practically no bloodstaining would suggest ischemia as the reason for the non-healing of the ulcer. The chronic simple ulcer is best treated by applying a below-the-knee plaster of Paris cast after cleaning the ulcer.<sup>3</sup> This method of treatment of plantar ulcers in leprosy patients was first described in the literature in 1939, and its usefulness confirmed a few years later.<sup>16,19</sup> It became the standard method of treating plantar ulcers, all over the world, only in the '60s after Price published this technique.<sup>30</sup> The moulded inner shell of the plaster cast minimises the vertical pressures (compression load per unit area) over the ulcer. By making the sole rigid and by connecting the leg and the foot rigidly, deformation of the foot, during walking, is minimised and the foot gets 'physiological rest'. By avoiding repeated dressing and not allowing any other kind of interference with the ulcer, the process of epithelialisation is protected and healing is promoted.

The ulcer is cleaned with normal saline and dressed with wet saline gauze for a couple of days. It is then gently scraped, with a periosteal elevator or a 10-blade knife, to remove any surface debris and the edges of the ulcer are thinned by tangential shaving off of the thick hyperkeratotic tissue. The ulcer is then covered with a layer of sterile vaseline (petrolatum) gauze, which is packed from above with small pledgets of moist (but not soaking wet) cotton wool so that the Vaseline gauze conforms to the contours of the ulcer and no dead space is left between the gauze and the ulcer. The limb is encased in an adequately, but thinly, padded,

well-moulded, below-the-knee plaster cast (see Appendix D). After 48 to 96 hours, when the plaster cast has dried well (not just hardened but it should have completely dried, as it would break otherwise) it is converted into a walking plaster cast by adding a walking wooden rocker sole. At this stage, it is better to cover the toes completely with a toe cap (after padding the part and allowing sufficient room on the top of the toes for them to bend at their middle joint without rubbing on the toe cap) using plaster bandages. That prevents the front end of the cast shovelling sand and gravel into the cast under the foot. The patient is instructed regarding recognition of a tight plaster cast, how to take care of the limb and the cast, and is then permitted to walk. It is best to measure the feet for appropriate footwear before the plaster is applied and keep them ready for use by the time the cast is removed. Usually, the plaster cast is removed after six weeks, by which time the ulcer should have healed completely. Occasionally a small raw area may still be present that may be treated with a second plaster cast as before or with sticking plaster dressings, without recourse to plaster casting.

### Sticking plaster dressing technique

If for any reason the patient refuses to have the plaster cast, especially when the ulcer is small (< 10 to 12 mm) and not deep (i.e., does not extend deep to the deep fascia), or, a plaster cast is not advisable due to poor skin condition, or, we cannot give the cast for some other reason, it is best to resort to the "sticking plaster technique" for treating the ulcer. In this technique, the ulcer is cleaned and the surrounding areas are mopped completely dry (this is very important as the tape will not stick to moist skin), and narrow (3 or 4 mm wide), overlapping strips of ordinary zinc oxide adhesive plaster (coated with ZnO<sub>3</sub> paste) are laid directly over the ulcer without any intervening gauze piece or medication.<sup>59</sup> The plaster strips

should extend for at least 15 cm, all round, beyond the margins of the ulcer. If the adhesive plaster spans the ulcer, because of its depth, leaving a dead space between the ulcer and the plaster, packing the top of the plaster with small pledgets of cotton wool, or small wads of gauze, and using a bandage or larger pieces of sticking plaster to retain them in position will eliminate the dead space and establish total contact between the ulcer and the plaster strips. The outer bandage may be changed daily or as often as necessary. However, the adhesive plaster dressing is not removed daily but kept on for four to seven days, or, till it starts peeling off. The oily exudate is wiped clean, the ulcer is mopped dry and dressed with adhesive plaster strips, exactly as before. The patient is instructed to keep the plaster dressing as long as possible, avoid walking as much as possible and if the foot gets wet, mop it dry, without removing the sticking plaster strips, at the earliest opportunity. When the foot gets dirty, it is washed well and mopped dry only. Apart from these instructions, there are no other prohibitions. In fact, patients may be given the plaster strips to take home, after teaching them and a member from their family the correct way to apply the sticking plaster strips.<sup>22</sup> This technique is very useful, particularly in the field. This useful mode of treating plantar ulcers, was first discussed in connection with venous ulcers by Gilje in 1948 and applied successfully to treat burn wounds and popularised for use in ulcers in leprosy in the late '70s and early '80s by Stenström.<sup>30,57,60</sup> It was described originally by Paul in Sri Lanka for treating ulcers in leprosy patients in the 1930s!<sup>32</sup>

Under treatment, using the sticking plaster technique, the ulcer undergoes autolytic debridement and it heals completely, in the moist environment, in three to eight weeks. The delicate epithelium covering the newly formed scar needs to be protected (with sticking plaster, cotton wool and bandage) for

another three weeks or so before exposing it to direct weight bearing in footwear.

### Use of skin grafts

Healing of large (>20 mm) simple ulcers is significantly hastened by covering them with split-thickness skin grafts (medium-thickness, preferably from the instep), after cleaning them up and scraping them. The graft takes in two weeks, but it should be protected for another three to four weeks. Even if the graft does not take, it serves as the perfect dressing for the raw area and the ulcer heals under it. It should be noted that there is great shearing strain at the graft-skin junction because of the difference in the thickness of the two structures and this junction dehisces in course of time. Therefore, it is best to replace the split-thickness graft at the earliest opportunity with a full-thickness skin graft, taken preferably from the dorsum of the foot.

Innumerable methods of treating plantar ulcers are found in medical literature, ranging from local use of a variety of antibiotics, anti-septic agents, vitamins, other chemical, biological and plant extracts, anti leprosy drugs and their derivatives, vasodilators, surgery for improving blood flow in the foot to stretching and surgery on the posterior tibial nerve and perineural injections of vasodilators and other chemicals, magnetotherapy and homeopathy all claiming good results.<sup>8,38,39</sup> For a critique of such practices readers may consult the papers by Price and Srinivasan.<sup>36,37,54</sup> Evidently, if any attention is paid to the ulcer, it will usually heal.

We must bring home to the patient that healing is only one stage in the natural history of the ulcer, the next stage being recurrence of the ulcer, that recurrence is not inevitable and that the patient's efforts are needed to achieve that. Therefore, the patient's responsibility to take care of the foot does not diminish or disappear with getting the ulcer healed. In fact it increases and it becomes even more important



that he/she should continue to use protective footwear (indoor as well as outdoor) besides taking other protective foot-care measures. Otherwise, the ulcer is most likely to recur and each bout of recurrence makes it that much more difficult to heal it subsequently.

### **Management of (Chronic) Complicated Ulcer**

One reason for the non-healing of an ulcer is the presence of a complication. The most common complication is the continued presence of a focus of non-specific infection in a deeper structure, which has become infected from the ulcer. Healing is significantly retarded when a sufficient bacterial load (>10<sup>5</sup> bacteria per gram of tissue) is present. Breakdown of the wound and delayed healing occur when there is 'invasive infection, not just colonization of the ulcer'. The non-specific infection may thus persist in an underlying bone or joint or improperly drained tendon sheath or soft tissue space. This deep site of infection communicates with the exterior through one or more sinus tracks and the wound gets constantly re-infected from the deep pocket. The infection destroys the epithelium, effectively preventing healing of the ulcer. It is evident that we can get the ulcer to heal only if we get rid of the deep focus of infection and this is achieved through surgical debridement. One should attempt to locate the focus of infection by careful clinical examination, systematically examining the whole foot, not just the ulcer site, and all the structures likely to be involved such as bones, joints, tendon sheaths and plantar tissue spaces. Radiographic examination is equally important and that should always be done without fail.

### **Debridement**

In the technical jargon of people working in the field of management of chronic wounds, the term 'necrotic tissue' refers to dead tissue that looks black and is adherent to living tissue,

'non-viable tissue' refers to creamy white stringy non-living tissue that is loosely adherent to live tissue, 'cleansing' is removal of foreign matter from the ulcer and 'debridement' is removal of non-viable tissue from the wound. Based on the means used, ulcer debridement has been described as autolytic, biochemical, mechanical and sharp or surgical.

In *autolytic* debridement we make use of the body's own ability to digest and dissolve non-viable tissue. Occlusive and semi-occlusive dressings, left in place for a few days allow accumulation of the exudates from the wound and permit concentration of white cells, enzymes like elastase and growth factors which help clearance of the necrotic material and promote healing. In adopting plaster of Paris casting and using the sticking plaster technique of dressing chronic ulcers, we are using autolytic debridement to get the ulcer healed.

*Biochemical* debridement is achieved by using enzymes to digest and dissolve the non-viable tissue. This is particularly useful in sites that are difficult to access for sharp or surgical debridement.

*Mechanical* debridement is achieved by using the so-called 'wet-to-dry dressing' technique. A moist coarse-meshed gauze is used to cover the wound and it is allowed to dry. Later when the gauze is ripped off, necrotic tissue adherent to the gauze comes off along with the gauze.

In *sharp* or *surgical* debridement the necrotic tissue is removed by sharp dissection using knife and scissors.

Those specialising in treating chronic ulcers, especially burns, decubiti (bed sores) and chronic venous stasis ulcers in the leg have developed the above terminology. Leprosy workers do not make such fine distinctions in terminology while dealing with plantar ulcers. Generally, 'biochemical' and 'mechanical debridement' are not used in leprosy. We use the word 'cleansing' to refer to non-surgical

methods of cleaning up an ulcer. "Debridement" is used more as in the context of acute traumatic wounds to denote surgical cleaning of the ulcer to get rid of all dead and doubtfully viable tissue and hopelessly infected tissue as well as any foreign matter that may be present in the ulcer.

*Surgical debridement.* A chronic ulcer develops a micro-environment that is hostile to wound healing and different from that of an acute wound.<sup>66,67</sup> The exudates have a diminished amount of growth factors and the macrophages are less responsive to carry out repair due to senescence, proteolytic activity is increased and there is bacterial contamination in these wounds.<sup>58,65</sup> All these factors adversely affect wound healing. Furthermore, necrotic tissue is a very good medium for bacterial growth; and the persistent inflammatory activity that results delays the healing process, preventing it from moving on to the next stage of wound repair. It is logical, therefore, to eliminate these hostile environmental factors by surgical debridement and convert the chronic ulcer into an acute wound that has greater potential for healing.<sup>12</sup>

Surgical debridement is the technique of ridding an ulcer of dead and doubtfully viable tissue and foreign material, using surgical dissection in order to achieve healing of the ulcer. This is not a bedside procedure like "scraping the ulcer". During the procedure, every part of the ulcer is systematically attended to as described below.

*Ulcer margin.* Excise a thin (ca. 1 to 1.5 mm) rim of the edge of the ulcer cleanly using a size 10 or 11 blade knife to get a freely bleeding edge for the ulcer; and thin the thickened and hyperkeratotic margins of the ulcer by tangentially shaving off the superficial layers of the skin, using size 10 blade knife.

*Floor of the ulcer.* Curette the floor of the ulcer thoroughly using a sharp Volkmann's curette or the sharp edge of a curved periosteal elevator, removing in the process all dead and

devitalised tissue and unhealthy granulation as well as any foreign matter like grit, sand particles, thorns and splinters. Control any bleeding with hot gauze packs. The base of the ulcer is now exposed.

*Base of the ulcer:* Examine the base of the ulcer visually and by probing carefully for openings of sinus tracks, curette the sinus tracks thoroughly and fully lay them open. Search the deep ends of the sinus tracks for pent up pockets of infection like abscess cavities in bones, joint spaces, tendon sheaths and tissue spaces. These are thoroughly curetted and spiky or rough bone ends are trimmed. Infected tendon sheaths should be curetted in their entirety and proper drainage ensured by appropriate and adequate counter incisions. In the process of dealing with the base of the ulcer, remove all badly infected soft tissue as well as pieces of sequestra and small grains of dead bone ('bone sand') and the rough surfaces of infected ends of bones. In the case of ulcers under the head of the first metatarsal, if found infected and deformed, one should not hesitate to excise the concerned sesamoid bone(s) in toto. At the same time, one should be careful not to remove too much of normal and near normal tissue in the process of debridement. The guiding principle in carrying out surgical debridement is: "*Ruthless excision of all dead and devitalised tissue, but careful conservation of all healthy tissue*". At the end of the procedure, a badly draining deep ulcer with infected sinuses and deep foci of infection will have been converted into a healthily bleeding, freely draining, clean and comparatively shallow wound.

*Counter incisions:* Wherever felt necessary, one should not hesitate to make adequate counter incisions in order to ensure free drainage. Counter incisions are usually needed over the dorsum of the foot, sometimes along the sides of a toe or the foot, over the proximal part of a tendon sheath, below the ankle or in the region

of the tarsal tunnel for draining infected long flexor tendon sheaths.

*Dressings:* After completing surgical debridement, the wound is dressed with one layer of Vaseline (petroleum jelly) gauze overlaid with pledgets of moist gauze (in order to eliminate dead space between the wound and the Vaseline gauze), and covered with bulky gauze dressing. The wound is subsequently dressed once a day for a few days and when the discharge from the wound becomes mere blood staining of the gauze, the limb is encased in a

below-the-knee plaster of Paris cast. The cast is retained for at least six weeks. In most cases the wound would have healed by that time. If not, another plaster cast may be applied and retained for another four weeks or longer depending on the state of the residual ulcer. If it is a small, superficial and healing wound we may use the sticking plaster technique described earlier without resorting to a cumbersome plaster cast.

A summary of the management of plantar ulcers is shown in Figure 15-14. While it does not include all contingencies, it shows the

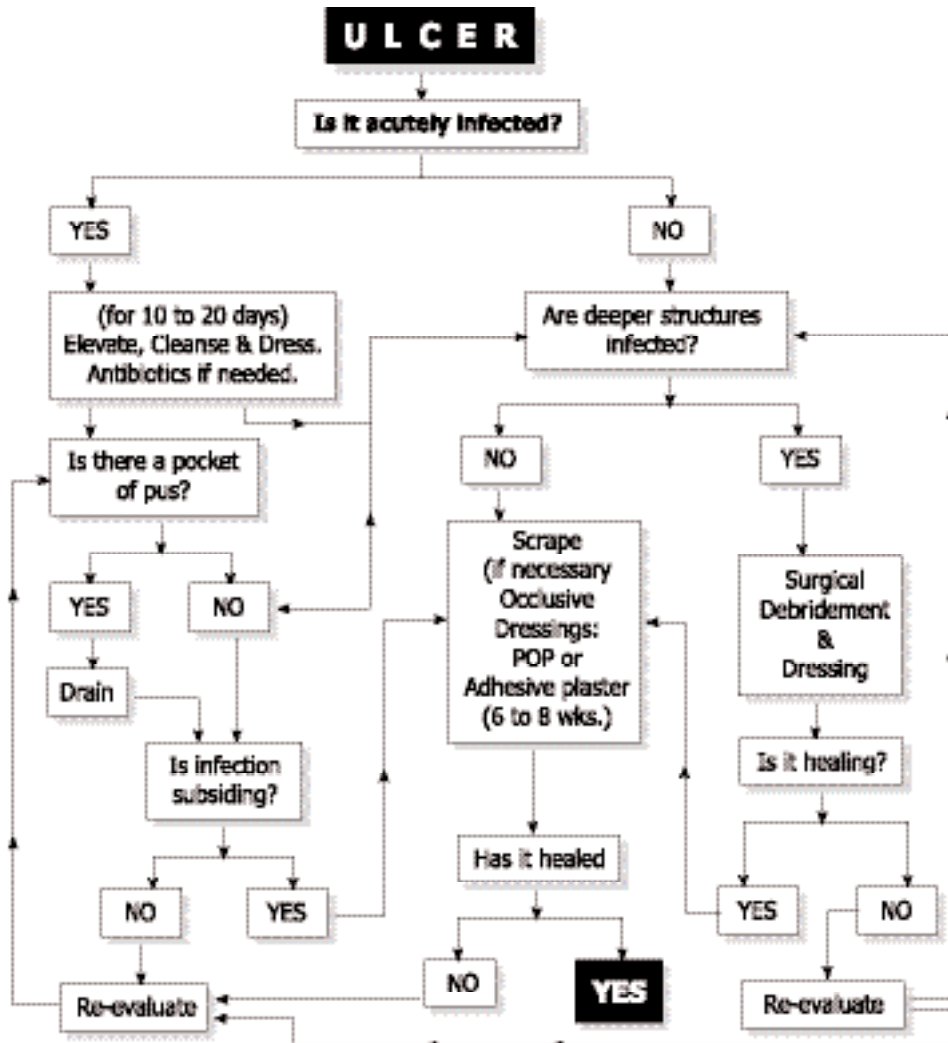


FIGURE 15-14 Decision Tree for the Management of Plantar Ulcer.

major approaches to the management of plantar ulcers. It should also be noted that, in order to avoid complicating the chart further, it does not cover the problem of recurrent plantar ulceration and occasional complications like malignant degeneration.

### Other complicating factors

Sometimes, some other feature besides local spread of non-specific infection complicates the situation. The complicating factors include neoplastic degeneration, septicæmia, clostridial infections and deep fungal (and pseudofungal) infection.

*Neoplastic degeneration.* Chronic ulcers are known to undergo malignant transformation and plantar ulcers are no exception. It is not a very common occurrence and probably not more than 1 to 2 % of plantar ulcers seen in a leprosy hospital will be malignant. Malignant plantar ulcers usually present as 'cauliflower growths' (CFGs), which are proliferative fungating lesions developing in a fairly long-standing ulcer of a few years' duration (see Chapter 18).<sup>40,42</sup>

*Septicæmia.* In patients debilitated by inanition, or, in the concomitant presence of debilitating conditions like diabetes or tuberculosis, generalised septicaemia may develop. The condition must be treated promptly and aggressively with parenteral antibiotics and supportive measures, as emergency. Surgery is limited to necessary drainage and debridement procedures only.

*Deep fungal infection.* Occasionally, the plantar ulcer is complicated by concomitant development of mycetoma ('Madura foot') due to deep (subcutaneous) fungal or pseudofungal infection such as actinomycetes and Nocardia. Considering that chronic plantar ulcers provide excellent opportunities for infection by these organisms, such infections are surprisingly rare and only a few case reports are found in

the literature.<sup>18,21</sup> In view of its infrequency, there is not enough published information to suggest which one, the mycetoma or the plantar ulcer, is usually the primary lesion and even whether they are related to one another at all. It should also be mentioned that heel ulcers presenting with chronically infected calcaneum and gross thickening of the bone, fibrosis of soft tissue and multiple sinuses around the heel area, clinically indistinguishable from mycetoma, are far more common than mycetomas. In these cases, the diagnosis of mycetoma must be established by diligent search for fungal colonies (white, yellow or black "granules") in the discharges and scrapings from sinuses or by biopsies of deeper tissues.

Prolonged antibiotic therapy and anti fungal medication, for at least six to ten months, combined with repeated debridement of sinuses and abscess cavities in the bones and soft tissues are required for getting rid of these infections.

*Clostridial Infection.* A chronic wound, especially in the foot, is always in danger of infection with clostridia, especially with *C. tetani*, but the patient rarely develops local or even general tetanus. Occasionally, gas gangrene may supervene. The patient is in a state of toxæmia and collapse and the condition is characterized by severe toxæmia, swelling of the part, crepitus in the subcutaneous tissue and muscles and translucent areas delineating muscles and tissue planes in the radiograph. There is thin bloody discharge from the ulcer and necrotic patches in the limb. While swabs are taken for bacteriological diagnosis, one does not wait for the results to start treatment. Treatment is started on clinical diagnosis. This is a surgical emergency carrying a grave prognosis and calls for emergency amputation, aggressive administration of antibiotics and supportive therapy.

### **Management of Recurrent Plantar**

## Ulcers

Recurrence of plantar ulceration is so common a feature that it is “normally” expected to occur. Most people would consider healing as just one stage in the natural history of the ulcer, the next being its recurrence. This is a defeatist view, which could have been valid half a century ago, but not now. It should be emphasised that recurrent ulceration is a preventable condition in almost all instances if the problem is tackled rationally, diligently and with optimism, applying practices of orthopaedics, podiatry and plastic surgery. We should also remember that management of plantar ulceration always has two aims: (a) an immediate aim to get the ulcer healed, and (b) a long-term aim, to ensure that it does not recur.

Recurrent plantar ulcers are of two general types: 1. those that recur because the affected person has not taken normal precautionary preventive measures, and 2. those that recur despite adequate precautionary measures. Most of them belong to the first category and, for their prevention, they require diligent practice of ulcer-preventive practices by the affected persons. However, in a small proportion of patients, the ulcer has already recurred a number of times (because of earlier negligence) and the tissues have suffered such severe damage that ordinary or standard preventive measures are inadequate to prevent recurrence. This type of recurrent ulcers needs additional measures, by way of surgery and/or special footwear, besides standard foot-care practices for their prevention.<sup>56</sup> These are the ‘true recurrent ulcers’ and their management is discussed in this section.

### Causes of recurrent ulceration

Plantar ulcers recur for the following four reasons:

1. *The original causes continue to operate.* The conditions that originally contributed to the development of the ulcer continue to be pres-

ent. They are: denervation and consequent insensibility and dryness of plantar skin, with or without plantar intrinsic muscle paralysis, combined with unprotected and unlimited use of the feet. If normal plantar tissue, structured to withstand walking strains, gave way under these conditions originally, it is not surprising that scar tissue, which is not structured to withstand walking strains, gives way again and again. This is the first kind of recurrent ulcer mentioned earlier. The remedy here is to follow ulcer-preventive foot-care practices, including the use of appropriate protective footwear, diligently.

2. *The scar tissue is of poor quality:* Because of repeated bouts of ulceration and healing the scar at that site becomes dense, brittle, ischaemic and unstable, ready to breakdown even under conditions of less than normal loading. In some feet, the scar is of such poor quality that taking literally half a dozen steps, even with protective footwear, is sufficient to make it breakdown and cause recurrence of the ulcer. The remedy here is to improve the quality of load-bearing tissue, by tissue replacement, or, protect the scar, by some means, preventing the load falling on the scar.

3. *The scar is loaded excessively.* The scar tissue that replaces the normal, finely loculated, subcutaneous fat layer lacks the latter’s springiness and shock-absorbing cushioning effect. Repeated infection or neuropathic bone disintegration may distort the local anatomy by destroying local structures, and these changes result in excessive loading of the scar tissue. This, inevitably, causes early breakdown of the scar and recurrence of ulcer. The remedy here is to protect the scar by modifications in the footwear or by surgically realigning anatomical structures such that the scar is relieved of much if not the entire load.

4. *There is a periodic flare up of infection.*



Lastly, as with infection in the larger bones, infection in the bones of the foot also tends to persist and flare up periodically, with opening up of old sinuses and ulcers and formation of new ones. This kind of acute-on-chronic osteitis happens particularly in feet with infection of the calcaneum or some other major tarsal bone like the cuboid, sometimes in feet with infection of the metatarsal head. Often a minor injury triggers the episode, most probably by producing a local hæmatoma, which would permit an invasive proliferation of the pathogenic organism. The remedy for preventing recurrence of ulcers from this cause is to eradicate the infection with aggressive treatment using all available methods viz., cleansing, repeated surgical debridement and adequate use of effective antibiotics. Occasionally, one may have to resort to radical surgery to get rid of the infected focus. Thus, subtotal resection of the calcaneum (excising much of the body of the calcaneum, leaving behind only the talocalcaneal joints with some bone underneath) has been found very useful to eliminate the hopelessly infected sclerotic bone not amenable to antibiotic therapy.<sup>52</sup> After this procedure, the patient can walk with any type of footwear in which the heel is built up and cushioned.

We can avoid recurrent ulcers by a) having the patient diligently practising foot-care procedures including constant use of appropriate protective footwear and b) eradication of infection locally. If the ulcers still recur, the foot is evaluated afresh and, depending on the local condition, c) replacement of the scar with better quality tissue and, d) use of surgical and non-surgical measures to relieve the load on the scar will help prevent recurrence of these ulcers.

### **Foot-care (see also Appendix C)**

The denervated feet of affected persons are substandard structures, both structurally and functionally, and they require special care measures to maintain their integrity without

which they will invariably breakdown. The dry, anhidrotic and insensitive plantar skin (sole) should be cared for properly to avoid development of cracks and fissures, which are precursors to ulcers. Further, in many leprosy-affected persons, the foot is structurally weakened because of muscle paralysis and walking with such weakened feet without protective footwear damages the plantar tissues, especially the subcutaneous fatty layer that acts as shock-absorbing cushion, and causes ulceration. Therefore, we need 1. 'skin care' practices to keep the skin intact and avoid it breaking up, and 2. 'walking-care' practices to permit walking without exposing the foot to the danger of ulceration.

1. 'Skin care' practices have two different aims: a) keeping the skin soft and supple. Otherwise the denervated, dry skin develops cracks which become portals of entry of infection leading to ulceration; and, b) protecting the insensitive skin from being wounded from without. The first aim of keeping the sole soft and supple is achieved by the procedure of daily soaking, scrubbing and smearing with oil. The foot is soaked in soapy water or saline for ten minutes, the sole is scrubbed with a pumice stone or any similar object with a rough surface to scrape off superficial keratin layers, washed, mopped to remove the excess moisture and smeared with some oil, preferably one which will not attract ants and other vermin (e.g., neem (margosa) oil or castor oil). This procedure should become a daily habit, like brushing one's teeth. If the patient can afford it, moisturising lotions could be used, though this is less effective than soaking and oiling. The second aim of preventing wounding of the sole (by nails, thorns, sharp stones or hot surfaces) is achieved by using footwear with tough soles. Such footwear should be worn, preferably all the time one is on one's feet or, at least every time the person goes out of the house, and not just on some special occa-

sions (like going to the weekly village fair or going to the town for seeing a cinema), as is the habit with some people. While leprosy institutions provide their clients footwear with tyre soles for this purpose (because of considerations of cost), those who can afford it can use commercially available modern, lightweight, durable and tough soles made of synthetic material. While plantar skin is protected by footwear, using gloves when handling hot or rough objects protects palmar skin. This topic is dealt with in detail elsewhere.<sup>55</sup>

2. *Reduction of walking strains.* The second aim of protecting the feet from walking strains is achieved by two strategies namely: a) reducing the duration of walking, avoiding walking long distances and using a vehicle if one has to do so; and b) using appropriate protective footwear (with suitable modifications and inserts depending on the local condition of the foot) in order to reduce the strains on the feet during walking.

When the foot is merely anaesthetic, as mentioned earlier, the foot only needs to be protected from being injured from without and this is achieved by having a tough outer sole to the footwear. Where there is plantar intrinsic muscle paralysis in addition, a shock-absorbing, pressure-reducing modification is needed and this is achieved by the addition of a soft springy insole to the footwear. Microcellular rubber (MCR) that will mimic the action of the normal subcutaneous layer in the sole of the foot is the material most often used for this purpose. The average hardness of the normal (unscarred) human sole is about 20 shore 'A' (personal observation in South Indian patients who were not using footwear as a routine). MCR of similar, or preferably slightly less (say, 15 shore A), hardness is to be used in the routine footwear intended for leprosy affected persons having plantar intrinsic muscle paralysis besides loss of sensibility in the sole. If the foot has already had ulcers, the scar may be protect-

ed by additional modifications such as a rigid sole-rocker, metatarsal bar, extended heel or arch support (Chapter 17).

### Improving quality of scarred site

Durability of the scarred weight-bearing site is obtained by replacing the unstable scar with tissue of better quality, or by shifting the scar to a non-weight-bearing locale. Figure 15-15 lists the common methods of achieving this aim.

Where feasible the scar is excised, the

#### Scar excision and wound closure by:

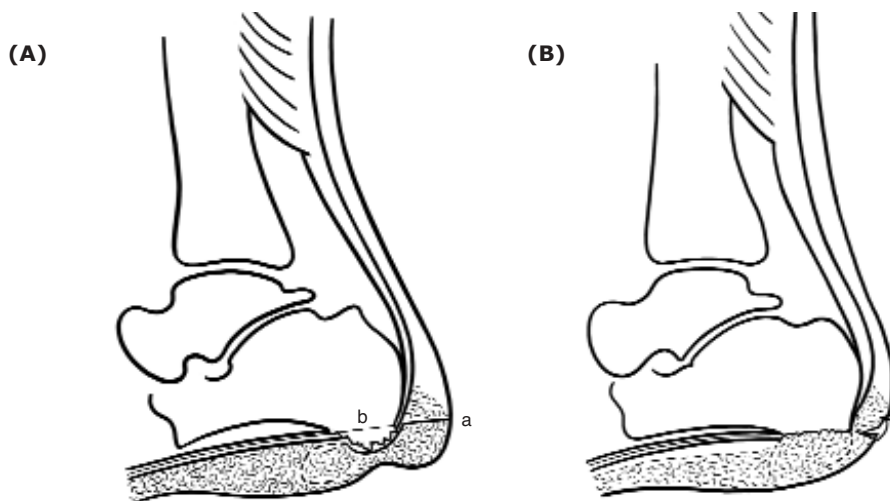
- Suture or skin graft
- Local flap or distant flap
- Island pedicle flap or free flap, or,
- Shifting scar to non-weight-bearing site

**FIGURE 15-15** Means of improving scar sites.

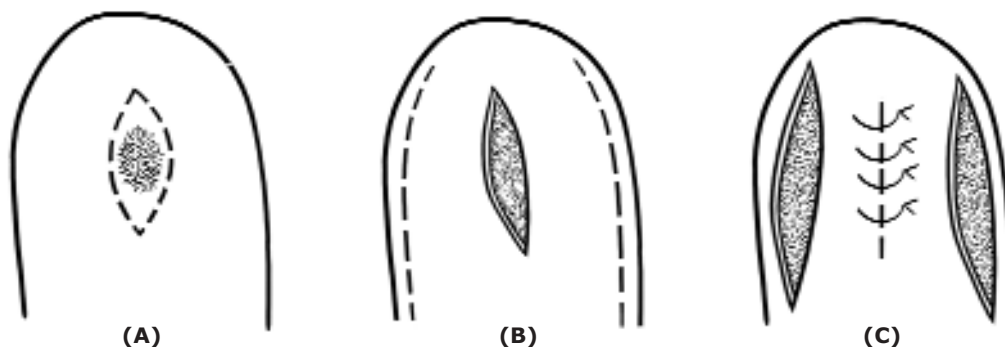
wound edges are undermined and the wound is closed by direct suturing. If possible, a subcutaneous fat flap may be interposed between the scar and the deeper tissues in order to improve the shock-absorbing quality of the weight-bearing site.<sup>46</sup>

When closure by excision and re-suture is not feasible, skin grafting may be done to cover the raw area. Depending on the local condition, we may use split-thickness or full-thickness skin graft. Split-thickness graft may be taken from the sole itself, from a non weight-bearing area like the instep. The dorsum of the foot is a good donor site for full-thickness skin graft in the sole of the foot.

*Use of local flaps.* Using a local flap, mobilised from around the ulcer may be a better way to cover the raw area resulting from excision of the scar. This has the advantage of providing tissue very similar to the one that was lost due to ulceration. Small to medium sized unstable adherent scars in the middle of the heel are so excised as to give an antero-posteriorly oriented oval or lens-shaped wound.



**FIGURE 15-16** Improving scar site. Schematic illustration of the procedure: Interposition of subcutaneous fat flap between bone and skin combined with bumpectomy to reduce load on scar in heel. **A.** a) incision for exposure. b) level of bump excision. c) incision for mobilising subcutaneous fat flap. **B.** Following completion of the procedure.



**Figure 15-17** Scar excision and skin closure in heel using a bi-pedicle (buckle handle) flap **A.** Scar in heel and incision for excising the scar **B.** Scar excised; incisions in the margins of the heel for mobilising bi-pedicle flaps. These incisions should be longer than the gap in the skin and should be made in the non weightbearing area **C.** Bucket handle flaps mobilised and central gap closed without tension to provide a linear (and stable) scar in place of the broad, adherent (and unstable) scar.

This wound is then closed by raising two bucket-handle flaps from the two sides of the central wound, by making two release incisions, one on each side of the lateral margin of the heel, and suturing them together to provide a linear scar in place of the earlier unstable broad scar (Fig. 15-17).

The release incisions made for raising the bucket handle flaps should be longer than the central wound in order to ensure tension-free

closure.<sup>50</sup> An adherent and unstable scar under a metatarsal head may be excised and closed in his manner except that here the wound created by excising the ulcer is transversely oriented and the release incision (which should be longer than the wound to be closed) is also made transversely, about 20 mm to 25 mm anterior to the creases at the bases of the toes.

Another way of raising a local flap of good

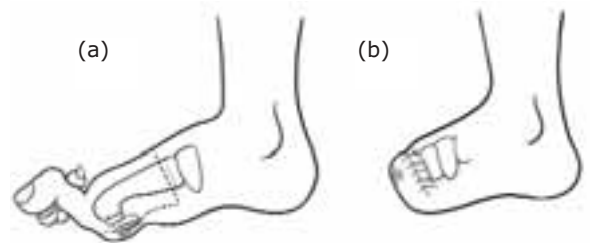
quality to replace a scar is to fillet a toe (i.e., remove all the remnants of phalanges in the toe leaving behind only the soft tissue) and use the now available skin of the toe for closing the raw area created by excising the unstable scar (Chapter 16). This procedure is indicated when the unstable scar is located under the head of a metatarsal, whose toe (or its neighbour) has become a functionless flail appendage and a positive nuisance while wearing footwear because of previous ulceration. Instead of amputating and discarding such a toe, it may be filleted and the soft tissue used for scar replacement as mentioned above.

We may also use a rotation flap to cover the raw area resulting from excision of an unstable scar. The scar is excised using a triangular incision and one side of the triangle is extended as a widely sweeping curve. A back cut of adequate length is made, sufficient to mobilise the flap to fully cover the wound created by scar excision but not so long as to endanger the blood supply of the flap. The flap is rotated to cover the raw area and sutured, using, if necessary, a free skin graft to cover any raw area in the region of the back cut.

The local flaps mentioned thus far are within the capabilities of a competent surgeon interested in this kind of surgery. There are other flaps, local and distant, like artery pedicled island flaps and composite (free) flaps, which have been found useful in dealing with recurrent ulceration, but they require specialist (plastic / microvascular) surgical expertise (Chapter 16).<sup>23-27</sup>

*Shifting scar to non weight-bearing site.* When the ball of the foot is badly scarred and normal protective precautions by way of foot-care and walking-care, including modifications in the footwear, are unable to prevent the breakdown of the scar, one may resort to diverting the body weight away from the scar (e.g., patellar

tendon bearing (PTB) orthosis), or, diverting the scar out of the way of body weight. We may achieve the second aim by doing a transmetatarsal amputation (bone section just distal to the bases of the metatarsal bones) and closing the wound using a long plantar flap incorporating the unstable scar near its distal end. When the flap is turned over to cover the wound, the scar is automatically shifted to the dorsum or the front end of the foot, escaping weight-bearing, and weight is now borne by normally structured plantar tissue (Fig. 15-18).



**FIGURE 15-18** Transmetatarsal amputation for preventing recurrent forefoot ulceration.  
**a.** Grossly deformed toes and unstable and adherent forefoot scar. Interrupted line shows skin incision to give a long plantar flap. Dotted line shows the level of bone section, preserving the proximal one-inch of the metatarsal.  
**b.** Amputation completed. Note suture line is on the dorsal side and the scar has been shifted to a non-weightbearing site of the foot.

### Reducing stress on the scar

Another reason for frequent recurrence of the plantar ulcer is that the scar, which is already of poor quality, is further subjected to excessive stress during walking. The site of excessive stress and its relation to the scar may be demonstrated by taking footprints, preferably using a Harris mat, but they can be taken even without it. The scar may be relieved of excessive stress by introducing modifications in the footwear or by surgery (Chapter 16, 17).

## CONCLUSION

It should be made clear that there are no set solutions, like cookery recipes, telling us what to do for a given ulcer, because each foot, and each ulcer in a given foot, has a unique history and morbid anatomy of its own. Nevertheless, with the knowledge of the varieties and patterns of stress and loading that a foot is subject to during standing and walking, one can work out a solution for relieving the particular stress in the given case. This means that one should examine the foot very carefully, and study each ulcer in that foot, develop a plausible hypothesis about how the ulcer is stressed during standing and walking and, work out a method of eliminating that stress based on that hypothesis.<sup>48,51</sup> The following case summaries illustrate this approach.

**CASE 1.** PRN (male, 37 years). Problem: Frequently breaking down ulcer in the region of proximal phalanx (area between the two digital creases on the plantar surface) of right big toe. Ulcer starts as a crack in the old scar, and the crack widens into an ulcer. No involvement of bone or tendon sheath or chronic local infection. Plantar anaesthesia present. No plantar intrinsic paralysis. Hypothesis: The relatively unyielding scar gets unduly stretched during walking causing it to breakdown. Proposed solutions: 1. Replace scar with tissue that can stretch better or, 2) eliminate the stretching stress by making the plantar tissues of the big toe lax, by shortening the skeleton of the toe.

The second solution was adopted and excising the distal half of the proximal phalanx shortened the toe. Follow-up 18 months later showed no recurrence of the ulcer.

**CASE 2.** RK (male, 28 years). Problem: Frequently recurring ulcer in left foot under 3rd metatarsal head (MTH). Originally started as an area of hyperkeratosis under MTH 3, which broke down and developed into an

ulcer. No underlying deep infection. Footprint shows very high pressure under MTH 3. Plantar anaesthesia present, no plantar intrinsic paralysis. Hypothesis: Head of 3rd MT wedge shaped giving rise to high pressure under this MTH. Proposed solution: Duvries' condylectomy (through a dorsal approach, tangential excision of the undersurface of the MTH making it flat (instead of being wedge shaped) and thus enlarging the weight-bearing area many times).

This was done. Follow-up 11 months later showed no recurrence. Footprint showed no high-pressure sites.

**CASE 3.** RM (male, 35 years). Problem: Recurrent ulceration of terminal pad of 2nd toe (left foot). Earlier had ulcer of big toe pad and during one episode of severe infection the big toe was removed. Second toe ulceration started some months later. Ulcer over pulp (terminal pad) of 2nd toe with no bony involvement and no big toe. Second toe much longer than the others. Anaesthesia medial half of sole with paralysis of muscles supplied by medial plantar nerve. Walking footprint shows dragging of tip of 2nd toe with high pressure. Hypothesis: In the absence of big toe, tip of the 2nd toe bears most of the stress of transfer of load from the foot. Proposed solution: Shorten the 2nd toe so that it is level with the others so that all four toes share walking stresses and reduce that on the 2nd toe.

This was done by excising the middle phalanx of the 2nd toe. Follow-up one year later showed an ulcer-free 2nd toe.

**CASE 4.** MS (male, 19 years). Problem: Frequently recurring ulcer under first MTH (right foot). Started with ulcer under MTH3 many years ago followed later by ulceration under MTH 1. Foot shows a deep cleft under MTH3, dorsal migration of 2nd and 3rd toes, and severe secondary hallux valgus with thin adherent scar under MTH1. The 1st MTH ulcer heals without difficulty, but recurs promptly on



walking (with protective footwear) even for a day or so. Footprint shows high-pressure area under MTH1. Hypothesis: Repeated ulceration led to loss of head and distal shafts of 2nd and 3rd metatarsals with shortening of these rays and dorsal migration of the central toes followed by hallux valgus because of loss of lateral support to big toe. Hallux valgus rendered the big toe useless permitting severe overloading under MTH1. Proposed solution: Correct hallux valgus, release the dorsal scar and bring the toes forward and retain them in that position by fusing the 2nd toe with the big toe and 3rd toe with the 4th (surgical syndactylia).

This was done. Seen eight months later, the foot was ulcer-free.

**CASE 5.** VKR (male, 28 years). Problem: Recurrent ulceration under 3rd and 4th MTH for the last seven years. Ulcer recurs despite protective footwear and foot-care practices. End-on (frontal) view of non weight-bearing foot shows severe 'reversal of the distal transverse metatarsal arch' (the metatarsal heads describe an arch with convexity towards the ground). Third degree clawing of 2nd, 3rd and 4th toes (flexion contracture of PIP joint, dorsal migration of toe with the base of proximal phalanx of the toe resting on the neck of its metatarsal and the MTH can be felt in the sole, like a pebble just under the skin). Walking footprint shows high pressure area under 2nd, 3rd and 4th MTH's. Hypothesis: Because of the 3rd degree claw deformity, the concerned MTH is pushed down by the PP of the toe during walking (during contraction of FDL and EDL muscles). Proposed solution: Reduce the dislocation of MTP joints, re-position the toes to lie in front of their MTH's instead of lying on top of them, straighten the toes and lift up the "fallen" metatarsal heads by transplanting concerned EDL tendons to the necks of their respective metatarsals (proximalization of EDL).

This was done through a dorsal approach. Follow-up for five years showed no recurrence of the ulcer.

**CASE 6.** M (female, 31 years). Problem: Recurrent ulcer in middle of left heel. Adherent scar in the middle of the heel with a bony mass just under the scar. X-ray with marker over the scar shows abnormally prominent calcaneal tubercle directly above the scar. Hypothesis: Scar breaks down due to excessive shearing and compression during walking. Proposed solution: Convert broad adherent scar into thin linear scar-by-scar excision and resuture and enlarge bony weight-bearing surface by excising the bossy calcaneal tubercles to provide a larger, flat surface. If feasible, interpose between bone and scar, a local fat flap mobilized from one side.

This, including fat flap interposition, was done. Seen 14 months later, the ulcer had not recurred.

**CASE 7.** JM (male, 57 years). Problem: Recurrent ulceration of both heels for many years, despite use of protective footwear and practicing foot-care. Has sound scar in mid heel. Ulcer found in anterior heel area. X-ray (with marker over ulcer) shows secondary calcaneus recurvatus deformity ("boat-shaped calcaneum") with ulcer under the front end of calcaneum. Subtalar articulation is intact. It is this ulcer that keeps recurring now. Hypothesis: The posterior pillar of longitudinal plantar arch has been lost because of the bony deformity. Therefore, during heel strike, the front end of calcaneum hits the ground and this is the reason for recurrent ulceration under front end of heel. Proposed solution: Restore posterior pillar to produce normal heel strike. This was done by doing a displacement osteotomy of calcaneum. Seen 18 years later, the heel was ulcer-free.

It should be evident from the above illustrative case summaries that a plantar scar may be

overloaded due to dynamic and/or static stresses, because of obvious, or not so obvious or even occult, anatomical abnormalities (e.g., talipes, congenital varus 5th toe and wedge shaped MTH respectively). Our experience shows that it is worth taking the trouble and spending time to identify the exact cause of recurrence and eliminate it. The expertise required is eclectic and techniques from the disciplines of orthopaedics and plastic surgery are needed for surgery in this field.

## REFERENCES

1. Basmajian JV: *Muscles Alive: Their Functions Revealed by Electromyography*. Baltimore, Williams & Wilkins, 1962
2. Bassan MM: Near fatal systemic oxygen embolism due to wound irrigation with hydrogen peroxide, *Postgrad Med* 58:448-451, 1982
3. Birke JA, Novick A, Hoard A, et al.: Methods of healing plantar ulcers in Hansen's disease patients. *The Star* 51:5-10, 1992
4. Bloomfield SF, Sizer TJ: Eusol B.P.C. and other hypochlorite formulations used in hospitals. *Pharm J* 235:153-157, 1985
5. Bradley M, Cullum N, Sheldon T: The debridement of chronic wounds: a systematic review. *Health Techn Assess* 3, No. 17, 1999
6. Brand PW: Pressure sores: the problem. pp.19-23. In Kenedi RM, Cowden JM, Scales JT(eds): *Bed Sore Biomechanics*. Macmillan, London, 1976
7. Brand PW: *Insensitive Feet: a practical handbook on foot problems in leprosy*, 3rd ed. The Leprosy Mission, London, 1991
8. Chakraborti D, Datta S, Chakraborti T: Trial of homeopathic medicine in the prevention of disability. *Proceedings 16th International Leprosy Congress, Salvador, Brazil*, pp. 314, 2002
9. Cherian E, Vanaja G, Krishnan R, Bhatia VN: Bacterial flora of ulcers treated by three types of dressings. *Ind J Lepr* 60:389-391, 1988
10. Dakin H.D: On the use of certain antiseptic substances in the treatment of infected wounds. *Brit Med J* 11: 318-320, 1915
11. Ebenezer G, Daniel S, Suneetha S, et al: Bacteriological study of pus isolates from neuropathic plantar ulcer associated with acute inflammatory phase. *Ind J Lepr*, 72:443-449, 2000
12. Ehrlich HP: Why wounds need to be debrided. pp. 23-29. In Westerhof W and Vanscheidt W (eds): *Proteolytic Enzymes and Wound Healing*. Springer, Berlin, 1994
13. Fritschi EP: *Surgical Reconstruction and Physical Rehabilitation in Leprosy*. The Leprosy Mission, Delhi, 1984
14. George M, Bhatia VN, Kar HK, Roy RG: Anaerobic flora in trophic ulcers in leprosy patients. *Ind J Lepr* 57: 336, 1984
15. Gorse GJ, Messner RL: Improved pressure sore healing with hydrocolloid dressings. *Arch Dermat* 123: 766-771, 1987
16. Haythornthwaite HW: Closed plaster for trophic ulcers. *Lepr India*, 15:20-22, 1943
17. Impey SP: *Handbook of Leprosy*. J&A Churchill, London, 1896
18. Jayakumar J, Aschoff M, Renuka G: Mycetomas in leprosy. *Ind J Lepr*, 65:229-233, 1993
19. Khan JS: Treatment of leprosy trophic ulcers. *Lepr India* 11:19-21, 1939
20. Kozol R.A., et al: Effects of sodium hypochlorite (Dakin's Solution) on cells of the wound module, *Arch Surg* 123: 420-423, 1988
21. Kulkarni RB, Patil RT, Praveena S: Actinomycotic mycetoma due to *Nocardia brasiliensis* in a case of leprosy. *Ind J Lepr* 73:263-265, 2001
22. Kumar A, Laxmanan M: Adhesive zinc tape treatment of uncomplicated ulcers amongst leprosy patients. *Lepr Rev* 57:45-91, 1986
23. Liwen D, Futian L, Zaimeng W, Juan J: Techniques for covering soft tissue defects resulting from plantar ulcers in leprosy: General considerations and summary. *Ind J Lepr* 71:279-295, 1999
24. Liwen D, Futian L, Juan J, Guocheng Z: Techniques for covering soft tissue defects resulting from plantar ulcers in leprosy-2: first toe web and dorsal foot flaps. *Ind J Lepr* 71:297-309, 1999
25. Liwen D, Futian L, Jugen Z, Yongling Y, Juan J, Guocheng Z: Techniques for covering soft tissue defects resulting from plantar ulcers in leprosy-3: use of plantar skin or musculocutaneous flaps and anterior leg flap. *Ind J Lepr* 71:3-16, 1999
26. Liwen D, Futian L, Juan J, Guocheng Z: Techniques for covering soft tissue defects resulting from plantar ulcers in leprosy-4: use of medial leg flap and medial knee flap. *Ind J Lepr* 71:17-30, 1999

27. Liwen D, Futian L, Juan J, Guocheng Z. Techniques for covering soft tissue defects resulting from plantar ulcers in leprosy-5: use of the flap in the inguinal region and latissimus dorsi musculocutaneous flap. *Ind J Lepr* 72:227-244, 2000
28. Malaviya GN, Husain S, Girdhar A, Girdhar BK: Sensory functions in limbs of normal persons and leprosy patients with peripheral Trunk damage. *Ind J Lepr* 66:157-164, 1994
29. Molan PC: Honey as a dressing for wounds, burns and ulcers: a brief review of clinical reports and experimental studies, *Primary Intention* 6: 148-158, 1998
30. Ovington L: Wound dressings: their evolution and use. pp221-232. In V.Falanga, (ed): *Cutaneous Wound Healing*. Martin Dunitz, London, 2001
31. Palande DD, Desevery C, Rajagopalan MS: Plantar ulcers with osteomyelitis underneath. A bacteriological study. *Lepr India* 49:322-329, 1977
32. Paul M: Surgical measures in leprosy. *Int J Lepr* 4: 29-34, 1936
33. Price EW: Studies on plantar ulceration in leprosy. *Lepr Rev*, 30:98-105, 1959
34. Price EW: The natural history of plantar ulcers. *Lepr Rev*, 30:180-183, 1959
35. Price EW: The etiology of plantar ulcers. *Lepr Rev* 30:242-248, 1959
36. Price EW: The complications in plantar ulcers. *Lepr Rev* 31:97-103, 1960
37. Price EW: Plantar ulcers in leprosy: A review of the literature. *Lepr Rev* 32:108-116, 1961
38. Raghupathi SG, Subramanyam S, Deenabandhu A et al.: Exposure to pulsed magnetic fields in the treatment of plantar ulcers in leprosy patients: a pilot, randomised, double blind controlled clinical trial. *Ind J Lepr* 69:241-250, 1997
39. Rao KS, Mahendra Kumar, Oommen PK et al.: Collagen sheet and its usefulness in healing ulcers in leprosy patients. *Ind J Lepr* 59:435-441, 1987
40. Richardus JH, Smith TC: Squamous cell carcinoma in chronic ulcers in leprosy. A review of 38 consecutive cases. *Lepr Rev* 62:381-387, 1991
41. Ross FW: Aetiology and treatment of plantar ulcers. *Lepr Rev* 33:25-40, 1962
42. Sane SB, Mehta JM: Malignant transformation of trophic ulcers in leprosy: a study of 12 cases. *Ind J Lepr* 60: 93-99, 1988
43. Sleigh JW, Linter SPK: Hazards of hydrogen peroxide. *Brit Med J* 291:1706, 1985
44. Srinivasan H: Trophic ulcers in leprosy-I: distribution of ulcers in the sole of the foot. *Lepr India* 35:119-127, 1963
45. Srinivasan H: Trophic ulcers in leprosy-II: ulceration and plantar intrinsic paralysis. *Lepr India* 36:110-118, 1964
46. Srinivasan H, Mukherjee SM: Trophic ulcers in leprosy III. Surgical management of chronic foot ulceration. *Lepr India* 36:186-193, 1964
47. Srinivasan H: Plantar ulcers and corrective surgery: determining factors in localization of foot ulcers in leprosy patients. *Lepr India* 37 (Suppl 3A): 3-8, 1965
48. Srinivasan H: Reconstructive surgery and prevention of neuropathic plantar ulcers. In *Proceedings of International leprosy Seminar, Agra, 1967*. Published by Ministry of Health, Government of India, New Delhi, 1967
49. Srinivasan H, Desikan KV: Cauliflower growths in plantar ulcers in leprosy. *Lepr India* 43:24-32, 1971
50. Srinivasan H: Heel ulcers in leprosy patients. *Lepr India* 48:355-361, 1976
51. Srinivasan H: Reconstructive surgery for correction of deformities of foot and for prevention of recurrent plantar ulceration. pp 637-649. In Dharmendra (ed): *Leprosy-Vol. 1*. Kothari Medical Publishing House, Bombay, 1978
52. Srinivasan H: Surgery of os calcis in leprosy patients. *Bull Tamil Nadu Orthop Assn*, 28-32, 1981
53. Srinivasan H: Prevention of recurrent neuropathic ulceration of the forepart of the foot. *Ind J Surg* 44:300-304, 1982
54. Srinivasan H: Do we need trials of agents alleged to improve healing of plantar ulcers? *Lepr Rev* 60:278-282, 1989
55. Srinivasan H: Prevention of Disabilities in Patients with Leprosy. Geneva, World Health Organization, 1993
56. Srinivasan H, Palande DD: Essential Surgery in Leprosy: techniques for district hospitals. pp.18-35. Geneva, World Health Organization, 1997
57. Süderberg T et al: Treatment of leprosy wounds with adhesive zinc tape. *Lepr Rev* 53:271-276, 1982
58. Stadelman WK, Digenis AG, Tobin GR: Impediments to wound healing. *Am J Surg* 176 (Suppl. 2A):39S-47, 1994

59. Stenstrøm S, Bergman G, Bergman S: Wound healing with ordinary adhesive tape. *Scand J Plast Reconstr Surg* 6: 40, 1972
60. Stenstrøm S et al: Leprosy wound healing with ordinary adhesive tape: a preliminary report. *Scand J Plast Reconstr Surg* 10:241, 1976
61. Sturm AW, Jamil BMC, Adam KPWJ et al: Microbial colonizers leprosy skin ulcers and intensity of inflammation. *Int J Lepr* 64:274-281, 1996
62. Tarnuzzer RW, Schulz GS: Biochemical analysis of chronic and acute wound environments. *Wound Rep Reg* 4:321-325, 1996
63. Taylor HD: The solvent action of antiseptics on necrotic tissue. *J Exp Med* 27:155-164, 1918
64. Tudhope M: Management of pressure ulcers with a hydro-colloid occlusive dressing: results in twenty-three patients, *J Enterostomal Ther* 11:102-105, 1984
65. Vande Berg JS, Rudolph R, Holan C, Haywood-Reid PL: Growth factors and chronic wounds: Fibroblast senescence in pressure ulcers. *Wound Rep Reg* 6:38-49, 1998
66. Vinodkummar CHD, Harikrishnan S, Bhatia VN, Rot RG: Bacteriological study of trophic ulcers in leprosy patients. *Lepr Rev* 55: 504, 1983
67. Yager DR, Chen SM, Ward SI et al: Ability of chronic wound fluids to degrade peptide growth factors associated with increased levels of elastase activity and diminished levels of proteinase inhibitors. *Wound Rep Reg* 5:23-32, 1997

# Role of Flaps and Skin Grafts in the Management of Neuropathic Plantar Ulcers

• P.E. GRAVEM

## INTRODUCTION

When I for the first time saw leprosy patients at ALERT Hospital, Addis Ababa in 1986, I was taken by surprise seeing so many people walking around on seriously neurologically impaired feet. Most of them were relatively young people who had to walk a lot in order to earn their daily living. Foot ulcers were very common. As a plastic surgeon, I was familiar with covering tissue defects of different kinds with skin grafts and flaps. I must say I started off rather enthusiastically trying to cover many plantar ulcers, believing that time could be saved and that the quality of life could be improved for many patients by an active surgical approach to the ulcer problem. When I look back today, the only group of patients I feel really benefited from modern plastic surgical procedures, and actually got a “new foot”, was a rather small but still important group of patients with big heel defects, ulcers as well as unstable scars. The medial plantar island flap turned out to be very successful and represented a real improvement compared with surgical procedures described in more traditional textbooks for surgeons dealing with leprosy related problems. Otherwise, it is also my experience that one often can be quite conservative waiting for secondary healing of the majority of plantar ulcers in leprosy. Of course, the basic principles of pressure point reduction and adjustment of footwear must be addressed. But there are exceptions, and covering procedures sometimes have to be considered.

## GENERAL CONSIDERATIONS

The skin and underlying soft tissue of the sole of the foot is anatomically unique and damage to the weight bearing portions requires reconstruction by similar tissue for the best long-term results. There seems to be an innate mechanical property of the sole itself that gives it capacity to bear weight and to withstand shear, which is very important in preventing ulceration, as is sensation.<sup>6,7</sup> The firm adhesion of skin to plantar fascia limits skin mobility and makes it a firm-gripping pad for heavy traction. Therefore, local flaps are employed whenever possible. As a main principle, tissue from a non-weight bearing area of the foot is moved into a weight bearing area and the donor site may or may not have to be covered with a skin graft.

Before considering any surgical procedure to introduce new tissue in an ulcerated plantar area, the cause of the ulceration must be analyzed. Methods of preventing recurrent ulceration can be deduced from a study of the mechanism resulting in ulceration. Often it is obvious, such as infected wounds and cracks. In these cases general foot- and skin care is of uttermost importance in preventing re-ulceration. Another large group of ulcers has a tendency to persist without treatment and rest, and to relapse on the resumption of walking with a considerable risk of deep infection and consequent deformity and destruction of the foot. Such ulcers are usually pressure sores over a bony prominence. In such a case, to perform skin grafting or to do a beautiful flap



without being able to reduce the pressure of which the ulcer was caused, is useless and a waste of time. Only footwear modification or bone surgery, or both can reduce the harmful pressure in such areas. The surgery may consist of simple osteotomy of a bone spur or an arthrodesis to realign the foot.

## **METHODS OF COVERAGE OF ULCERS**

### ***Distant Skin Flaps***

Multiple distant flaps (i.e. cross thigh flaps, cross groin flaps, buttock skin flaps, free muscle flaps covered with split skin graft) with tissue not specialized to withstand walking, are described in the literature to cover plantar defects. Patients with normal plantar sensation might to some extent be able to protect such tissue somehow by avoiding full weight bearing during the cycle of walking. However, distant flaps are seldom indicated in leprosy. These patients have feet that lack protective sensation and they need to be able to walk a lot. Distant flaps will not be further described in this chapter with the exception of the medial cross-plantar flap, which I personally have found quite useful.

### ***Local Muscle Flaps***

Different local muscle flaps like abductor digiti minimi, abductor hallucis brevis and flexor digiti minimi muscle covered with skin graft are usually of little value since these intrinsic muscles are usually atrophied in the neurologically impaired foot. These flaps will not be further described.

### ***Transposition and Rotation Skin Flaps of the Sole of the Foot***

Fascio-cutaneous flaps, i.e. flaps consisting of skin, subcutaneous tissue as well as plantar fascia have been recommended in older leprosy textbooks.<sup>7</sup>

With the exception of the medial plantar island flap, I personally do not have much experience with such flaps. However, the results I have seen done by other surgeons have not been convincing (Fig. 16-7).

In inexperienced hands, these big fasciocutaneous flaps can easily leave the patient in a less favourable situation. However, similar but thinner flaps where the plantar fascia is not included can work well. These are flaps consisting of epidermis, dermis and the specialized fibro-fatty pad overlying the plantar fascia. The dissection is more superficial and technically simpler to do than a fasciocutaneous flap based on an axial vessel, i.e. the medial plantar flap. These superficial flaps must be considered random flaps. The blood supply does not permit an immediate transfer, so they need to be delayed. The flaps should in most cases be laterally based, leaving the donor area with a skin graft in the non-weight bearing medial aspect of the foot. The preferred method of delay might be incision of skin and sub-cutaneous tissue only without undermining the flap, and then re-suturing. After 2 or 3 weeks the flap is transferred into the defect. A split skin graft is applied to the donor area.

### ***Skin Grafting***

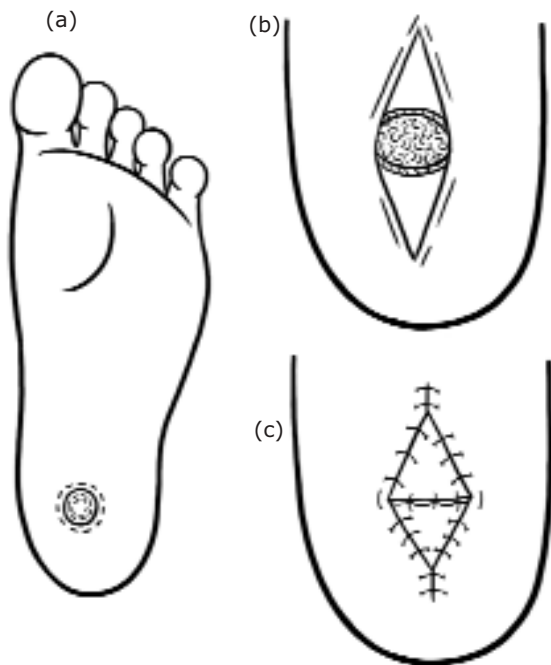
When an ulcer or defect is due to loss of skin only (e.g. burns), split skin grafting is a useful primary treatment for large and clean granulating ulcers on the sole. In these cases, a layer of plantar fascia and padding remains intact between the graft and the underlying bone. In the non-weight-bearing areas like the instep a split-skin graft can usually be applied successfully even when the pulp consisting of subcutaneous tissue and fascia is missing.

## **SPECIFIC PROCEDURES**

The specific procedures for coverage of ulcer defects on the sole are described below, divided by anatomic region.

### Heel Coverage

Small or superficial defects can usually be treated with rest, application of a plaster cast, or simple split skin grafting. In case of a chronic sinus leading down to the bone or the plantar fascia attached to the calcaneus, so-called calcaneal paring is indicated (see Chapter 15). For small deep ulcers a V-Y plasty or delayed cutaneous transposition flap can also work well (See below).



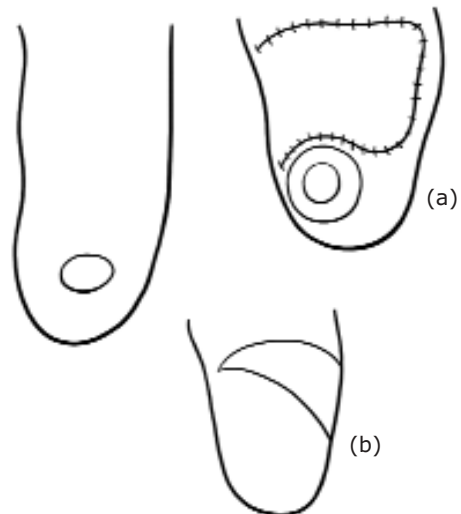
**FIGURE 16-1** Small deep heel ulcer covered with opposing V-Y flaps. Because there is absolutely no undermining with the local V-Y flap, its mobility is restricted by underlying tissue and can usually be advanced only 1-1,5 cm. To expand the size of the defect that a single V-Y flap can cover, two opposing V-Y flaps can be designed. The larger the V-Y, the better is the blood supply and the more the flap can be advanced.

The large heel defects, which sometimes present with total loss of soft tissue and bone involvement as well, have too often been an indication for below knee amputation. Large

local fascio-cutaneous transposition flaps recommended in older textbooks might be sufficient to cover smaller defects, but frequently these flaps just do not reach to the area where the tissue is needed the most. Furthermore, the scar left by a poorly designed flap can add an additional problem to the function of the foot.

### Laterally based transposition flaps for heel coverage

Alternatively, a laterally based skin flap can be applied (Fig. 16-2).<sup>3,7</sup>

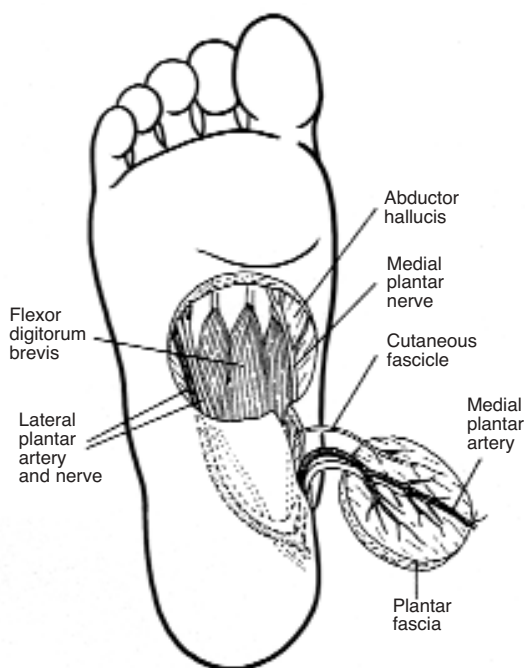


**FIGURE 16-2** A relatively small heel defect can be covered with a laterally based transposition flap. **a.** Delay procedure is performed **b.** Surgical correction with excision of ulcer and surrounding scar. The previously delayed flap is transposed into the defect and the donor area is covered with split skin graft.

### Medial plantar island flap for heel coverage

This flap has proved to be reliable and extremely useful for heel reconstruction in leprosy (Fig. 16-3).<sup>5</sup> Hence, it will be described in detail. It should be stressed, however that the dissection is not easy and that some familiarity with more complicated plastic surgical procedures as well as microsurgery is an advantage.

General surgeons with some experience in basic plastic surgery should be able to perform the operation safely after necessary exposure. Learning to utilize this flap is well worth the effort.



**FIGURE 16-3** Anatomy and dissection of the flap.

### Indications

This flap is recommended as a standard method for heel reconstruction in most cases where there is major loss of soft tissue. It can be used for recurrent ulcers as well as squamous cell carcinomas of the heel. The posterior tibial artery must be patent. Dorsalis pedis artery or the peroneal artery must also be patent.

### Anaesthesia

A spinal or general anaesthesia is usually necessary.

### Procedure

The position and route of the posterior tibial artery is marked prior to surgery (Figs. 16-3,

4a). A Doppler can be helpful in this. The patient is placed in a prone position, and a tourniquet is applied. The heel ulcer should be debrided, if necessary debridement could be performed some days prior to the coverage procedure. The ulcer, together with surrounding scar tissue should be excised and the underlying bone should in most cases be trimmed to make sure the bony surface is smooth and healthy. A circular defect is easiest to cover. The flap, which is based on the medial plantar vessels, is planned just proximal to the weight bearing area of the metacarpal heads. The diameter of the flap should correspond to the size of the heel defect and there is no reason to oversize it. A line is drawn from the centre of the flap to the area behind the medial malleolus where the posterior tibial artery was felt before the tourniquet was applied. Then a second line is drawn from the centre of the heel defect to the medial malleolus. The flap is first incised distally down through the subcutaneous fat and the plantar fascia, then in the same manner laterally and medially. Proximally, the incision should be more superficial so as not to destroy the pedicle. Deep intra muscular septa have to be divided in order to raise the flap. The medial plantar nerve can be visualized, and in most cases it can be cut distally and included in the pedicle. This makes the dissection simple and reduces the risk of injuring the vessels. In rare cases, with intact protective sensation of the forefoot, one could consider to retain the nerve in the foot while the cutaneous fibres to the flap itself are peeled off the main nerve. This kind of dissection needs loop magnification. Knowing the direction of the vascular pedicle, a strip of soft tissue about 2 cm wide located between the short muscles of the foot and the plantar fascia will incorporate the vessels. Some deep septa under the pedicle need to be divided. Where the pedicle goes under the abductor hallucis muscle this muscle sometimes needs to be

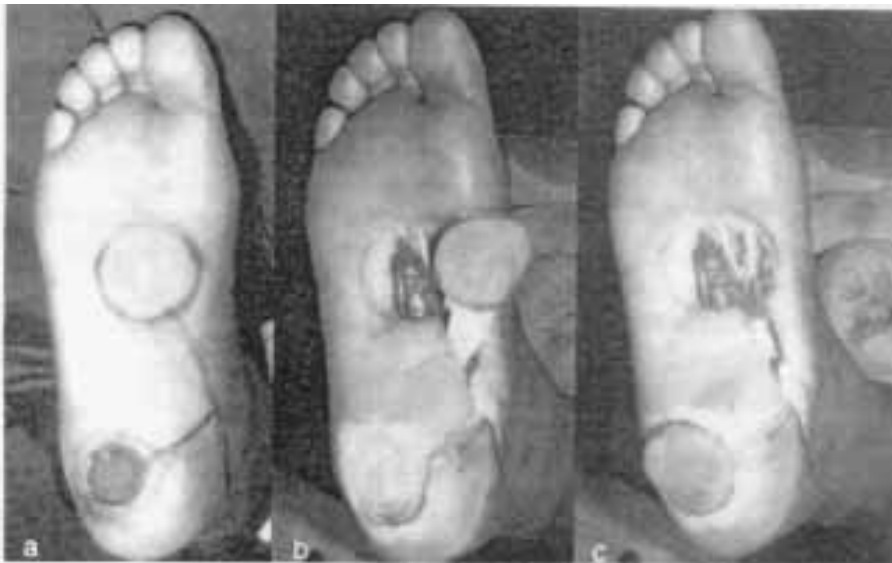
divided in order to make the pedicle long enough to allow the flap to be transposed smoothly into the heel defect without any tension. It is recommended to make the incision from the heel defect towards the pedicle quite deep, and to do this prior to the dissection of the pedicle itself (Fig. 16-4b). Some undermining of the soft tissue between these incisions will make the flap reach the heel more easily, and one can avoid the most proximal and hazardous dissection of the pedicle. When the pedicle is long enough, the flap is transposed and the tourniquet is released (Fig. 16-4c). After a few minutes of light compression, the bleeding is controlled with a bipolar cautery and a rubber drain is left to drain the pedicle and flap area. The incisions are closed with interrupted 3-0 stitches before the donor area is covered with a split skin graft. A compressing dressing is applied on the donor area with the skin graft while a rather loose well-padded dressing, pos-

sibly with a window for inspection is applied on the heel itself.

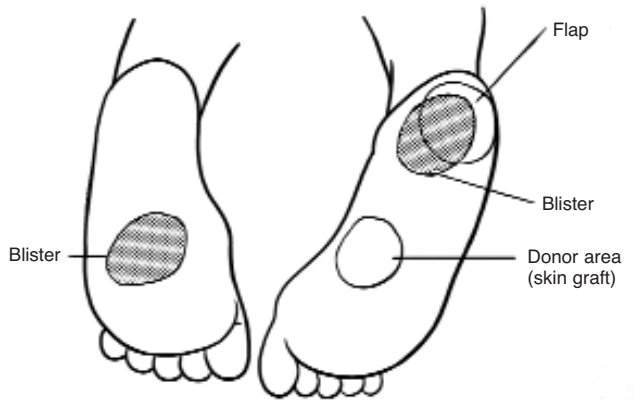
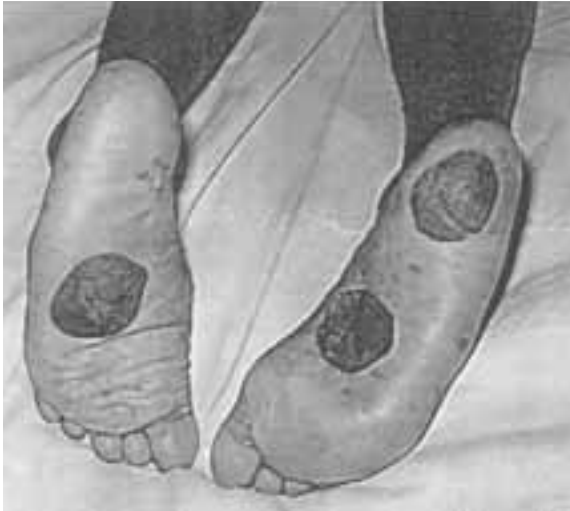#### After-Care

An adequate prophylactic antibiotic should be given pre- and postoperatively for a few days. The rubber drain is pulled out after 2-3 days, and the whole dressing can be changed after 5-7 days. During this period the patient should have strict bed rest with the foot slightly elevated. Walking without weight bearing is then gradually allowed, and the stitches are removed after 2 weeks time. In most cases full weight bearing is allowed after four to five weeks. Results are shown in Figs. 16-5 and 16-8.

There is a possibility that removal of the plantar fascia weakens the support of the foot and hence predisposes for collapse of the arch later on. In case arch support is considered it is important to wait up to 3 months time in order



**FIGURE 16-4** **a.** Preoperative marking in an 18 year old girl with an ulcer of 2 years duration. Notice how the scar tissue surrounding the ulcer is excised with the ulcer and how the flap is constructed just proximal to the weight-bearing region of the metacarpal heads. A line is drawn from the posterior tibial artery behind the medial malleolus to the centre of the planned flap. Another line is drawn to mark the incision for the tunnel of the pedicle. **b.** The flap consisting of skin, subcutaneous fat, and a thick well-defined plantar fascia is raised on the vascular pedicle. Note the bulk of the pedicle containing the vessels. **c.** The flap is transposed smoothly to the defect without tension or kinking.



**FIGURE 16-5** A 33 year old man operated for an ulcer of the right heel 4 months previously. His left foot was “boatshaped” because of collapse of the longitudinal arch. A 10 km long walk resulted in haemorrhagic blisters (dark area of left midfoot and right heel). Notice how the blister of the right heel is affecting the flap and surrounding tissue equally, indicating that the quality of the flap is similar to that of the native soft tissue of the heel.

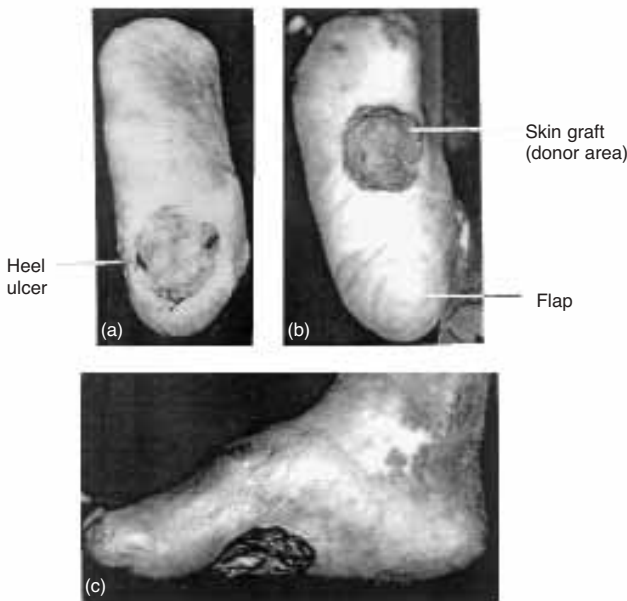
to let the split skin graft of the donor area gain sufficient stability and strength to take the pressure from the inlay device. The defect left by the removal of subcutaneous tissue will have filled in by that time.

### Cross-Foot Flap for heel coverage

In case the instep of the same foot is not suitable for a flap harvest, it is possible to raise the medial plantar flap from the contra lateral foot (Fig. 16-7). An external osteo-fixation between the tibias as well as a K-wire between the two calcaneal bones will keep the legs in a stable position until the pedicle is safely divided after two weeks. Alternatively, plastering can be used to hold the position but is difficult to maintain.

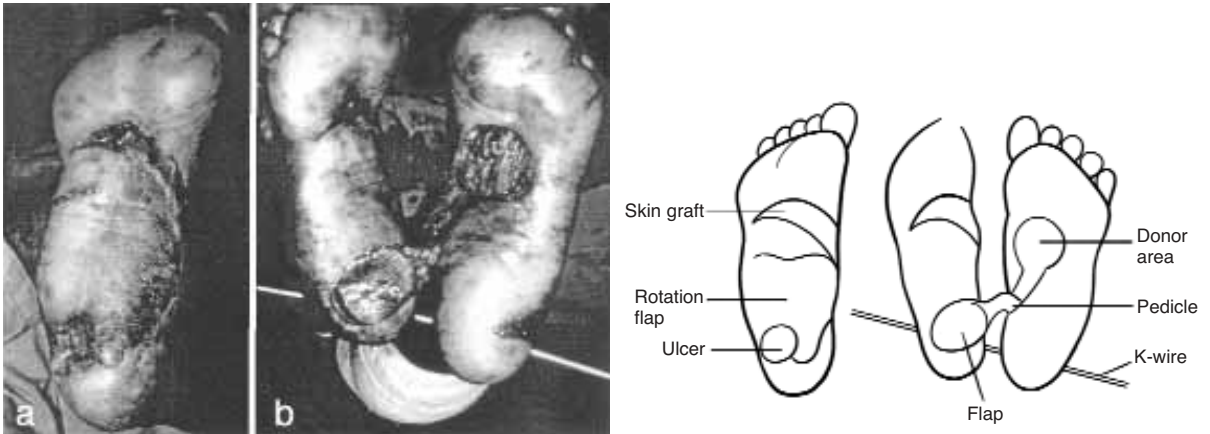
### Midfoot Coverage

Defects on the medial aspect of the plantar surface are non-weight bearing and are best treated with skin grafts. If there is an underlying

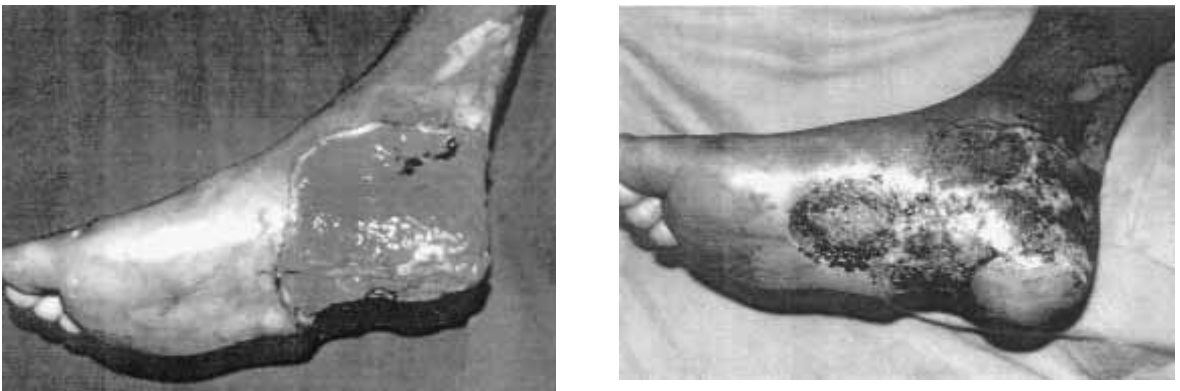


**FIGURE 16-6 a.** Extensive heel ulcer with total loss of soft tissue of 8 years duration in a 48 year old man. **b.** 8 months after reconstruction the heel looks normal with an excellent result including good stability.





**FIGURE 16-7** **a.** The plantar area in a 40 year old woman who had a huge laterally based fasciocutaneous transposition flap raised 3 years previously. Notice new ulceration of the heel area. **b.** Operative picture showing adequate length of the vascular pedicle reaching from one instep to the opposite heel. External osteofixation between the two tibias and a K-wire through the calcaneal bones kept the legs in a stable position until the pedicle was safely divided two weeks later.



**FIGURE 16-8** Pre- and postoperative pictures in case of an extensive avulsion injury in 25 years old non-leprosy patient. The weigh-bearing area of the heel is covered with an island flap from an intact distal instep. The donor area as well as the remaining raw area is covered with split-skin.

bone causing an existing midfoot ulcer, as usually occurs with a collapsed Charcot foot, the excess bone can be shaved via a lateral or medial approach or sometimes directly through the ulcer during debridement. The ulcer can be either allowed to heal by secondary intention or addressed depending on its size. For small defects, a V-Y flap can be useful, while for larger defects large medially or laterally based delayed random flaps can work well (See type of flaps).

Once healed, the patient with a Charcot foot has to be considered for a possible mid/hind foot fusion so that the breakdown will have less chance of recurring.

### **Forefoot Coverage**

For small ulcers over the MTP joint without bone involvement a pressure point reduction procedure (see Chapter 15) is usually sufficient for the ulcer to heal by secondary intention. Small deep forefoot ulcers without an obvious

bony prominence can also be covered with a local flap: a filleted toe flap, (Fig. 16-9) a toe island flap (Fig. 16-10), a V-Y flap<sup>2</sup> (6) or a larger rotation flap (Fig. 16-11).

#### Using soft tissue from a toe:

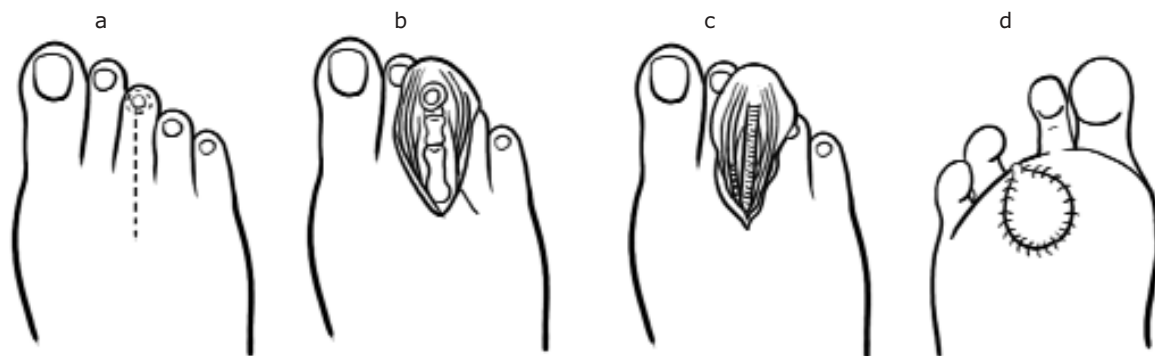
**Indication:** Small and deep recurrent ulcers of the forefoot, usually under the metacarpal heads.

In leprosy, functionless toes, subluxated appendages with their own risk of friction ulceration can serve the foot instead of being a troublesome liability. Generally, the soft tissue of the toe is used in the flap, discarding the skeleton. Alternatively, if the toe has a normal

The toe is incised dorsally and the soft tissue is dissected from the skeleton, visualizing the neurovascular bundles. The toe skeleton can now be excised. The metacarpal head should be trimmed or removed, depending on the condition of the forefoot. The neurovascular bundles are then mobilized, dividing the transverse ligament. After freeing the skin, the flap is hinged into the defect. Excess toe skin might need to be resected.<sup>4,8</sup>

#### Toe island flap (Digital Artery Island Flap (Fig. 16-10)

Based on one of the neurovascular pedicles this flap can close small forefoot ulcers.



**FIGURE 16-9** Toe island flap (Digital Artery Island Flap) **a, b.** Dorsal incision with excision of nail **c.** Excision of bone **d.** Final result.

shape and size, one-half of the toe skin based on one neurovascular bundle could be used, grafting the resulting defect on the toe. For replacement of a defect in the metacarpal head area the soft tissue of the toe might be hinged at the level of the transverse plantar ligament, although it can be hinged as far back as the plantar arch if dissection deep to the toe flexors is involved.

#### Filleted Toe Flap (Fig. 16-9)

**Technique:** The plantar ulcer with surrounding scar is excised, leaving edges of healthy tissue.

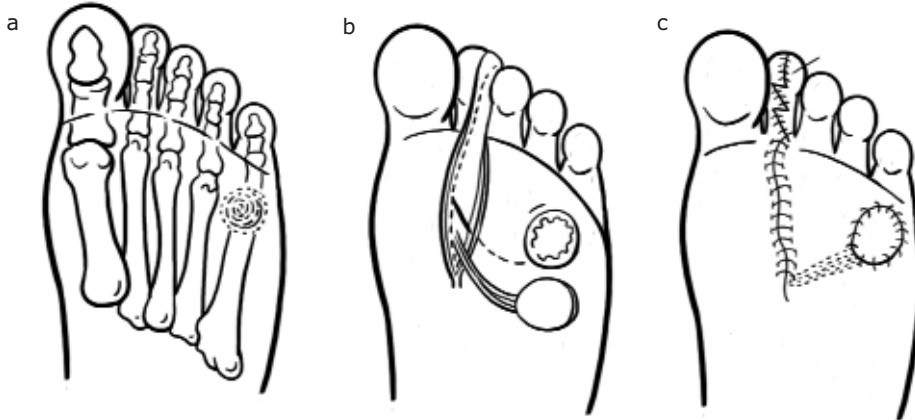
**Technique:** The flap consisting of skin and subcutaneous tissue is designed on the side of the toe avoiding the nailbed and including only part of the plantar area of the toe. The incision is extended through the plantar pad of the forefoot, and the neurovascular bundle that lies on the side of the flexor tendon is mobilised. As for the filleting toe flap, the transverse ligament must be divided. When the pedicle has sufficient length, a subcutaneous tunnel is created to the ulcer area; the island flap is transposed and sutured. The donor area of the toe is covered with a skin graft.

**V-Y Plasty for forefoot coverage**

See V-Y Plasty for coverage in the heel area. (Fig. 16-1) The principle as well as the limitations is much the same in the metacarpal areas.

**Laterally based Transposition Flap for forefoot coverage (Fig. 16-11).**

**Indications:** Recurrent ulcers of the medial and central forefoot.



**FIGURE 16-10** Digital artery island flap. **a.** Site of ulcer under 5th metatarsal head. **b.** flap raised from site of toe based on neurovascular pedicle. **c.** Flap insert, skin graft sutured over defect.

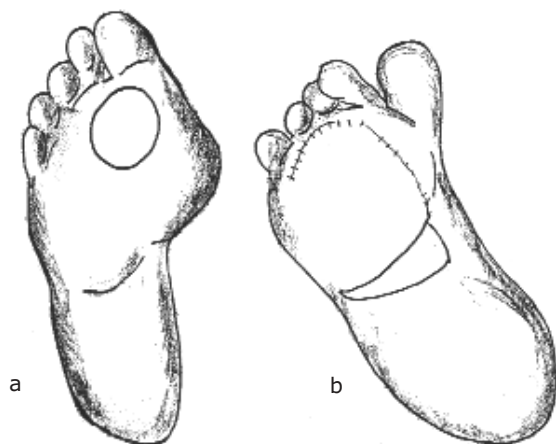
**Reversed medial plantar island flap for forefoot coverage**

A modification of the medial plantar flap is also described to cover the distal weight bearing area of the foot. The standard medial plantar flap described above derives its blood supply from the medial plantar artery, a terminal branch from the posterior tibial artery. The modified flap gets its blood supply from a reversed flow in the lateral plantar artery and vein. This flap is probably most useful after trauma and tumour resection, but occasionally the neuropathic foot might present a huge ulcer or unstable scar on the forefoot area where this flap might be used. Technically it is more complicated to raise the reversed flap than the standard flap, and the surgeon should be familiar with the latter before trying the more complicated reversed one. The operation will not be described in detail in this chapter, but interested readers might find out more about this flap described by Martin and co-workers.<sup>8</sup>

**Technique:** See discussion above regarding rotation flaps in the foot. A laterally based flap starting just posterior to the ulcer is cut down to fascia and sutured. Two weeks later the ulcer with surrounding scar is excised, the flap is raised in a plane just superficial to fascia. The flap is then rotated into position and sutured. The defect on the non weight-bearing instep is skin grafted. Post-operative care is as for the medial plantar artery flap.<sup>3</sup>

**Summary**

In the neurologically impaired foot pressure ulcers are common. Pressure point reduction must always be addressed. Most ulcers, perhaps with the exception of huge heel ulcers, will heal by secondary intention if treated conservatively in the right manner. However, conservative treatment can be very time consuming and might sometimes leave unstable scars. For those with recurrent ulcers, the time taken off work to heal these ulcers can be economi-



**FIGURE 16-11** Lateterally based fascio-cutaneous flap. **a.** large medial forefoot ulcer **b.** Flap raised and sutured into defect with skin graft to donor area.

cally debilitating. Skin grafting and flap coverage can be rewarding in selected cases. Follow up with proper footwear is of uttermost importance.

Soft tissue coverage can only occur when all signs of infection have resolved and the foot has an adequate blood supply.

## REFERENCES

1. Attinger C E: Use of Soft Tissue Techniques for Salvage of the Diabetic Foot. pp 323-366. Kominsky. Medical and surgical management of the diabetic foot. St Louis: Mosby Year Book, 1994
2. Colen LB, Repogle SL, Mathes SJ: The V-Y plantar flap for reconstruction of the forefoot, *Plast reconstr Surg* 81:220, 1988
3. Curtin JW: Transposition and Rotation Skin Flaps of the Sole of the Foot. pp 1815-1819. In Grabb's Encyclopaedia of Flaps, Volume three, second edition. Lippincott-Raven, 1998
4. Emmet AJJ: The filleted toe flap. *Br J Plast Surg* 29:19, 1976
5. Gravem PE: Heel ulcer in leprosy treated with fasciocutaneous island flap from the instep of the sole. *Scand J Plast Reconstr Hand Surg* 25: 155-60, 1991
6. Harrison DH, Morgan BDG: The instep island flap to resurface plantar defects. *Br J Plast Surg* 34: 315, 1981
7. Lennox WM: Surgical treatment of chronic deformities of the aneathetic foot. pp 350-373. In McDowell F and Enna CD (eds): *Surgical Rehabilitation in Leprosy*. The Williams & Wilkins Company, Baltimore, 1974
8. Martin, D. Gorowitz, B. Peres, J.M. and Baudet, J: Medial plantar artery flap. pp 1848-1850. Grabb's Encyclopaedia of Flaps, Volume three, second edition. Lippincott-Raven, 1998

## Foot Orthotic Therapy

• H. CROSS

*“There is hope of saving the feet of leprosy patients only when it is widely recognised that the whole problem is really one of mechanics, not of medicine. The advice and help of the physiotherapist, the social worker and the shoe maker are likely to be of more significance than the medicine of the physician or the knife of the surgeon.” (Brand, 1989)<sup>4</sup>*

### INTRODUCTION

Many of the principles underlying footwear design for anaesthetic feet have remained essentially unchanged since the early 1960s when pioneers such as Bauman, Brand, Price and Ross began to accentuate the importance of footwear provision.<sup>1,4,22,24,27,28</sup> With utmost respect to those who have contributed so much to our current understanding of foot pathology, this chapter is offered as a further contribution. The chapter does not, however, provide the definitive answers. The early pioneers used physics to explain why people affected by leprosy developed ulcers. It may be that in the twenty-first century, physics will not be enough. We will need to find psychosocial answers to explain why people affected by leprosy are still developing ulcers. Footwear affordability with client acceptability and compliance have perhaps become the most important factors to consider if the challenge of plantar ulceration is to be met. Any attempt to provide appropriate footwear and appliances will be confounded if these crucial issues are not respected.

### PHYSICS AND FUNCTION

Price recommended that all feet compromised by scarring should be fitted with a rigid soled sandal with a soft insole.<sup>24</sup> He designed a wooden sandal with a soft insole to meet these criteria and suggested that:

*“The rigid sole forestalls deep damage between soft tissues and the bony skeleton of the plantar region. The soft insole forestalls damage caused by friction between the skin surface and the immediate points of contact.”*

Price's assumption that soft material would forestall damage due to friction was at best only partially correct. The effect of cushioning is to reduce force by decreasing the acceleration quotient of the “mass x acceleration” equation describing force. The suggestion that the “rigid sole forestalls deep damage between soft tissues and the bony skeleton of the plantar region” finds some support because the rigid sole he designed incorporated a rocker effect beneath the metatarsal heads.

Translational friction is an essential component of grip and is proportional to the product of the normal force and a coefficient of friction dependent on the properties of two involved surfaces. It may be described as a force acting to prevent relative sliding between two contacting surfaces. Friction acts to stop the moving foot and as such it is essential if man is to walk. If the internal momentum between bone and soft tissue continues to excess however, shearing stress and tissue fatigue can be a result.<sup>25</sup>

Many have sought to address the problem of shearing stress by immobilising the foot



using rigid soled footwear. Although the concept of immobilisation to prevent shearing stress appears sound, it can bear a high functional cost.

Dorsiflexion of the toes stabilises the forefoot and thereby facilitates effective ankle plantarflexion at propulsion. When the toes dorsiflex the skin is drawn distally to permit unimpaired motion. This action results in horizontal shear between skin and metatarsal heads which is greatly exacerbated by the posterior thrusting of the skeleton to achieve acceleration for locomotion. It was reasoned, therefore, that by preventing toe dorsiflexion shearing stress in the tissues between the metatarsal heads and the skin would be reduced.

The anatomy of the normal footpad, however, is structured to accommodate shear.<sup>5</sup> Further mechanisms permit an element of sliding between soft tissue structures and bones, these include bursae and synovium encapsulated joints. It is only if the integrity of these structures is challenged by excessive demand that they will demonstrate fatigue. Alternatively if the structures have been damaged and scarring has resulted in the adhesion of skin and fascia, the functional capacity of these features may be markedly reduced. By eliminating the requirement to dorsiflex the toes, therefore, there will be a reduction in stress in the tissues beneath the metatarsal heads. Although eliminating these sagittal movements may be advantageous, the potential problems associated with uncontrolled frontal and transverse plane movements should also be considered

## FOOTWEAR

### **Rocker Shoes**

Bauman et al. conducted a comprehensive study of rocker shoes for leprosy patients.<sup>1</sup> Their study focused on kinetic effects and assumed that changes in pressure distribution

would alter a predisposition for the foot to ulcerate. On the basis of their findings they suggested that the angle of rocker, the antero-posterior position of the rocker axis and the orientation of the rocker axis with the shoe were key criteria. What arises from reviewing the literature however, is that there is no consensus relating to rocker shoes on these criteria.<sup>21,30,31</sup>

A reduction in pressure under the medial and central metatarsal heads (MTHs) with a rocker positioned behind the MTHs was a recurrent finding.<sup>6,7,21,30,31</sup> However, a comparable reduction in pressure on the lateral forefoot has not been reported. Some investigators have recorded an increase in pressure under the fifth MTH.<sup>30</sup> The elevated pressure, or insignificant reductions in pressure on the fifth MTH, were probably due to rockers being positioned nearer the fifth MTH which lies in a proximal position relative to other MTHs (author's opinion).

Pollard et al. were able to report that an effect of rocker bottom shoes is the reduction of shearing stress.<sup>23</sup> Significant reductions in longitudinal shear were demonstrated when a shoe, incorporating a "deep rocker" behind the MTHs was compared with other types of footwear. Increased heel loading and force impulse, the product of force and the duration of the application of force, are widely reported. Such findings suggest that rockers are contraindicated for individuals with a history of heel ulcers.

The height of the rocker is a critical factor. If the anterior edge of the rigid shoe makes ground contact at propulsion there will be considerable force applied to the forefoot. This effect is the result of an alteration in the order of leverage with the distal displacement of the axis of motion. However, a greater risk may prevail for the midfoot due to the loss of toe dorsiflexion. If the distal edge of the footwear does make ground contact, the lever arm that normally extends to dorsiflex the toes at the

MPJs is extended to demand dorsiflexion at the ankle which, during propulsion, is being used to apply a plantarflexion thrust. The effect of the opposing forces of dorsiflexion and plantarflexion is that propulsive plantarflexion is jammed. A large dorsiflexion moment is created around the ankle. As the ankle reaches the limit of its range of motion, force is translated forward into the subtalar and midtarsal joints. The talar navicular articulation will present the first occasion of least resistance and excessive opposing forces may cause the dorsal edges of the opposing bones to impinge on each other thereby potentiating trauma. This may be a significant consideration for neurologically impaired feet, vulnerable to neuropathic bone disorganisation.

Further rationale for the use of rocker shoes was that the rigidity and alternative geometry of the shoe would alter gait to the benefit of the injured foot. Schaff and Cavanagh demonstrated this effect by recording that all subjects wearing rocker shoes in their study took shorter steps (reduced by 8 cm) and increased rate of cadence by six steps a minute.<sup>30</sup> Zhu et al. reported findings that support Brand's hypothesis that a shuffling gait would reduce peak pressure.<sup>33</sup> They later presented evidence to indicate that an increased cadence was associated with increases in peak pressure.<sup>34</sup>

There can be little doubt that rocker shoes may significantly improve the prospects for foot salvage. The cost of producing and supplying effective rocker shoes, however, is prohibitive. Furthermore, in India distinctive footwear is a major stigmatising agent and patients are understandably unwilling to pay for footwear meeting such low patient acceptance.

## SANDAL DESIGN

Enna presented a sandal designed for leprosy impaired patients in America.<sup>10</sup> He sought to

produce a sandal incorporating a moulded polyethylene insole, supported by a mixture of sawdust and latex on a neoprene crepe sole. This approach could be useful for patients with an a-propulsive gait, but it may be contra-indicated for more normally functioning feet. The foot is a dynamic structure, it shortens and lengthens during the normal stance phase of the gait cycle. Unless the foot is immobilised with a rigid sole incorporating a rocker, a close fitting moulded innersole could be counterproductive. Enna's choice of expanded polyethylene is not appropriate unless resources permit frequent change because the material compresses within a relatively short period.

Patil et al. also based their recommendations on static studies.<sup>22</sup> However, their recommendations were that microcellular rubber, of varying degree shore, should be used as components to form a composite sandal insole. Their recommendations are based on findings relating to one atypical subject and whilst demonstrating the requirement to address individual needs their recommendations may not be applicable for the general population of leprosy sufferers.

Attempting to address the problem of stigmatising footwear, Antia designed an extruded plastic sandal which was similar in appearance to sandals obtainable in local markets throughout India. This sandal incorporated an upper to hide moderate deformities, a heel counter and a steel shank beneath an 8mm, 18 shore EVA sponge. These sandals were evaluated by Kulkarni et al. who used Harris mats to demonstrate reduced loading.<sup>18</sup> They also reported problems associated with the dorsum of the foot where the plastic had caused cuts. There were further problems with the fittings on the shoe (buckles snapped off).

The rationale for introducing a steel shank is to limit dorsiflexion at the metatarsophalangeal joints (MPJs). The potential for damaging effects on the midfoot if toe dorsiflexion is

prevented is presented above (see Physics and Function).

### **THE FOOT ORTHOSIS AS AN APPROACH TO MECHANICAL MALFUNCTION AND ITS EFFECTS**

The general aim of a foot orthosis is that it should intervene to attenuate the punishing consequences of abnormal foot structure or function. More specific aims will depend on the nature of the underlying problem. The action of some orthoses will be to perform as a substitute for anatomical inadequacy whilst others will aim to alter kinematic function or the effects thereof. More specific aims include:

1. The correction of phasic joint kinematics by controlling the extent of subtalar pronation.
2. The redirection and redistribution of force.
3. The accommodation of foot structure to facilitate optimum foot function.
4. The attenuation of effects of uncontrolled subtalar pronation.
5. The distribution of weight over an increased area of the foot.
6. The support and palliation of vulnerable areas of the foot
7. The deflection of pressure from a vulnerable area.
8. Cushioning to reduce impact.

Investigators have studied a variety of variables considered to be affected by foot orthoses. Landorf and Keenan have presented a comprehensive literature review of recent studies which the author recommends.<sup>13</sup>

#### ***The Functional Orthosis***

The term “functional” when used in this context usually refers to an orthotic device that restricts subtalar pronation. The aim of a functional orthosis is to improve the prospects for

the foot to achieve the desirable objective of reaching mid stance with the subtalar joint approximately neutral (i.e. neither pronated nor supinated). If this objective is reached it is reasoned that the foot will be ideally prepared, kinematically, for the demands of the propulsive phase of stance.<sup>17</sup>

An appropriately angled wedge beneath the heel effectively brings the supporting surface into contact with the inverted position of the calcaneus at heel strike. The angle of the wedge is calculated by measuring the angle between the supporting surface and the calcaneus when the subtalar joint is in its neutral position.<sup>3</sup> A response to this approach is that the subtalar joint will pronate but not to excess. The angle of the wedge may be increased to accommodate ligamentous laxity which would exacerbate the tendency of the subtalar joint to pronate.<sup>26</sup>

Orthoses that do restrict or attenuate the effects of subtalar pronation are likely to affect the subsequent function of the foot. Such devices are, therefore, “functional” in their action. A term commonly used for orthoses that are not prescribed principally to alter foot function is “accommodative”. The term has passive connotations and does not project the potential for such devices which can in fact initiate dynamic effects.

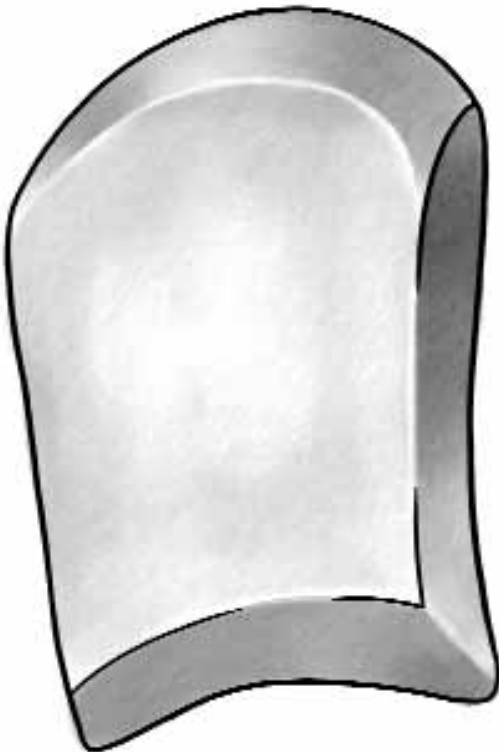
Individuality dictates that orthoses require consideration of peculiar specifications. Orthoses are prescribed on consideration of a combination of criteria. The prescription will be based primarily on a subject’s foot structure and gait. Other physiological considerations will be arterial supply, venous return and neurological status. An assessment of intellect and psychosocial factors is also required. There are basic components that can be incorporated in the manufacture of an orthosis. These are commonly used in combinations, however, each component is specific and may be applied in isolation, where appropriate. The efficacy of

foot appliances as an adjunct to the treatment of plantar ulceration in leprosy has been investigated.<sup>8,9</sup>

*Note: All foot orthoses described in this chapter are ideally constructed using micro cellular rubber (MCR) but can be made using other materials including ethyl vinyl acetate (EVA) or Poron.*

### The Tarsal Platform

The tarsal platform is designed to extend from the anterior edge of the heel to a line immediately proximal to the metatarsal formula (the arc in which an individual's metatarsal heads lie in the transverse plane) where the full thickness of the material (4 to 5 mm) is bevelled to accommodate the metatarsal heads (Fig. 17-1).



**FIGURE 17-1** Tarsal Platform— **Action:** Reduce pressure and the duration of pressure applied to metatarsal heads; Loads metatarsal shafts; Counters STJ supinatory effects.

**Indications:** pressure lesions affecting a rigid functioning foot (as with STJ supination).

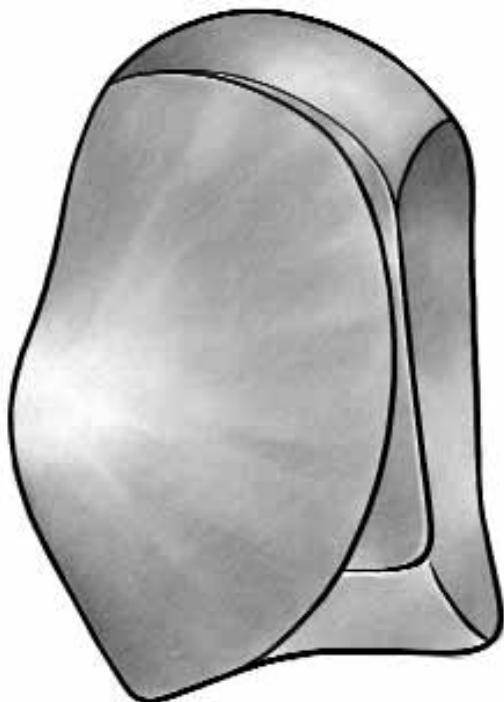
The posterior edge is shaped to the heel and bevelled to a width of approximately 1 cm. As a platform of firm material, it enlarges the weight bearing area of the foot and relieves the loading on the heel and metatarsal heads. Its primary function is to bring the lateral border of the foot into contact with the supporting surface. In so doing it imposes a slight evertory force on the foot. As a basic structure, it is indicated for pes cavus feet which exhibit excessive metatarsal loading and lateral instability but is contra indicated for feet with fixed varus abnormalities.<sup>32</sup> The author suggests that it should not be used where feet demonstrate grossly abnormal lateral loading (as in foot drop). The tarsal platform is the base for a number of modifications designed to meet individual requirements.

### The Tarsal Cradle

This is an extension of the tarsal platform to include a medial arch support with a flanged extension (Fig. 17-2). The structure is modelled to fill the concavity of the medial longitudinal arch thereby maintaining the architecture of the arch as it resists the effects of abnormal (late or excessive) subtalar pronation.<sup>29</sup> The author recommends that it should extend medially, as a flange, to cover the sustentaculum tali, the talar head and the tuberosity of the navicular. From its highest point, at the tuberosity of the navicular, it should slope inferiorly to the base of the first metatarsal head.

*Note: Whether an arch support is used as a component of a tarsal cradle or independently, the structure of the support is crucial to its function and acceptability.*

A well-designed tarsal cradle will support both the medial and lateral borders and present resistance to hypermobility of the foot. When the calcaneus everts it causes an axial rotation



**FIGURE 17-2** Tarsal cradle— **Action:** Redistributes forces; Stabilises the foot against the affects of STJ pronation; Augments first ray function.

**Indications:** Feet at risk of the affects of aphasic STJ pronation.

of the cuboid which destabilises the lateral column and consequently causes hypermobility of the fourth and fifth metatarsals.<sup>12</sup> The tarsal platform component supports the medial, plantar and posterior process of the cuboid which underlaps the calcaneus. This support adds resistance to calcaneal eversion and in so doing enhances the stability of the lateral column.<sup>20</sup> In a similar fashion, support beneath the tuberosity of the navicular and sustentaculum tali should resist the adduction and plantarflexion of the talus and the eversion of the calcaneus respectively. These effects should contribute to the stability of the medial column and the foot in general.

The salient objective of the tarsal cradle is to facilitate efficient functioning of the first ray.

Assuming normal phasic activity, as the STJ starts to supinate (after heel strike), the tarsus inverts and the second metatarsal follows to assume an inversion tilt. Responding to ground reaction force the lateral metatarsals will dorsiflex to the extent allowed by individual tarsometatarsal connections. This is usually sufficient to allow the metatarsal heads to lie in a common transverse plane.<sup>12</sup>

As the lateral metatarsals dorsiflex in response to ground reaction, the medial side of the foot remains tilted in inversion. To attain a plantigrade attitude and stabilise the foot for propulsion the first ray must plantarflex. The first ray has a triplane axis. As the first ray plantarflexes therefore, it also everts. The torsional twist around the second metatarsal head contributes to a tightening of the support structures of the medial arch.<sup>19</sup> The medial arch is simultaneously heightened by the plantarflexion of the first ray and extension of the digits.<sup>15</sup> Whereas the dorsiflexion of the lateral rays is principally a passive response to ground reaction, the plantarflexion of the first ray is dynamic. Efficient first ray function is dependent on a number of structural and functional variables.<sup>26</sup>

If the STJ is supinated the first cuneiform and the base of the first metatarsal are elevated relative to the cuboid. Using the stabilised cuboid as a pulley, the plantar direction force of peroneus longus is enhanced by the increased angle of approach to its insertion. This mechanical advantage allows peroneus longus to stabilise the first ray at its base. Its function is also to synergise with the actions of abductor hallucis and flexor hallucis to bring the ray into plantarflexion. In so doing maximal benefit is achieved from compressional forces to stabilise the medial kinematic chain in preparation for propulsion.<sup>12,26</sup>

If the medial column is destabilised due to subtalar pronation the first ray will dorsiflex in response to ground reaction. As a consequence



the angle of approach of peroneus longus will be reduced. Having lost mechanical advantage peroneus longus will be unable to effect adequate plantarflexion of the ray and the integrity of this crucial mechanism is compromised. The second or third metatarsal heads are exposed to excessive compressional and shearing stress.<sup>26</sup>

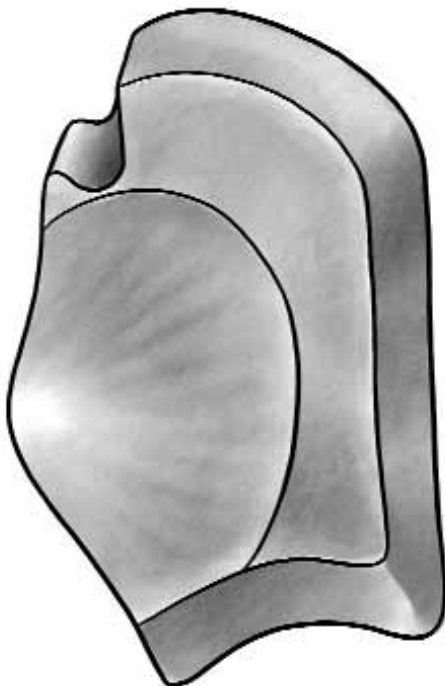
Facilitating first ray function is a fundamental aim if forefoot integrity is to be maintained.<sup>15</sup> By supporting the structures that maintain the optimal height of the arch it is reasoned that the dynamic features of first ray function will be augmented. This may be the most important function of the tarsal cradle.

The author suggests that if the tarsal cradle is extended medially and posteriorly to include a partial heel meniscus this will benefit the

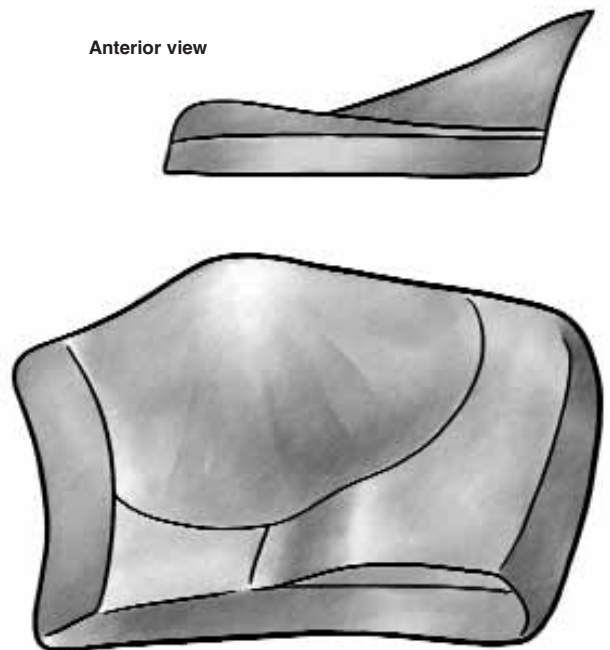
objective of subtalar pronation control. By including a medial wedge a supinatory moment will oppose the pronatory moment around the subtalar axis (Fig. 17-4). This effect will inhibit, if not prevent, the eversion of the calcaneus.<sup>11,17</sup> Other modifications can be made to address individual specifications.

### Anti Pronatory Orthosis

Whereas the tarsal cradle can be useful as a therapeutic appliance (i.e. used where there is frank ulceration or other trauma) an anti pronatory orthosis can be prescribed as a prophylactic appliance. The appliance described here is known by various different names some of the more colourful of which reflect its shape (eg. Cobra pad, Hathi pad). The appliance comprises a combination of a medial arch sup-



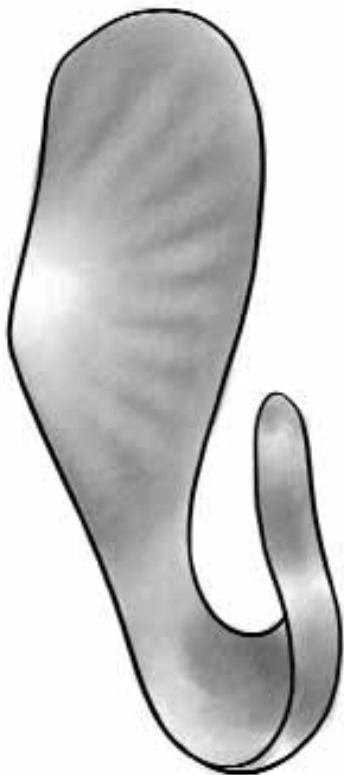**FIGURE 17-3** Combination Tarsal cradle with PMP- **Action:** Stabilises the foot against the affects of STJ pronation; Deflects pressure from an injured metatarsal head; Loads metatarsal shafts and unaffected metatarsal heads.  
**Indications:** Lesions affecting a hypermobile foot (as with STJ pronation)



**FIGURE 17-4** Combination Tarsal Cradle and Medial Wedge- **Action:** Accommodates forefoot valgus deformity; Stabilises the foot against the affects of STJ pronation.  
**Indications:** Forefoot Valgus.

port with a heel meniscus (Fig. 17-5). The heel meniscus is designed such that the medial aspect has a wedge effect to limit the extent of calcaneal eversion. The lateral aspect (which extends to the styloid process of the fifth metatarsal) increases the weight bearing area of the heel and contributes to the stability of the foot.

As a general principle, where it is found that patients present with aphasic pronation an anti pronatory appliance should be offered to promote optimal foot function and thereby reduce the risk of insidious trauma. It should also be considered as a post Tibialis Posterior Transfer intervention. Electromyographic stud-



**FIGURE 17-5** Anti-pronatory appliance— **Action:** Resists the eversion of the calcaneus; Stabilises the foot against the affects of pronation; Enhances first ray function.

**Indications:** Feet demonstrating excessive STJ pronation.

ies have demonstrated that tibialis posterior fires at heel strike.<sup>26</sup> The timing of activity and insertions of the tendon suggest that principle actions of the muscle are to prevent excessive STJ pronation and to restrain the foot against the effects of pronatory force. The removal of the tendon from its insertion therefore leaves the foot without this crucial protective mechanism. An antipronatory appliance as described here will compensate, to some extent, for the loss of normal tibialis posterior action.

**Note:** Whilst TPT surgery should be conducted to address the gross insult of foot drop (a sagittal plane problem) the effect of muscle transfer on frontal plane action should not be ignored. Although less likely to lead to acute trauma the affects of hyper pronation after TPT surgery are an insidious threat to the integrity of the foot. Soft tissues are challenged but there may also be a significant threat to joints. If the STJ is pronated at the propulsive phase of gait the tarsal joints will be more vulnerable to trauma because the articulating surfaces of opposing bones will not be congruent. Loss of joint congruency favours rotational forces rather than stability. Rotational forces destabilise the joints and increase the risk of fracture. Furthermore loss of congruency can lead to foci of force being applied to small areas of an articulating surface which can cause joint destruction (as in osteochondritis dissecans).

### The Metatarsal Rocker

The metatarsal rocker is shaped to conform to the metatarsal formula and is situated immediately proximal to the metatarsal heads.<sup>20</sup> The author suggests that if a foot has been damaged such that the osseous structures of the forefoot no longer conform to normality, a metatarsal rocker can be shaped to correspond with the tread line of the foot. With such a foot the rocker is positioned immediately proximal to the tread line. The bar can be incorporated

onto a tarsal platform or a tarsal cradle (Fig. 17-6). It can also be used independently of other options.

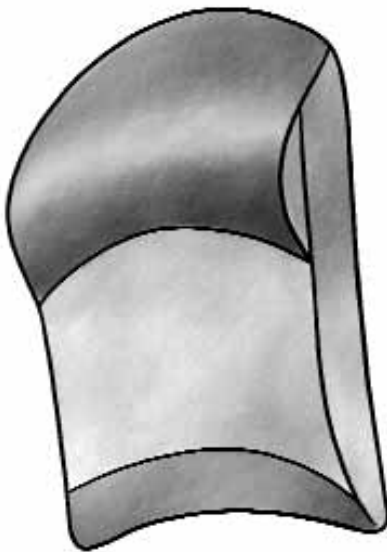
The author suggests that the action of the metatarsal rocker is that it should shift the tread line posteriorly, away from a vulnerable or traumatised area, to a less vulnerable area of the foot. In so doing it will mimic the pivotal role of the metatarsal heads. It must, therefore, be constructed to an optimal height to allow clearance of the vulnerable area. These devices may be particularly useful for feet that no longer demonstrate a normal heel toe gait.

### The Plantar Metatarsal Pad

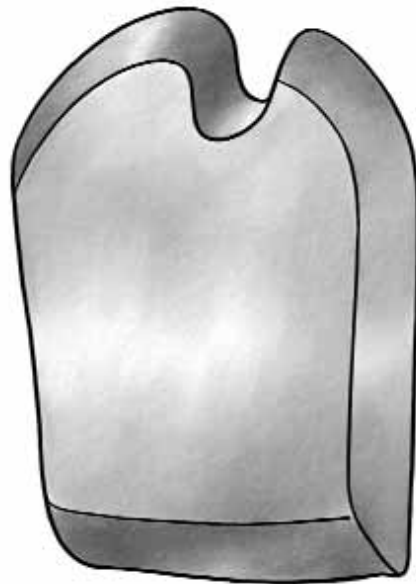
The full thickness of a plantar metatarsal pad (PMP) extends from beneath the heads of the three central metatarsals to two thirds of the length of the metatarsal shafts (Fig. 17-7). The anterior edge conforms to the metatarsal formula. It is bevelled from the metatarsal heads

to extend beneath the anterior plantar fat pad, to a distance immediately proximal to the webbing of the toes. The lateral and medial edges are also bevelled from the area beneath the second and fourth metatarsals to the medial and lateral aspects of the forefoot respectively. A 1 cm bevel extends from the posterior limit of the full thickness of the pad. The effect is, that on weight bearing, the central metatarsals are elevated. The load on the metatarsal heads is relieved due to the combination of elevation and an increased area of weight bearing.<sup>2</sup>

Where feet are compromised by the chronic fixation, dislocation or subluxation of the metatarsophalangeal joints, the PMP is applied to palliate the metatarsal heads by redistributing the load. Where a foot presents with mobile claw toes or retracted toes the metatarsals are forcibly plantarflexed.<sup>26</sup> In the action of elevating the metatarsals, the PMP assists by correcting the alignment of the metatarsal heads.



**FIGURE 17-6** Combination Tarsal Platform and Metatarsal Rocker– **Action:** Deflects pressure from affected metatarsal heads; Shifts the treadline away from the metatarsal heads.  
**Indications:** Multiple lesions distributed over the forefoot.



**FIGURE 17-7** Plantar Metatarsal Pad (PMP)– **Action:** Deflects pressure from affected metatarsal head; Loads metatarsal shafts and unaffected metatarsal heads.  
**Indications:** Pressure lesions affecting a rigid functioning foot (as with STJ supination).

The PMP can be modified to palliate the first of fifth metatarsal head or any other metatarsal head in isolation. The width of the PMP is extended so that the full thickness of the PMP supports the first and fifth metatarsals. An appropriate shape, conforming to the metatarsal head, is cut from the PMP and bevelled to allow the metatarsal head to be accommodated in the cut away area. The effect of a "U" or "wing" shaped section cut away from the PMP is that pressure is deflected from the vulnerable metatarsal head to the PMP and other metatarsal heads.<sup>2</sup>

**Note:** *If the foot is affected by aphasic subtalar pronation a PMP should not be used unless it is incorporated as an extension of a tarsal cradle (Fig. 17-3). The reason is that when the STJ pronates, the foot becomes hypermobile and demonstrates a tendency to spread and elongate as it bears weight. The instability of the foot with associated mobility of the plantar surface can result in a traumatised plantar site being forced repeatedly over the bevelled edges of the PMP. The resulting shearing stress can exacerbate the trauma.*

### Moulded Insoles

These appliances should be used with care. They are best prescribed for patients with gross rigid deformities or those for whom surgical correction has resulted in multiple joint fixation. The function of a moulded insole is to maximise the weight-bearing surface and thereby reduce the risk of high pressure lesions at vulnerable prominences. The manufacture of a moulded insole is based on a static impression. They are suitable therefore for people who present with feet that only function as a supportive prop and are not expected to facilitate the more dynamic functions of the normal foot.

**Note:** *Moulds should always be taken with the patient fully weight bearing so that a valid impression of the foot's surface can be recorded.*

The method of manufacture limits the usefulness of the moulded insole. Moulds are made from a static impression but it must be considered that the foot may not be static on weight bearing. Before any appliance is made to accommodate the shape of the foot, therefore, it should be ascertained whether the foot is mobile during stance. It is not sufficient to determine only whether the foot can dorsiflex and plantarflex. It must also be ascertained to what extent the foot responds to frontal plane demands. If the foot everts on weight bearing the foot could be at risk in a moulded insole.

The entire plantar aspect will shift laterally and distally thereby potentially placing vulnerable sites out of the areas moulded for their protection.

### CONCLUSION

Mechanical problems require mechanical solutions. The more that can be understood about the underlying mechanisms that lead to tissue breakdown, the more we will be able to address the cause. However, man is not merely a machine. Function relates, in the first instance, to managing the challenge to the intellect and emotions of social and economic realities. There is a hierarchy for preservation against physical realities: hunger, shelter and security head that hierarchy. While poverty persists our efforts to save the feet of people will, therefore, depend on pragmatic solutions. Foot orthoses will not solve all problems. They will at best be an adjunct to treatment, but the therapies suggested here follow a simple and pragmatic methodology that is known to help.

### GLOSSARY OF TERMS RELATING TO ORTHOTIC THERAPY

**KINETICS:** The study of forces that cause motion

**MASS:** The quantity of matter in an object. i.e.:  
The number of atoms that make up an object will remain the same no matter if that object is affected by gravity or not.

**CENTRE OF GRAVITY:** This is an imagined point in an object around which all other parts of the object exactly balance each other so that, if this point is supported, the object will remain at rest. In the body, its location will vary according to the position of body segments. For most practical purposes the location of the CENTRE OF GRAVITY has the same location as the CENTRE OF MASS.

**CENTRE OF MASS:** An imagined point in an object that moves in the same direction as any particle would move if it was responding to the same forces.

**GROUND REACTION FORCE:** The force that acts on a body as a result of the body's contact with the ground.

**SI UNITS:** (System International Units) A system where mass is measured in Kilograms Length is measured in meters Time is measured in seconds.

**NEWTON:** 1 Newton is the force that will give a mass of 1kg. an acceleration of 1 meter per second/per second.

**WEIGHT:** Force due to the gravitational pull of the earth. Without gravity we would have mass but no weight.

**GRAVITY:** An attraction between objects. On the Earth's surface all objects are pulled toward the earth so that they have an acceleration of 9.81 m/s.

**ACCELERATION:** A change in velocity

$$\frac{\text{Velocity 1} - \text{Velocity 2}}{\text{Time}}$$

**FORCE:** Mass x Acceleration

**PRESSURE:** Force / Area

**LOAD:** To apply force

**COMPRESSION:** When an object is loaded by collinear forces acting on it from opposite directions to push it together.

**TENSION:** When an object is loaded by collinear forces which act in an opposite direction to pull the object apart.

**SHEAR:** When an object is loaded by forces which act on it in opposite but parallel directions.

**FRICTION:** Friction is the property that objects have which makes them resist being moved across one another. If two objects with flat surfaces are placed one on top of the other, the top object can be lifted without any resistance except that of gravity. But if one object is pushed or pulled along the surface of the other, there is a resistance caused by friction.

**STRESS:** Force that develops in an object in response to externally applied loads. Stress may be tensile if the object is subjected to tension, compressive if the object is subjected to compression or shearing if the object is subjected to shear. Normal stress changes the length of a structure. Shear stress changes the angle of a structure.

**FATIGUE:** The failure of tissue or other material due to loading.

## REFERENCES

1. Bauman JH, Girling JP, Brand PW: Plantar pressures and trophic ulceration. J Bone Joint Surg 45-B: 652, 1963



2. Black JA: Orthoses. In Lorimer, D (Ed) Disorders of the Foot. Edinburgh: Churchill Livingstone. 2002
3. Blake R.L. and Ferguson H: The inverted orthotic technique: a practical discussion of an orthotic therapy. *J Brit Pod Med*; 48: 25-29, 1993
4. Brand P: Insensitive Feet, A Practical Handbook on Foot Problems in Leprosy. London: The Leprosy Mission, 1981
5. Bøsjen-Møller F, and Jorgensen U: The plantar soft tissues: Functional and clinical applications. In Jahhs, M.H: (Ed.) Disorders of the foot. Philadelphia: W.B Saunders and Co., 1982
6. Coleman WC: The relief of forefoot pressures using outer sole shoe modifications. In: Proceedings Int Conf Biomech Clin Kines Hand Foot. Madras: Indian Institute of Technology, 1985
7. Coleman WC: Shoe gear for the insensitive foot. *Clin Pod Med Surg* 4, 459-470, 1987
8. Cross H, Sane S, Dey A, and Kulkarni VN: The efficacy of podiatric orthoses as an adjunct to the treatment of plantar ulceration in leprosy. *Lepr Rev* 66:144-157, 1995
9. Cross H, Kulkarni VN, Dey A, Rendall G: Plantar ulceration in patients with leprosy. *J Wound Care* 5: 406-411, 1996
10. Enna SG, Brand PW, Reed JK, Welch D: The ortho-tic care of the denervated foot in Hansen's disease: a survey updated. *Orthot Prosth*, 30: 33-39, 1976
11. Ferguson H, Blake RL. Update and rationale for the inverted functional foot orthosis. *Clin Podiatr Med Surg* 11:311-37, 1994
12. Huson A: Functional Anatomy of the Foot. In: Disorders of the foot. Vol 1 ed. Jahhs M.H. W.B. Saunders and Co., Philadelphia, 1991
13. Landorf KB and Keenan A: Efficacy of foot orthoses: what does the literature tell us? *Austr J Pod Med* 32: 105-113, 1998
14. Kirby K: Effects of longitudinal Arch height on lateral ankle instability. Newsletter. R. Orthotic Laboratories, California, 1991
15. Kirby K: Plantarflexed first ray deformity. Newsletter. R. Orthotic Laboratories, California, 1991
16. Kirby K: Methods for determination of positional variations in the subtalar joint axis. *J Am Pod Med Ass* 77: 228-234, 1987
17. Kirby KA: The medial heel skive technique. Improving pronation control in foot orthoses. *J Am Podiatr Med Assoc* 82:177-88, 1992
18. Kulkarni VN, Antia NH, Mehta JA: Newer Designs in footwear for leprosy patients. *Ind J Lepr* 62:483-487, 1990
19. Mann RA: Overview of foot and ankle biomechanics. In M.H. Jahhs, Disorders of the foot. Vol 1. W.B. Saunders and Co., Philadelphia, 1991
20. Neale D, and Boyd PM: Structure and Function. In D. Neale, and I.M. Adams (Eds.): Common Foot Disorders Edinburgh: Churchill Livingstone, 1989
21. Nawoczinski DA, Birke JA, and Coleman WC: Effect of rocker sole design on plantar forefoot pressures. *J Am Pod Med Ass* 78: 455-460, 1988
22. Patil KM, Babu TS, Oommen PK, and Srinivasan H: Foot pressure measurements in leprosy and footwear design. *Ind J Lepr* 58: 357-366, 1986
23. Pollard JP, LeQuesne LP, and Tappin JW: Forces under the foot. *J Biom Eng* 5: 37-40, 1983
24. Price EW: Studies on plantar ulceration in leprosy. VI The management of plantar ulcers. *Lepr Rev* 31: 159-171, 1960
25. Rodgers MM and Cavanagh PR: Glossary of biomechanical terms, concepts and units. *Phys Ther* 64: 1886-1902, 1984
26. Root ML, Orien WP and Weed JH: Abnormal Function of the Foot. Clin Biom Vol.2. Clinical Biomechanics Corporation, Los Angeles, 1977
27. Ross WF: Aetiology and treatment of plantar ulcers. *Lepr Rev* 33:25-40, 1962
28. Ross WF: Footwear and the prevention of ulcers in leprosy. *Lepr Rev* 33:202-206, 1962
29. Ross JA: Sports medicine and injuries. In: Lorimer, D (Ed) Disorders of the Foot. Churchill Livingstone, Edinburgh, 2002
30. Schaff PS and Cavanagh PR: Shoes for the insensitive foot: The effect of a rocker bottom shoe modification on plantar pressure distribution. *Foot Ankle* 11: 129-140, 1990
31. Sims DS and Birke JA: Effect of rocker sole placement on plantar pressures. Proceedings 20th. Annual Meeting of the USPHS Professional Association, (Abstract) p. 53 Atlanta, 1985
32. Thomson CE, Campbell RH, Wood AR, Rendall GC: Adult foot disorders. In Lorimer, D (Ed) Disorders of the Foot. Churchill Livingstone, Edinburgh: 2002
33. Zhu H, Wertsch JJ, Harris GF, Loftsgaarden JD and Price MB: Foot pressure distribution during walking and shuffling. *Arch Phys Med Rehab* 72: 390-397, 1991
34. Zhu H, Harris GF, Alba HM, Wertsch JJ: Effect of walking cadence on plantar pressures. *Arch Phys Med Rehab* 76:1000-1005, 1995

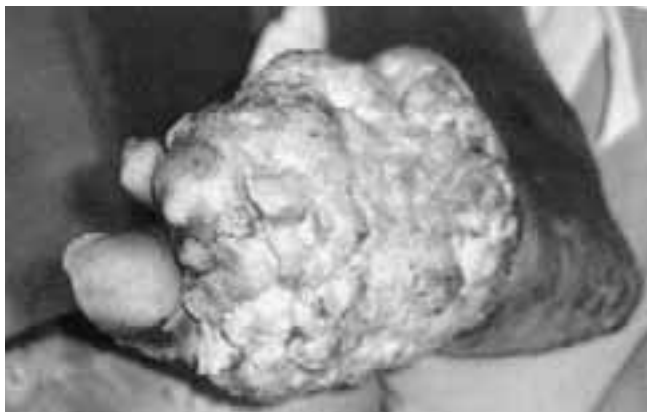## Squamous Cell Carcinoma and Amputations

• R. SCHWARZ

### SQUAMOUS CELL CARCINOMA

The incidence of squamous cell carcinoma in the foot is very high in patients affected with chronic plantar ulcers from leprosy.<sup>1,7,10-13</sup> Those with chronic ulcers due to other neuropathic diseases appear to have a much lower incidence given the paucity of reports in the literature. The development of carcinoma in leprosy patients is due to the prolonged ulceration to which these patients are subject, especially in those patients residing in developing countries who are unable to seek medical attention early. Richardus and Smith<sup>10</sup> found that patients with a malignant ulcer had a history of ulceration of 15 years duration. Interestingly matched controls with benign plantar ulcers had an average duration of ulceration of 26 years. The pathologic progression is similar to that seen in a Marjolin's ulcer, a squamous cell carcinoma arising in an old burn scar.<sup>6</sup> The chronic attempts at wound healing over many years gradually leads to metaplastic changes, which then progress to dysplasia and finally neoplasia. As in Marjolin's ulcer, squamous cell carcinoma usually arises after a history of an ulcer being present for many years or decades. These patients often present with large fungating tumours already involving bone (Fig. 18-1), but they may also present with flat benign appearing ulcers as well. Bobhate et al<sup>1</sup> found that plantar ulcers in the heel are more likely to undergo malignant transformation than those in the forefoot. Any suspicious ulcer or any ulcer that fails to heal with appropriate conservative management should be biopsied. It must be kept in mind that the pathologic diagnosis

of these lesions is difficult. In one study 41% of squamous cell carcinomas had a benign diagnosis on initial biopsy.<sup>8</sup> Some required up to four biopsies (the last biopsy including the foot!) to establish the diagnosis. In the same study review by four different pathologists showed considerable conflict in pathologic diagnoses, the most common benign diagnoses being corneum cutis and hyperkeratosis.



**FIGURE 18-1** Fungating squamous cell carcinoma of the foot, treated with excision and coverage with medial plantary artery flap.

Obviously the best management is prevention, emphasizing again the need of appropriate counselling and footwear in those with loss of sensation in the sole. When patients present with established carcinoma, one tries to preserve as much of the foot as possible while performing a curative resection of the cancer. A minimum of 1 cm clearance of the tumour at the margins is necessary, although for late stage tumours 3-5 cm is recommended due to the deep invasion that is sometimes present.

Surgical resection margins should be checked by the pathologist, and re-excision planned if the margins are involved. In relatively early cases it may be possible to perform a curative resection without an amputation. Some cases of the heel we have treated with wide excision and a medial plantar artery or cross-leg flap for reconstruction, with no recurrence for up to 5 years. However, at present we would not recommend a cross-leg flap due to the risk of seeding tumour to the other leg and the development of better, local flaps such as the medial plantar artery flap (see Chapter 16). Fritschi reports patients treated with excision and skin grafting with no recurrence for years.<sup>4</sup>

The majority of patients will require an amputation of some kind. If on one side of the forefoot, the half bearing the cancer is excised in a wedge and the other side is used to close the wound after removal of the metatarsals.<sup>4</sup> This will preserve some toes for the patient. I would recommend tendon Achilles lengthening after this procedure, which is essentially a Lisfranc's amputation. Other patients will require a Boyd's or Syme's amputation to achieve a curative resection (see below for technique).<sup>13</sup> Only in large tumours involving the heel will a below knee amputation be necessary. McDonald reports that 40% required a foot saving amputation and 52% required a below-knee amputation.<sup>8</sup> 8% were treated with local excision and flaps. No recurrences were reported.

Patients frequently present with popliteal, femoral and inguinal lymphadenopathy.<sup>1,12</sup> In most cases this is due to inflammatory lymphadenopathy. This can be diagnosed by fine-needle aspiration cytology, or the surgeon can wait until after excision of the tumour to see if the lymphadenopathy resolves. In those with proven metastatic disease in the groin, a block dissection of the femoral lymph nodes is carried out, although these patients have a poor prognosis.

## AMPUTATIONS

While all reasonable efforts to preserve a foot should be expended, some patients will present with a foot that is no longer salvageable. This may be due to destruction of the foot by infection, gross bony destruction by neuropathic bone disease or osteomyelitis, or massive plantar ulceration. Amputation does not mean failure but should be approached with the goal of preserving as much quality weight-bearing sole as possible. Especially for those patients living in remote areas, being able to walk without a special prosthesis is a great advantage. Amputations at various levels are described below. Other than the toe amputation all should be done under tourniquet control with pre-operative exsanguination, releasing the tourniquet prior to skin closure to check hemostasis. A single dose of pre-operative antibiotic, covering gram-positive organisms, should be given.

### Toe Amputation

Fish-mouth flaps are created on the dorsal and ventral surfaces preserving all fat, starting the incision at the level of intended bone section and making the plantar flap slightly longer than the dorsal flap. Tendons are divided as far proximally as possible. In the great toe the sesamoids are removed. Digital nerves are divided proximally and the vessels ligated and divided. If the amputation is through the level of the metatarsophalangeal joint the joint capsule must be resected but the articular cartilage can be left. Skin is closed in one layer.

### Ray Amputation

This is of benefit to preserve as much of the distal weight-bearing foot as possible. It is usually used on the first and fifth digits but can be used for multiple digits.

**Technique:** Fishmouth flaps are raised at the base of the digit and a longitudinal dorsolateral-

al incision is then extended to the base of the metatarsal. Part or all of the metatarsal is removed and the tendons are then divided proximally. Skin is closed in a single layer.

### Transmetatarsal Amputation

This is seldom indicated in leprosy but is more common in diabetes due to vascular insufficiency. A long plantar flap is raised just distal to the level of the metatarsophalangeal joints and with a dorsal flap extending just beyond the mid-metatarsal level. The flaps are slightly longer on the medial side because of the greater foot thickness here. The metatarsals are divided taking care to preserve at least the proximal quarter. Skin is closed in two layers with a drain left in that is removed in 48 hours.

At times the patient may present with advanced infection and destruction of the forefoot but preserved toes. Patients like their toes and if possible the surgeon should try to preserve them. In this situation the metacarpals can be excised as needed, the edges smoothed with a file, and any plantar ulcerations excised and closed. The dorsal wounds are left to close on their own and may be skin grafted after an appropriate time interval to speed healing.

No special footwear is needed.

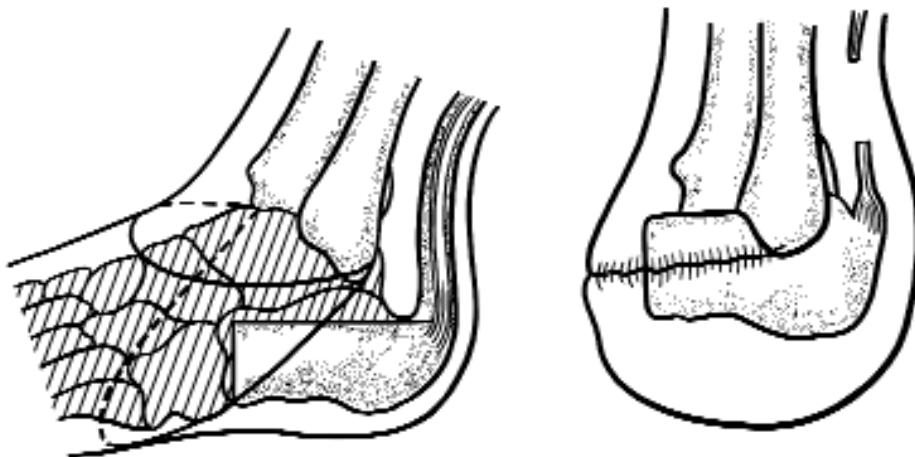
### Lisfranc's Amputation

This procedure is indicated in severe forefoot destruction. A fishmouth incision is made distal to the tarso-metatarsal joints and amputation is made through this level. The incision can be closed by either the plantar or dorsal skin flap, and if there is a shortage of skin due to infection the wound can be left to close by secondary intention. The foot retains dorsi-flexion function, and no special footwear is needed. The patient may request a filler in the toe to fill out the shoe and prevent it from "flapping".<sup>16</sup>

### Boyd Amputation

This gives a more functional foot than a Pirigoff as the weight bearing area of bone is larger and the weight bearing skin is sole rather than the skin of the back of the heel. It is commonly used for squamous cell carcinoma of the forefoot.

**Technique:** Starting at a point just anterior and one cm inferior to the distal medial malleolus, a long flap is made on the sole just distal to the fifth metatarsal base, ending at a point at the tip of the lateral malleolus (Fig. 18-2).<sup>2</sup> The dorsal flap is made at the level of the talo-navicu-



**FIGURE 18-2** Boyd Amputation.

lar joint. The distal foot is removed through the midtarsal joints. The talus is removed according to the technique of Whitfield. In this the talus is grasped, pulled inferiorly and the ligaments superior to the talus are divided. Lateral ligaments are then divided, after which the inferior and finally the posterior attachments are divided. The calcaneus is divided just distal to the peroneal tubercle and the superior surface cut off transversely with an osteotome. The distal tibial articular surface is removed and the malleoli are trimmed on their inner surfaces to fit the calcaneus. Tendons and the medial and lateral plantar nerves are divided high. The calcaneus is then shifted slightly forward inserted into the mortise and fixed with a Steinman pin from the heel. Skin is closed in two layers with a drain in place that is removed in 48 hours. A plaster is placed and left for three months. The pin is removed at one month and weight bearing is commenced. The walking plaster is left until the arthrodesis is complete, usually by three months.

### Pirogoff Amputation<sup>9,16</sup>

While not as functional as the Boyd, it is possible to perform a Pirogoff amputation with a shorter ventral flap, allowing salvage of the foot in certain cases. Weight bearing occurs on the skin covering the back of the heel, similar to a Syme's amputation.

**Technique:** Starting at a point just anterior to the medial malleolus, the sole flap is cut at the level of the talo-navicular joint, ending 1 cm above the lateral malleolus (Fig. 18-3). The dorsal flap cut at the level of the talo-navicular joint. The distal foot is removed through the midtarsal joints and the talus removed as in the Boyd amputation. The ankle joint articular cartilage is removed as for the Boyd amputation. The calcaneus is cut at a right angle through the neck, or more proximally just anterior to the posterior tubercle. In this case the calcaneus is transected at an angle 30° to the long axis of the tibia, although this angle can be varied. The calcaneus is then rotated forward to oppose the anterior calcaneal surface to the ankle mortise and fixed in place with a Steinman pin. Skin is closed in two layers with a drain in place, which is removed at 48 hours. A plaster is applied. The pin is removed at one month. The plaster is removed at three months and weight bearing commenced.

### Syme's Amputation

A Syme's amputation is indicated if the sole skin is insufficient to preserve the calcaneus. It has the disadvantage of not entirely weight-bearing on sole skin. It requires a special prosthesis to walk a significant distance, but can be used for very short distances without a prosthesis such as to go to the toilet at night. It has

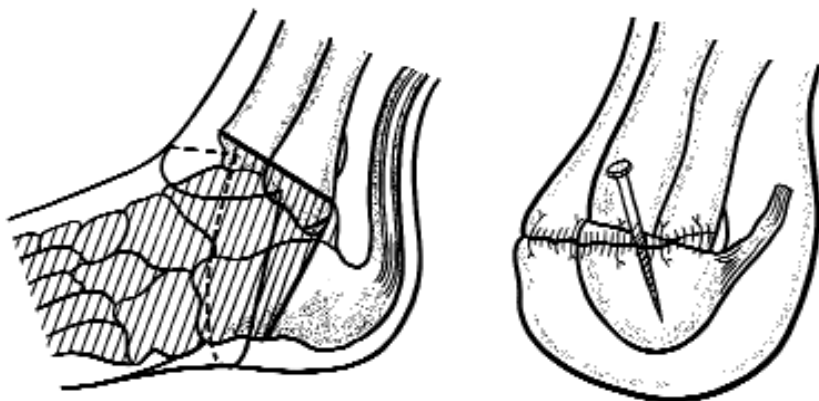
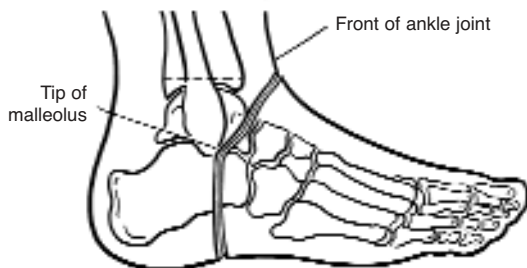


FIGURE 18-3 Pirogoff amputation.



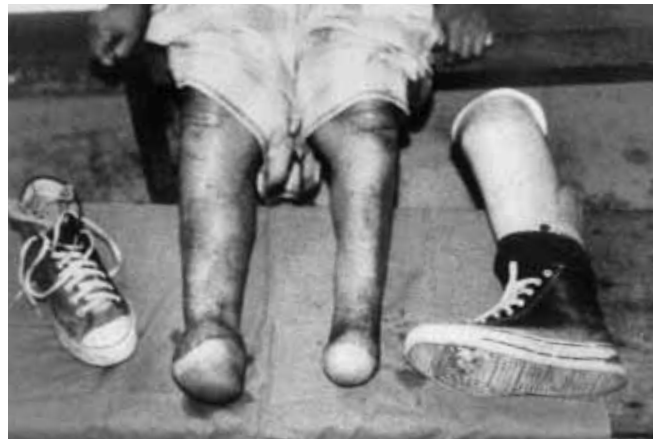a tendency to form a pseudobursa, making the weight-bearing skin pad very mobile. If this occurs it can be excised, but it has a tendency to re-form. Common causes of failure are flap necrosis due to overzealous trimming of the dog-ears and posterior migration of the heel pad.<sup>4</sup>

**Technique:** Starting 1 cm inferior to the medial malleolus, the plantar flap is made at the level of the mid-calcaneus, ending at the tip of the lateral malleolus (Fig. 18-4). The anterior flap is made at the level of the ankle joint. The medial and lateral ligamentous attachments of the ankle are divided starting with the blade in the joint space, taking care not to damage the vessels. A bone hook is placed in the talus to place it in extreme equinus after which the posterior ankle joint capsule and then the Achilles tendon are divided. The plantar flap is taken off the calcaneus in a sub-periosteal plane, being careful to preserve the blood supply to the flap. The foot is then removed through the ankle joint. Soft tissues are dissected off the distal tibia and fibula with the periosteal elevator. The periosteum is then divided sharply 6 mm above the joint line and the bone then divided at this level, perpendicular to the line of the tibia. All tendons and the medial and lateral plantar nerves are divided high and vessels are tied. The heel flap is brought forward to be sutured to the anterior flap ensuring that the suture line is anterior to the weight-bearing surface. Wagner has described a technique to



**FIGURE 18-4** Syme's amputation- skin flaps. (from Richardson<sup>9</sup>, used with permission)

prevent the posterior migration of the heel flap.<sup>8,15</sup> Holes are drilled through the anterior edge of the tibia and fibula and the fascia of the heel flap is then sutured to the bones through these holes. A drain is left and removed at 48 hours, and a bulky dressing applied. Weight bearing is commenced at one month with a prosthesis, or a prosthetic cast can be applied after the drain has been removed and early ambulation commenced. A patient with a left Syme's amputation and a right Pirigoff amputation is shown in Fig. 18-5.



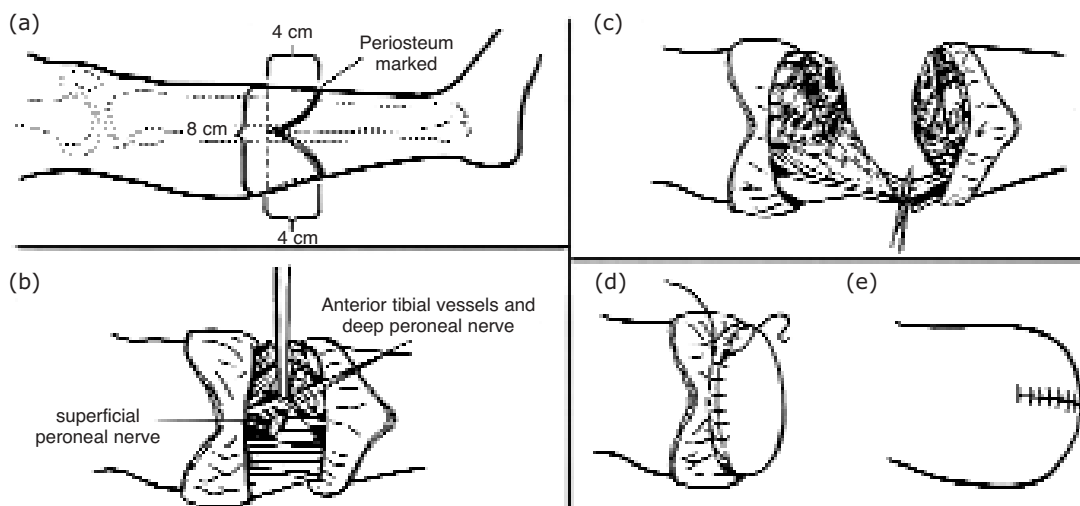
**FIGURE 18-5** Patient with a left Syme's amputation and a right Pirigoff amputation. The patient is able to ambulate with bare feet, but uses a patellar weight bearing prosthesis on the left when walking long distances.

### **Below-Knee Amputation**

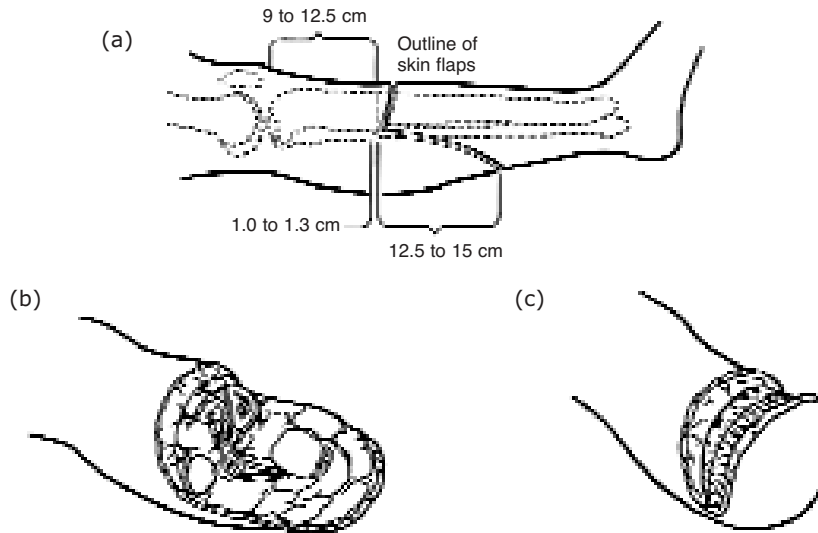
If the septic or other destructive process makes a more distal amputation impossible, the surgeon should carry out a below-knee amputation without unnecessary delay so that the rehabilitation process can start as soon as possible. For amputations for peripheral vascular disease there are many factors regarding the estimation of blood supply to the calf skin that can be used to predict flap survival and wound healing. The reader is referred to a surgical textbook for a full discussion of these issues.<sup>14</sup>

In amputations for neuropathy the blood supply is generally good and good wound healing can be expected in almost all cases. In those patients with an active septic process in the foot at the time of amputation, there is an increased likelihood of wound infection, especially if cellulitis is extending up the calf. In these cases one should consider a guillotine amputation at the level of the ankle as an initial procedure. The definitive procedure can then be carried out several days later after the infection has been controlled. Both the standard Burgess<sup>3</sup> amputation and the fishmouth amputation have been reported, but only the Burgess amputation is described in the following text. The fishmouth amputation is shown and briefly described in Figure 18-6. In non-ischaemic limbs tension myoplastic procedures are performed or even firmer stabilization with myodesis. These are contraindicated in the ischaemic limb as they may further compromise a tenuous blood supply. Preserving adequate length of the stump is important, as it has been shown that a short stump leads to

increased energy expenditure of ambulation.<sup>5</sup> **Technique:** A point is marked 12.5-17 cm below the joint line, or 10-12.5 cm in ischaemic limbs, depending on body height.<sup>14</sup> Points are then made at the mid-point of the calf on both medial and lateral sides 1 cm proximal to the first point and the points connected (Fig. 18-7). The width of the calf is then measured, and the length of the posterior flap is then marked at this length plus 1 cm. The anterior flap is 1 cm long. The anterior flap is then cut down to periosteum and the periosteum is then raised proximally. Muscles of the anterior compartment are divided. The anterior tibial vessels and peroneal nerve are divided and then ligated above the level of bone transection, first pulling on the nerve to allow them to retract well above the amputation levels. The tibia is cut 1 cm proximal to the tip of the anterior flap, beveling the anterior aspect and filing the edges smooth. After dividing muscles in the lateral compartment the fibula is divided 1 cm above the level of the tibial amputation. The posterior tibial vessels are then doubly tied and



**FIGURE 18-6** Below-knee amputation for non-ischemic limbs. **a.** Skin incisions creating equal anterior and posterior flaps, each one half of the anteroposterior diameter of the leg. **b.** Anterior tibial vessels divided. Tibial, deep and superficial peroneal nerves all divided and ligated high to avoid painful neuromas. **c.** Fashioning of long posterior myofascial flap. **d.** Posterior myofascial flap sutured to periosteum anteriorly. **e.** Skin closure (From Tooms<sup>14</sup>, used with permission).



**FIGURE 18-7** Burgess' below knee amputation **a.** Skin incisions. **b.** Distal leg removed and muscles bevelled. **c.** Posterior fascia sutured to periosteum and anterior fascia (Modified from Tooms<sup>14</sup>, used with permission).

divided. The posterior tibial nerve is divided high and allowed to retract. The posterior muscles are divided, leaving only gastrocnemius muscle mass attached to the posterior flap so that the stump will not be too bulky. An amputation knife is used to bevel this muscle mass. Gastrocnemius tendon is divided 1 cm proximal to the level of the skin flap, taking care not to separate the skin from the underlying muscle. The wound is well irrigated and hemostasis obtained after release of the tourniquet. A drain is left and removed at 48 hours. The posterior fascia is sutured with some tension to the anterior fascia. Skin is then closed with interrupted sutures and a padded bandage placed, ensuring that this does not compromise circulation to the stump. Stump bandaging is commenced at one week and continued until the stump is ready for prosthesis fitting. The stump will shrink over the first three to four months, after which permanent prosthesis fitting can be done. A temporary prosthesis can be fitted in the interim.

## References

1. Bobhate SK, Madankar ST, Parate SN, Chaudhary RK, Kumbhalkar DT: Malignant transformation of plantar ulcers in leprosy. *Ind J Lepr* 65:297-303, 1993
2. Boyd, HB: Amputation of the foot, with calcaneotibial arthrodesis. *J Bone Joint Surg* 21:997-1001, 1939
3. Burgess EM: Prevention and correction of fixed equinus deformity in mid-foot amputations. *Inter-Clin Bull* 6:20, 1966
4. Fritchi, EP: *Surgical Reconstruction and Rehabilitation in Leprosy*. The Leprosy Mission, New Delhi, 1984
5. Gonzales EG, Corcoran PJ, Reyes RI: Energy expenditure in below knee amputee: correlation with stump length. *Arch Phys Med Rehabil* 55:111, 1974
6. Konigova R, Rychterova : Marjolin's ulcer. *Acta Chir Plast* 42:91-4, 2000
7. Kumaravel S: Neoplastic transformation of chronic ulcers in leprosy patients--a retrospective study of 23 consecutive cases. *Ind J Lepr* 70:179-87, 1998
8. McDonald M: Squamous cell carcinoma in plantar ulcers. In *Book of Abstracts of the First Asian Leprosy Congress*, Agra, Nov, 2000

9. Richardson EG, Tooms RE: Amputations about the foot. pp 1973-1990. In Canale ST (ed) Campbell's Operative Orthopaedics, 9th ed. Mosby, St. Louis, 1998
10. Richardus JH, Smith TC: Squamous cell carcinoma in plantar ulcers in leprosy. A case control study. *Lepr Rev* 64:270-4, 1993
11. Richardus JH, Smith TC: Squamous cell carcinoma in chronic ulcers in leprosy: a review of 38 consecutive cases. *Lepr Rev* 62:381-8, 1991
12. Sane SB, Mehta JM: Malignant transformation in trophic ulcers in leprosy: a study of 12 cases. *Ind J Lepr* 60:93-99, 1988
13. Soares D, Kimula Y: Squamous cell carcinoma of the foot arising in chronic ulcers in leprosy patients. *Lepr Rev* 67:325-9, 1996
14. Tooms, ET: Amputations of the lower extremity. Pp532-541. In Canale ST (ed) Campbell's Operative Orthopaedics, 9th ed.. Mosby, St. Louis, 1998
15. Wagner FW Jr: Management of the diabetic-neurotrophic foot: Part II. A classification and treatment program for diabetic, neuropathic and dysvascular foot problems. In Cooper RR (ed): AAOS Instructional Course Lectures, vol 28. CV Mosby, St. Louis, 1979
16. Warren GW, Nade S: The Care of Neuropathic Limbs. Parthenon Publishing Group, 1999

### **Other Reading**

1. Pinzur MS, Kaminsky M, Sage R, Cronin R, Osterman H: Amputations at the middle level of the foot: A retrospective review. *J Bone Joint Surg* 68A: 1061-70, 1986
2. Sage R, Pinzur MS, Cronin R, Preuss HF, Osterman H: Complications following mid-foot amputation in neuropathic and dysvascular feet. *J Am Pod Med Ass* 79:277-81, 1989

## Surgery of Facial Palsy in Leprosy

• J. JOSHUA

### INTRODUCTION

Leprosy has been the commonest cause of paralysis of the facial nerve in India. Lagophthalmos is the most common presentation of facial nerve paralysis. The manifestations of paralysis, in order of frequency as well as urgency of treatment, are: lagophthalmos (Zygomatic branch) and total facial paralysis (branches to all facial muscles. The exact incidence of facial paralysis in leprosy is not known. However, Courtright et al<sup>4,5</sup> found facial nerve paralysis in 3.8% of newly detected cases. These persons had a 7.5 fold higher risk of keratitis. In our control area in Calcutta, where we cover a population of 1.2 million, in over a period of 20 years, we found that less than 0.1% of cases (a total of 28 cases) had facial paralysis. Of these, 82% had lagophthalmos alone and 18% had paralysis of other facial muscles as well. In 68% of cases the impairment was unilateral and in 32%, bilateral. Twelve out of 28 cases had a patch around the eye and the side of the face (unpublished data). Hogeweg<sup>11</sup> reports an incidence of 2% among cases under treatment with Multi-Drug Therapy.

At one time the involvement of the facial nerve was believed to be restricted to the Zygomatic branch, especially where it crosses the bone. Subsequently, much more proximal involvement of the facial nerve has been demonstrated and Lubbers et al<sup>20</sup> have recorded patchy involvement of the facial nerve. The work of Richards and Jacobs<sup>24</sup> suggests intracranial involvement of the nerve. In short the last word is yet to be written regarding the

site of nerve involvement in leprosy (Palandepersonal communication).

What we do know is that lagophthalmos is common and may often need urgent treatment to prevent impairment of vision secondary to exposure keratitis.

When the cornea is exposed because of lagophthalmos, exposure keratitis is inevitable. The situation becomes much worse when corneal sensation is also lost (because of involvement of the peripheral branches of the trigeminal nerve). This removes the stimulus to blink, and leaves the eye constantly open to the elements. In this situation protection of the eye requires emergency measures. Early surgery may be indicated in order to preserve vision.

Lagophthalmos by itself may require correction because it is unsightly, although it must be realised that some procedures actually worsen the cosmesis. However,

1. The danger of exposure keratitis due to drying of the cornea can lead to corneal ulceration, opaque scar formation and total blindness or organisation of the keratitis and subequatorial blindness, and
2. In the absence of corneal sensation and the stimulus to blink, the risk of corneal ulceration and its complications leading to blindness is increased.

In view of the seriousness of the condition, lagophthalmos with loss of corneal sensation constitutes one of the urgent complications of leprosy, which demands immediate careful treatment.



In the case of early paralysis, (paralysis of less than six months duration), systemic steroids are indicated along with measures to protect the cornea.<sup>12</sup> Measures to protect the cornea include wearing dark glasses during the day and using methylcellulose drops or sterile castor oil drops twice daily for about three months. This helps in keeping the cornea moist and transparent. Eye pads at night are helpful. A simple stay suture placed through the upper lid and then strapped down to the cheek<sup>18</sup> to keep the cornea covered is advocated as a temporary measure by some authors. Strapping of the face, in near symmetrical position and electrical stimulation of the paralysed muscles are also useful measures (Palande- personal communication). Active and passive exercises to close the eyes frequently are of great importance. If no improvement is evident within six months definitive surgical measures are required to protect the cornea, recognising however that in a few cases spontaneous recovery may still occur.<sup>9</sup>

Treatment of paresis of the facial nerve in leprosy has seen increasing choices during the past three decades. The possibilities of surgical treatment of the problem per se, regardless of its pathology, are very extensive—from implantations of springs and weights, to static and dynamic supports and muscle transfers, transposition and suture of regional nerves to branches of the facial nerve (nerve crossovers), cross facial nerve grafts and micro-vascular muscle transplants<sup>2</sup>.

However, in leprosy only some of these methods have been practiced. The common procedures are:

### **Static procedures:**

- Tarsorrhaphies
- Canthoplasties
- Canthopexies
- Lid magnets
- Sialastic slings
- Springs
- Lid Loading
- Ear cartilage grafts

### **Dynamic Procedures:**

Muscle transfers

### **PROCEDURES**

The operation for the correction of lagophthalmos aims at <sup>9</sup>

1. Narrowing the widened palpebral fissure.
2. Correction of ectropion.
3. Apposing the lower eyelid and its lacrimal punctum to the globe to facilitate drainage of tears.
4. Providing for voluntary closing and opening of the eye and.
5. Being cosmetically acceptable to the patient.

The operation for correction of facial palsy involving the buccal and mandibular divisions of the facial nerve in addition to the zygomatic division, aims at all the above as well as providing for the continence of the lips.<sup>2</sup>

If, on light closure of the eye (not closed tightly, but as in sleep), there is a lid-gap of more than 5 mm, a dynamic procedure is usually indicated. If the lid gap is less than 5 mm, a static procedure may be indicated. In case of old age, where there is a laxity of the lower lid and ectropion in addition to the paralysis, a static procedure to either shorten the lower lid and/or bring up the lower lacrimal punctum to appose the globe may be combined with a dynamic procedure.

Loss of corneal sensation removes the stimulus for active lid closure. In these cases we prefer a dynamic procedure, as it tends to close the eyelids on chewing, which in itself may be protective. Further the concept of 'think and blink' can be practiced effectively only when the ability to close and open the eyes is present and therefore a dynamic procedure is indicated.

Various methods are in use, and there are inadequate follow-up studies to draw specific

conclusions as to which are the best procedures. Multiple procedures or a combination of procedures may be required for individual cases, such as a local procedure both medially and laterally. The following is a brief description of common procedures in use in facial palsy due to leprosy.

### **Static procedures**

#### **Lateral Tarsorrhaphy (McLaughlin)<sup>13</sup>**

This is only of historical interest and is mentioned because we still come across patients who have undergone this procedure in the past. Today there is no indication for this procedure except in situations where appropriate expertise is not available. We are still being called upon to correct lagophthalmos in patients who had undergone this procedure. The author prefers to undo this tarsorrhaphy before proceeding with a dynamic procedure. The tarsorrhaphy as described by McLaughlin is as follows.

**Technique:** An incision is made along the lateral end of the lower lid margin for about 5 mm. A part of the anterior lamella is excised. The inter-marginal line of the upper lid is similarly split and a part of the conjunctiva and tarsus is excised. The two raw areas are sutured together using 5:0 silk sutures tying the knot over the

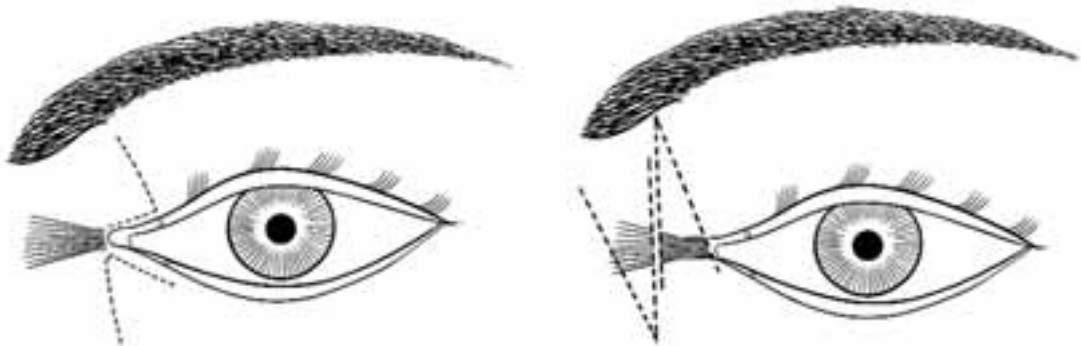
upper lid over a rubber strip. Sutures can be removed on the 5th post-operative day.

This procedure is not very effective because most of the laxity is on the medial side. Fusion of the lateral end of the palpebral fissure does not help.<sup>9</sup> This procedure is not recommended.

#### **Fritschi's Medial tarsorrhaphy<sup>9</sup>**

This works on the principle of the Z plasty and is indicated in cases with ectropion. The cosmetic result is better in this than in the preceding procedure.

**Technique:** Under local anaesthesia incisions are made in the upper and lower lid margins in the part of the lid medial to the punctum (Fig. 19-1a). These incisions should involve the entire thickness of the lids including the skin and mucous membrane medial to the punctum. Two triangular flaps are designed as follows. The lower flap is designed by incising from the medial end of the full thickness incision of the lower lid to raise a thin skin flap based laterally. The upper flap is cut from the lateral end to raise a thin skin flap based medially. These are both triangular flaps and are raised by undermining. The exposed edges of the tarsal plates of both lids are sutured to each other with 4:0 catgut. The skin flaps are interchanged and sutured with 5:0 silk (Fig. 19-1b). The eye is kept covered by a pressure dressing



**FIGURE 19-1** Fritschi's medial tarsorrhaphy.

for 24 hours. Skin sutures are removed on the 6th postoperative day.

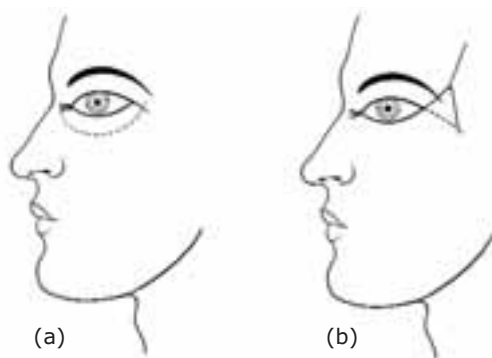
This procedure has the following advantages.

Hitching up the lower lid to the upper is done in the area which shows the maximum laxity. This procedure causes the lachrymal punctum to be turned inwards and thus brings it to appose the globe.

### Kuhnt-Szymanowski Palpebroplasty<sup>9, 18</sup>

This procedure is indicated when the ectropion is severe and involves the whole of the lower lid. In such cases the lower lid needs to be shortened and supported.

An incision is made just below the ciliary margin of the lower lid extending laterally from the medial third to the orbital margin (Fig. 19-2a). The incision is then angled along the 'crow's feet' wrinkles. The skin is undermined right down to the inferior orbital margin. The flap of skin is then raised and pulled laterally. The overlapping part of the flap is excised (Fig. 19-2b). This is then sutured in its new position supporting and shortening the lower lid. This procedure can be modified, by excising a full thickness of the lower lid at the lateral edge. A strip of fascia lata can be added to give support, medially attached to the medial palpebral ligament and laterally to the lateral orbital margin as high as necessary.



**FIGURE 19-2a,b** Kuhnt-Szymanowski palpebroplasty.

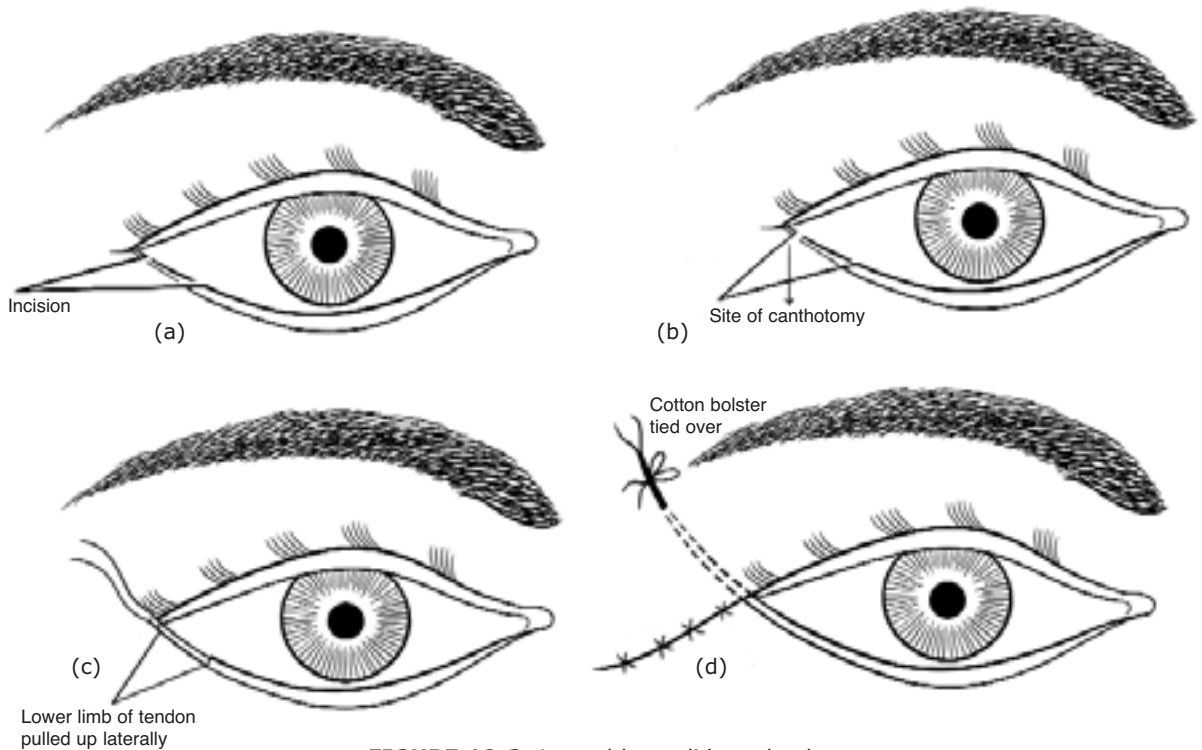
### Edgerton-Montandon technique of canthoplasty and tarsorrhaphy<sup>2,7,23</sup>

Edgerton and Wolfort described a technique to support the lower lid using a dermal flap secured to the lateral rim in cases of lower lid laxity. This was similar to the above procedure by Kuhnt-Szymanowski. Montandon later modified this technique to incorporate a portion of the upper and lower eyelid margins with the dermal flap, in effect combining the lateral canthoplasty with a lateral tarsorrhaphy. Grauwin, Saboye and Cartel<sup>10</sup> followed up 30 eyes in 21 leprosy patients treated by this technique and reported favourable results.

### Lateral Lower Lid Canthoplasty<sup>2,15</sup>

In cases of mild lagophthalmos associated with ectropion, Jelks et al described a procedure of shortening the inferior limb of the lateral canthal tendon and hitching it to the periosteum at the lateral orbital rim. It is also known as the lateral tarsal slip procedure.

**Technique:** The lateral canthal tendon is exposed and the lower limb is divided at the orbital rim (Fig. 19-3a). The skin of the lateral edge of the palpebral fissure is raised from over both tarsal plates and over the lateral orbital rim. Upward and lateral traction is exerted on the lower lid to determine the position of the new lateral canthal angle. At this point a laterally based flap of periosteum is raised from the orbital rim. The lower tarsal plate is then divided (Fig. 19-3b). A 4:0 silk suture is passed through the lower tarsal plate and then through the periosteal flap and brought out through the skin at the level of the eyebrow laterally, and tied over a bolster (Fig. 19-3 c-d). Vicryl sutures are used to reinforce the tarsal plate- periosteum attachment. The skin is closed. The final result should initially show over correction. This procedure is often combined with gold weight implantation to load the upper lid.



**FIGURE 19-3** Lateral lower lid canthoplasty.

### Upper Lid Loading<sup>2,19,22</sup>

Implanting a weight in the upper lid uses gravity to reduce the width of the palpebral fissure and to aid in eye closure. A stainless steel mesh, tantalum strip or a gold weight can be implanted into the eyelid. To assess the required load, a series of weights are taped to the upper lid until normal closure is obtained. This weight is then implanted into the upper lid. Gold weights or tantalum strips varying from 0.6 to 1.6 g are implanted. The shape of the tantalum strips can be hand fashioned. This is not possible with gold. In a series by Foda<sup>8</sup>, 40 patients underwent upper lid loading, of which 14 underwent lateral canthoplasty for the lower lid laxity.

Its drawback is that it does not close the eye well when the patient is supine.

Complications include extrusion of the implant, infection and insufficient loading.

### Ear cartilage graft for elongating the levator palpebrae muscle<sup>3,14</sup>

This procedure, originally described by Inigo et al, has been used in leprosy, by Balakrishnan.<sup>3</sup> This operation is helpful in decreasing the palpebral fissure with an ear cartilage sutured between the tarsal plate and the levator palpebrae superioris aponeurosis. The graft provides elongation of the levator muscle and also decreases its strength, since there is no opposing orbicularis oculi activity.

This is performed under local anaesthesia. An incision is made at the supra tarsal fold of the upper eyelid. (Balakrishnan prefers an incision on the palpebral conjunctiva). The insertions of the levator palpebrae superioris and Muller's muscle into the tarsal plate are dissected off the plate. The conjunctiva is completely exposed but left intact.

An auricular conchal cartilage graft is taken with the same length as the tarsal plate and a maximum width of 4 mm for each millimeter of palpebral closure to be achieved. (usually a width of 8 to 12 mm for reducing the palpebral fissure by 2 to 3 mm). The cartilage graft is attached inferiorly to the superior edge of the tarsal plate and superiorly to the levator palpebrae superioris aponeurosis. 5:0 nonabsorbable sutures are used. The skin incision is closed with the same material.

A ptotic eyelid should always be avoided.

**Other techniques** such as the use of sialastic slings (Arion Prosthesis), lid magnets and Morel-Fatio spring implantation in the lids are also available modes of treatment. They have however not found much favour among those working in the field of leprosy as yet, if the available literature is to be taken as reference.

### **Dynamic Procedures**

These are the procedures of choice in lagophthalmos and facial palsy.

They provide for animation of the face and voluntary closure of the lids. The cosmetic results are also much better with these procedures.

### **Temporalis Muscle Transfer:**

#### **Principles laid down by Gillies<sup>2,9</sup>**

The muscle originates from the temporal bone and periosteum between the inferior temporal line and the infra temporal crest on the deep aspect in the infra temporal fossa and from the temporalis fascia superficially. It inserts into the coronoid process and a portion of the ascending ramus of the mandible.

The blood supply is from the anterior and deep temporal arteries and veins which are the tributaries of the internal maxillary system which enter the infra temporal fossa inferior to the zygoma predominantly on its antero-medial aspect and spread out through the muscle superiorly.

The nerve supply is from the anterior and posterior deep temporal nerves which are branches of the mandibular divisions of the trigeminal nerve. The nerves are deeper and posterior to the vascular supply and enter the muscle in proximity with the vessels and traverse it from below upward.

The muscle can therefore be mobilised from its origin and still be viable and retain its nerve supply and its function.

### **Temporalis muscle transfer for unilateral, lagophthalmos**

**Gillies method<sup>1,18</sup>:** This is the method first described by Gillies and first employed in leprosy by Antia<sup>1</sup>. This is indicated in lagophthalmos. The benefits of this procedure are seen in a very short time.<sup>25</sup>

**Anaesthesia:** Local or general anaesthesia can be used.

**Procedure:** A vertical incision is made from the superior temporal line down to the zygoma within the hairline. The underlying superficial temporal fascia is exposed. A vertical strip of fascia from about the middle of the muscle extending the length of the incision and about 1 cm in width is cut, detached from the zygoma and raised upwards taking care not to strip it off the superior aspect of the muscle (Fig. 19-4a-b). The strong musculo-periosteal junction at the temporal line is preserved in continuity with the dissected fascia. The periosteum is raised from above, downwards right down into the temporal fossa. A muscle belly of about 3 cm breadth is thus elevated from the bone down to the level of the zygoma. A mattress suture is applied to the musculo-periosteal junction with the temporal fascia to prevent accidental separation during these manipulations. We thus have a strip of muscle in conti-

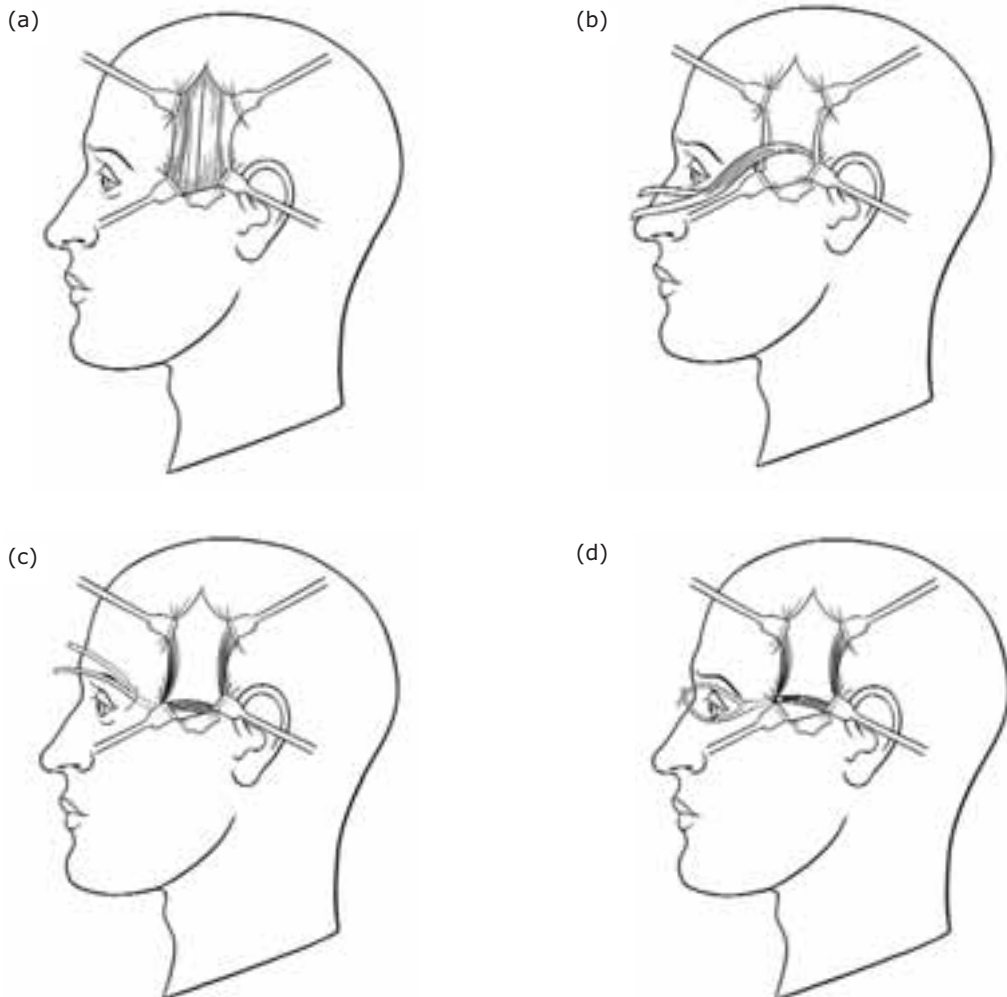


nuity with a strip of superficial temporal fascia. This fascia is then divided into two slips. Yoleri and Sangur<sup>27</sup> use a small slip for the lower lid and twice this mass for the upper lid.

A horizontal incision is made along the crow's feet wrinkles at the lateral orbital ridge and the two facial slips along with the muscle are tunneled in a subcutaneous plane to that site (Fig. 19-4c).

A curved incision is made on the lateral aspect of the nose to display the medial canthal ligament. This is dissected and undermined.

One of the facial slips is tunneled along the edge of the upper lid in a superficial plane and the other is tunneled similarly through the lower lid from the lateral incision to the medial incision. Care is taken to tunnel along the lid margin and as superficially as possible. Failure to do this will result in eversion of the lid margin when the muscle contracts. At the medial incision, each slip is passed deep to the medial canthal ligament, brought together superficial to it and sutured to each other and to the ligament, using 5:0 silk sutures (Fig. 19-4d).



**FIGURE 19-4 a - d** Temporalis muscle transfer for unilateral lagophthalmos: Gillies method.

Schwarz uses PDS to avoid stitch abscesses (personal communication). The tension is adjusted by allowing the lids to close the eye with a little bit of overlap of the upper over the lower lid. If the free ends of the slips are held by mosquito artery clamps and allowed to hang free after taking up the slack, the tension has been found to be just right. The suture is then applied. The tension on the lower one is usually set higher than the upper, as the major problem is with the lower lid. Too tight on the upper lid and the person can get restricted vision.

All wounds are closed with 5:0 non-absorbable sutures. An antibiotic ointment is placed beneath the eyelids to keep the cornea and conjunctiva lubricated. A pad is placed over the eye and the temporal region for one day. This is removed 24 hours after surgery. Skin sutures are removed on the 5th postoperative day.

The patient is kept on a liquid diet for three weeks. Chewing is gradually resumed and increased as the patient is taught to practice control of facial movements in front of the mirror.

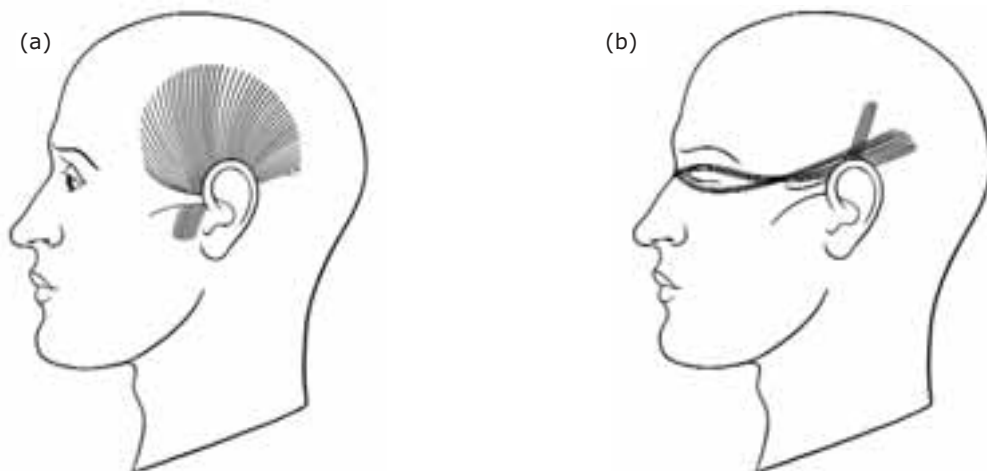
#### Johnson's method<sup>9,16,17,26</sup>

This operation utilises the same muscle but instead of the muscle slip being mobilized from

its origin, a posterior slip of muscle is taken and its tendon just above the zygoma is mobilised, leaving its origin intact. It has the advantage that there is no angulation of the fibres of the slip, there is much less blood loss and there is no visible bulge of muscle seen. The disadvantage is that, removal of the fascia lata has to be done as a separate procedure.

**Anaesthesia:** Local or general anaesthesia can be used. Local anaesthesia is preferred.

**Procedure:** A vertical incision is made from the zygoma for about 4 cm upwards, within the hairline anterior to the ear. The superficial temporal fascia is exposed and incised along this line and widened by cutting across by blunt or sharp dissection. The fibres of the temporalis muscle and its tendon are seen through this incision (Fig. 19-5a). The nearly horizontal posterior fibres of the tendon and muscle are separated and isolated using a right angled or curved artery clamp. This bundle of tendon and muscle is cut away at its insertion and the cut end brought out of the wound and held in an artery clamp. If the procedure is being done under local anaesthesia, on requesting the patient to clench his/her teeth, the cut tendon



**FIGURE 19-5a,b** Temporalis muscle transfer for unilateral, lagophthalmos: Johnson's method.

slip will retract into the wound and on relaxing, will come into the wound.

A 10 cm long, 1 cm wide strip of fascia lata graft is harvested from the thigh under local anaesthesia. Thin fascia is needed, which is found more anteriorly.

The end of the fascia is passed through the free end of the fascicle of muscle and tendon and sutured and the stump buried in the muscle. The fascia in turn is wrapped around the free end of the muscle slip.

A horizontal incision is made along the crow's feet wrinkles at the lateral orbital ridge. The tendon graft is now tunneled to this incision in a subcutaneous plane. Here it is divided into two slips (Fig. 19-5b).

The remainder of the procedure and post-operative care is as described under the Gillies method. Pre- and early post-operative results are seen in Fig. 19-6.

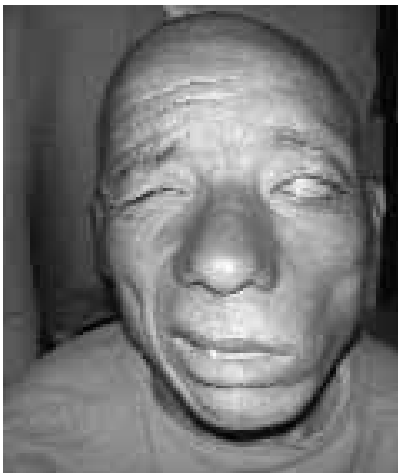Johnson's method needs a graft for extending the posterior part of the tendon of Temporalis muscle. Fascia lata or palmaris longus tendon are the usual choices. This procedure has the main advantage that the pull is horizontal and not oblique. Hence there is also a higher likelihood of a higher than needed tension. Conversely, excessive care to prevent

higher tension may result in inadequate tension<sup>24</sup>.

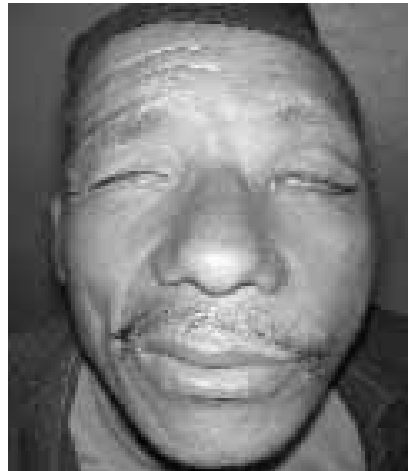
In either method, it is essential to ensure that the transferred slip stays along the curved lid margin and does not become straight on contraction of the temporalis. If the slip shifts up/down and becomes straight this would cause eversion of the lid and also lowered tension – inadequate lid closure. An additional stitch in the middle may sometimes be required to prevent lid eversion. (Schwarz, Palandepersonal communication). Personally I prefer the technique described by Johnson because the dissection involved is much less. The length of the fascia used can be longer and therefore the final insertion into the medial canthal ligament is easier and the tensions can be easily adjusted without any worry about the availability of adequate fascia. In the Gillies procedure, there is a tendency to be left with inadequate length of the temporal fascia, resulting in difficulty at the point of suturing the slips to the medial canthal ligament.

### ***Procedures for Total Facial Palsy***

In cases where the entire half of the face requires reanimation, muscle transfers are the most often used procedures. A masseter trans-



**FIGURE 19-6a** Left total facial nerve palsy.



**FIGURE 19-6b** Following Johnson temporalis muscle transfer.

fer for the mouth and cheek can be combined with any of the above-mentioned dynamic procedures. A temporalis muscle transfer as described by Gillies can be used as a single procedure to reanimate the entire face.

### Masseter Transfer<sup>1,2</sup>

This procedure can be combined with any of the above-mentioned procedures for lagophthalmos, when the lips need to be made continent and the lower face reanimated.

The surgical anatomy, and location of the masseter muscle make it ideal for transposition to animate the upper and lower lips and the oral commissure. The muscle arises from the inferior surface of the zygomatic arch and is inserted into the lateral aspect of the ascending ramus of the mandible (Fig. 19-7a).

the entire muscle may be used. Transposing only the anterior two third of the muscle runs the risk of denervating and devascularising the transposed part of the muscle. Mobilising the entire muscle causes problems of reach. The posterior fibres of the muscle may not extend up to the oral commissure. Methods to counter these problems are described with the procedure. The latter is the safer technique.

**Anaesthesia:** The surgery can be done under general anaesthesia or under local anaesthesia.

**Procedure:** Antia<sup>1</sup> describes a submandibular incision, and transfers only the anterior two thirds of the muscle. Baker<sup>2</sup> refers to an intra-oral approach for limited transfers of the muscle and an extra-oral approach using a preau-

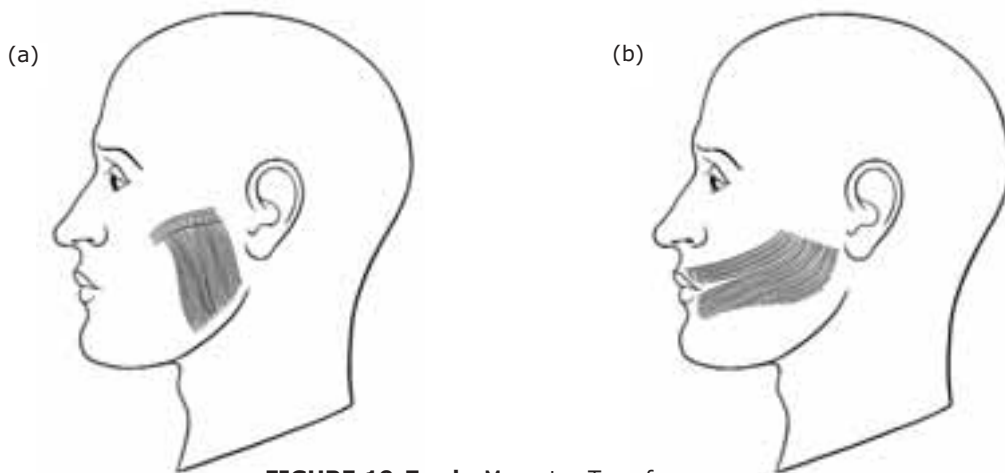


FIGURE 19-7 a-b Masseter Transfer.

The nerve supply is from the masseteric nerve arising from the mandibular nerve and the blood supply is from the masseteric artery arising from the internal maxillary artery in the infratemporal fossa. The neurovascular bundle passes through the coronoid notch of the mandible and runs obliquely forward and diagonally downward across the muscle. In transposing the muscle for reanimation of the lips, part of the muscle (anterior two third) or

ricular incision with a submandibular extension for transfer of the entire muscle. The skin needs to be undermined to expose the muscle.

This last is favoured by the author, as it provides adequate exposure when the cheek flap is elevated. This is also cosmetically acceptable. The tendinous insertion of the muscle is incised and raised from the lower end of the horizontal ramus of the mandible. The muscle is mobilised from the mandible taking care not to

injure its neurovascular supply at the coronoid notch. The anterior portion can be freed entirely from the mandible. The lateral cheek is undermined to create a tunnel for the muscle to the lips. At the angle of the mouth, the tunnel extends into the upper and lower lips as two extensions. As described by Antia<sup>1</sup> and by Baker<sup>2</sup>, the muscle is received in the cheek through an incision along the nasolabial fold, divided into two slips. This division should not extend proximal to its distal third so as not to damage its nerve supply and vascularity. If the muscle is long the slips can be tunneled into the lips one into the upper lip and one into the lower lip (Fig. 19-7b). If short, the slips are lengthened by two fascia-lata strips and passed into the lips. Alternatively length can be gained by partial release of the muscle from its tendinous origin. Insertion is into the intact orbicularis oris muscle of the opposite side and into the dermis using a pullout suture. Suitable incisions can be made over the philtral column of the non-paralysed side.

Meticulous haemostasis is achieved. The wounds are closed in two layers over a drain. A tight dressing is applied. The drain is removed after 48 hours and sutures are removed on the 5th post-operative day. Postoperative management is the same as for the previously described muscle transfer procedures.

### **Temporalis muscle transfer for unilateral, total facial palsy<sup>2</sup>**

The procedure described here is Gillies' procedure, modified by Baker<sup>2</sup> for facial paralysis involving the zygomatic, buccal and mandibular divisions. This has the advantage of using one muscle to reanimate the entire face, providing continence to the lips and closure of the eye.

**Anaesthesia:** General anaesthesia is preferred but the procedure can be carried out under

local infiltration with 1% Xylocaine with 1 in 200,000 dilution of Adrenaline.

**Procedure:** The superficial temporal fascia is exposed above the zygoma through a crescent-shaped, cruciate, or T type of incision anterior to the ear of the affected side. The entire temporal muscle is elevated with 2 cm of pericranium about its peripheral margin, starting from above, proceeding downwards using a periosteal elevator down to the level of the zygoma. The superficial temporal fascia is separated from the zygoma and five slips<sup>3</sup> of the fascia are created by incising the fascia vertically. This is then separated from the muscle, starting inferiorly and proceeding upwards, and the slips of fascia are left attached to the pericranium at the superior extent of the dissection. At this point, each of the five slips are sutured to the dissected pericranium and the superior end of the temporalis muscle by mattress sutures, to prevent them from accidentally separating from the muscle. The muscle is now incised so as to provide five active muscle bellies for the five facial slips. The two anterior slips are set apart for use for the eyelids and the other three for the upper lip, angle of the mouth and the lower lip respectively (Fig. 19-8a).

**For the eyelids:** A horizontal incision is made along the crow's feet wrinkles at the lateral orbital ridge and two facial slips along with the muscle slips are tunneled in a subcutaneous plane to that site.

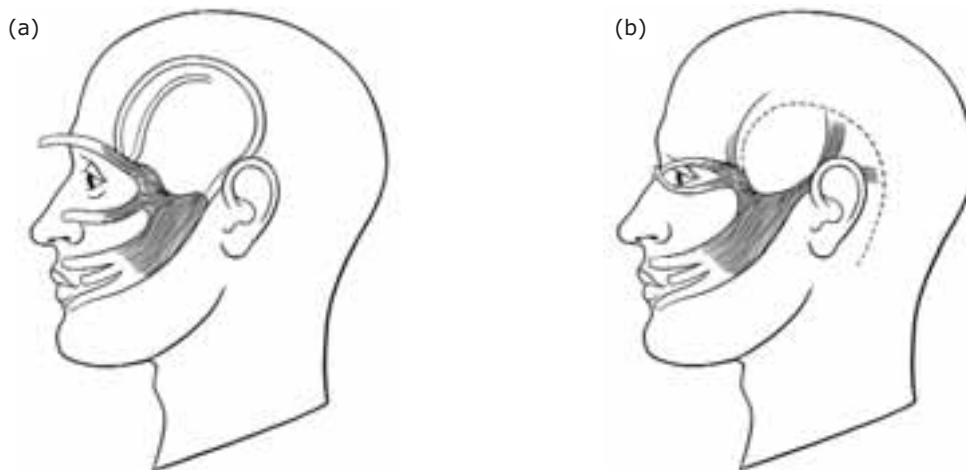
The remainder of the eye portion of the procedure is as that described for the Gillies transfer above.

**For the mouth:** An incision is then made along the naso-labial fold of the affected side.

The other three slips are tunneled in a subcutaneous plane to the naso-labial fold incision (Fig. 19-8b). Here the slack is taken up.

**For the upper lip:** One of these slips is then again tunneled along the upper lip in a subcu-





**FIGURE 19-8** Temporalis muscle transfer for unilateral, total facial palsy.

taneous plane to an incision along the philtral column of the opposite side. The slip is sutured to the dermis of the skin just lateral to this incision, using 4:0 or 5:0 vicryl sutures. If the slip does not extend this far, a fascia lata graft can be anastomosed to the tip of this slip and used. Adequate tension is used to provide over correction enough to bring the opposite philtral column to the midline. The point between the first incisors of either side determines the midline.

**For the lower lip:** The last slip is now tunneled through the subcutaneous plane of the lower lip and recovered through an incision on the skin at a site just below the opposite philtral column before the sutures of the upper lip had been applied. This is sutured now under similar tension producing an over correction bringing this sutured site to the midline (point between the first incisors of either side)

**For the angle of the mouth:** One slip is sutured to the dermis at the commissure, at the same tension. Just taking up the slack will now produce the desired result. This step can be accomplished from the same nasolabial incision.

Over correction and exaggeration of the nasolabial fold and corner of the mouth are

essential. The over correction resolves within a few weeks.

All wounds are closed with 5:0 non-absorbable sutures. An antibiotic ointment is placed beneath the eyelids to keep the cornea and conjunctiva lubricated. A pad is placed over the eye and the temporal region for one day. This is removed 24 hours after surgery. Skin sutures are removed on the 5th postoperative day.

The patient is kept on a liquid diet for three weeks. Chewing is gradually resumed and increased as the patient is taught to practice control of facial movements in front of the mirror.

This can also be done as per the Johnson technique. Pre- and post-operative results are seen in Fig. 19-6.

**Other Procedures:** Procedures such as cross facial nerve grafts, hypoglossal nerve crossovers (end to end and side to end), and microvascular functional muscle transfers used in cases of facial nerve palsy due to other causes have not as yet found application among those working in leprosy. The future possibilities are immense and need to be explored.

## REFERENCES

1. Antia NH: Facial paralysis. pp 113-121. In MacDowell F and Enna CD: Surgical Rehabilitation in Leprosy and in other Peripheral Nerve Disorders. The William and Wilkins Company, Baltimore, 1974
2. Baker DC: Facial Paralysis. pp 2237 – 2315. In McCarthy J.G: Plastic Surgery, Vol 3. WB Saunders Company, Philadelphia, 1990
3. Balakrishnan G. Personal communications.
4. Courtright P, Lewallen S, Li H, Hu L & Yang J: Lagophthalmos in a multi-bacillary population under multidrug therapy in the People's Republic of China. *Lepr Rev* 66: 214-219, 1995
5. Courtright P, Kim S, Tungpakron N, Cho B, Lim Y, Lee H, Lewallen S: Lagophthalmos surgery in leprosy: Findings from a population-based survey in Korea. *Lepr Rev* 72: 285-291, 2001
6. Daniel E, Premkumar R, Koshy S, Yowan P, Kurian N, ffytche TJ: Hypopigmented face patches; their distribution and relevance to ocular complications in leprosy. *Int J Lepr Other Mycobact Dis* 67(4):388-391, 1999
7. Edgerton MT, Wolford FG: The dermal-flap canthal lift for lower eyelid support. *Plast Reconstr Surg* 43: 42, 1969
8. Foda HM: Surgical management of lagophthalmos in patients with facial palsy. *Am J of Otolaryngology* 20(6):391-395, 1999
9. Fritschi EP: The Surgery of Facial Deformity. pp 129-137. In Surgical Reconstruction and Rehabilitation in Leprosy 2nd edition, 1984
10. Grauwin MY, Saboye J, Cartel JL: External canthopexy using the Edgerton-Montandon procedure in lagophthalmos of leprosy patients. [Technique and indications. Apropos of 30 cases]. *Ann Chir Plast Esthet* 41(4):332-337, 1996
11. Hogeweg M: Ocular Leprosy. *Int J Lepr* 69(2):30-35, 2001
12. Hogeweg M, Kiran KU, Suneetha S: The significance of facial patches and type I reaction for the development of facial nerve damage in leprosy. A retrospective study among 1226 paucibacillary leprosy patients. *Lepr Rev* 62(2):143-149, 1991
13. Holmes WJ: Surgical procedures for Lagophthalmos, other than the temporalis transfer. pp 105-112. In MacDowell F, and Enna CD: Surgical Rehabilitation in Leprosy and in other Peripheral Nerve Disorders. The William and Wilkins Company, Baltimore, 1974
14. Inigo F, Chapa P, Jimenez Y, and Arroyo O: Surgical treatment of lagophthalmos in facial palsy: ear cartilage graft for elongating the levatorpalpebrae muscle. *Brit J Plast Surg* 49:452-456, 1996
15. Jelks GW, Smith B, Bosniak S: The evaluation and management of the eye in facial palsy. *Clin Plast Surg* 6:397, 1979
16. Johnson HA: A Modification of Gillies Temporalis Transfer for the Surgery of the Lagophthalmos of Leprosy. *Plast Reconstr Surg* 30: 378, 1962
17. Johnson H.A: An Operation to Restore Eyelid Function Lost in Leprosy. *Int J Lepr* 33: 89, 1965
18. Karat S: Correction of Lagophthalmos by Temporalis Transfer. pp 85- 94. In MacDowell F, and Enna CD: Surgical Rehabilitation in Leprosy and in other Peripheral Nerve Disorders. The William and Wilkins Company, Baltimore, 1974
19. Levine RE, Shapiro JP: Reanimation of the paralysed eyelid with the enhanced palpebral spring or the gold weight: modern replacements for tarsorrhaphy. *Facial Plast Surg* 16(4):325-336, 2000
20. Lubbers WJ, Schipper A, Hogeweg M, de Soldenhoff R: Paralysis of facial muscles in leprosy patients with lagophthalmos. *Int J Lepr* 62(2):220-, 1994
21. Miller SH, Wood M: Surgical treatment of facial nerve involvement caused by leprosy. *Am J Trop Med Hyg* 25(3):445-448, 1976
22. Misra A, Grover R, Withey S, Grobbelaar AO, Harrison DH: Reducing postoperative morbidity after the insertion of gold weights to treat lagophthalmos. *Ann Plast Surg* 45(6):623-628, 2000
23. Montandon DA: A modification of the dermal-flap canthal lift for correction of the paralysed lower eyelid. *Plast Reconstr Surg* 61: 555, 1978
24. Richard BM, Jacobs JM: Facial nerve pathology in leprosy: searching for the proximal extent of the lesion in facial nerve biopsies. *Lepr Rev* 70(3):333-344 1999
25. Soares D, Chew M: Temporalis muscle transfer in the correction of lagophthalmos due to leprosy. *Lepr Rev* 68(1):38-42, 1997
26. Warren G: Facial palsy--a leprosy surgeon's viewpoint. *Aust N Z J Ophthalmol* 18(3):257-266, 1990
27. Yoleri L, Songur E: Modified temporalis muscle transfer for paralytic eyelids. *Ann Plast Surg* 43(6):598-605, 1999

## Surgery of the Nose and Other Aesthetic Surgery

• G. WARREN  
R. SCHWARZ

### INTRODUCTION

Facial appearance is often important in social contacts in creating a good first impression. Many patients with a facial impairment will be aware that a facial impairment will make them look different. This could count against them in social acceptance. Many would want or request for aesthetic surgery to minimise or restore their facial impairment. Even if the surgeon is not able to completely correct the impairment, any reduction will be an advantage and may enable society and the patient to change their perception. In the case of leprosy the loss of eyebrows and presence of nasal deformities are often a real problem for social acceptance by the community. The scarred slack redundant skin of the face that follows marked leprous leprosy makes a young man look much

older than his calendar years. Deformity of the pinna may indicate old lepra reaction or infection to the clinician but to the patient may mean possible rejection. Large ear lobes are often unacceptable to the patient trying to get on with life. In some patients the provision of a pair of glasses (even plain glass) with ornate or attractive frames (Fig. 20-1), or a new attractive "hairdo" may be enough to hide the impairment and deflect unwanted attention. However, in the younger age group surgical intervention may provide a much better permanent alternative. There are many surgical textbooks that describe facial operations. It is impractical to include all the possible procedures in this chapter. Those selected for inclusion are the most commonly used and applicable in leprosy affected persons and yet are sim-



**FIGURE 20-1a** This degree of deformity of his nose was enough to stigmatise this patient.



**FIGURE 20-1b** When he acquired a pair of fancy rimmed glasses the stigma was no longer a problem.

ple enough for most surgeons to perform. Consideration is also given to the time required for each procedure and the expenses involved. Most centres treating large numbers of leprosy patients cannot afford to use the expensive modern alternatives to the patient's own tissues, especially when these are available virtually free of charge. Any surgeon wishing to regularly do this type of surgery should read widely to understand the reasons for the many variations and possibilities.<sup>6,11,17</sup> It is recommended that at least one of the more recent text books is studied.

It must be remembered that lepromatous leprosy involves the skin and subcutaneous tissues and that lesions may heal with marked fibrosis. Lepromatous patients may have large areas of scarred skin in which there is considerable fibrosis that results in disruption of the normal blood supply so that rotation flaps and pedicle grafts may not survive a transfer. Hence some procedures regarded as "routine" in other situations are not applicable. Extra care needs to be taken when doing face-lifts, nose reconstruction, or flaps of any kind on the face, to avoid tissue loss and increased scars.

## **REGULAR RECONSTRUCTIVE PROCEDURES**

The most common procedures used for facial deformities due to leprosy are procedures for:

1) facial paralysis, 2) nose and 3) eyebrow reconstruction, 4) ear reconstruction and 5) face lifts.

### **1. Improvement of appearance and function after facial palsy**

Marked loss of symmetry and asymmetrical movement is frequently the first thing noticed when someone is met for the first time. It is important to remember that no one's face is completely symmetrical.

### **Facial paralysis can involve:**

- a. The eyelids- lagophthalmos, one or both lids,
- b. The lower face and
- c. The eyebrow, sometimes in isolation.

Improvement in basic appearance may be achieved either by static slings or muscle transfers. There are also more complicated nerve and/or muscle grafting procedures available (Chapter 19).

### **2. Reconstruction of the Nose**

Various methods are available. Simple insertion of bone or cartilage may be adequate. However, it may be better combined with reconstruction of soft tissues by various methods. In leprosy the most common nose deformity is the so called "saddle nose" due to destruction of the septal cartilage and the contraction of the lining of the nose. If the nasal lining is released the external skin is usually adequate so that no or minimal external scars are produced in reconstructing a cosmetically acceptable nose. In planning nose reconstruction it is important to consider the ethnicity of the patient, his family characteristics and to study any photographs of the patient prior to the development of the deformity. Some patients require high nasal tips and bridges but some dislike this height. Most leprosy patients are satisfied if the obvious stigma of leprosy is removed. It is better to use the more simple techniques and succeed than to attempt the more difficult operations and increase the scars on the patient's face.

### **3. Eyebrow Replacement or Supplementation**

Eyebrow reconstruction could consist of:

- a. Individual hair follicles replacement. This is ideal to correct thin eyebrows without leaving scars, or for ethnic groups with

normally thin eyebrows.<sup>4,14</sup> Larger punch grafts may also be used.<sup>22</sup>

- b. Free graft of hair bearing skin; usually post auricular skin.<sup>9</sup>
- c. Pedicle graft. This is usually based on the superficial temporal artery and is advisable in ethnic groups where very thick eyebrows are desirable.<sup>11</sup>

#### 4. Ear Trims

Usually it is only the lobes, which may become very large and floppy after lepromatous leprosy. Patients may also benefit from excision of nodules and scars on the pinna. The whole edge of the pinna may be destroyed or it may present a moth eaten appearance after severe lepra reaction. Occasionally long tube pedicle grafts to repair damage to the helix and/or lobe are applicable.

#### 5. Face-lift

After severe lepromatous leprosy the skin is often left redundant, especially the midface, including the upper lip. This may make a young man look prematurely old. In many cases of facial palsy a midface face-lift combined with fascial slings can result in a very acceptable face.

### 1. PARALYTIC IMPAIRMENTS (See Chapter 19)

#### 2. NASAL DEFORMITY

In leprosy the mucous membrane of the septum of the nose is very prone to ulceration, either as a result of rupture of a lepromatous nodule, or from ulceration of lepra reaction lesions. Defects in the mucous membranes allow secondary infection to destroy the septal cartilage. As the main support of the dorsum of the nose is destroyed there is a tendency for the

nose to collapse. Initially the bridge is usually unaffected while there may be a complete collapse of the mid-third and retraction of the lower nose. In leprosy, the nasal bones are usually destroyed by sepsis, not directly by the leprosy process. Hence the pathology and anatomical changes are different to those occurring in syphilis where the primary involvement is in the nasal bones although the external appearance may be similar.<sup>6</sup> Millard and Mejia state that the deformities of the nose caused by cocaine use are similar to those caused by leprosy.<sup>19</sup> Irrespective of the cause of the collapse the methods of correction described here are relevant.

In leprosy, the nasal bones are usually spared until very late. Many leprosy patients do not require any surgery to increase the height of the bridge of the nose. However, they usually are not averse to having the bridge heightened as is necessary if a bone graft is going to be arthrodesed to the bridge. Once the cartilage support has been destroyed the damaged mucous membrane, now without support, tends to scar and contract, and this contraction pulls down the external skin of the nose towards the maxilla, resulting in the characteristic depression of the dorsum of the nose and flaring of the nostrils. When the nostrils flare there may be an accompanying increase in the depth of the creases separating the ala from the cheek. The result is that when one stands eye to eye with the patient one can look into the nostril, and that is not normal (Fig. 20-2).

It is most important to study the nasal contours of the racial group as a whole before embarking on nasal reconstruction. For social acceptance it is necessary that the nose does conform to the norm for that racial group. In some races the nose is basically flat and a "saddle nose" may not be a big problem if the nasal bones are intact and normal.

In leprosy, in cases of mild nasal collapse, the appearance is similar to that found in





**FIGURE 20-2** This patient shows the typical flaring of the nostrils, that are almost vertical due to some soft tissue contraction.



**FIGURE 20-3** The same patient as in Fig. 20.2 after insertion of bone graft without need of lining release.

patients who have undergone nasal trauma or overzealous septo-plasty. If the patient is seen early when the nasal ridge is just beginning to collapse, he should be encouraged to pull the nasal skin out at the site where the depression may occur so that the skin is not allowed to contract. This may be enough to prevent an obvious collapse occurring. Figure 20-3 shows the effect of a bone graft in the patient in Figure 20-2 who did not require a lining release. Ointments may also be used to reduce the infection and inflammation of the septal lesions. Do not attempt inserting cartilage or bone grafts or synthetic material until the active phase of the leprosy is controlled and skin smears are negative as the risk of infection or ongoing destruction would be high. In some situations it is urgent that something be done to compensate for the collapsed nose, while the patient is highly positive. Then a reconstruction using naso-labial flaps, or a post-nasal epithelial inlay, will probably be best. Perhaps the bone graft can be added, if needed, once the active phase of the disease is completely controlled.

Nasal collapse due to leprosy seldom causes airway obstruction. In fact the nasal cavity is literally that- just a big cavity! Leprosy can cause airway obstruction if the mucosa contracts circularly. But if a patient *complains* of obstruction to breathing it is usually due to some other pathology or active leprosy rhinitis.

### ***Nasal Collapse: Grading***

#### **a. Mild**

There is a slight depression or dip in the nose ridge, with mobile skin (Fig. 20-4). This can usually be corrected by bone or cartilage grafting, or the insertion of a synthetic prosthesis. The whole of the septal cartilage has not been destroyed and the skin not tightly tethered. To check for this, pull the skin of the nose at the site of the depression and see if it is possible to elevate it as much as is required without too much force. If the skin over the dorsum is unduly stretched and is under too much tension it may breakdown after the graft is inserted! These are the noses that are relatively



**FIGURE 20-4** Mild nasal deformity due to loss of septum.

easy to correct by a standard bone, cartilage or synthetic graft, leaving no obvious external scars.

#### **b. Moderate**

This is usually associated with some flaring and moderate to major destruction of the cartilage. Usually there is some contraction of the nasal lining so that the nose cannot be easily mobilised. Initially, at least, the nasal bones and nasal spine are not destroyed. However, as the contraction of the mucous membranes increases the tissues around the nasal edge of the maxilla contract and the skin becomes tightly tethered until flaring of the alae is evident. The tip of the nose is pulled back and the nostrils appear to be wider and more vertical than normal (Fig. 20-2). Any degree of flaring implies that there is a definite contracture of the lining of the nose and that it is probably necessary to replace the lining after primary release of the scar tissue in the septal and alar areas. With these patients there is usually enough skin after release of the lining to cover the reshaped nose.

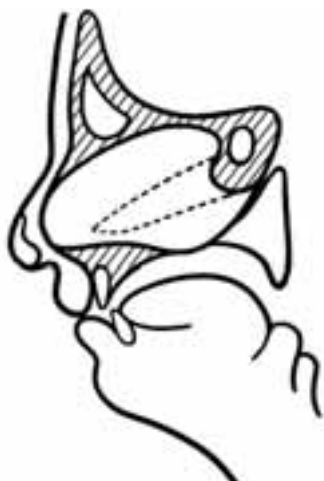This is the group that does well with a post-nasal epithelial inlay skin graft (PNEI) This operation was first described by Gilles who developed it for correction of syphilitic saddle nose, in which the external appearance is similar to that of leprosy deformities.<sup>13</sup> After freeing up the internal scars a split skin graft is applied over a stent to maintain external skin stretch for 3-6 months till contraction ceases. Then a support of the nasal ridge may be inserted if needed. A big advantage of the PNEI technique is that there are no external scars to show where the surgery has been done. Patients like it, and many would prefer it, even if the final nose is smaller than what could have been achieved by some other procedure that would leave more scars.

There are other flaps, such as naso-labial, forehead or from a distance that can be utilised. Each has their own special indications. Some races (Chinese, Koreans and many of the Asian tribal patients) normally do not have a high bridge and are happy if the nose is low and straight as long as the bridge has not been destroyed. In these people a simple post-nasal epithelial inlay as a single procedure may be adequate without any permanent support such as a bone graft. In these racial groups one needs to do the more complicated flaps and grafts less often than for those who desire a high pointed nose and a tall columella.

Figure 20-5 shows the shape of a normal nose and Figure 20-6 the cavity of the nose as altered by typical collapse.

#### **c. Severe**

In late stages, complicated by infection, the nasal bones and maxillary spine may be partly destroyed. Usually the nasal bones are still, at least partially, present. But there may be loss, usually from trauma or infection of alae, tip of nose or columella. This may require some type of flap reconstruction, to provide a new lining and external nasal skin. These may be forehead



**FIGURE 20-5** Diagram of vertical section through the normal nose.

flaps, naso-labial flaps, or other more distant flaps, or a combination of these. They usually need a structural support. Fortunately these severe deformities are relatively rare in leprosy. Many leprosy patients seeing other patients who have had the older forehead and scalp flaps that have left unsightly residual scars, request procedures with fewer scars. The "gull wing" forehead flap, in experienced hands, leaves minimal scars on the forehead and may be acceptable to the appearance conscious patient. The main need in most patients is to remove the leprosy stigma.

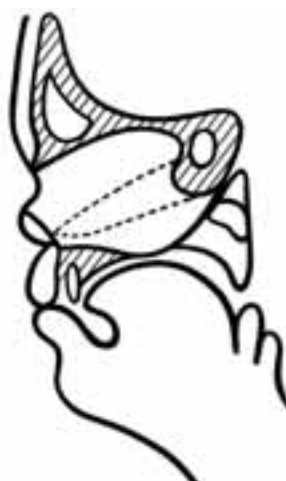*Do not attempt any major nasal reconstruction, especially using bone or cartilage grafting for any patient with dental caries or any infection of the head and neck.*

## **SURGICAL PROCEDURES FOR NASAL COLLAPSE**

### ***i. Structural Replacement - Grafting***

#### **1. MATERIAL FOR GRAFT**

When there is a definite "saddle-nose" or collapse of the ridge of the nose without marked flaring of the nostrils it may be possible to



**FIGURE 20-6** Diagram through typical collapsed nose showing distortion of anterior portion and cartilage.

insert a simple graft of bone, cartilage or synthetic material. Bone was the material of choice till the mid-1960s when cartilage came more into use. Later more synthetic materials were developed. Initially synthetic materials were frequently rejected but it appears that some of the more recent ones are better accepted. The authors do not recommend them as a routine for leprosy patients, due to high costs.

#### **A. Cartilage grafts**

Cartilage grafts can be harvested from the ear or a rib. Some consider them easier to obtain than a bone graft. It has been suggested that cartilage grafts are more frequently absorbed in children and that they do not grow with the child. Nasal collapse in children is rare but is seen in pre-teenagers. The best age to reconstruct the nose in these instances is open to controversy.

It is well documented that rib cartilage grafts can warp if not cut carefully. This particularly affects the costal cartilages of the lower ribs, which have a tendency to curl upon themselves. Gibson and Davis described a technique of cutting the rib graft so that the cartilage is less likely to curl.<sup>12</sup>

**Technique of harvesting rib cartilage:** The cartilage is often harvested from the lower ribs. The curve of the ribs needs to be carefully considered in order to obtain a piece that is long enough. Any remaining curves are acceptable in the finished nose. To prevent the twisting of a cartilage graft when in situ it is desirable that the graft should be cut uniformly. Hence it is not practical to take a straight graft out of the curve of a rib. Rib cartilage can usually be carved with a No. 10 or No. 20-scalpel blade. For a graft to extend from bridge to tip a straight length of cartilage, which can only be obtained from a larger rib, is often required. It can be cantilevered as described above and if necessary fixed as above. It will not arthrodese. The best one can hope for is marked fibrosis. Therefore make sure there is a good flat area of graft against a flattened nasal bones. Carving it to the required shape often means breaking of the usual rules to maintain the normal tension that prevents the curling of the graft after insertion.<sup>12</sup> If cartilage grafts are boiled or formalin sterilised they do not warp but are more likely to be absorbed.

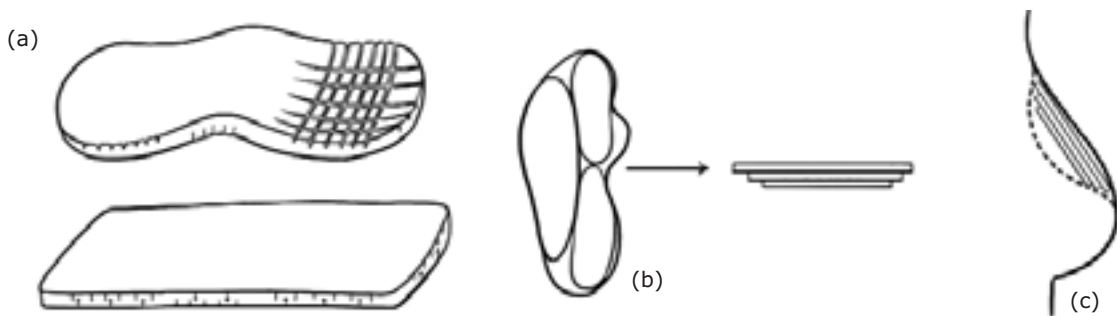
**Technique of harvesting ear cartilage:** Usually cartilage of one ear will suffice but for a large collapse of the nose both may be required. To harvest the cartilage, an incision is made just inside the anti-helix and a skin flap raised with scissors towards the external meatus. The con-

chal cartilage is then removed with the cymba, giving a butterfly-shaped graft with a maximum size of 3.0 × 2.5 cm. For minor collapse a single layer of cartilage is used but usually sandwiching several layers will give better results (Fig. 20-7b). A small piece to place in the columella for tip support is also shaped. The grafts are cut to shape. To help the graft conform to the desired shape cross-hatching at 1-mm intervals on the concave surface is performed (Fig. 20-7a). The layers are then sutured together with chromic sutures and inserted into the dorsal defect through one of the access incisions as described below (Fig. 20-7c).

### B. Cartilage and Bone

Celik states that if the nasal bones are reabsorbed it is advisable to use bone to replace them. He recommends the use of calvarium bone and cartilage grafts to provide bone for the bridge and cartilage on the nasal dorsum.<sup>5</sup> Lee et al<sup>16</sup> and Neu<sup>21</sup> report using osteochondral grafts to provide bone to replace the ridge defect and combines this with conchal cartilage grafts to provide a flexible tip.

Bone graft can be used to increase the height of the nasal bones, or replace them, and to provide for the bridge at the same time. However, it is reported to have a higher rate of absorption than cartilage especially if the arthrodese is not complete. There may also be a higher rate of infection. Reabsorption of bone takes place



**FIGURE 20-7** Chonchal cartilage grafting for reconstruction of mild nasal collapse. **a.** Cross-hatching technique to flatten the concave graft. **b.** Method of dividing cartilage to create three-layer sandwich graft. **c.** Placement of graft to fill dorsal defect.

slowly and even after it is complete there is often enough residual scar tissue to provide adequate support for the patient not to ask for further surgery. This is especially so in races with a basically low or flat nose. Some workers do not like the rigidity of the nose tip that is produced by a bone graft but we have not had any major complaints from the patients about this, and found that long-term the cosmetic results of bone grafts are good.

### C. Bone Graft

*Bone grafts* may be taken from the top of ulna, front of tibia or calverium. The anterior part of the iliac crest provides a good graft that is a mixture of cancellous and cortical bone and is easily carved to shape in situ. It can be taken under local anaesthetic with general sedation. Once the path for the graft is opened and the length of graft is determined it is possible to select a section of the anterior half of the iliac crest which has an appropriate shape for the dorsum. Unfortunately, a bone graft can be fractured during trauma and a different deformity result. However such a deformity will not usually carry the stigma of a leprosy nose. If a columella strut is added, it increases tip rigidity, but breaks easily. I prefer to cantilever a bone graft off the nasal bone carefully shaping both surfaces so that no columella strut is required.

### D. Synthetics

There is now a trend to using synthetic materials for nose reconstruction. Boyce and Toriumi discussed various synthetics and compared results obtained by their use with those obtained by autologous materials.<sup>2</sup> Motoki also discussed the pros and cons of various materials and the rate of absorption.<sup>20</sup> Early synthetic grafting materials were frequently rejected and hence the tendency to use autologous materials. Silicone rubber has had extensive use with good results.<sup>23</sup> It is non-porous and there is

therefore a tendency to capsule formation and risk of migration infection and extrusion. Good results have been reported using polyethylene implants in saddle nose reconstruction.<sup>26</sup> It is porous and has a low rate of extrusion or infection. However given the risks and costs with synthetics, autologous materials are still strongly preferred by these authors.

## 2. THE TECHNIQUES FOR SURGERY

### A. Preparation of nose for grafting

The whole nose area must be well infiltrated with local anaesthetic, containing adrenaline. The nostrils are packed to prevent contamination of the surgical area, and prevent any blood from tracking down into the throat. This is especially important if the surgery is being done under local anaesthetic. The authors do all nose reconstruction under local anaesthesia with sedation. It is much easier to ensure correct positioning in relation to the rest of the face, when there is no need of anaesthetic tubes obstructing the view or distorting the mouth or nose. It is advised to give broad-spectrum antibiotics preoperative and to continue for 5-10 days post operation.

### B. Approach for insertion of graft

Many incisions have been devised:

(1) *Through the columella, midline.* We prefer this approach. The midline incision is made along the whole length of the columella and the edges are retracted using fine skin hooks. The suturing can be done from side to side so that there are no suture scars on the columella itself.

(2) *Through one nostril.* Use an inter-cartilaginous incision, so that the scar is not external as it would be on the columella. The incision is made on the septum about 4-5 mm inside the nose. The tissues are dissected care-



fully to make a track that goes midline to the tip of the nose and then up the ridge as for the standard method. It is less convenient if a columella strut is required. Beware of suturing under tension.

(3) *Through the mouth.* This requires tunnelling up the columella and then angling to get into the nose. Hence this is a less easy approach for inserting the graft and it is difficult to maintain sterility as the work is through the mouth cavity. This is not recommended for regular use.

(4) *Over the root of the nose.* This makes it easier to achieve bone fixation of the graft to the nasal bone to ensure arthrodesis.

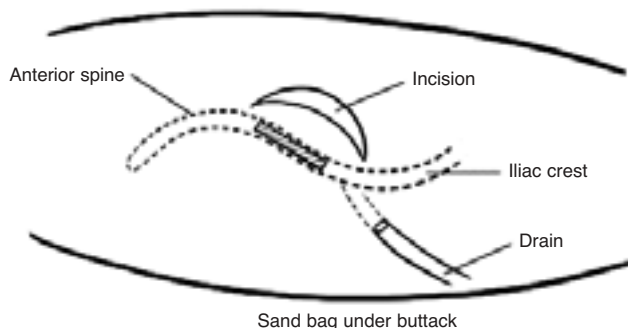
**Technique:** Make a large inverted V incision over the glabella so the point is midline mid-forehead and the arms of the incision extend well down on each side of the nose bridge. The incision ought to almost reach the eyebrows laterally and terminate distal to the medial canthal ligament and well out towards the cheek. The flap is elevated at periosteal level and the nasal bones can be flattened under vision. The Metzenbaum scissors are passed down towards the tip till all the area to be elevated is freed. The bone graft can be fairly large over the bridge of the nose and slimming down towards the tip for ease of insertion. The nasal bones are chiselled flat and then the graft fixed as described later. The forehead skin flap can be used as an advancement flap to allow the skin over the bridge to be stretched laterally to fill any defect on the lateral sides of the nose. Because of the easy vision it is possible to remove more of the nasal bones to flatten them so that the graft is not so prominent and the final bridge may be no higher than the original. However, if the patient has a prominent forehead the insertion of the graft could be very difficult.

### C. Surgical procedure for insertion of bone graft

**Nasal Dissection:** Using Metzenbaum long thin curved scissors, a track is carefully prepared from the tip of the nose up to the root of the nose. Do not tunnel through the skin itself. Make sure there is enough skin above the scissors so that the graft will be adequately covered, but on the other hand, try not to puncture the mucous membrane into the nose. If this happens infection of the graft is very likely to occur. An infected bone graft in the nose is a tragedy, as it will usually need removal. At the best it will result in a reduced cosmetic result. At the root of the nose the scissors are directed onto the nasal bones, which are rarely involved in leprosy. A small chisel (3-4 mm size) is inserted and used to elevate the dorsal periosteum and to break up the upper table of the nasal bones to encourage arthrodesis. It is sometimes possible to elevate the whole of the upper table in one piece with the periosteum intact so that the graft can be driven between the two pieces. If this can be done it provides excellent stability. Otherwise strip the periosteum off the bone until the frontal bone is reached and then chisel a notch in the frontal bone where the graft can be wedged. Widen the soft tissue track to make it large enough to take a Kockers opened so that the space is about 1 cm wide and 1 cm deep. Measure the length of bone required and allow an extra cm. for handling when cutting the bone. Pack the space in the nose with ribbon gauze to obtain haemostasis, while the bone graft is taken from the iliac crest.

**Technique for taking Iliac crest:** The iliac crest is prepared as usual, with a sandbag beneath the side to be operated upon to make the crest more prominent. The iliac crest needs to be carefully examined to determine the site from the best shape of bone graft can be obtained. This is usually on the anterior half, but preferably not touching the anterior iliac spine. At the selected site a curved incision is made, on

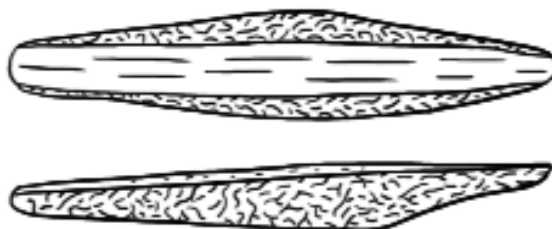
the soft skin just above the iliac crest with the concave side to the crest. The ends of the incision are 1-2 cm above the iliac crest so the scar will not be irritated by the belt rubbing it against the iliac crest. The incision will be about 10-15 cm long starting on or just lateral to the anterior superior iliac spine, depending on the site chosen to take the graft (Fig. 20-8).



**FIGURE 20-8** Diagram of where to take the graft from the Iliac crest. Note that the hip is elevated on a sand bag to make the crest more prominent. The iliac crest is marked as broken line and graft to be removed is hatched. Avoid area directly adjacent to Anterior Iliac spine- incision curved concave to the crest behind the spine will cause less long term discomfort. Exit the drain well below the suture line.

A piece of bone at least the required length of the nose, preferably 1 cm longer about 8-10 mm in width and 3-5 mm in depth, is cut out of the hip. It is necessary to ensure that the right shape is selected to give the nose a natural contour. Some workers like to use a piece of periosteal covered iliac crest but it is not always possible to get it straight enough or with a suitable curve. It is highly desirable to be familiar with the local ethnic variations in nose shape! It is easiest to achieve the basic shape of the bone in situ, and while still on the hip it is relatively easy to straighten the sides and smooth off any irregularity on the dorsal ridge that may otherwise end up as a bump on the dorsum. Once removed "fine tuning" can be done.

If the crest is very curved and it is not practical to obtain a relatively straight piece, while in situ, cut the upper edge of the graft flat without including periosteum. A certain degree of shaping can be done with the bone nibblers and a large flat rasp after the removal of the graft from the donor site. The rough edges need to be filed away so the graft can be slid into the cavity already prepared (Fig. 20-9).



**FIGURE 20-9** Diagram of bone graft ready for insertion, (Permission by Fritschi).<sup>11</sup>

If the patient requires a nose with a very high tip, it may be advisable to use a columella strut. This can be cut in one piece so that an L shaped block of bone is removed from the hip, this is more difficult, or a separate columella strut can be cut, preferably from at least partly cortical bone. It is more difficult to stabilise a separate columella strut and many people prefer to use an "L" shaped block. However, the authors find that with an adequate cantilever a columella strut is not necessary. This then leaves the columella more supple than when a strut is inserted into it. Even for those needing a long columella it is usually possible to achieve a high tip by an adequately angled cantilever. To assist in holding it in position the nasal passages are packed, not so tightly that ischemia of the nasal mucosa will occur, and the packing is not changed for seven to ten days.

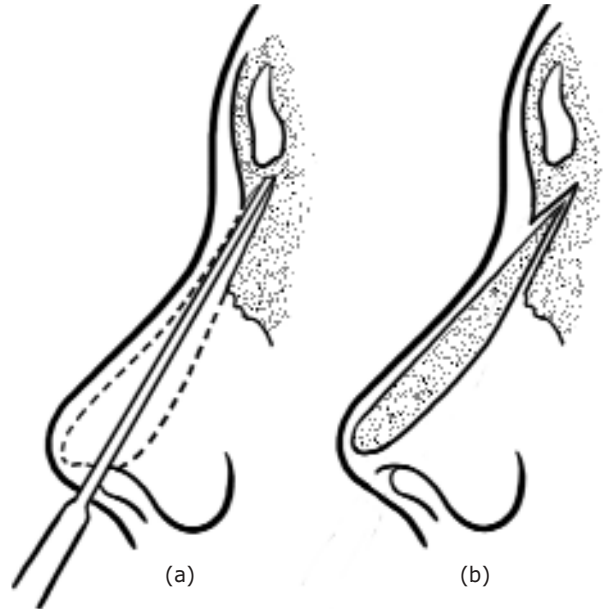
The iliac crest wound is closed, paying special attention to closure of the periosteum and/or muscle in layers over the bone deficit and draining the bone cavity. It is advisable to

use a drain for the first two days to prevent a haematoma. A dressing in the form of an abdominal binder makes the patient more comfortable and the knee of the operated side should be flexed, with the leg on an elevated pillow, during the first few postoperative days.

**Insertion of bone:** The bone graft is trimmed to size and the upper end is bevelled so there is cancellous bone to arthrodese to the nasal bones. Also the upper edges, that will lie along the ridge, are rounded off so the final nose in twelve months time will not continue to look like a rectangular block. If the bone has been cut longer than is needed, the lower centimetre can be used for holding it in a Kockers or large toothed dressing forceps, while inserting. It can easily be nibbled off when the graft is in situ and final length determined. A pair of nasal packing forceps, long armed nasal speculum or the kidney clamp mentioned above, are extremely useful to separate the edges of the track while the graft is slipped up between their blades. Once the graft is in situ, smooth the skin down as far distally along the graft as possible to make the nose as long as possible. At the same time, push the graft as far proximal as possible to jam the bevelled end under the bone flap or into the hole in the frontal bone, whichever is used (Fig. 20-10).

The length of the graft should be adjusted so that there is no real pressure on the tip of the nose, and so that the columella incision can easily be closed over the bone to minimise the risk of infection entering by that route. If the graft is well bevelled and the nasal bones have been flattened and denuded of periosteum the graft should be stable without special fixation.

A *columella strut* may be inserted if the bone feels unstable over the nasal bones, and/or the patient asks for a high tip. For this a track is prepared directly down through the columella to the maxilla and a notch cut out of the maxilla into which to slip the graft. If the bone graft is an L shaped piece this can be a little more dif-



**FIGURE 20-10** Diagram of nose grafting **a.** a small chisel has been driven up into the frontal bone so the graft can be wedged into the space. **b.** The bone inserted the wedge on the top of the graft cantilevers the bone off the nasal bones (*Permission from Fritschi*).<sup>11</sup>

ficult getting it into place, but once in situ it will be more stable. If it is a separate piece, it is easier to insert, but needs to be wedged in to an indentation made on the under side of the long piece of bone that forms the ridge of the nose, near the point of the nose to hold it firm.

**Fixation of graft:** If the cantilever is well shaped it should be stable and no other means of fixation is needed. However, fixation may be provided by:

*a) A piece of 2x0 braided nylon.* This can be utilised to stabilise the graft.

A piece of thread is anchored to the medial end of the canthal ligament on one side of the nose, and passed across the nose above the bone graft but under the skin then anchored on the canthal ligament on the other side similarly and then passed back lying parallel to the first thread, to be tied at the initial bite of canthal ligament. This provides a loop over the new

nose bone that should stabilise it, at least till fibrous union or ankylosis occurs. If carefully inserted the knot can be buried and it never needs to be removed, unless it causes problems later. The intranasal pack is still used, post operatively.

*b)* If there are good quality nasal bones, a small drill hole can be passed from side to side through them and a nylon thread passed through that and then tied over the top of the graft, similar to that just described, to fix it firmly to the nasal bones. The thread does not need to be removed.

*c)* It is possible to thread a *Kirschner wire* the full length of the bone graft from the tip and drive it about 5 mm into the frontal bone. It is usually cut off short at the tip so never removed.

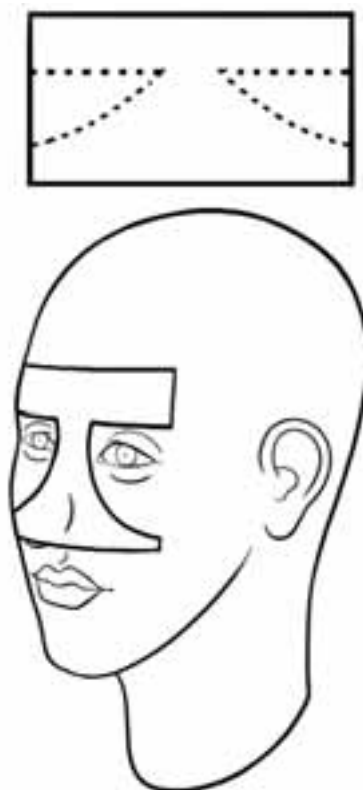
*d)* A *short Kirschner wire* can be driven at right angles to the graft through the graft into the remains of the nasal bone. If this can be cut flush with the nose that is good but if it is not cut flush it can be removed in about 10-14 days when all swelling has settled. It may be better to expect to remove it especially if there is any doubt about the depth to which it was inserted and any risk of infection ascending from the sinuses or postnasal space.

*e)* With the forehead nasal base incision is may be possible to drill holes into the nasal bones and wire the graft onto the bones, as described in "a" above, or to use a *Kirschner wire* that is driven the whole length of the graft so it protrudes distally and then when the graft is in place reverse drive it in so a known length is in the frontal bone. Make sure it is cut short distally, but this may require an incision at the tip to cut it.

#### D. Post operative care

After insertion of the bone, the columella is closed using mattress sutures that go from

inside one nostril across to the other nostril, and back, everting the cut edges, so no suture marks are made on the skin. If an intra-nares incision is used the edges need to be accurately approximated to ensure no tension. The packing that was initially inserted in the nostril is removed and inspected. If there is evidence of the mucosa being broken the nose should be packed with a layer of Vaseline gauze first and then routine saline soaked gauze to fill the nasal cavity, in all cases. The saline-soaked gauze is basically to prevent the development of a haematoma and to stabilise the bone graft so it is not displaced during the postoperative swelling. Do not pack so tight that it will cause necrosis of the mucosa. Use a spray on dressing over the columella incision- or Tincture Benzoin Compound to seal the wound. A plaster of Paris shield is made to protect the nose from trauma (Fig. 20-11), and a piece of gauze



**FIGURE 20-11** Pattern for plaster of Paris nose shield, and diagram to show its placement.

used to cover the incision on the columella. The plaster shield should be designed so the eyes are not covered. Initial attachment of this shield can be made using adhesive plaster, which will stick to the wet plaster if the plaster is first painted with Tinc Benz Co. Tinc Benz Co will also help stick the adhesive plaster onto the skin. Then a good firm bandage (cotton crepe or gauze not elastic) is placed around the head to keep a firm pressure on the whole nose, and reduce the swelling that could displace the graft.

The face and eyes will be very swollen for 3-4 days. It is advisable to use antibiotics for 5-10 days to cover this procedure. The longer duration is for patients in whom it is thought that there may have been a breach in the nasal mucosa. Antibiotic eye drops such as Chloramphenicol, should be inserted 4 times daily even if the lids will hardly open. The firm bandage is not changed for 3-4 days, by which time the worst of the swelling has subsided after which the plaster protector is held into place by adhesive plaster, and worn all the time for 6 weeks. The small skin sutures can be removed after 5-7 days. The plaster shield is worn at night or if out in crowds or other situation where trauma could occur, for 3 months to prevent accidental displacement of the graft from pressure or trauma. About 10 days after surgery, the plaster shield can be remade with tapes or elastic to tie it round the head. Keep a close check on the face for signs of postoperative infection and, if in doubt, continue antibiotics, or preferably change the antibiotic.

After cartilage grafts it is advisable to pack the nares and use the nose guard, and give antibiotics as described above. Cartilage will not break as bone does when impacted during direct trauma, but in the early stages can still be displaced by a blow.

## **ii. Post Nasal Epithelial Inlay (PNEI)**

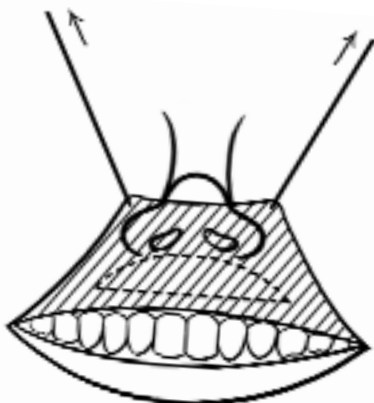
For the patient with marked scarring of the mucous lining of the nose, it is necessary to

replace the whole lining. The basic surgery is still the same. The Post Nasal Epithelial Inlay provides adequate lining for the patients with normally low noses who do not require a high columella, especially if they are happy with the height of their nasal bones. However, as the split skin graft is placed on minimal subcutaneous tissue it is difficult to get a bone graft between the skin graft and the dorsal skin if a straight ridge is desired. There are other methods of providing lining to the nose but I (GW) find that this inlay is simple and effective for selected patients.

### **Technique of PNEI**

The whole face must be prepared including the inside of the mouth. We paint the gums, lips and teeth with Gentian Violet before the incision is made. Gentian Violet does not taste as bad as cetrimide and helps to define the mucosa edge during suturing. The nose cavity is packed as far back into the postnasal space as possible so that blood will not trickle down the throat but also so the cavity itself can be worked upon and grafted. The whole area is infiltrated with local anaesthetic. Most patients do not require a general anaesthetic if well sedated initially. The incision is in the upper sulcus of the mouth extending to just beyond the fourth tooth on each side (Fig. 20-12). Using a curved dissecting scissors, dissect straight down to the periosteum of the maxilla and keep at that level for the whole of the dissection. The muscle fibres are then elevated off the bone with minimum bleeding. A diathermy is used for haemostasis. When the tissues from the maxilla have been elevated it will be possible to open into the nose itself. Try and cut the mucosa as far back from the external nares as possible. It is best to leave normal skin in the nares where grafting would be very difficult. After that, the septum, if present, can be split well back, so that a small part of it remains in the posterior aspect of the nasal space, but the

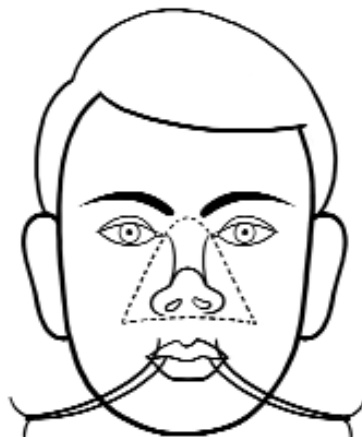



**FIGURE 20-12** This diagram shows the naso-oral fistula extending to level of 4th tooth on each side and the upper lip elevated by a black thread on each side.

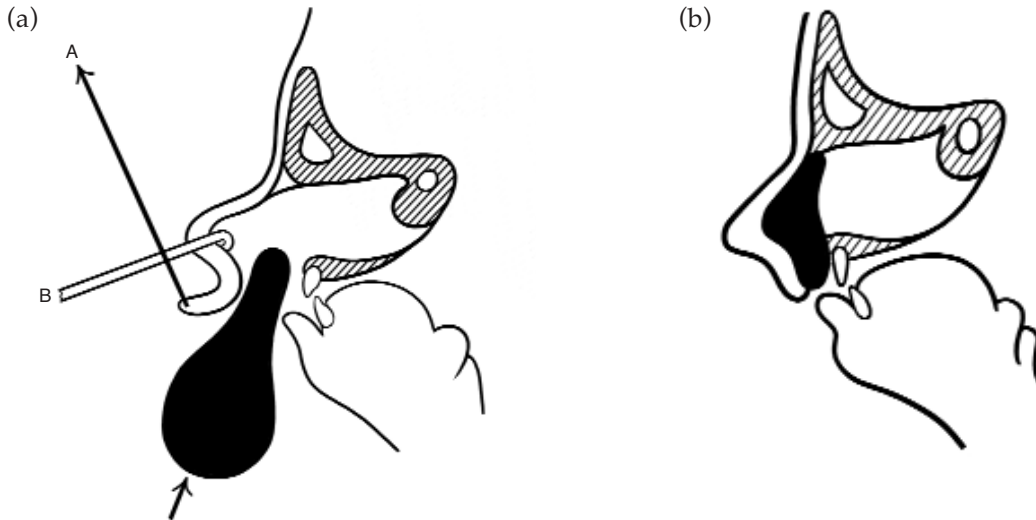
back of the columella is still complete. This helps to maintain the stent in position. The dissection is continued until the whole of the nose is freed from the maxilla up to the nasal bones. The area that is elevated from the face is shown in Fig. 20-13. However, stay beneath the nasal bones, not above them, especially if they are basically normal. This will make it easier to elevate the tissues off the nasal bones if a bone graft is required at a later date. The mucosa must be cut right round the nasal cavity, distal to the end of the nasal bones, and connection with the incisions along the maxilla, to completely free the dorsal skin and lining from the maxilla. The periosteum is not removed from the maxilla.

When adequate haemostasis is achieved a stent is made from guttae percha. The stent needs to over-stretch the skin of the nose as far as possible and extends into the mouth to keep open the full width of the naso-oral incision so that the stent can be removed via this route at a later date. The black gutta percha is the ideal material (see later). Once the cavity is prepared the guttae percha is moulded into a roughly pear shaped mass that will over-fill the space created, and is forced into the cavity. It is

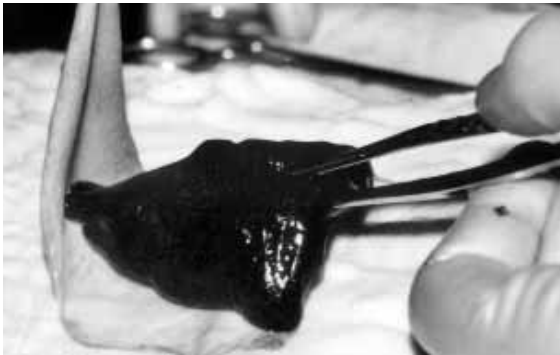

**FIGURE 20-13** The hatched area indicates the area of the face to be elevated for the PNEI. The two silk threads through the upper lip, one on each side, serve as retractors and provide counter traction, during dissection.

moulded with the fingers so that it overlaps the maxilla on each side of the nasal cavity and stretches the dorsal ridge as long as possible to make the tip as high as possible. To achieve this, use a blunt hook or small bladed retractor through the nares and an assistant pulls the nasal dorsum as long as possible while the surgeon moulds the guttae percha into the desired shape (Figs. 14a and 14b). It is only by making the nasal ridge as long as possible i.e. stretching the nose to its maximum length, to make the tip as high as possible, that the final angle in (6 months time) between the columella and the upper lip will be adequately small. A large angle may produce a nose, the lower end of which appears almost like a snout. Once the stent is made use sterile ice, on the outside of the nose, to set it firm. While it is setting obtain a large piece of split skin graft, preferably from a non-hairy donor site such as the thigh. Then practice inserting and removing the piece of guttae percha. The stent is then draped with the piece of split skin (Fig. 20-15) with the raw surface outside so that when the skin draped stent is replaced in the nose, the skin will grow



**FIGURE 20-14 a.** A vertical section through the nose during surgery for PNEI. The guttae percha (filled in-black) is being forced, as indicated by the arrow, into the cavity in order to fill it completely. The arrow "A" indicates the direction of pull of the two black silk threads elevating the upper lip. The arrow "B" is the direction of pull on a small flat bladed retractor under the top of the columella, used to stretch the nasal ridge to its maximum. The cranium and hard palate are marked with hatching. **b.** Shows the guttae percha in the nasal cavity. It reaches up till just under the nasal bones at the top and rests on the maxilla at the bottom protruding into the mouth, distending the upper lip. It should lie on the maxillary bones on each side and not protrude any further backwards.



**FIGURE 20-15** The black guttae percha stent has been allowed to set with the assistance of ice. It is now being draped with SSG ready for insertion. Note the height of the lower end that will occupy the naso-oral fistula. It is being held by a large toothed forceps to make handling easier.

on the raw inner surface of the nose and become its new lining. Avoid hair-bearing skin, as it has been known to grow, and may then need removal.

Once the skin covered stent is placed into the nose the operation is finished and the only dressing necessary is a little Vaseline gauze in the external nares and a piece of dry gauze on the outside to prevent flies and secondary infection. The immediate post operation appearance appears very gross with a markedly stretched and elevated upper lip, pushed out by the stent. The stent must be kept as thick as possible between lip and maxilla, as shown in Fig. 20-15, to enable the stent to be inserted and removed. The donor site for the skin graft is dressed as usual. Swelling can be reduced post-operatively by the use of ice bags, over the face, around the nose, for the first 48 hours.

#### Use of Guttae Percha

When guttae percha is being used in the operation room, boiling water, sterile ice, and cold water are necessary. To make sterile ice water, sterilise a metal screw top container and fill it

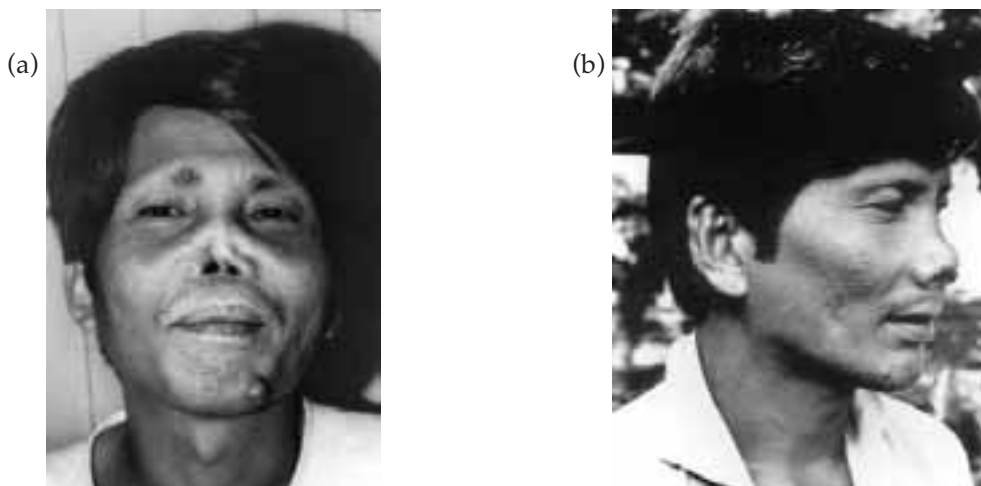
with sterile boiled water and freeze the whole in an ordinary refrigerator. When it is needed the scout nurse can unscrew the top and tip the ice out of the tin into a sterile bowl on the scrub nurse's table, where a hammer and chisel will be needed to break it up! If sterile ice in a plastic bag is placed over the nose with the guttae percha in situ, while the skin graft is being taken, it will help to make the guttae percha firm and also control bleeding.

Gutta percha is the ideal material to use. It can be sterilised prior to use, by soaking. It is easy to soften with very hot water and sets again relatively quickly after which it can be carved with a knife if needed. It can be reheated and reshaped. It has an elasticity and will not break if dropped. The black guttae percha is more adaptable than the pink dental gutta percha. It is not the same as the easily available red type. Dental impression material is not so easily mouldable. It cannot be carved with a knife, so minor adjustments needed during use are difficult. The same guttae percha stent can be used for as long as a stent is needed. Either material can be replaced later by an acrylic or other material such as is used for dental plates. In some patients because of the difficult in

inserting bone between the nasal skin and the skin graft, it may be best if a PNEI is followed permanently by a nasal stent. This is recommended by Antia.<sup>1</sup> This can be attached to an upper denture utilising the naso-oral fistula created at the initial surgery.

### Postoperative care

After the post nasal epithelial inlay has been completed, the stent is left in place for ten days to allow good healing of the graft. It is then removed via the mouth. It is best if the surgeon or his assistant is the one who initially changes the stent. The area inside the nose is cleaned with simple saline to remove any excess skin that will now be dead. It is usually well healed and the stent is replaced at once (Fig. 20-16). It is important that the stent not be left outside the mouth for more than a few minutes. The cavity can shrink at an amazing rate. Do not try and make a new stent at an early stage, as that will require too much time and contraction of the cavity may occur while it is being done. If there are any obvious rough areas or protruding areas that may traumatise during insertion and removal these can be removed with a scalpel and then smoothed off by a short soak



**FIGURE 20-16 a.** Marked deformity of the nose tip with average midnose contraction treated by PNEI. **b.** Same patient after 6 months. Note the nice curve of the nose and that the contracted nostril has been completely released.

in very hot water. Over the next few weeks it may be necessary to do this on many occasions if areas are taking excessive pressures. After 3-4 weeks holes can be drilled through the stent so the patient can breathe through the nose. The stent can now be replaced daily, initially checking for healing and to see if the stent needs to be modified, for ease of application. Do not make it too small or it will not do its job! Patients say it is uncomfortable but not really painful and becomes painless after the first few weeks. But later change twice weekly, or weekly as necessary, depending on the cleanliness of the nasal area. Many patients learn how to do it themselves. However, if the area is clean and well healed, then the patient can be taught to rinse his nose out by using saline sniffs daily instead of having the stent removed. This is very useful for patients with bad hands who are not able to handle the stent, and is safer when the patient goes home. It is not recommended that a removable PNEI stent be used in patients with very bad hands who will live at home where no one is available to help them.

The stent must be worn for at least three months until all contracture of the skin and soft tissue has ceased. By that time the stent will be considerably smaller and the upper lip will not need to protrude so much, and the nose will have quite an acceptable shape. Then it can be considered that the patient will be ready to have the bone graft inserted into his nose, as previously described or to have a permanent prosthesis made. If a bone graft is later inserted, about 3-6 months after the PNEI, the surgeon must be careful not to puncture the skin graft, which is rather thin, but it is usually quite possible to get a slim graft into position without damaging the skin graft. Some patients seeing the appearance of the nose about 3-4 months after surgery, with the stent in, decide that they will not have a bone graft added. Some patients prefer to use the permanent prosthesis, which may be fixed to an upper

denture to provide support to the stretched nasal skin. A dentist should be able to make this, inserting a thin nasal supporting prosthesis through the naso-oral fistula. Some patients decide that the nose is "good enough" without any support. If they are not going to have a graft or dental support they ought to wear the stent for a total of 6 months to be sure there will not be and significant skin contracture (Fig. 16 a & b).

Long-term patients have been seen who abandoned the stent after 6-12 months leaving the nose hypermobile, but in whom no further contraction occurred and the nasal shape remained satisfactory for up to five years! These would be patients who only require a low nose and in whom the original contractures were not very severe. They may ask for the naso-oral fistula to be closed which is a good idea.

### **iii. Crockett's Operation**

A combined operation was devised by Crockett.<sup>11,17</sup> The PNEI dissection is done in basically the same way but then is modified so that the bone graft is inserted at the same time and chips of cartilage are used to fill the space around the nasal bone/graft junction. The initial oral incision is made so that it is on the lip side of the sulcus leaving a flap of oral mucosa on the maxilla that can be used to close the naso-oral fistula at the end. The skin graft is still used but not draped over a stent, so is more difficult to insert. It is also more difficult to ensure the area is fully clothed with graft and all the graft is kept in contact with the recipient area.

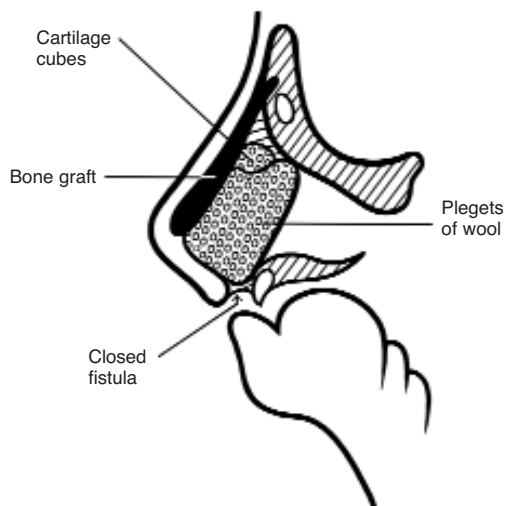
### **Technique**

The operation is commenced as for the PNEI with the difference in the raising of the flap of oral mucosa as mentioned above. Once the cavity is ready take a large piece of medium thick-

ness SSG and fold it over and sew the sides together with chromic cat gut to make a bag that is a little longer than the desired length of the finished nose and one cm wider than the nasal cavity in the maxilla. A slim bone graft is cut and used as described above, inserted above the nasal bones, preferably by driving a wedge into the frontal bone or under a flap of anterior nasal bone or periosteum as described previously. The graft must be narrow because a wide graft will not allow the growth of the skin across the bare bone. The graft needs to be cantilevered as described previously. The upper part of the nasal cavity, just behind and adjacent to the nasal bones, is packed with small cubes of cartilage (1mm cubes). Then the skin bag is filled with small pledgets of cotton wool soaked with Chloramphenicol 2% solution and well rung out. The bag is inserted into the nasal cavity with the open end towards the mouth. Further pledgets are added to ensure a firm packing that will give good contact between skin and bone and cartilage. This is a difficult stage as adequate packing is needed to obtain adhesion of skin but if excessive pressure is applied the SSG may slough. The bag is sutured closed and then the naso-oral fistula is closed in layers with vicryl making sure all sutures are buried (Fig. 20-17).

After the columella incision and the oral incisions are closed the nose is moulded by the surgeons hands into the desired shape and covered with several layers of gauze before a nose guard of plaster of Paris is made and moulded to maintain the desired position. The moulding of this plaster is important to prevent a changing of shape immediately post operative when swelling occurs. The nostrils are covered with a piece of gauze that will be removed daily to clean the external nares.

Antibiotics are given for 5-10 days. The face generally will be very swollen. Antibiotic eye-drops are given four times daily. At 10-12 days the skin bag at the anterior nares is ruptured and the pellets are carefully removed and the



**FIGURE 20-17** Diagram to show lateral view through a nose after a Crockett operation. The solid filled-in area is the bone graft wedged into the skull bones which are hatched. The small squares are the pieces of cartilage up under the graft and nasal bones and the small rings are the plegets of cotton wool filling the bag made of SSG. The naso-oral fistula has been closed over the skin bag.

cavity cleaned, through the nares. If practical, open the posterior nares by puncturing the skin bag. Then repack the cavity with ribbon gauze soaked in Chloramphenicol and paraffin and leave in situ for another 3-4 days. After its removal the patient learns to hold saline in the cup of his hand and sniff it up, and spit it out, to wash the inside of the nose, to keep it clean. Tovey<sup>25</sup> recommends the plaster splint be discarded after 2 weeks but I prefer the patient to use a nose guard all the time for 6 weeks to 3 months as described above in the standard bone graft protocol.

This technique can be quite effective but is more likely to result in secondary complications if infection results. The fact that the skin grafts do basically take over cartilage and bone is of great interest. In a very severely contracted nose it is preferable to use the PNEI first and hence it becomes a two-stage procedure.



Certainly the novice should not attempt a one stage "Crockett's" until he has had some experience in dealing with the problems that may occur from each of the procedures used alone.

#### iv. Naso-labial Flaps for Nasal Lining

Nasolabial flaps depend on the nasolabial vessels and so can be made much longer in comparison to the width than is normally possible for direct transferred flaps. There are several techniques described.<sup>10,11,15</sup> These flaps are used to create lining of the superior nasal cavity in the presence of moderate to severe contracture.

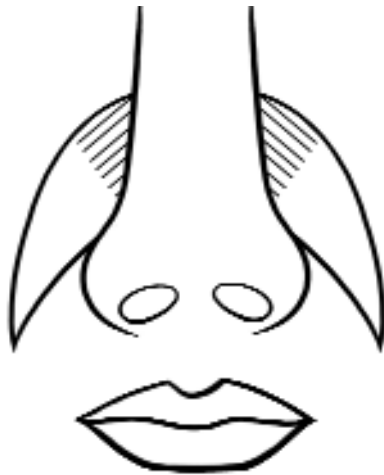For lining the nose it is recommended that superior based nasolabial flaps be used. Because of the excellent blood supply they can be up to 2 cm wide. The surrounding skin can be undermined and the defect closed without tension or deformity, giving the effect of a mid-face face-lift. With careful surgery when lining the nose it is possible to completely close the area of deficiency so that the bone graft can be placed in situ at the same time as the new lining with less risk than with a Crockett procedure.

There should be no need for a free skin graft.

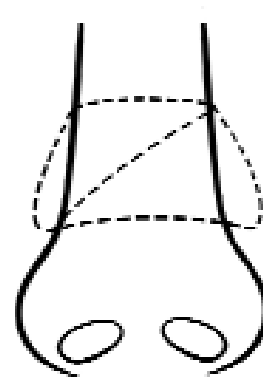
#### Technique of Naso-labial flap nose reconstruction

Carefully check the patients skin. If the patient has had severe Type 2 reaction and there is a lot of scar of the nasolabial skin it is possible that the blood supply will not be adequate and another method of reconstruction should be considered.

The classical method of doing a nasolabial flaps for full nasal reconstruction is to turn the flaps in to reline the nose without freeing the alae. This can be a little difficult but in many noses it is possible. The standard skin incisions are shown in Figure 20-18a. The nasolabial flaps are raised, from distal to medial, raising them at the level of deep fascia. They need to be long enough to go right across the nose to line the dorsum. Use a heavy silk thread through the tip of each flap, to hold and control and move the flaps. If the tissues are thin it is advisable to take muscle in the flap near the nasal end. These flaps are raised till they can be



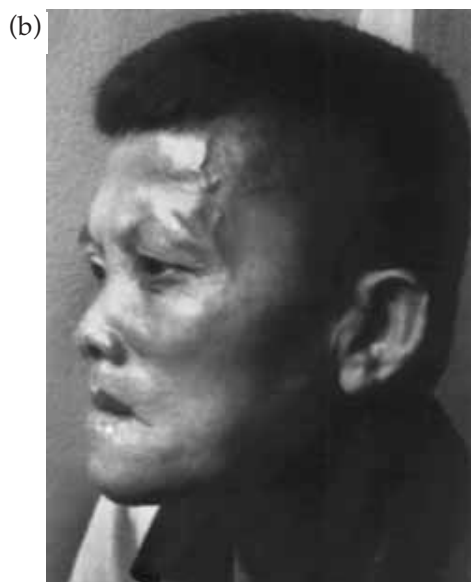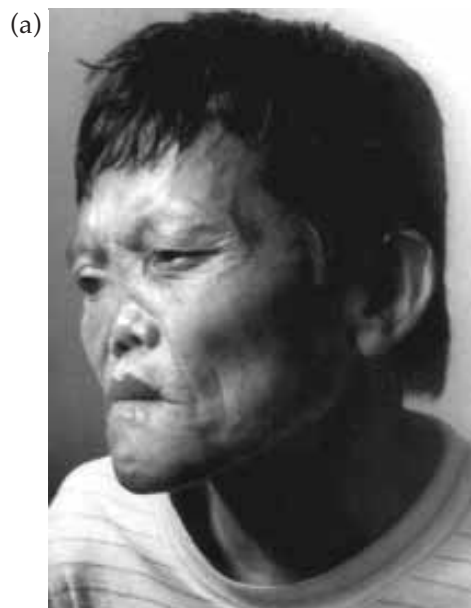**FIGURE 20-18a** Diagram of Nasolabial flaps. Note that the hatched triangle near the nose on each side will be de-epithelised in order to obtain attachment for the flap which will be the new lining.



**FIGURE 20-18b.** Diagram to show how the flaps are folded beneath the skin. Suturing is difficult but can be done by using the two black threads to pull the graft out to one side and then the other during suturing. There is no need to suture the upper and lower incisions between the transplanted skin and the mucosa. As long as there is adequate width. The skin elevated during de-epithelisation can be sutured back to fill any gap beside the nose.

passed through an incision that opens, at the level of the maxillary periosteum, into the nasal cavity from the root of the flap so that the flap turns through 180 degrees to go into the nasal cavity. Through this small incision remove any septum that is directly in the line of view so that the cavity will not be blocked by the flaps when the two flaps are inside. The mucosa is cut from side to side across the bridge and freed as far as necessary to achieve a good external shape with a straight dorsal ridge. Estimate the triangle of epithelium on the flap, shown by hatching on the diagram, that will not be making the new cavity lining, usually about 1–1.5 cm. De-epithelise that, leaving it attached to the nose initially so that it can be used if necessary to close the nasolabial incision after the flaps are turned into the nose. The de-epithelised area will come to lie in the tunnel created into the nasal cavity. Then pass the two flaps through using the threads in their tips and line the flaps up so that they lie flat, side by side. Mark the point where the end of one flap lies against the other. Then pull first to one side and then to the other to suture the two flaps together to make a continuous lining for the mid-nose with absorbable sutures. Figure 20-18b shows the way the de-epithelised flaps turn under and the epithelium can fill the triangular gap beside the nose. The two flaps then cross inside to replace the lining, and are sutured. When the flaps are sutured together, centralise them and suture the incisions on the side of the nose. These flaps alone may give an adequate cosmetic result, especially in ethnic groups with a flat nose (Fig. 20-19). Bone can be inserted at the same time, but it is safer to leave the bone graft for at least 3 months or till fully healed.

The area where the flap turns under often tends to leave a widened area, spreading the bridge of the nose outwards onto the cheeks. The extra skin and fat can safely be removed at 3 months.



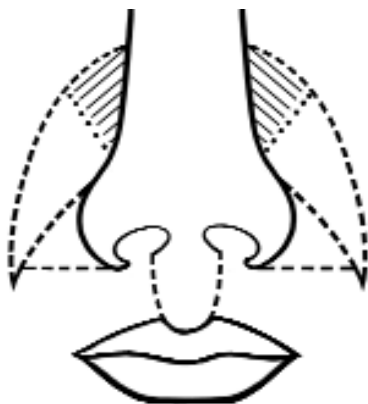
**FIGURE 20-19 a.** A typical depressed nose with flared nostrils, and marked nasolabial folds. He is still in his twenties but looks older. He still has a good nasal bridge.

**b.** Same patient after Nasolabial flap correction of depression. The flaps have achieved a mid-face lift. The nose maintained a good contour without a bone graft. He looks years younger.

### Modification of Farina's procedure

If the nose is badly contracted and/or a high tip is desired it may be better to do a full three-flap naso-labial flap reconstruction.

**Technique:** The skin incisions are shown in Figure 20-20, with three flaps to be raised. Note the third flap extends from the columella onto the filtrum and it will allow some lengthening of the columella.



**FIGURE 20-20** Skin incisions for a Modified Farina procedure. Note that the hatched portion will be de-epithelised. The alae are raised with good bases for easy reattachment. The whole nose can be turned back at midlevel to allow dissection and attachment of the bone graft under vision.

The lateral flaps are cut so that they can be crossed as described in the standard naso-labial flap reconstruction. The filtral flap is made about 1 cm beyond the columella removing a thick piece of upper lip that can be closed as a V-Y scar if the columella needs to be lengthened. The point of each flap should have a black silk thread for easy control and movement, without constantly being gripped by forceps. The whole of each alar is raised down to deep fascia with a triangle of skin attached to make it easy for reinsertion. All flaps are raised down to deep fascia and the mucosa is cut along the edge of the nasal cavity. If the septum is intact cut it about 0.5-1 cm inside the nose and leave adequate mucosa in the external

nares so it can be sutured back into place. Cut the mucosa across the midline from side to side, as the mucosa will be lengthened by the side flaps turning in. This will release the nose. The nose can then be turned back on its base and if bone is to be inserted the nasal bones can be prepared under vision to take a cantilevered bone graft of good size.

Turn the two lateral flaps over the raw area of the ridge of the nose and suture them with buried Vicryl (3x0 or 4x0) sutures. Then suture the flaps to the mucosa so that the lining is now complete. The bone can be inserted from the side and then the nose placed correctly and all the skin incisions closed carefully. By cutting the alae flaps large it should be easy to realign them and to close the flaps making sure the lining is closed before attempting to close the superficial tissue and skin.

The cavity is packed with gauze soaked in acriflavine emulsion or similar. A Plaster nasal protector is made as for other nose bone grafts. Antibiotics are given as usual. The packs are removed in about 7-10 days and the nose checked inside. If well healed there is no need to repack again. If there is any open area or an unhealed area it needs to be packed twice weekly with antibiotic ointment until healed.

The modified Farina's flaps do take more time to do than the PNEI but should give a better final result for the patient who requires a high tip and straight ridge to his nose, or when a badly contracted or deformed tip is present.

### v. Forehead flap

With most nasal defects, the skin is sufficient in itself for nasal reconstruction. In some long-standing cases or where the infective process has destroyed part of the skin covering of the nose and the underlying bony/cartilage framework, some skin from a distant site is required. For this the ideal flap is a paramedian forehead flap. As described by Burget and Menick it can be used to cover the dorsum, tip, columella or

entire nose.<sup>3,18</sup> It is used only for nasal cover. Mucosal cover must be obtained from elsewhere, either from nasolabial flaps, existing nasal skin, septal mucosa or a full-thickness skin graft. Using septal lining is usually not practical in leprosy due to the large septal defect. I find that turning down existing nasal skin is usually adequate for lining the inner surface of the nose and that nasolabial flaps are ideal for replacing a deficit of mucosa around the roof of the nasal cavity. The paramedian flap is advantageous as it leaves minimal scar, does not require grafting for closure, is reliable and gives skin of a good thickness and colour match. It is based on the supratrochlear artery, either left or right. The scar should be vertical, as the axial blood supply to the flap will thus be maintained. An oblique design will give greater length but may compromise the blood supply and may make thinning of the distal portion hazardous.<sup>18</sup> The forehead flap described by Farina also appears to give good results although we have not used this technique.<sup>10</sup>

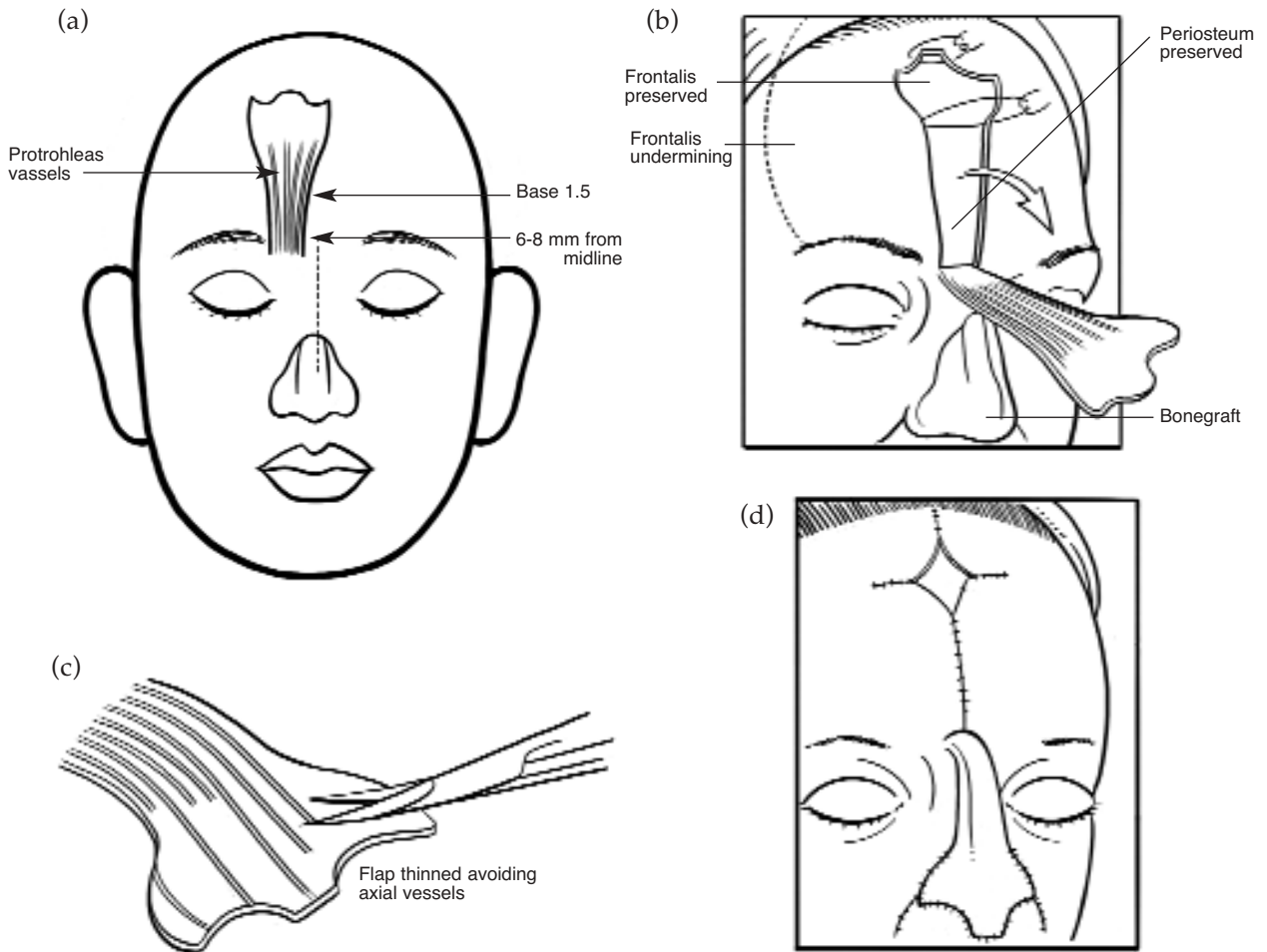
**Technique:** The location of the vessels may be checked by Doppler. They are approximately 1.5 cm from the midline of the forehead. A three-dimensional pattern is made of the skin defect. This must be exact. The graft is placed on the forehead near the hairline and the position checked to make sure that it will reach the intended site (Fig. 20-21). If the arc of rotation is too short, the distal part of the flap can be placed in hair-bearing skin, or the base may be extended through the eyebrow to give extra length. If the patient has adequate columella this can be used, thereby shortening the flap. The base is 1.2 to 1.5 cm wide. This allows easy primary closure and easy rotation. The flap is then raised and the distal part of the flap thinned, avoiding the axial vessels. Frontalis muscle is included in the base of the flap.

The recipient site should be prepared prior

to moving the flap. The skin from the tip of the nose can be turned down as lining. Otherwise nasolabial flaps are raised to rebuild the roof of the nose which allows the native lining of the tip of the nose to be moved down to a more normal position. The nasolabial flaps must be transferred via tunnels rather than detaching the alae as otherwise the lining of the tip would become avascular. In either case the entire tip and both alae must be replaced by the forehead flap to give a pleasing appearance. Usually in leprosy a bone graft will be necessary to support the nose. Otherwise chonchal cartilage grafts are harvested to rebuild the nasal tip structure as needed. These are sutured in position with absorbable sutures. The forehead flap is then rotated down without tension and sutured in position. If the dorsum of the nose is also being replaced no pedicle results. If only the tip and alae are being replaced then the raw undersurface of the pedicle is covered with paraffin gauze. The donor defect is closed by undermining and advancing frontalis muscle, then suturing in two layers. A gap will usually result near the hairline, which should not be grafted. It will be no larger than 2-cm in diameter. It should be left open and will contract and heal with minimal scar within four to five weeks.

In three weeks the pedicle can be divided, at which time the upper part of the flap can be thinned of frontalis fascia. The pedicle is not returned to the forehead but rather divided horizontally and discarded so that the resultant scar is parallel to the eyebrow. This will give a very aesthetically pleasing new nose and usually will not require further revisions.

Especially with severe loss of nasal structures the use of other flaps and tube pedicles may be required, which are described in plastic surgery textbooks. However the authors have found the above flaps to suffice for virtually all nasal deformities in leprosy.



**FIGURE 20-21** Gullwing forehead flap. **a.** Anatomy and outline of flap. **b.** Flap raised and lower part of donor defect and "tips" of wings closed by suture. **c.** Tip of flap thinned, avoiding axial vessels. **d.** Flap rotated down to cover nasal tip. Central portion of upper portion of donor defect left to close by secondary intention.

### 3. LOSS OF EYEBROWS

In lepromatous leprosy the loss of eyebrows may be complete or incomplete, due to destruction of the follicles. When incomplete, the smaller hairs often remain though the larger coarser hairs are lost. In borderline and reactional leprosy loss of eyebrows may be due to ulceration, infection and scarring. Only one eyebrow or even a part of one may be lost.

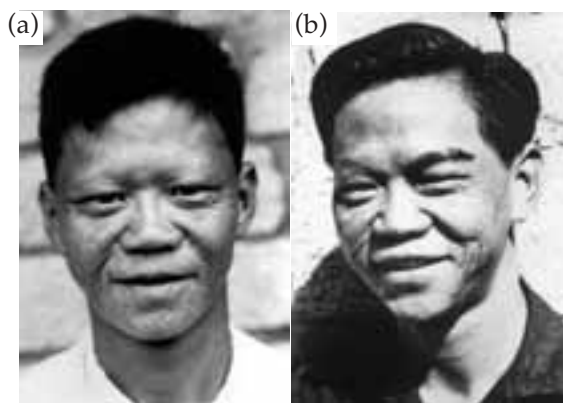Eyebrow replacements should not be performed until the skin has returned to as nearly

normal as possible, the risk of reaction is passed and the infection is completely controlled. If a lepromatous patient is seen at the stage of acute inflammation of the eyebrow region and the eyebrows are still present but becoming scanty, it may be beneficial to rub in cortisone cream thrice daily into the eyebrow area till all inflammation has ceased.

If a patient comes and asks for eyebrow replacement it is essential to find out what he wants. There are many possibilities. If he re-



quires full eyebrows get him to draw them. The patient should do this before surgery is planned, while he is vertical and he and his friends can comment. Eyebrows designed on the operation table rarely give the desired expression. He can cut out various shapes in adhesive plaster coloured black and after cutting a pair, experiment with the different positions, angles and shapes. When he is satisfied, tattoo the outline using gentian violet or similar on a hypodermic needle to mark the skin. Cut the shapes in tinfoil e.g. inside lid of a milk tin. These can be sterilised and used as the pattern for cutting the actual grafts. Do not decide where to put the grafts when the patient is on the table. The result may not be satisfactory. Figure 20-22 shows the typical appearance before and after free graft eyebrow replacement.



**FIGURE 20-22 a & b** Pre and post operative pictures of patient with free graft eyebrow replacements. He has also had a bone graft in his nose. He is now ready to face the world.

The site of the donor area needs to be selected at least the day before and the hair cut to about 3-5 mm length for easy cleaning and handling. Wash the hair thoroughly with cetrimide or similar, the day before to remove all oil and again immediately before coming to operation room. There is no need to shave the

whole head. The short hair helps one know the direction of growth of the hair to select the correct site for the grafts. It is essential to note the patterns of baldness in the community, the ethnic group and the family. It may be necessary to use occipital, post-auricular or crown hair. In many Asian patients, the postauricular hair is softer and more suitable than that of the crown and therefore makes "nicer" eyebrows.

There are four methods of eyebrow replacement. The free grafts are easiest and quickest, and in the author's hands, reasonably successful.

### i. Individual follicle planting

In some endemic leprosy countries this technique is sometimes referred to as rice planting. This technique is most useful in partial loss of eyebrows as the grafted longer hairs can supplement the remaining short hairs.

**Technique:** A piece of scalp is removed, usually retro-auricular, as the hair is relatively soft and easy to handle. This is the preferred site because the direction of hair growth is more easily adapted to suit the recipient needs. It is carefully dissected into individual hair follicles making sure that the root bulb is not damaged when cutting it (Fig. 20-23). Sometimes two or three hairs make up one bundle. The dissected hairs are put in an antibiotic/saline solution.

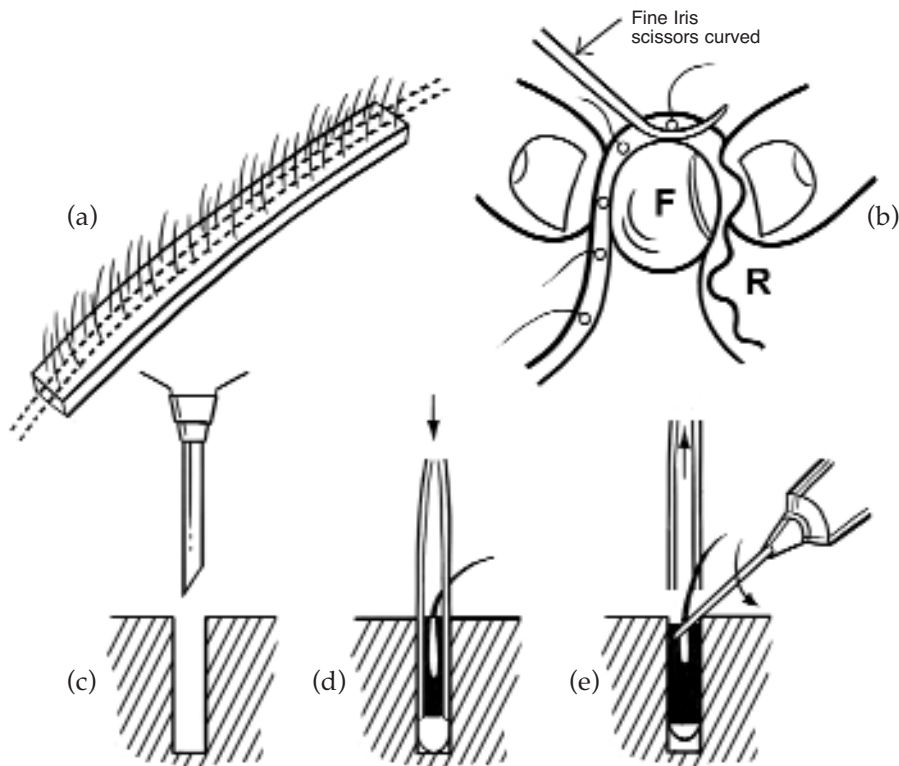
After infiltration of the recipient area with a local anaesthetic containing adrenaline, the whole recipient area is punched with holes, using a No.18 or 16 hypodermic needle. It is wisest to punch all of one eyebrow at the beginning or the pressure of punching may force out hairs already planted. Be careful with the punching to ensure that the hair grows in the desired direction. For a full eyebrow 60-150 hairs are needed depending on whether there is partial or complete loss. Do not punch in straight rows and punch in the direction you wish the hair to grow. Patients have ended up

with eyebrows that stick up like the bristles on a toothbrush.

The hairs are then picked up in a fine non-toothed thumb forceps with the bulb at the point end. A straight non-toothed Iris forceps is ideal. Two or three hairs may be in one small bundle. The forceps is used to plant the hair into the punched hole using an injection needle to help prevent it being pulled out again as the forceps is withdrawn (Fig. 20-23). When enough hairs are planted, the area is covered with a piece of Vaseline gauze and a folded pile of saline gauze to make a pressure dressing just over the planted area. The pressure is exerted by adhesive plaster stuck to the local skin, and left on for ten days. Cover the plaster reinforcement with a firmly applied cotton bandage, not

true elastic, to provide a uniform pressure dressing for the first three days. Be careful not to put pressure on the ears or the rims may become gangrenous. After ten days, remove the dressings and keep the area dry and clean. Use spirit if necessary. Do not pull out hairs when washing or cleaning the area. The hairs will fall out and regrow over the next 3-6 months. We expect about 60% take if no infection occurs. Inform the patient that in 6-8 weeks time he may have no eyebrows but that they will re-grow after that period.

There is a Japanese hair holder for planting these follicles. However, I (GW) find it difficult to load and handle, and of no real advantage over the earlier described method. Ranney writes about the use of biopsy punch grafts as



**FIGURE 20-23** Planting technique. **a.** A piece of hairbearing skin is taken. **b.** Wrap it over a finger (labelled F) and with a scalpel cut parallel to the lines of the hair follicles. Then use a pair of fine curved scissors, such as iris scissors, to cut out the complete follicle. **c.** Punch the hole with a thick bored hypodermic needle. **d.** Pick up the follicle in fine straight non-toothed forceps and plant it into the hole. **e.** Use a hypodermic needle to hold graft into hole as the forceps are withdrawn.

now used for bald heads.<sup>22</sup> These would be similar, but being larger would leave a more definite scar pattern which would be more obvious if used on large areas.

The method described here leaves little or no scar where the hairs are planted and provided the hairs are planted so that they will grow in the correct direction those that do grow appear to be normal, even if the eyebrow is still thin.

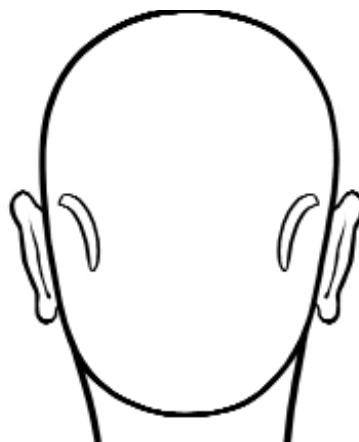## ii. Full thickness grafts of hairbearing skin

If all the hairs have gone, or the patient wishes to change position of eyebrows, it is probably better to graft the whole eyebrow in one piece. Note that the free grafts should not be wide or the central section may not survive.

First cut the scalp hair to about 3-5mm length so that the direction of growth can be easily seen and the 3mm of hair will provide a handle to hold the grafts. The whole head is prepared as described above, for surgery.

**Technique:** The eyebrow recipient sites are prepared by removing the skin inside the tattoo lines, securing haemostasis. Then grafts are cut using either the removed pieces of skin or the tinfoil shapes previously cut.

The tinfoil patterns can be sterilised to achieve correct size and shape. Remember to cut a pair of eyebrows. Often the piece for the right eyebrow comes from behind the left ear (Fig. 20-24). It is usually best to take one from each side as this makes the lines of hair growth on each side similar. Be careful to note the direction of hair growth if natural eyebrows are desired. It is possible to bend the graft slightly and change the direction of growth as does occur at midline. Notice that the hairs in most eyebrows tend to grow up and out along the top. The central 1 cm of the hairs are often in a different direction. Examine carefully when preparing to cut the grafts to ensure that the final directions of growth will be satisfactory. It



**FIGURE 20-24** Shows the back of a head to indicate placement of the two sites for graft harvesting. For free grafting post – auricular hair usually gives the best results and the piece from behind the right ear goes to the left eyebrow, and from behind the left ear to the right eyebrow. The natural change in the direction of the hair follicles lends itself to making the new eyebrow more realistic as the hair follicles naturally lie in the direction in which they should grow in future. The growth patterns can sometimes be improved by slightly curving the piece of skin as it is sutured into place.

is usually possible to slightly rotate the medial end of the graft during suturing to get a subtle change in direction of growth that is needed.

The post auricular area is frequently the best donor site as the skin is supple and the hair soft, but occipital hair may be better. The crown may provide a better direction for hair growth unless there is familial baldness.

The graft is then cut. Try and keep the knife blade in the line of the hair growth so that each root has a complete follicle. Be sure to elevate the graft just above galea and be careful not to damage the base of the hair follicles. It may be safer to remove the galea initially and then carefully remove it from the graft to ensure that no damage is done to the follicles that lie very close to the galea. The scalp is sutured with fairly deep mattress sutures to ensure haemostasis. Usually one layer is adequate. The excess fat and any fascia are trimmed off

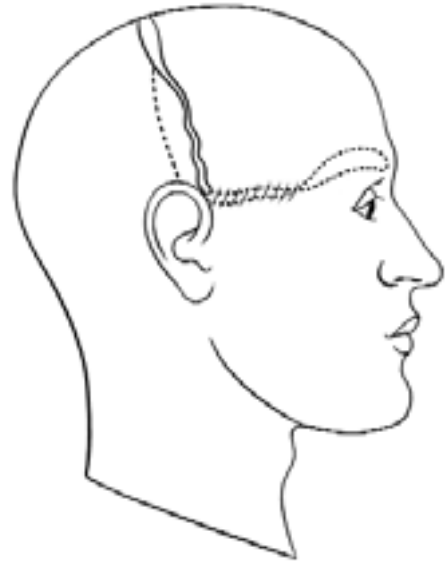
the graft so that the occasional hair follicles are seen. However, do not remove all the fat or the hair follicles will be damaged. All fascia must be removed to assist in the take.

The graft is then sutured into the recipient site, using tie over sutures, which need to be deep enough to provide pressure when tied over. They should not encroach far into either the non-hair-bearing recipient skin or the graft. When the suturing is complete, cover the graft with Vaseline gauze and then make a bolus of saline soaked gauze to about 1.5 cm diameter and 2cm longer than the eyebrow and tie over it with the multiple ties. This is then covered with dry gauze and then cover this with adhesive plaster to construct a pressure dressing over the whole sutured area. This is then reinforced with a firm cotton, not elastic, bandage to minimise movement and haematoma formation. Also make sure the ears are protected by cotton wool pads to prevent excessive pressure on the rims. The ears are often anaesthetic and pressure sores on them after the removal of extra firm bandages for eye, eyebrow and face surgery, are not uncommon. After 3 days the pressure bandage is taken off but the firm adhesive plaster dressing is left in place till the tenth day. Then the sutures are removed. After removal of sutures, keep the eyebrows dry and clean. The hairs will drop out in 2-3 weeks and will grow again in 3-6 months if the follicles have not been damaged and scarring from infection does not follow (Fig. 20-22b).

### (iii) Pedicle or island artery grafts

It is usually recommended that no adrenaline be used in the local anaesthetic, on the scalp as adrenaline makes it more difficult to dissect the artery without damage. This often allows a lot of bleeding and a diathermy is desirable. Adrenaline may make it more difficult to find the vessels and so they get damaged. Ideally the superficial temporal artery should be traced out before surgery and tattooed in as a

guide, and the correct site for the grafts selected. Take into account the direction of hair growth, the thickness desired and the likelihood of baldness later (Fig. 20-25). The most common donor site is towards the crown as the superficial temporal artery is usually easy to find and the lines of hair growth suitable.



**FIGURE 20-25** Diagram of technique for Pedicle Artery Grafts. Note incision is behind the artery and the incision is continuous with the graft to be moved for suture into recipient site.

**Technique:** An incision is made roughly concave to the artery and 1-2 cm behind it, extending up till it is continuous with the area for the graft. Dissect down to the deep fascia and cut that and elevate below the deep fascia so that the artery and vein can be seen, from the cranial side of the fascia. In this manner it is easier to get the vessels without damage than if the vessel is approached directly from the skin. The superficial fascia is cut with the neurovascular bundle intact. This can be difficult as the vessels meander especially if a direct approach is used. The vessels in the deep fascia need to be freed up from just above the ear till the pedicle is long enough to reach the outer end of the

eyebrow recipient. At the end the eyebrow shape is cut, attached to the vessels. A generous tunnel is made from the recipient site to in front of the ear and the eyebrow carefully tunneled through. The graft is stitched into position as before with tie over sutures. Similar dressings are used, adhesive tape over the 'tie over bolus' and then a pressure bandage for three days.

The hairs do not usually fall out by this method. Therefore the eyebrows may be presentable soon after surgery. If they do fall out do not hurry to redo! They should grow back in 3-6 months. It is sometimes very difficult to dissect the artery to get it long enough. The hair of the crown may be very wiry and may grow in the wrong direction. These points need to be considered in planning. This is the best method of producing a thick luxuriant eyebrow such as many patients of the Indian subcontinent desire, but they are not appreciated by most Chinese patients.

(iv) Sometimes more complicated methods are used, such as swinging a bucket handle flap of scalp over from the back of the scalp and suturing into the eyebrow position and returning later to replace what is unused and trim it all up. These methods are no more successful and are more time consuming and more prone to infection. Also, it is difficult to achieve a suitable directional growth of the hairs that eventually form the eyebrow.

#### 4. BAGGY EARS

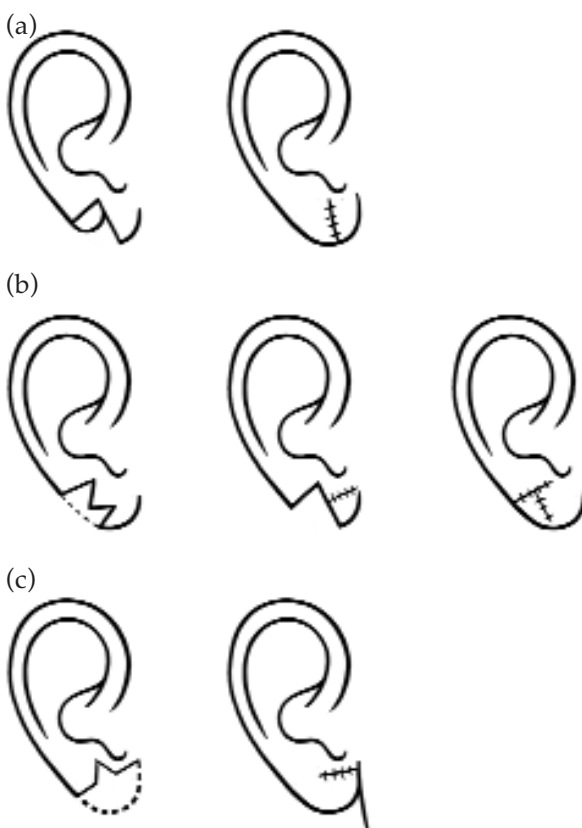
It is usually only the ear lobe in a lepromatous leprosy patient that can become enlarged, 'baggy'.

Tanzer and Converse report about wedging to reshape large lobes and still maintain normal edges.<sup>24</sup> There have been many modifications published since. If one edge of the wedge is in the line where the ear joins the face the scar will be negligible as in the T-wedge (Fig. 20-26) A

second incision will be needed to fold the edge round. As far as possible keep the natural rolled edge of the ear to make it look more normal.

The most effective wedges are removal of a Single V, a W-shaped wedge and the T-wedge (Fig. 20-26). In suturing make sure the posterior points of the wedges are correctly placed.

The sutures can be removed on the fifth day and wounds are protected for another week or two, especially to protect the ear(s) in case the patient is pulling a shirt or sweater over his head. It is advisable to keep adhesive strapping to minimise such problems. Typical enlarged

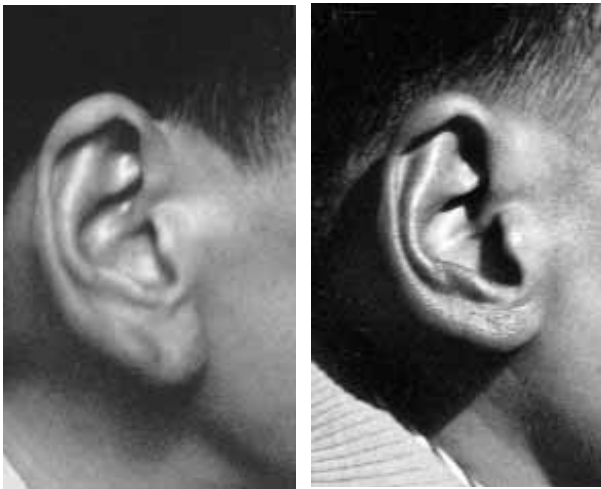


**FIGURE 20-26** Diagrams of wedges to reshape ear lobes. **a.** the simple V wedge if the lobe is not excessively large., **b.** a long double wedge is of use if there are defects on the edge that need removal. **c.** The T wedge is excellent as the top of the T is in the skin crease and so less obvious than some of the other wedges.



lobes are shown in Fig. 20-27a and after wedging in Fig. 20-27b.

Occasionally the edge of the pinna may also need to be tidied up if reaction or infection has caused irregularities of the helix and a rat eaten appearance may have resulted. If a patient has a complete loss of the whole helix roll, it may be desirable to replace it with a local flap of post auricular skin or even a tubed pedicle graft from the sub auricular area of the neck or the acromio-clavicular area. Such a graft would need to be raised in say three sections, which could be joined to make one long tube. This can then be jumped on to the neck as a staging point. Three weeks later it can be sutured around the edge to provide a smooth rounded helix. A post-auricular flap with skin grafting is much simpler than this.



**FIGURE 20-27a & b** Pre and post operative views of a trimmed ear lobe.

## 5. EXCESSIVE WRINKLING

After recovery from severe lepromatous leprosy a patient may have very wrinkled skin of the face. His appearance can be improved, and often the appearance of youth restored by a face-lift. In leprosy the main looseness of skin occurs around the mouth- especially the upper

lip and in the nasolabial folds area. The pre-auricular skin and forehead are rarely badly affected. Most patients are not concerned about those areas.

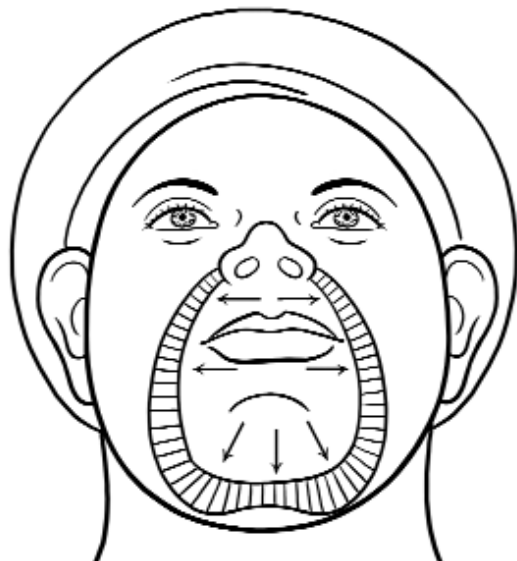The classical face-lift is a massive and time-consuming procedure whereby all scars are inside the hairline. The skin is elevated from that point to the lips and nose, then pulled tight and sutured firm with the excess skin excised. There is often a need to make extra incisions around the nose and mouth to eliminate the wrinkles that are the main problem. The classical face lift, done through the hairline, deals with large areas of skin that are usually unaffected in leprosy and it is usually not necessary to perform such extensive dissections.

By utilising the nasolabial face lift the amount of dissection is greatly reduced and the scars can be placed so that they appear to be the normal nasolabial creases. This can be done at the same time as the nasolabial flaps are taken out to reconstruct a collapsed nose. It is the patients with marked nasal collapse who often desire a face-lift.

### Nasolabial Face Lift: Technique

A curved incision is made in the nasolabial fold, commencing at the nose and swinging about 1 cm lateral to the angle of the mouth, then back towards the point of the chin (Fig. 20-28). The two incisions can meet in a V about 1-3 cm below the chin point, allowing excessive skin of chin and neck to be excised at the same time though if that area is not badly affected they can be discontinued at a higher level. Through the incision the skin of the cheeks and lips is elevated far enough to achieve the desired smoothness. Care must be taken to peel the skin off the fat, because removal of the fat always leads to extra bleeding and possible haematoma formation. Haemostasis is secured and then 4-0 Vicryl or similar suture is used to secure the subcutaneous tissues in the desired position to remove as many wrinkles as possi-

ble and be sure that the scar will not stretch later. There should be no tension of the fine skin sutures. The excess skin is excised and then the incision closed.



**FIGURE 20-28** Diagram of a face to show the incision and the direction of pull of the skin before the first fixation with Vicryl. The incision does not need to go right under the chin but can if the skin there is also redundant.

Similar incisions can be made, on the upper eyelids and the forehead, if there is excessive skin that the patient wishes to have removed. Provided they follow normal crease lines, they should not be very obvious when healed. If adequate haemostasis is achieved it should not be necessary to use pressure dressings which are difficult to apply on the face. In six months the scar should be hardly detectable, as it should lie in the natural crease. If the surgeon is clever he can actually produce an artificial dimple beside the mouth.

Face lifting should not be done while there is any risk of a lepra reaction.

In patients who have a facial palsy of the lower half of the face a vast improvement in appearance can be achieved by a nasolabial face-lift. This is especially useful when the tem-

poral muscle is needed to protect the eyes that are affected by lagophthalmos.

## 6. SKIN SCARS

Skin scars may result from ulcerating lepra reaction. They may cause disfigurement, or may cause deformities due to contractures. Lepra reaction around the eyelids may produce scars that pre-dispose to exposure keratitis, or chronic infections. Routine plastic surgical measures may be employed. When contractures occur round the eyes it may be necessary to apply skin grafts to the lids to ensure future closure. Post auricular skin, full thickness, is the best, as it is very like eyelid skin. The graft should be large enough to allow the lids to overlap without being stretched, and preferably a "tie over" bolus of gauze used to prevent contractures and haematoma during early healing. It is advisable to do a temporary median tarsorrhaphy to hold the whole lid closed for 3 months to prevent the graft contracting again and causing recurrent ectropion. In the post-operative stage antibiotic drops should be dropped onto the medial canthus, when the patient is lying down, so that it will trickle into the eye as the lids are closed in the centre.

## CONCLUSION

It is obvious that there are many procedures that will help improve the appearance and social acceptance of the leprosy patient whose disease is controlled. However, some patients have no interest in such management. They accept their deformities and disabilities and may even be accepted by the community. However, if there is a deformity such as lagophthalmos that may threaten the patient's welfare in the future we ought to try and persuade the patient to have something done to correct the impairment.

There are also individuals who may request things that are not discussed. Many of these people need counselling to deal with problems that are often much deeper than those that can be corrected by surgery. Do not neglect to try and meet these needs when considering surgery. If the emotional problems are deep seated, no amount of facial reconstruction will solve the problems. What we do should be aimed at improving quality of life, not just an improvement in appearance.

## REFERENCES

1. Antia NH: Reconstructive Surgery of the Face. pp 497-509. In Cochrane R, Davey T (eds): *Leprosy in Theory and Practice*, 2nd edition. John Wright and Sons Ltd., Bristol, 1964
2. Boyce RG, Toriumi DM: Considerations in the use of biologic grafts and alloplastic implants in facial plastic and reconstructive surgery. *J Long Term Eff Med Implants* 2(4):199-220, 1992
3. Burget GC, Menick FJ: Nasal support and lining: the marriage of beauty and blood supply. *Plast Reconstr Surg* 84:189-203, 1989
4. Caputy GG, Flowers R: The pluck and sew technique of individual hair follicle placement. *Plast Reconstr Surg* 93(3): 615-620, 1994
5. Celik M, and Tuncer S: Nasal reconstruction using both cranial bone and ear cartilage. *Plast Reconstr Surg* 105: 1624-1627, 2000
6. Cochrane R, Davey T: *Leprosy in Theory and Practice*, 2nd edition. John Wright and Sons Ltd., Bristol, 1964
7. Cochrane RG. Lesions of the Nose, Ear Mouth and Throat. pp 322-330. In: Cochrane RG, Davey TF (eds): *Leprosy in Theory and practice*, 2nd Edition. John Wright and Sons Ltd, Bristol, 1964
8. Converse JH et al: Deformities of the Nose. pp 694-828. In: Converse JH (ed): *Reconstructive Plastic Surgery*. WB Saunders, Philadelphia, 1964
9. English FP, Forster TD: The eyebrow graft. *Ophthal Surg* 10(7):39-41, 1979
10. Farina, R: Total Rhinoplasty for the Destroyed Nose. pp 143-148. In: Enna CD, McDowell F (eds): *Surgical Rehabilitation in Leprosy*. The Williams and Wilkins Co, Baltimore, 1974
11. Fritschi EP: *Reconstructive Surgery in Leprosy*. The Leprosy Mission, Delhi, 1984
12. Gibson T, Davis WB: The distortion of autogenous cartilage grafts: its cause and prevention. *Brit J Plast Surg*, 10:257-274, 1958
13. Gilles HD: Deformities of the syphilitic nose. *Brit Med J* 2:977-979, 1923
14. Goldman GD: Eyebrow transplantation. *Dermatol Surg* 27: 352-354, 2001
15. Hari K: Reconstruction of the short nose with iliac bone graft and nasolabial flaps. *Plast Reconstr Surg* 69:863-870, 1982
16. Lee Y. Kim J, Lee E: Lengthening of the postoperative short nose. Combined use of a gull-wing and Concha composite graft and a rib costochondral dorsal onlay graft. *Plast Reconstr Surg* 105:2190-2199, 2000
17. McDowell F, Enna CD (eds): *Surgical Rehabilitation in Leprosy*. Williams and Wilkins Co, Baltimore, 1974
18. Menick FJ: Aesthetic refinements in use of forehead for nasal reconstruction: the paramedian forehead flap. *Clin Plast Surg* 17:607-622, 1990
19. Millard DR, Mejia AM: Reconstruction of the nose damaged by cocaine. *Plast Reconstr Surg* 107:419-424, 2001
20. Motoki DS, Mulliken JB: The healing of bone and cartilage. *Clin Plast Surg* 17:527-544, 1990
21. Neu BR: Segmental bone and cartilage reconstruction of major nasal dorsal defects. *Plast Reconstr Surg* 106:160-179, 2000
22. Ranney DA: The role of punch grafting in eyebrow replacement. *Lepr Rev* 45:153-157, 1974
23. Shirakabe Y, Shirakabe T, Takayanai S: The classification of complications after augmentation rhinoplasty. *Aesth Plast Surg* 9:185-192, 1985
24. Tanzer RC, Converse JM: Deformities of the auricle. pp 1084. In Converse JH (ed): *Reconstructive Plastic Surgery*. WB. Saunders, 1964
25. Tovey FH: Reconstruction of the nose in leprosy patients. *Lepr Rev* 36:215-220, 1965
26. Turegun H, Sengezer M, Guler M: Reconstruction of saddle nose deformity. *Aesth Plastic Surg* 22:38-41, 1998

# Pre- and Postoperative Therapy Following Tendon Transfer Surgery

• J. WIM BRANDSMA  
M. EBENEZER

## INTRODUCTION

In this chapter the pre- and postoperative care will be discussed for patients having paralysis of hands or feet in whom tendon transfer surgery is performed to correct the important primary functional impairments.

Peripheral neuropathies and nerve injuries may lead to paralysis and weakness of hands and feet. With the peripheral neuropathies we include also the sequels of such entities as (post) poliomyelitis and Guillain-Barré. The paralytic conditions in hands and feet due to Hereditary Motor Sensory Neuropathy can often also be surgically corrected.

We emphasise that for tendon transfer surgery to be successful the surgeon needs to have the necessary training. Likewise, surgery will only be successful if the therapist has the necessary understanding and skill in re-educating muscles whose distal tendon is transferred or re-routed to substitute for weak or lost functions.

First, the pre-and post-operative care of tendon transfers for the hand will be discussed, followed by a discussion of the care related to tendon transfer for the paralytic foot. No distinctions will be made to specific functions or responsibilities of the physiotherapist or occupational therapist in the rehabilitation of the corrected paralysed hand or foot. Work setting and availability of expertise determine pre- and postoperative responsibilities. Assessment forms are given in the appendices of the book. For a good understanding of the subject matter

of this chapter the reader may want to review the chapters on functional anatomy of the hand and foot.

## SELECTION CRITERIA

Patients should be willing and motivated for tendon transfer surgery. Many patients may have become 'used' to splints or have accepted the condition and have 'adjusted'. Surgery will involve 3-4 weeks of postoperative immobilisation and another 4-6 weeks of rehabilitation before the patients will have full use of the hand or foot again.

Ideally, there should be no secondary impairments present at the time of surgery (Chapter 5). Advanced age is a relative contra-indication. Good results are also attainable in older patients when there are no secondary impairments and the patients are very motivated.

A slow progressive neuromuscular condition is also a relative contra-indication. If the use of splints can be delayed, or if the functionality of the hand or foot can be maintained/improved for some more years, it is worthwhile considering tendon transfer surgery.

It is important that the patients know and understand what the operation and postoperative rehabilitation is about. This will ensure postoperative compliance with the therapy. A useful question to ask the patient before opera-

tion is: "What do you expect from the surgery"?

It is important to know that the patient's expectations are realistic and that it is explained to the patient what can be expected, taking, of course, into account the present condition of the hand or foot.

With respect to leprosy, the ILEP guidelines about "identifying patients for reconstructive surgery" should be consulted.<sup>13</sup>

### **Assessment**

It is essential to use specific assessment forms. If we want to know to what extent surgery has been beneficial in correcting the impairment and enhancing functional use, we need to have baseline (pre-operative) data against which postoperative data can be evaluated (see appendices in this book).

Essential in the pre-operative assessment is an evaluation of the muscle status.<sup>7-9</sup> Often the improvement in tendon transfer surgery for claw fingers is only judged on the basis of improved extension angles (less clawing). There are to date no data available to show how the function of the hand may have improved following claw finger correction. It is advisable to assess the angles of the hand on a weekly basis for as long as the patient is hospitalised and then do a functional evaluation at the time of discharge. Ideally the patients should be seen a few months postoperatively and 1-2 years later to see if the results obtained by the surgery are sustained.

Also for tendon transfer surgery for foot-drop the success of surgery is often only based on the range of active dorsiflexion only. Few data are available on aspects such as restored gait or prevention of ulceration.

### **A. PRE- AND POSTOPERATIVE CARE FOR THE PARALYSED HAND**

The ideal hand for tendon transfer in ulnar and/or median palsy is the hand with full

mobility of all finger joints. The mobile claw hand is defined as the hand with full assisted extension in the IP joints. Exercises and splinting are indicated for the stiff hand to overcome contractures (Chapter 5). The tendon transfer will not overcome pre-existing joint stiffness or other secondary impairments.

#### **1. Ulnar Palsy: 'Clawing'**

The main functional defect is 'clawing' which is due to the paralysis of the interosseus muscles. The main purpose of a tendon transfer for clawfinger is to restore primary MCP flexion.

The postoperative surgical cast is usually removed 3 weeks after the surgery. Sometimes the cast is bivalved and one half is used to maintain the wrist/fingers in the 'lumbrical position' in between exercise sessions. We do not recommend this as there will not be a snug fit from the operation cast when bulky bandages have been used, immediately postoperative and prior to immobilisation.

A new slab should be made to support fingers and wrist in a position in which there is no undue tension on the sutures/grfts. Often the fingers will be immobilised in cylindrical Plaster of Paris bandages for the initial 2-3 weeks of postoperative re-education, but the 'cylindrical' plaster splints should be taken off for short periods daily for supervised 'isolation' exercises. The plasters serve two purposes:

- In the exercise session immobilisation of the IP joints will help in isolating the transferred muscle/tendon by preventing IP flexion;
- Any remaining joint stiffness or lag in assisted active extension can be further corrected (Chapter 5).

Following the tendon transfer the fingers should ideally be immobilised in full extension in the IP joints and full flexion in the MCP joints. This is often not achieved in the operating room. The serial casting then will also cor-



rect the mild flexion contractures that may have occurred.

Some surgeons will also do a separate tendon transfer to improve pinch strength, to restore adduction power to the thumb. This does not need specific care when done simultaneously with the tendon transfer for the correction of clawing. This transfer is not always needed (chapter 6).

### ***A Guideline: Rehabilitation of the Hand with Ulnar Nerve Paralysis***

This is a *Guide-line*. In individual cases, depending on such things as progress made and occurrence of complications, deviations of the guidelines can/should be made. Reasons for deviating from the guidelines should always be recorded in the progress notes.

Loss of motor function of the ulnar nerve may result in clawing of all the fingers of the hand. Usually clawing is more obvious in the ulnar fingers. 'Hidden' or *latent* clawing will usually be present in the fingers that may not show *overt* clawing (usually the index and middle fingers). Clawing in these fingers will become evident in functional activities and weakness will be revealed in the so-called 'lumbrical' test.<sup>7-9</sup>

Even the thumb may 'claw' (Froment's sign) or show a Z-deformity due to paralysis of the ulnar innervated intrinsic muscles of the thenar. (Hyperflexion of the thumb IP joint with hyperextension of the thumb MCP joint). As a routine, usually all four fingers are corrected in an ulnar palsy. The thumb may need correction depending on the presence and severity of the deformity and functional demands of the hand.

The following is an outline of the important points in the rehabilitation of the hand that will

undergo surgical correction of the deformity (tendon transfer(s)). Basic knowledge of the anatomy and (patho) kinesiology of the hand with paralysis of the intrinsic muscles is assumed.

No distinction is being made of the relative and often complementary roles and function of occupational therapist (OT) versus physiotherapist (PT) (or OT-PT assistants/technicians). Local circumstances and arrangements will often determine whether specific activities are the main or sole responsibility of one professional.

### **Tendon Transfer for Ulnar Palsy**

The distal tendon of a 'donor' muscle (commonly PL, FDS, or ERCL) is detached from its insertion. In case of use of PL or ERCL the distal tendon is lengthened with a free graft to be able to reach the fingers.

The distal tendon or the free graft is split into four tails, one for each finger. The tendon slip is attached to the lateral band of the extensor mechanism through the lumbrical canal or is attached to the A<sup>1-2</sup> pulley of a finger ('Lasso') insertion (chapter 6).<sup>2-4</sup>

### **Aim of the Operation and Rehabilitation:**

To restore function and appearance of the hand to its fullest potential.

With an 'open' hand the fingers are straight; in closing the hand there is a proper sequence of flexion of the finger joints. This is achieved by restoring primary flexion of the MCP joints.

The clawing position of the fingers is a *cosmetic* impairment (deformity); the inability to close the finger joints sequentially is a *functional* impairment.

The final outcome of surgery/rehabilitation may depend on such factors as:

presence of secondary impairments prior to surgery, duration of palsy, age of patient, skill and experience of the surgeon and the therapist, and motivation and perseverance of patient and therapist.

#### **Tendon Transfer (TT) Surgery**

*Surgery will mainly address the problem of finger clawing and finger closure. The fingers will be adducted following surgery, but active ab- and adduction will not be possible. The arch is usually not restored and little is known about the possible effect of TT surgery on pinch- and grip strength.*

#### **Assessment:**

- *It is highly recommended that specific forms be used to assess and monitor impairments and activity limitations of the hand. The use of graph paper is recommended to evaluate changes in finger extension/flexion angles. Graph paper can also be used to monitor changes in hand volume to evaluate oedema. Only when records are kept is one able to tell to what extent surgery/rehabilitation may have benefited the patient.*

#### **Pre-operative goals:**

- a) to achieve optimal skin condition;
- b) to reduce, if present, secondary impairments as much as possible;
- c) to treat and manage other health problems that could prevent or delay reconstructive surgery;
- d) to assure that the patient understands the procedure and postoperative rehabilitation involved and to obtain his co-operation.

**Secondary impairments:** Secondary impairments should all have been eliminated or reduced to the extent where further improve-

ment is not shown.<sup>6</sup> When there is no further improvement (no change for two weeks) surgery could be planned but additional procedures may have to be done at the time of tendon transfer surgery or even prior to tendon transfer surgery to correct the secondary impairment.

The best results with tendon transfer surgery are obtained in the hand without secondary impairments. This is the hand with mobile 'clawing'.

#### **Definition:** Mobile clawing

*When the patient is asked to extend the fingers there is full/complete IP extension when hyperextension of the MCP joints is prevented.*

*Hyperextension can be prevented by the patient's own hand or the hand of the examiner (Bouvier's test), or by a splint.*

**Exercises and Splinting:** For exercises to prevent or overcome joint stiffness see Chapter 4.

Serial cylindrical Plaster of Paris finger splints have been shown to be very effective and safe in the release of PIP contractures.<sup>10,11</sup> Other splints could be used when available.<sup>12</sup> More expertise/supervision is usually then needed and compliance may be lower.

**Isolation exercises:** Often the patients are taught how to isolate the muscle, which is selected as a donor. This may help the patient in finding the muscle again in the postoperative rehabilitation phase, usually 3 – 4 weeks after surgery.

Isolation exercises for this purpose are not essential. If a patient cannot find the muscle after surgery, it may be helpful to isolate the muscle on the non-operated arm and then 'transfer' the exercise to the operated side. Strengthening of a donor muscle is not a realis-

tic objective. The possible effect of strengthening (if any) will be lost in the 3 – 4 weeks of immobilisation.

## NOTES

- a) *Generally speaking, splinting is not needed for the hand with mobile clawing. The exercises will prevent the development of secondary impairments. In some cases a splint may enhance the function of the hand. A splint could also be considered when compliance with exercises is not expected.*
- b) *Habitual wrist flexion when opening the hand is a major problem. Wrist flexion will enhance opening of the hand. This habit needs to be addressed prior to surgery. Continuation of this habit after surgery will compromise the outcome.*
- c) *Flexor tightness, when severe, could also be addressed with specific splints.*
- d) *Some surgeons experiment in the 'Lasso' operation with a cast that is open at the volar side of the hand. This will allow for 'unresisted' finger flexion. The patient can also do active extension exercises against the cast. Such cast may reduce duration of post – operative stiffness. Care should be taken that the patient will not use the hand (e.g., to carry something). It is advisable that during the postoperative rehabilitation period the hand is bandaged in extension against the cast, at least for the night.*

### Postoperative goals:

- a) to protect tendon sutures during healing phase;
  - b) to prevent, or reduce and eventually eliminate swelling;
  - c) to obtain control of transferred muscle/tendon;
  - d) to regain pre-operative range of motion;
  - e) to integrate new function(s) in functional activities.
- assessment and progress notes to be written weekly!

### Week 1 (3 – 4 weeks after surgery):

Concentrate on contraction ('isolation') of the donor muscle. Protect tendon sutures for at least the first 2–3 weeks following removal/bivalving of the surgical cast. Exercise sessions should be supervised: 3–5 short sessions daily rather than 1–2 longer sessions.

Cylindrical plasters for the fingers during the first 1 – 2 weeks may help the patient to isolate the muscle whose tendon is transferred. It will also be a 'reminder' for the patient not to use the hand, except when supervised in exercise sessions, and may prevent recurrence of contracture when contractures have been present pre-operatively.

The plasters should be removed regularly for supervised exercises to see how well the transfer is working.

Be aware of trick movements and habitual wrist flexion!

**Care for skin:** soaking and oiling!

### Week 2

Continue as in week 1 but add finger flexion when there is good control of the transferred muscle/tendon.

When patient shows good control of TT practice isolation with and without visual control.

Patient can be weaned off cylindrical plasters when there is good control of TT and no indication for recurrence of contractures.

### Week 3 – 5

During this time, provided that the patient shows good 'control' of the transferred tendon, contraction of the transferred muscle/tendon should be integrated in functional activities.

*Where FDS has been used one should be alert for the development of a checkrein deformity. Timely intervention (cylindrical cast) can prevent the development of a progressive flexion contracture of the donor finger!*

## NOTES

- a) *If patients have had pre-operative secondary impairments, which took a long time to correct/minimize, then the postoperative rehabilitation period should be proportionally longer. Up to 6 – 8 weeks. Contractures recur easily! These patients need also to be called for review earlier after discharge so that when recurrence of secondary impairments occurs immediate action can be taken.*
- b) *Especially where severe contractures have been present pre-operatively it is advisable that night splinting is continued for a longer time post-operatively.*
- c) *Electrostimulation is usually not required to either strengthen a transferred muscle or to help the patient 'find' a transferred muscle.*
- d) *When adherence (scarring down) of a transferred tendon is suspected gentle friction may be useful. To be done 2 – 3 times daily for 5 – 10 minutes followed by active contractions. The supposed benefits of ultrasound in the breaking down of scar tissue have not been proven.*
- e) *Failure to progress, or deterioration of any finger should be shown to the surgeon promptly.*

### ➤ Follow-up

The patient is called for review/reassessment after discharge from the hospital. Changes may occur after discharge (further improvement, but also late complications and recurrence of contractures). As a guideline, it is advisable to re-assess the hand 2 – 3 months post surgery and again 1 – 2 years after surgery.

After this period changes due to the surgical intervention are not likely to occur.

### Comment on 'Static' Corrections

Tendon transfers are often considered to be 'dynamic' procedures as opposed to static procedures by which MCP hyperextension will be 'passively' restricted. The most common procedure is often combined with an advancement of the pulley to enhance the moment arm of the long flexors on the MCP joint. Postoperatively MCP extension should be protected for a long time. No specific re-education is required! This operation restores the appearance of the hand (straight open hand/fingers) but does not restore the sequence in closing the hand. The operation is often performed in centres where expertise for dynamic corrections and post-operative rehabilitation may not be available.

### The Thumb in Ulnar Palsy

Depending on the innervation pattern of the thenar muscles (FPB), the mobility of the thumb MCP joint and the use of the hand, a patient may develop a Z-deformity or complain of a weak thumb in pinching. In a Z-deformity of the thumb there will be MCP hyperextension in addition to the often present thumb IP flexion (Froment's sign).

Various operations can address this problem. They can be done as a separate operation but are often done in conjunction with the tendon transfer that corrects the claw deformity. Besides the normal protection for the first 3 weeks, no specific rehabilitation is usually needed for this additional procedure.

### 2. Median Palsy: Loss of Opposition

A combined ulnar and median palsy is common in leprosy. Many surgeons prefer to correct the 'claw' deformity and loss of thumb

opposition at the same time. In the authors' experience this can be done safely provided the surgeon feels confident about this and the expertise is available for postoperative re-education. There are definite advantages of combining the two operations in one session: cutting down on the hospitalisation period and, in functional re-education, the thumb and fingers can work together in functional activities.

The thumb should ideally be corrected first if the surgeon prefers to correct the hand in two separate sessions.

Re-education of the transferred tendon is relatively easy. The donor finger may develop secondary impairments and these are often not recognised.<sup>5</sup> An important complication is the development of a progressive flexion contracture of the PIP joint (checkrein deformity). If timely recognised the finger should be splinted in extension. This may have to be continued for a longer time. The patient could at some time be given a removable night splint only and then be weaned off the splint being aware that the contracture does not recur.

We have not (yet) developed a specific pre-postoperative guideline for median or radial nerve paralysis as presented in this chapter for ulnar paralysis. In leprosy isolated median nerve paralysis is relatively rare.

Postoperative rehabilitation for tendon transfer in connection with median palsy requires the same sequence and timing of interventions as outlined in more detail for ulnar nerve palsy.

For the first 3-4 weeks the tendons need to be protected by splint(s) to protect tendon sutures and unwanted use of the hand. The first two weeks will focus on isolation of the muscle(s) whose tendon(s) is/are transferred, gradually building up the frequency and duration of sessions. The new function of the transferred muscle(s) needs to be integrated in pur-

poseful activities, usually by the end of the second or third week.

### **Flexor digitorum superficialis transfer**

The best transfer for opposition-abduction replacement for the thumb with consistent good results is a transfer of a flexor digitorum superficialis (FDS) tendon. This transfer is also the easiest to re-educate. Asking for flexion of the PIP joint from which the tendon has been removed, the 'donor' finger, will result in abduction-opposition of the thumb. Sometimes when patients find it difficult to isolate the muscle it may be helpful to isolate PIP flexion on the non-operated hand and then transfer the exercise to the operated hand.

The therapist and surgeon should be aware of secondary defects that may develop following removal of the FDS on the donor finger.<sup>9</sup> Timely intervention, prolonged splinting, should prevent or correct the development of a rigid flexion contracture that may develop following FDS removal.

**Other transfers:** Extensor indicis, palmaris longus, and extensor pollicis longus (Chapter 7).

Extensor indicis transfer, in my experience, gives less consistent good results when compared to a FDS transfer. Re-education should be relatively easy especially when the transfer is done in an isolated median palsy or prior to, or following, tendon transfer for ulnar palsy. In such cases isolation of the muscle-tendon can be asked for from a clenched wrist position by asking for index finger extension only. This would not be possible in a combined ulnar-median transfer when both fingers and thumb are corrected at the same time. A full fist will only be possible after several weeks of therapy. The EIP transfer is a weaker transfer than FDS



but should be of sufficient strength for positioning the thumb for pinch activities.<sup>2</sup>

Palmaris tendon is rarely used in reconstruction of the thumb in leprosy affected persons. It is often a 'muscle of choice' in the very mobile Asian hand for reconstruction in ulnar palsy. If used, re-education should be relatively easy as wrist flexion and cupping of the hand will result in contraction of the palmaris longus. Extensor pollicis longus rerouting is a definite third choice in hands that often have severe secondary defects and when few motors are available. Re-education should be relatively easy as the tendon is only re-routed but attached again to its own distal stump. Thumb IP extension should result in abduction-opposition of the thumb. Often the wrist will have to be immobilised in maximal flexion to facilitate approximation of the tendon ends. Postoperatively, the wrist will have to be gradually moved into extension again by modifying the splint regularly (2-3 times a week).

### **3. Radial Palsy: Wrist Drop**

A radial palsy is relatively uncommon in leprosy. When present it is usually associated with an ulnar and median palsy. The operation of choice is a Pronator Teres transfer for wrist correction. There are several options to correct finger and thumb extension (Chapter 8).<sup>2</sup>

The radial motor impairments need to be corrected prior to correction of possible ulnar and median motor nerve impairments. Re-education of wrist extension is relatively easy. Active pronation of the forearm will result in active wrist extension. Following flexor carpi radialis to extensor digitorum transfer, asking the patient to initiate radial wrist flexion will produce finger extension.

For median and radial tendon transfer re-education, the same goals and principles apply as listed for the ulnar palsy (see above):

Post cast removal, usually 3 weeks after surgery:

- protect the tendon suture site for the first 2-3 weeks in a splint;
- ask for active contractions without resistance for the first 2-3 weeks;
- gradually mobilise the joints again that have been immobilised for a few weeks to get the tissues to heal and
- integrate transferred tendon/muscle contractions in purposeful activities.

## **B. PRE- AND POSTOPERATIVE CARE FOR THE PARALYSED FOOT**

A footdrop correction is relatively easy when compared to tendon transfer surgery in the hand. Re-education is also less demanding and chances for postoperative complications are less. It is a procedure that is very rewarding and it will help in reducing stress on the anterior/lateral side of the foot, the site of the foot where patients are likely to develop ulcers if they have concomitant paralysis of the posterior tibial nerve.

Motivation and age are only relative contraindications for footdrop surgery. Even if the muscle-tendon unit is not working, the foot will still be in a better position. Gait will be better and the risk for (re) ulceration will be reduced.

One of the main outcome measures for footdrop correction has been the range of active dorsiflexion. More importantly, it is the placement of the range that is important and that will show whether the patient will be able to clear the ground. What is the range of active dorsiflexion as it relates to the neutral position of the foot?

An assessment form to evaluate the outcome of tendon transfer surgery for footdrop correction is given in Appendix H.

### **A Guideline: Rehabilitation of the Foot with Common Peroneal Nerve Paralysis**

*This is a Guide-line. In individual cases, depending on such things as progress made and occurrence of complications, deviations of the guidelines can/should be made. Reasons for deviating from the guidelines should always be recorded in the progress notes.*

Common peroneal involvement in leprosy may result in paralysis of the anterior tibial and/or peroneal muscles. The common peroneal nerve (lateral popliteal) consists of two branches: the deep peroneal nerve and the superficial peroneal nerve. The *deep* branch innervates the *dorsiflexors* (tibialis anterior, extensor hallucis and extensor digitorum longus), and the superficial branch the *evertors* (peroneus longus and brevis).

The site of predilection for common peroneal nerve involvement is at the head of the fibula. At this site the common peroneal nerve divides into its two branches. Depending on the extent of damage therefore, the patient may present with a complete foot drop in which both branches are affected or an incomplete/irregular footdrop, usually paralysis of the anterior tibial muscles with sparing of the evertors. Even among the anterior tibial muscle group there may sometimes be isolated weakness or paralysis of the extensor of the big toe only.

#### **Aim of the Operation and Rehabilitation:**

The goal is to obtain active dorsiflexion of the foot and restore normal gait pattern as much as possible.

The surgeon should also aim to get the right balance/position of the foot between in- and eversion. When the function/position of the foot is restored a near normal gait pattern can

be expected (no high stepping gait) and the foot will be less prone to injury. Many patients have concomitant damage of the posterior nerve also and therefore may have paralysis of intrinsic muscles of the foot and loss of protective sensation of the sole of the foot.

#### **NOTES**

*Some surgeons/therapists do not expect active dorsiflexion to take place after tendon transfer in elderly patients. Even if active dorsiflexion is not achieved, the better position of the foot may still result in an improved gait pattern and the foot is less prone to injury. It is therefore still worthwhile considering footdrop correction in elderly patients.*

#### **When surgery is not available or wanted**

For many patients with a footdrop, surgery is not available. Others, for different reasons, may not want to have surgery done when it is available. These patients could benefit from a footdrop spring or an orthoses that can be worn in a shoe.

The 'classical' footdrop spring has a cuff that starts from above the knee. It is often difficult for patients to adjust the strap in such a way that a spring is effective. It is also difficult to wear the spring under a pair of trousers. This may explain why compliance with a classical foot drop spring is often low. An alternative footdrop spring starts from below the knee.<sup>14</sup> The distal end of the cuff needs to be modified to prevent undue pressure on the dorsum of the foot.

#### **Assessment**

Pre- and postoperative assessments are mandatory if one is to say something about the end result of footdrop surgery or if modifications of techniques are to be compared (e.g. between centres or techniques). Assessment should be done pre-operative and weekly post-operative until discharge.

It is strongly recommended that specific forms be used which will facilitate the assessment of the outcome for an individual patient or cohort of patients.

**Pre-operative goals:**

- a) to achieve optimal skin condition.
- b) to reduce, if present, secondary impairments as much as possible e.g. tight Achilles tendon.
- c) to assure that the patient understands the procedure and postoperative rehabilitation involved, and to obtain his co-operation.

**Joints:** Patients with a footdrop may develop some shortening of the Achilles tendon (AT). Activities of daily living such as squatting and walking up hill usually will prevent the development of shortening of the AT. Specific exercises to 'stretch' the heel chord are therefore usually not needed. Most surgeons prefer a lengthening of the AT during surgery, which will correct some tightness if present. At the same time a lengthened AT may 'disadvantage' the transferred TP for some time, as some surgeons/therapists believe.

***Tibialis Posterior Transfer (TPT) for foot-drop correction***

*The tibialis posterior tendon is rerouted, either through the interosseus membrane or circum-tibially, to the anterior side of the foot/leg where it usually will usually be attached to the tendon(s) of the anterior tibial group. The site of insertion is determined by the extent of the paralysis.*

**'Isolation' exercises:** Often the patients are taught how to isolate the posterior tibial muscle before surgery. This may help the patient in 'finding' the muscle again in the post operative rehabilitation phase, usually 4–6 weeks after

surgery. Isolation exercises for this purpose are not essential. If a patient cannot find the muscle after surgery, it may be helpful to isolate the muscle on the non-operated foot and then 'transfer' the exercise to the operated side. Strengthening of a donor muscle is not a realistic objective. The possible effect of strengthening (if any) will be lost in the 4 – 6 weeks of immobilisation.

**Post-operative goals:**

- a) to protect tendon sutures during healing phase;
- b) to prevent/reduce/eliminate swelling;
- c) to obtain control of transferred muscle;
- d) to regain pre-operative range of motion and
- e) to integrate the new function in gait/walking.

Post-operative immobilisation will be from 4 – 6 weeks depending on the surgeon's preference and possible additional surgical procedures.

***Week 1***

*Non weightbearing. Patient is asked to activate/contract the tibialis posterior muscle. This is best achieved by asking the patient to sit cross-legged with the operated foot crossing the non-operated foot. Asking the patient to 'lift' invert the operated foot will now result in dorsiflexion of the foot.*

*In patients who have difficulty in isolating the posterior tibial muscle the therapist could start with asking for inversion of the non-operated foot and then transfer this exercise to the operated side.*

*In between exercise sessions the foot is protected in a posterior splint/back slab. This should be the bivalved surgical cast. During the first two weeks no active plantar flexion is allowed to protect the tendon suture site(s).*

*Make sure you have the patient also practice with his eyes closed or looking away from the operated foot.*

### **Week 2**

*As for week 1. When there is good control of the TP the patient could start with partial weight-bearing. (This is best done in parallel bars.)*

### **Weeks 3 – 4**

*The patient should be ready for full weight bearing. When the foot cannot be moved beyond 80-90 degrees into plantar flexion careful active plantar flexion could be initiated.*

## **Follow-up**

Ask the patient to come for review 2 – 3 months after discharge and again 1 – 2 years after discharge from the hospital. Measure angles again and comment on gait and any abnormalities, if present, in gait and position of the foot. The final outcome of foot drop surgery will only be known after 1– 2 years follow up.

## **NOTES**

- a) *Unlike TT in the hand, a footdrop correction is often considered relatively easy with respect to the procedure itself and the postoperative rehabilitation. Often a TP transfer maybe the only TT procedure that is done in some hospitals. Isolation of the TT is easily taught.*
- b) *In the circumtibial route the tendon becomes often adherent with the skin. Nothing to worry about! It is a good 'check' on the function of the muscle. Possible benefits of Ultrasound and/or friction to break the scar have not been shown and in our opinion do not compromise the excursion of the TP.*

## **C. PRE- AND POSTOPERATIVE CARE FOR THE PARALYSED FACE**

The most common paralytic condition in the face is lagophthalmos, usually as a result of an isolated paralysis of the upper branch of the facial nerve. There are different surgical procedures available to correct a lidgap. The most common procedure is a lateral or medial partial suturing of the eyelids. No therapy is needed for this procedure.

A partial transfer of the temporalis muscle will restore the possibility for active eye closure again. Little re-education is needed for this procedure. Patients usually are on a liquid diet for the first week and gradually are allowed more solid food. Biting, closing the jaws actively, will result in voluntary eye closure. Patients will not develop involuntary eye closure, or an 'unconscious', integrated, use of the transfer as in footdrop surgery or surgery for paralysis of the intrinsic muscles of the fingers.

Whether a patient should be recommended a temporalis muscle transfer should depend on the sensory status of the eye itself and if the patient makes use of the so-called Bell's phenomenon: patients with protective sensation of the eye (trigeminal nerve) will regularly 'flip up' their eyeballs. This may be sufficient to protect their eyes.

In total facial palsy additional slips of the temporalis muscle and masseter muscle can restore the facial asymmetry. No specific exercises or re-education are needed. Little is known about long-term results of eyelid surgery. An assessment form to evaluate the outcome of tendon transfer surgery for footdrop correction is also given in the appendix of the book.

Mime-therapy seems promising in idiopathic facial palsy (Bell's palsy) when there is weakness of facial muscles.<sup>1</sup> There are no reports of the use of this therapy in facial palsy due to leprosy neuropathy.

## PHYSICAL THERAPY MODALITIES

Electrotherapy may sometimes be indicated in tendon transfer surgery to help patients 'find' a muscle whose tendon has been transferred. If patients have problems finding a muscle then the first thing to do is to ask for contraction of that muscle on the contralateral side and then transfer this exercise.

Sometimes stimulation of the muscle may also be useful to find out if the muscle/tendon may have become adherent or detached (less common) in which case there will also not be an effective pull of the tendon.

Ultrasound is sometimes used to break down adhesions that may have occurred between tendons or tendon and skin. These could limit full excursion of a tendon. There is no evidence that this may be the case. Gentle friction and lengthening-shortening exercises will enhance the excursion of a tendon.<sup>2</sup>

## SUMMARY

Tendon transfer surgery is very rewarding in well-selected individuals with paralytic sequelae due to peripheral neuropathy. Most functional and cosmetic impairments can be corrected and they will often enhance the quality of life. It is mandatory that a surgeon experienced in the various procedures performs the procedures and that postoperative therapy by therapists familiar with these procedures is available.

## REFERENCES:

1. Beurskens CHG: *Mime Therapy: Rehabilitation of Facial Expression* PhD dissertation, University of Nijmegen, Netherlands, 2003
2. Brand PW, Hollister AM: *Clinical Mechanics of the Hand*, ed 3. St. Louis, Mosby, Baltimore, 1999
3. Brand PW, Brandsma JW: Paralysis of the intrinsic muscles of the fingers. *J Hand Surg* 14A:361-366, 1989

4. Brandsma JW, Brand PW: Claw finger correction: considerations in choice of technique. *J Hand Surg* 17B:615-621, 1992
5. Brandsma JW, Ottenhoff-deJonge MW. Flexor digitorum superficialis tendon transfer for intrinsic replacement: effects on donor finger. *J Hand Surg* 17B:625-628, 1992
6. Brandsma JW: Secondary defects of the hand with intrinsic paralysis: prevention, assessment and treatment. *J Hand Ther* 3:14-19, 1993
7. Brandsma JW: Monitoring motor nerve function in leprosy patients. *Lepr Rev* 71:258-267, 2000
8. Brandsma JW, Brakel WH van: Protocol for motor nerve function assessment in leprosy and related research questions. *Ind J Lepr* 73:45-58, 2001
9. Brandsma JW, Schreuders TAR: Sensible manual muscle testing to evaluate and monitor strength of the intrinsic muscles of the hand: a commentary. *J Hand Ther* 14:273-278, 2001
10. Bell-Krotoski JA, Figarola JH: Biomechanics of soft-tissue growth and remodelling with plaster casting. *J Hand Ther* 8:131-137, 1995
11. Bell-Krotoski JA: Plaster cylinder casting for contractures of the interphalangeal joints. pp 839-1845. In: MacKin EJ, Callahan AD, Skirven TM, Schneider LH, Osterman AL, (eds.): *Rehabilitation of the Hand and Upper Extremity*. Mosby Year Book, St Louis, 2002
12. Fess EE: *Hand Splinting: Principles and Methods*. Mosby CV, 1987
13. ILEP: Guidelines for identifying patients for referral for surgery. *ILEP Medical Bulletin* 1-3, 1999
14. Srinivasan H: *Prevention of disabilities in leprosy patients*. Geneva: World Health Organization, 1993

## Further recommended reading:

Bell-Krotoski JA: Preoperative and Postoperative Management of Tendon Transfers after Median and Ulnar Nerve Injury. In: *Rehabilitation of the Hand and Upper Extremity*. MacKin EJ, Callahan AD et al (eds). Mosby Co, pp: 799-820, 2002

Breeger D: Pre-and postsurgical therapy and management of a patient with intrinsic minus hand. *J Hand Ther* 2: 177-184, 1989



Kelly ED: Physical Therapy in Leprosy for Paramedicals. American Leprosy Missions, Greenville SC USA, 1978

Reynolds CC. Preoperative and Postoperative Management of Tendon Transfers after Radial Nerve Injury. In: Rehabilitation of the Hand and Upper Extremity. MacKin EJ, Callahan AD et al (eds). Mosby Co, pp: 821-831.

Srinivasan H, Palande DD: Essential Surgery in Leprosy. WHO, Geneva, 1997

Warren G: The Care of Neuropathic Limbs: a practical manual. Parthenon Publishing, New York, London, 1999

Watson JM: Prevention of Disabilities in Leprosy. The Leprosy Mission, 1986

Indian Journal of Leprosy. Special issue: Re-ablement of the Hand in Leprosy. Vol. 69: January-March, 1997

# Unfavourable Outcomes after Reconstructive Surgery in Leprosy

• G.N. MALAVYA

## INTRODUCTION

Any surgical procedure has a risk of morbidity and these are generally complications of the anaesthetic or the procedure itself. In consenting the patient for the proposed operation it is these risks and benefits which are considered before agreeing to the operation. Complications can lead to an unfavourable result, but in reconstructive surgery it is usually a technical failure that leads to a suboptimal result. An unfavourable result after a tendon transfer or cosmetic procedure is not unusual and determining the causes of such an outcome may give insight into its treatment and future prevention.

There is a scarcity of information in the literature regarding unfavourable results of corrective surgery in leprosy patients. Most of these outcomes are due to one or more of the following factors - wrong surgical plan made due to an overlooked problem at the proposed operative site, imperfect technique, inadequate physiotherapy, non-cooperation of the patient or a surgical complication such as sepsis or a tendon fixation gives way. Occasionally having an unrealistic expectation and selecting a procedure in an overzealous attempt to restore normalcy can lead to a poor result.

Lack of anatomical knowledge is at the root of many surgical errors. Anatomy does not change but with advances in surgical techniques our needs for an understanding of various structures change.

A careful evaluation of the unfavourable result may reveal the factor(s) which can be

held responsible for such an outcome. It may not be possible to give the exact incidence of these outcomes because of inadequate follow-up.

Initial examination of the patient is an important first step in avoiding an unsatisfactory result.<sup>9</sup> One must evaluate both the deformity and patient and get a general idea whether or not surgical procedures are necessary, what can be achieved by surgery and how. Psychiatric morbidity is extremely common in leprosy patients, the commonest being neurosis.<sup>22</sup>

Long term follow-up is not only instructive but is necessary for a good result. Patients need reinforcement of their efforts which is best provided by periodic visits to the therapist. In the post-operative period note any lack of compliance to post-operative treatment and search out reasons for this rather than simply blame them. There may be an underlying social or financial problem. The aspirations of the patient are also changing<sup>22</sup> perhaps because of the hope being given to them by field staff or because of increasing medical knowledge in the population. These over expectations of patients may be a factor in some of these bad results because patients lose motivation when they see the reality.

The general complications which can occur with any surgery viz. infections, scarring, hypertrophic scars, tourniquet injury and increased cold sensitivity can occur in any case. In some cases, leprosy disease might show exacerbation whereas in some others a lepra

reaction might develop in spite of all the precautions.

Ischemia deserves special mention because many of these anaesthetic and paralysed hands show positive Raynaud's phenomena i.e. finger tips first become pale and then discoloured bluish when exposed to cold. Fingers may also swell-up. One has to be careful while immobilising the limb in a complete plaster cast after surgery, in situations where controlled room temperatures are not available during winter.

Adhesions may form along the course of the transferred tendon if tissue handling technique is poor or tendon suturing is not done properly. These adhesions interfere with tendon gliding and in severe cases transferred muscle may become non-functional. In mild cases gentle massage along the course of the tendon, electrical stimulation of muscle and ultrasonic therapy can help to break these adhesions. In severe cases, formal tenolysis might be required.

The unfavourable outcomes can be listed according to the type of surgery performed.

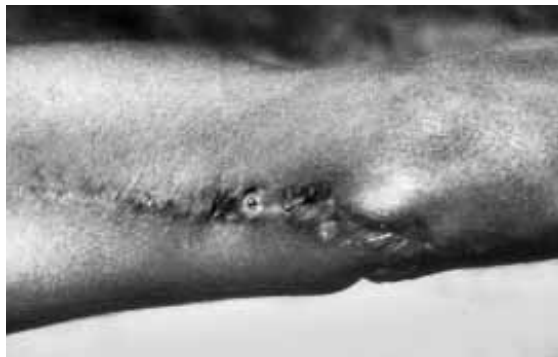## NERVE DECOMPRESSIONS

Peripheral nerve trunk decompressions can be performed in leprosy either for relief of intractable pain, to drain a chronic abscess or to restore sensory -motor functions in cases in which steroids have not helped. Although these procedures are quite straight forward, they have their own set of unfavourable outcomes.

The scar may become adherent to the nerve trunk restricting the mobility of nerve and may cause a traction injury. Such nerves may become painful and need re-exploration to release adhesions. Locally available subcutaneous tissue can be brought in as a flap to lie between the skin and nerve and also to cover the nerve.

In cases where nerve abscess has been evacuated a discharging sinus may form in the line

of scar which refuses to heal (Fig. 22-1). The sinus may need excision and removal of necrotic tissue, or a course of rifampicin and isoniazid can be tried which may dry the sinuses in about six months.<sup>10</sup>



**FIGURE 22-1** Sinus along the line of incision for cubital tunnel decompression.

A patient who has undergone nerve decompression should not have prolonged and significantly greater pain post-operatively even though sensations described as paraesthesia and dyesthesia may develop, in some cases even months after surgery. For paraesthesias dilantin has been tried but is not very successful. Carbamazepine (Tegrital) has relieved symptoms in some cases but needs careful monitoring.

The surgical trauma can lead to progression of paralysis. It is unlikely that a good surgical release will precipitate acute neuritis in other nerves due to sudden release of antigens because the patients are given steroids post-operatively.<sup>26</sup>

### Cubital tunnel decompression

After cubital tunnel decompression and the release of Osborne ligament the ulnar nerve may start subluxating or even dislocating when elbow is flexed. This may require an anterior transposition or medial epicondylectomy depending upon the width of the medial

epicondyle. If the epicondyle is larger in size it is easier to perform an anterior transposition.

The segmental and longitudinal blood supply of the nerve should be preserved as much as possible. Excessive mobilisation of the inflamed ischemic nerve trunk can be deleterious. Excision of the medial intermuscular septum if not done adequately may lead to incomplete decompression and dampen the process of recovery or rather may be more damaging. The medial head of triceps may snap against the nerve trunk causing recurrent injury.

The elbow and surrounding area may become anaesthetic due to injury of the medial cutaneous nerve of forearm. A neuroma may form. Persistent oozing from the nerve surface and/or nerve bed may lead to haematoma formation and secondary scarring. Fascicular neurolysis (which is not recommended) may induce intraneural fibrosis and cause nerve fiber damage. Prolonged immobilisation can lead to a stiff elbow.

### **Carpal tunnel decompression**

Incomplete division of either the area of nerve compression proximal to the transverse carpal ligament or the most distal part of the carpal ligament can result in failure of nerve recovery. Following carpal tunnel decompression the fingers should be exercised and wrist immobilised in 10° extension to prevent prolapse of nerve trunk in the wound which may cause adhesion formation. Damage to the palmar cutaneous branch of the median nerve can occur.

### **Common peroneal and posterior tibial nerve decompression**

Drop foot may develop due to excessive traction on the common peroneal nerve while the nerve is being decompressed for neuralgic pain or nerve abscess. Injury to posterior tibial vessels may occur while dissecting the nerve trunk

in the neurovascular bundle during tarsal tunnel decompressions.

## **CLAW FINGER CORRECTION**

The overall success rate of claw finger correction varies from 75-90% depending upon the procedure and assessment criteria used. The results are usually reported in terms of fingers, not in the context of the whole hand.<sup>4,5,19,20,28,29</sup> Even though it is said that results are stable after one year following surgery, the condition of the hand alters subsequently due to available care, overuse and misuse.

Correction of claw finger deformity requires a precise balancing of flexor and extensor forces across MCP and PIP joints of the fingers.<sup>7,13</sup> There can be a recurrence of clawing. The most common cause of recurrence is difficulty in re-educating the transferred muscle tendon unit in cases where dynamic correction has been made. Active co-operation of the patient is required to isolate and activate the transfer, which is difficult in older age groups especially with long standing paralysis or low intelligence. Low motivation in patients to learn, and lack of trained staff to educate may also affect the result of the operation.<sup>21</sup>

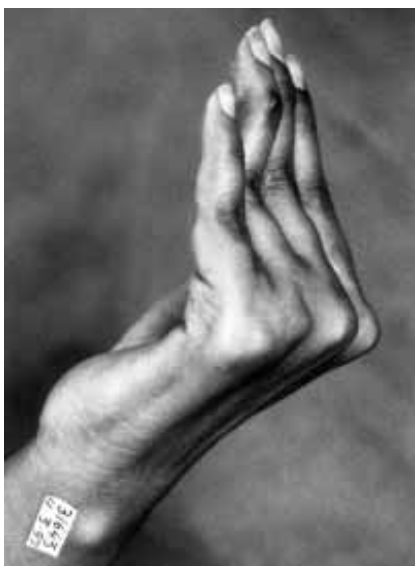There is always some loss of the tension during post-operative exercises due to stretching. Poor tendon to graft juncture, improper adjustment of tensions on individual slips or one of the slips getting loose, can alter length-tension relationships during the post-operative period and result in recurrence of clawing in one or more fingers. Such an event requires re-exploration to tighten or re-attach the slip(s) after properly positioning the fingers.

Overlooked residual long flexor contractures, boutonniere deformity and wrist flexing habit (which patients develop as an adaptation to live with their claw deformity) in cases having long standing paralysis also contribute to

recurrence. Volarly routed transfers lose some mechanical advantage when the wrist is flexed and suffer from disuse. The use of a volar wrist splint for several months after surgery and periodic supervision till the transfer is integrated into its new role, can help overcome this problem.

### **Swan Neck Deformity**

Problems of over-correction are seen in cases where insertions have been made in lateral bands especially in hands with long thin fingers having hypermobile joints (Fig. 22-2). Lateral band insertion procedures<sup>2,5,12</sup> add to PIP joint extensor forces as a result of which the PIP joint hyper-extends and the DIP joint flexes. This intrinsic plus deformity is severely disabling because it interferes with fist closure and grasp function. In hands with long thin fingers and hypermobile joints, over enthusiastic efforts to exercise PIP and DIP joints can damage PIP joint mechanisms (volar restraints) accentuating PIP joint hyperextension. Over correction was noted in about 15% cases by Brand<sup>5</sup> and 8% by Palande.<sup>20</sup>



**FIGURE 22-2** Intrinsic Plus Deformity after lateral band insertion procedure for correction of finger clawing.

Removal of the flexor digitorum superficialis (FDS) from a finger produces several problems of which "check rein" and "swan-neck" deformity are well known (Fig. 22-3).<sup>8,24,25</sup>

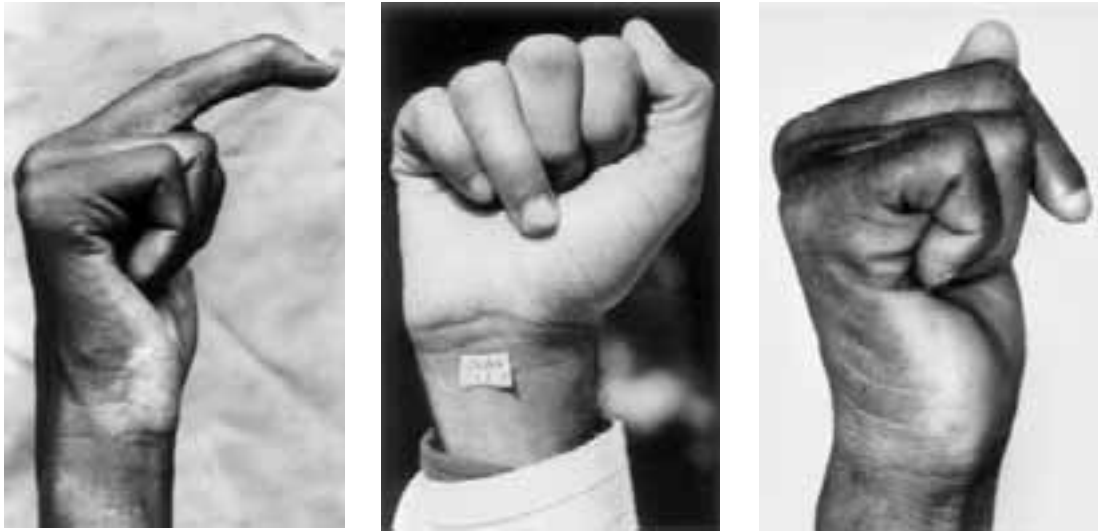
Superficialis minus deformity is seen in 50% of fingers where FDS has been removed, more often in patients with hypermobile finger joints.<sup>8</sup> It is characterised by extension of the PIP joint and flexion of the DIP joint. It is very much like intrinsic plus deformity but the mechanisms are different. In swan-neck deformity, extensor predominance over PIP joint is due to removal of FDS and laxity of volar plate of PIP joint. When the FDP attempts to flex the finger its smaller moment arm at the DIP joint results in DIP joint hyperflexion without PIP joint flexion. The problem is accentuated by attaching a motor unit to the lateral bands.

The best treatment is prevention. There is an increased incidence of swan-neck and check-rein deformities using a lateral incision as compared to a distal palmar incision. North and Littler<sup>18</sup> suggested removing FDS through the proximal digital crease incision leaving about a 2 cm long FDS stump in situ to reinforce the volar plate. They felt that this would minimize the risk of superficialis minus deformity.

### **PIP Joint Extension Limitation**

Check-rein deformity is characterised by a rigid flexion contracture of the PIP joint due to scarring at the level of division of the FDS to the tendon sheath, may appear as late as 7 to 9 months post-operatively. It must be diagnosed early, at which point cylindrical casting will both treat it and prevent its progression. The deformity can often be readily corrected by forceful extension of the joint to tear the adhesion if diagnosed in the immediate postoperative period. If it is diagnosed late and is not correctable by physiotherapy, operative release of the adhesions is indicated with post-operative splinting to prevent recurrence.





**FIGURE 22-3** Problems seen after removal of FDS for transfer. **a.** Flexion of DIP joint **b.** Incomplete fist closure. **c.** PIP joint flexion limitation.

Active PIP joint extension limitation may occur due to overlooked attritional boutonniere deformity, inadequate tension on the transferred slips, or residual long flexor contractures. This is differentiated from a check-rein deformity in which there is both active and passive PIP joint extension limitation.

MCP joint extension contracture is mostly seen with dorsally routed transfers like the extensor many tailed procedure and is either due to adherence of tendon juncture in the distal forearm and/or wrist or due to adherence of the transferred slip to inter-metacarpal fascia.

### **Other Unfavourable Results**

Inability to completely close the fist is seen in cases where FDS from ring finger has been removed for claw finger correction or opponensplasty. In high ulnar paralysis, ring and little finger profundus tendons may be weak and when FDS is removed, profundus alone is unable to flex those fingers completely. FDS should not be removed from the ring finger if the FDP is weak. Reduced grip strength is some times complained of by patients who have

their ulnar-median palsy corrected by FDS transfers.

Distal transverse metacarpal arch (DTMA) may be reversed in some cases pre-operatively and can get exaggerated when conventional lateral band insertion procedures are used, especially those where the motor is dorsally routed. Due to reversal of DTMA the cascading pattern of finger closure is altered and instead of converging towards the scaphoid tubercle in the palm, the fingers are splayed so that total contact digito-palmar grasp is not possible. Ranney<sup>23</sup> has described the procedures to restore it to normal.

Median nerve damage during procedures that route a tendon through the carpal tunnel has long been considered a risk. Brandsma and Brand<sup>6</sup> have shown that when the tendon is tunneled correctly through the carpal tunnel there is no increased risk of loss of median nerve function. There is sufficient space in the normal CT to accommodate one more tendon. If the tendon tunnel is passed close to the floor of tunnel posterior to all tendons, the risk of injury to the median nerve is minimal. If the

tip of tunneler is not fully closed the branches to the thenar muscles are at risk. The nerve should be carefully retracted towards the thumb to protect it because a medial retraction is likely to stretch the motor branch. Median nerve palsy detected in the early post-operative phase is likely to be due to direct injury to the nerve and there is a possibility of recovery in the coming 6 to 8 weeks. If the palsy is insidious, appearing after about 6 months or more, it is likely to be due to attrition of the nerve in the carpal tunnel.

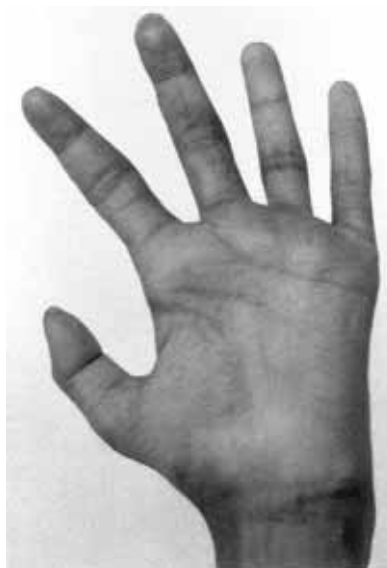
Deviation of fingers to the radial or ulnar side post-operatively on fully opening the fingers may be seen. The potential causes are several. There may have been poor alignment of tendon slips in the proximal palm, imbalanced tension during insertions or there may be radial or ulnar guttering of extensor tendons. In pulley advancement procedures, too much excision of a pulley can cause drift due to off center pull of flexors. Radial drift may also develop because of an intrinsic plus due to excessive tension on transfers or intrinsic recovery (Fig. 22-4).

## OPPONENSPLASTIES

In leprosy ulnar-median paralysis is more common than isolated median palsies. An overlooked web space contracture before surgery may prevent full abduction and pronation of the thumb.<sup>14</sup>

A common problem seen after surgery in cases who have ulnar-median palsy is recurrence of a thumb web contracture. Even in cases where the webspace has been restored by serial splinting pre-operatively the web contracture may recur.

Patients with long standing ulnar-median palsies tend to use key pinch for thumb function. This is done using the long extensor. With this adaptation the thumb web contracts. This



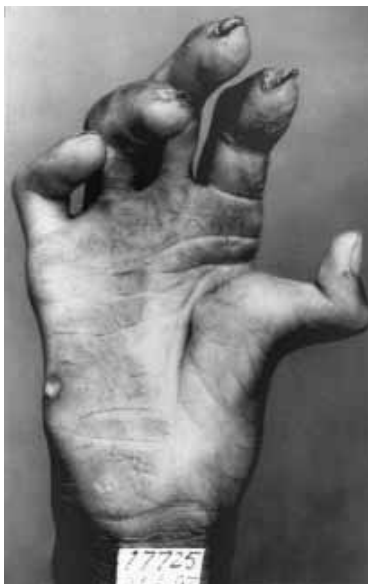**FIGURE 22-4** Post-operative radial deviation of fingers.

adaptive movement is difficult to correct with therapy, and is one of the important causes of failed surgery. This can be corrected by extensor pollicis longus re-routing (see Chapter 7 also for discussion of crankshaft deformity).

Migration of the pulley may adversely alter the mechanics of the transfer. Migration of the transfer anterior to MCP joint flexion axis leads to excessive MCP joint flexion whereas posterior migration leads to a Z-pinch with hyperextension of MCP joint (Fig. 22-5). The latter can be corrected by re-routing the tendon distal to the MCP joint, or by carrying out a MCP joint arthrodesis.

In extensor indicis opponensplasty there may be some extensor lag in the index finger and in some cases independent extension of the index finger is lost.

Subluxation of the CMC joint of the thumb may occur in ulnar median palsy and can prevent function of the opponensplasty. Overlooked contractures in trapezo-metacarpal joint may also render an opponensplasty ineffective (See Chapter 7).



**FIGURE 22-5** "Z" Pinch due to radial migration of transfer.

## RADIAL NERVE PALSY RECONSTRUCTIONS

These are usually seen in association with ulnar and or ulnar-median nerve palsies. The accepted procedure for correction of wrist drop involves transfer of pronator teres to ECRB. Occasionally full wrist extension is not achieved. The excursion of pronator teres may be a limiting factor although it is more likely to be due to poor technique or adhesions. Wrist extension may be weak due to less tension in wrist dorsiflexors and patients may complain of poor grip.

High tension in the finger extensors may result in a weak grip.

One handed activity patterns are seen in cases who have unilateral palsies. Since the other hand is normal, patients start using the unaffected hand for most of their daily activities as they find it more convenient. Consequently, when the patient is expected to use the operated hand during rehabilitation, he fails to do so and the transferred muscle is unable to integrate itself into its new role. This

problem is more severe in persons in whom the non-dominant hand has been surgically corrected.<sup>16</sup>

## DROP FOOT CORRECTION

These problems are covered in Chapter 14.

## FACIAL SURGERY

Local procedures such as medial canthoplasty or tarsorrhaphy may be ineffective in controlling tearing and corneal exposure. A longer length of tarsorrhaphy not only looks unsightly but it also interferes with the temporal field of vision. An ineffective procedure on the medial side can be supplemented with a lateral procedure such as a lateral tarsal strip procedure. If local procedures fail to treat the lagophthalmos, a temporalis muscle transfer can be done.

### *Temporalis Muscle Transfer*

1. Dynamic correction of lagophthalmos using temporalis musculofascial sling requires motivation on the part of patient.<sup>1</sup> Unwillingness to learn the use of transfer badly affects the result.
2. The transfer may be too loose in which case it can be tightened through a small incision at the lateral canthus. There may be a residual lag apparent only on lying supine as in sleeping. The eyes therefore need protection during sleep.
3. The transfer may be too tight with restriction of vision. In this situation the upper slip can be divided at the lateral canthus. Z-lengthening is usually ineffective.
4. The lachrymal sac may get injured while suturing the transferred slips at the medial angle of the eye leading to dacryocystitis.
5. Post-operatively ectropion can occur due to inferior migration of the lower slip. This can be corrected by exposing the entire lower

slip and holding it up beside the tarsal plate with prolene sutures which can be pulled out in ten days.

- The muscle may leave a cosmetically unacceptable bulk at the side of the face.

### ***Eyebrow Reconstruction***

Restoration of eyebrows either with a skin graft or a skin flap can lead to subsequent problems. Loss of hair may occur and the reconstructed eyebrow may not look as convincing as it used to be immediately after surgery due to poor growth of the hairs. While suturing it is to be ensured that the graft lies on the orbicularis muscle bed and not on subcutaneous tissues. While defatting the graft the hair bulbs need to be carefully preserved. Patchy growth of hair in eye brows does not give a good cosmetic result. This can be remedied by rice-planting technique (see Chapter 20).

### **CONCLUSIONS**

While reporting our results we often fail to mention possible pitfalls and assume that other clinicians will learn by their own observations and experience. It is essential that persons who want to undertake such surgery be forewarned so that they do not repeat avoidable errors. The chances for an undesirable result can generally be reduced by application of basic principles, careful assessment of a given patient, application of the dynamics of surgery and anticipation of the idiosyncrasies of each transfer. When unfavourable outcomes do occur they should be dealt with promptly with realistic reassurance of the patient.

### **REFERENCES**

- Antia NH: The temporalis musculofascial sling for correction of lagophthalmos. *Ind J Surg* 28:389-396, 1966
- Antia NH: The palmaris longus motor for lumbrical replacement. *The Hand* 1:139-145, 1969
- Antia NH, Pandya NJ: Surgical correction of nasal deformities in leprosy: A 16-year review. *Plast Reconstr Surg* 60:768-777, 1977
- Brand PW: Paralytic claw hand. *J Bone Joint Surg* 40-B: 618-632, 1958
- Brand PW: Tendon grafting: Illustrated by a new operation for intrinsic paralysis of the fingers. *J Bone Joint Surg* 43-B:444-453, 1961
- Brandsma JW, Brand PW: Median nerve function after tendon transfer for ulnar paralysis. *J Hand Surg* 10-B:30-32, 1985
- Brandsma JW, Ottenhoff de Jonge. Flexor digitorum superficialis tendons transfer for intrinsic replacement. Long term results and defects on donor fingers. *J Hand Surg* 17B:625-628, 1992
- Brandsma JW, Brand PW: Claw finger correction: Considerations in the choice of technique. *J Hand Surg* 17B:615-621, 1995
- Burkhalter WE: Complications of tendon transfers for nerve paralysis in the hand. pp 60-69. In Boswick JA (ed): *Complications of Hand Surgery* 1st Ed. WB Saunders, Philadelphia, 1986
- Husain S, Mishra B, Malaviya GN: Rifampicin and Isoniazid in the treatment of leprosy nerve abscess. *Acta Leprologica* 10:199-201, 1997
- Kulkarni, VN, Mehta, JM: Observations of tarsal disintegration in the cases operated for foot drop. *Ind J Lepr* 57:598-600, 1985
- Little JW: Tendon transfers and arthrodesis in combined median and ulnar paralysis. *J Bone Joint Surg*,31-A: 225-234, 1949
- Malaviya GN: Present trends in correction of claw fingers in leprosy. *Euro J Plast Surg* 13:115-118, 1990
- Malaviya GN: Restoration of abduction opposition of thumb with reference to leprosy palsy. *Euro J Plast Surg* 13:120-125, 1991
- Malaviya GN, Husain S: Correction of mild and moderately collapsed nose in leprosy patients using a second metatarsal cortico-periosteal bone graft -II, Long term follow-up results. *Euro J Plast Surg* 18:114-117, 1994
- Malaviya, GN: Unfavourable results after claw finger correction surgery as seen in leprosy. *Ind J Lepr* 69:43-52, 1997
- Malaviya, GN: Median nerve palsy following claw finger correction in leprosy: effect of M. leprae or a consequence of surgery. *Ind J Lepr* 74:217-220, 2002

18. North ER, Littler, JW: Transferring the flexor superficialis tendon. Technical considerations in the prevention of proximal interphalangeal joint disability. *J Hand Surg* 5:498-501, 1980
19. Palande DD: Correction of paralytic claw fingers in leprosy by capsulorrhaphy and pulley advancement. *J Bone Joint Surg* 65-A:514-521, 1976
20. Palande DD: Correction of intrinsic minus hands with reversal of transverse metacarpal arch. *J Bone Joint Surg* 58-A:59-66, 1983
21. Palande DD: Surgical correction of intrinsic minus fingers. *Ind J Lepr* 58:537-542, 1986
22. Ramnathan U, Malaviya GN, JainN, Husain, S: Psychosocial aspects of deformed leprosy patients undergoing surgical correction. *Lepr Review* 62:402- 410, 1991
23. Ranney DA: Restoration of hypothenar muscle function in ulnar nerve paralysis. *Lepr Rev* 44:196-202, 1973
24. Ranney DA: The Superficialis minus deformity and its treatment. *The Hand* 8:209-214, 1976
25. Reddy NR, Kolumban SL: Effects on fingers of leprosy patients having removal of sublimis tendons. *Lepr India* 53:594-599, 1981
26. Rydevik B, Lundborg G, Nordborg C: Intraneural tissue reaction induced by internal neurolysis. *Scand J Plast Reconstr Surg.* 10:3-8, 1976
27. Selvapandian AJ: Surgical correction of foot drop. pp 330-339. In McDowell F, Enna CD (eds): *Surgical rehabilitation in leprosy.* Williams and Wilkins, Baltimore, 1974
28. Srinivasan H: Extensor Diversion -A new approach in correction of intrinsic minus fingers. *J Bone Joint Surg* 55-B:58-65, 1973
29. Srinivasan H: Dermadesis and flexor pulley advancement. First report on a simpler operation for correction of paralytic claw fingers in patients with leprosy. *J Hand Surg* 10:979-982, 1985



## Orthotics and Prosthetics in Neuropathy

• C. VISSER  
S. MEANLEY

### INTRODUCTION

Chapter 17 focussed on footwear and in-shoe orthotic devices which are important in the prevention and management of foot ulcers associated with loss of protective sensation. Unfortunately, some people require more sophisticated appliances than in-shoe orthotic devices and (modified) footwear. Impaired sensory and motor nerve function and amputations at different levels may have a great impact on daily activities. The use of orthopaedic appliances (prostheses and orthoses) can enable people to overcome difficulties in mobility and in their “Activities of Daily Living” (ADL). Sometimes the appliance is used for a short time only for therapeutic purposes. An example of this is a backslab, as described later in this chapter. Often however, an appliance has to be used permanently if optimal mobility is to be maintained. Examples of these are orthoses for foot-drop and prostheses.

An orthopaedic workshop is essential in a tertiary referral hospital where reconstructive surgery is offered. Some orthopaedic appliances are leprosy specific, but most are also beneficial for those whose disability is unrelated to leprosy.<sup>9</sup> It can be advantageous for a leprosy institution to produce appliances suitable for those with leprosy and other conditions. The number of prosthetic and orthotic personnel in developing countries can not meet the need in general physical rehabilitation.<sup>17,19</sup> Therefore using the resources available at the leprosy hospital for non-leprosy related conditions can provide a service to the local community, while at the same time it may generate

income for the hospital. This can also help in reducing the stigma related to leprosy.

Successful rehabilitation often requires the skills of a number of different professions. Prosthetists and Orthotists combine with other paramedical and medical personnel to form the rehabilitation team. A multidisciplinary approach will increase the quality of care (Chapter 24). Therefore having the workshop situated near or as part of a hospital is advantageous.<sup>19</sup>

There are a few general guidelines for orthopaedic appliances:

- *Good fitting.* When protective sensation is lost, it is not always possible for the user to provide feedback on the fit of the device. If pressure points are not observed in time and the necessary alterations carried out, ulceration can result, so good fitting is essential.
- *Affordability and availability* often go together. When local materials are being used the availability will increase. At the same time prices can be kept reasonably low.
- *Cultural appropriateness.* Whenever possible, cosmetic/ cultural aspects should be kept in mind.<sup>22</sup> When appliances are not culturally acceptable, people will not be motivated to use them. It is better to have a reasonable but accepted appliance, than the best appliance, which is not accepted.

This chapter gives an overview of orthopaedic appliances commonly used for people with conditions resulting from leprosy.

Many of these conditions are secondary to peripheral neuropathy. There are several ways to classify orthopaedic appliances. In general terms, *prosthesis* is a device which replaces a part of the body, while an *orthosis* assists the body to regain lost function. In this chapter we look at how orthopaedic appliances for the lower limb can be beneficial for those with loss of sensation, loss of muscle power, loss of joint stability and loss of a limb.

### LOSS OF SENSATION

Sensory neuropathy in leprosy can result in “glove and stocking” anaesthesia as the peripheral nerves innervating the upper limb distal to the elbow and the lower limb distal to the knee are affected. The main danger arising from this results from neglected injury.<sup>1</sup> This neglect is due to lack of pain following injury, and can be combated by education in terms of an increase in awareness of the need for vigilance in self-care and protection of vulnerable areas of the body.

A number of different devices can be used to reduce the likelihood of injury. Footwear with special insoles are the key in the battle to protect the foot from ulcers which can ultimately lead to infection and even amputation.<sup>1,3</sup> This has been discussed in detail in Chapter 17, so will not be covered here.

People living in cultures where cross-legged sitting is common may develop ulcers on the lateral malleoli.<sup>1</sup> Cups or rings made from micro-cellular rubber (MCR) can be used to off-load the malleoli when prolonged sitting in this position is expected.

Repetitive or extensive use of hand tools or kitchen utensils can also be a cause of concern. The use of gloves or a thick cloth to protect the hands from hot items, for instance when cooking, is second nature to those with intact sensation, but may need to be reinforced as an

essential part of the self-care routine when peripheral neuropathy is present.

Adapting or modifying tools is also an option (see also Chapters 10 and 24). The grip of a neuropathic hand can be very strong, resulting in high pressure points, which need to be eliminated or reduced substantially if the hand is to be safe. Two laws of physics come into play here. Firstly, it is to be remembered that the force applied by the hand on the tool will be equal and opposite to the force applied by the tool on the hand (Newton’s First Law). Secondly, the pressure applied on the hand is equal to the force used to grip, divided by the area of the hand in contact with the tool. Therefore by distributing the forces over a larger surface of the hand, peak forces can be reduced.

This can be achieved simply by covering the grip of the tool with MCR, or by changing the shape of the grip of the tool to the anatomical hand-shape of the user. Anatomical grips can be made by carving wood, Appropriate Paper-based Technology (APT) or the use of epoxy resin putty.<sup>29,30</sup>

The latter two methods use a soft grip, which is moulded to the required shape and then sets to form the definitive handle.

### LOSS OF MUSCLE POWER

A second effect of neuropathy is loss of muscle power. As this effect is not universal, an imbalance occurs affecting the resting position of various joints as well as the more obvious functional loss. This can occur in both the upper and lower limbs. However, this chapter concentrates on lower limb problems. The posterior tibial and peroneal nerves are commonly affected in leprosy. The posterior tibial nerve innervates the intrinsic muscles of the foot, and when affected clawing of the toes and flattening of the arch can result (see Chapter 14).

Paralysis of the common peroneal nerve results in loss of function of the muscles which are responsible for dorsiflexing and everting the foot. The common term used for this condition is “foot-drop”. Foot-drop has an enormous effect on gait. Dorsiflexors are active during the swing phase of gait when they lift the foot to clear the floor and also immediately following heel strike when they control the rate of plantarflexion. A person with this condition, therefore, struggles to clear the ground in swing, the effective length of the leg below the knee being longer than normal.

There are two common ways to compensate for this. These are “high-stepping” gait and circumduction.<sup>5</sup> High-stepping gait is most commonly seen when knee and hip function has not been affected. In this type of gait the person lifts the foot higher from the ground by using extra flexion of the hip and knee. When compensating for foot-drop with circumduction, a combination of abduction, flexion and hiking of the hip is used to advance the leg.

Reduction in the ability to use the dorsiflexors of the foot in early stance will result in a condition known as “footslap”, as the descent of the forefoot to the ground is not well controlled and sometimes an audible slap can be heard. If dorsiflexion is severely affected, then the forefoot will contact the ground before the heel in the classic “toe-heel” gait.

Reconstructive surgery can bring a long-term solution compensating for loss of muscle power in the dorsiflexors and evertors. However, this is not always appropriate clinically, or even desirable to the patient. In this case, benefit can be derived from an orthosis to control unwanted movement. According to Neville 1-2% of patients do need some sort of appliance for footdrop.<sup>14</sup>

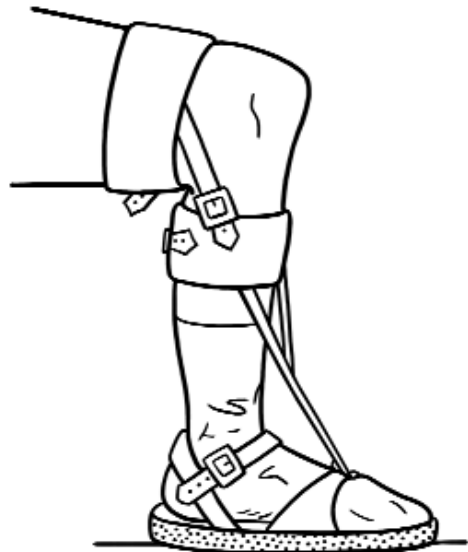
### **Ankle Foot Orthoses for footdrop**

The function of these orthoses is to substitute for dorsiflexion during the swing phase of gait

in order to provide ground clearance. As with all orthoses, comfort, ease of donning and doffing, and cosmetic appearance all need to be acceptable. The device should be both affordable and maintainable. As these orthoses are used to control the ankle and foot, they are known as Ankle Foot Orthoses (AFOs). These orthoses can be custom-made or prefabricated. If the latter are used, small adjustments are usually necessary to make them suitable for the client. The conventional AFOs using metal bars with a joint connected to the shoe are still common, although thermoplastic designs are rapidly becoming more common in Asia and Latin America<sup>7,15,23,29</sup> The main advantages of thermoplastic AFOs are their low weight and more cosmetic appearance. Several designs of AFO are possible. The appropriate choice will depend on clinical appropriateness, the personal wishes of the user, the skills of the technicians and the materials available.

### **Footdrop springs**

The simplest design is the foot-drop spring (Fig. 23-1). This has been used in leprosy since the early 1960s.<sup>1</sup> The basic design uses a leather



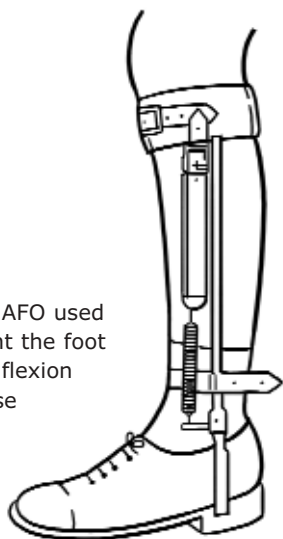**FIGURE 23-1** Footdrop spring. The elastic band keeps the foot in dorsiflexion during the swing phase of gait (with permission from Fritsch<sup>9</sup>).

cuff just below the knee, which is connected to the footwear by means of an elastic strap or a spring. Sometimes a second cuff is used above the knee to prevent the whole orthosis from slipping distally. The connection of the strap to the foot is at the level of the fourth metatarsal head to control the inversion/eversion of the foot.<sup>26</sup>

### Metal and Leather AFOs

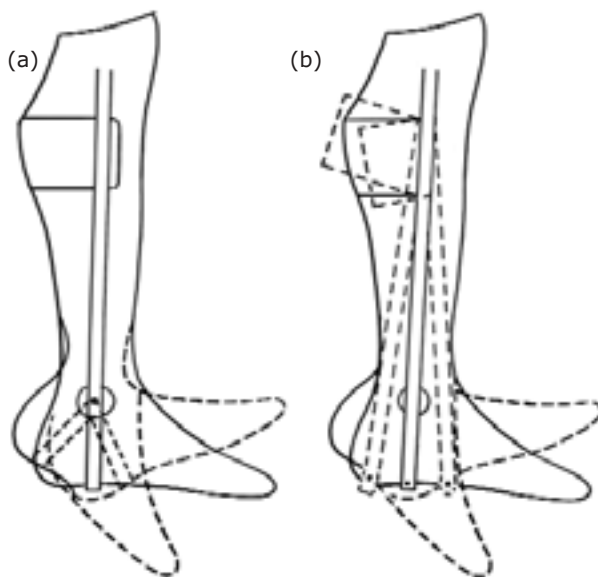
The use of metal and leather in AFO construction is the classical concept. Prefabricated metal components are produced in many countries, but making the device directly out of metal bar is also possible. Metal is often readily available, and techniques and skills to work with metal are widely known and commonly used. Huckstep and Dartnell both describe such AFOs.<sup>4,10</sup>

The basic design of a conventional AFO is a strong shoe with metal bars on either side of the lower leg, leading to a calf band and cuff. The AFO allows for dorsi- and plantarflexion of the ankle. The design used in Uganda for polio is simple, cheap and effective.<sup>10</sup> It allows plantar flexion after heel-strike and a normal rollover and push-off (Fig. 23-2). The spring pulls the foot into dorsiflexion during the



**FIGURE 23-2** Metal AFO used for footdrop to prevent the foot from going in plantar flexion during the swing phase (Huckstep<sup>10</sup>).

swing phase of gait, allowing for adequate ground clearance. It is very important that the joint centres and axes of the anatomical ankle and of the AFO correspond with each other (Fig. 23-3). If this is not the case, there will be strain on both joints and skin problems are likely. The connection between the metal sidebars and the footwear is made using a metal plate built into the heel and sole of the shoe. The size and strength of this is important to effect a good connection between the shoe and the AFO and the finished product needs to be smooth enough not to cause skin problems in the foot.



- axis of AFO
- O axis of ankle
- neutral position
- dorsal or plantar flexion

**FIGURE 23-3** The optimal position is when the axis of the AFO and axis of the ankle are in line with each other (A). If they are not in line (B), discomfort is experienced during plantar or dorsiflexion of the foot.

### Cosmetic AFOs

In more recent years a number of materials have been used in order to overcome the bulky nature of the foot-drop spring and the metal

metal-leather AFO. When limb volume is stable, it is often possible to manufacture an effective device which follows the contours of the leg more closely, and is often deemed more cosmetically acceptable. For this reason, they are known as “cosmetic AFOs”.

This type of AFO is manufactured on a modified cast of the client’s lower leg. To make this, a sock is used against the skin and marked in the pressure sensitive areas with a water-soluble pencil. A wrap cast is taken of the leg with the ankle in neutral or slightly dorsiflexed and the sub-talar joint in neutral. When dry this is removed, sealed and filled with plaster of Paris to provide a basic model of the lower leg. Accurate modification of this is essential to ensure that the close-fitting AFO does not cause skin problems and that it fits into the footwear. The model is then used to provide the desired shape for the AFO, which may be made from several different materials. In this section we look at orthoses made from resin and thermoplastics.

### Resin AFOs

The manufacture of resin AFOs is described by Neville.<sup>14</sup> This is a solid ankle AFO, allowing neither plantarflexion nor dorsiflexion. A positive model is made as above and then covered with a padding material such as evazote or plastazote, which can be moulded to the cast when heated in an oven at 130°-150° Celsius. It is then wrapped round the cast with care taken to avoid creases which could cause skin damage and weaken the AFO. The strength of the AFO comes from the reinforced resin layer which is applied on top of this. Polyester, acrylic or epoxy resins are most commonly used, all of which have slightly different properties. These resins come in a liquid form and are hardened by mixing them with a setting agent and allowing a chemical reaction to take place. Fumes from this process can be harmful, so care should be taken to minimise likelihood of inhalation. The resin mix is held in place by

means of an inner and outer plastic bag or sheet and is reinforced by layers of stockinette and if available, glass fibre. Resin is poured into one end of the sealed bags and drawn down into the reinforcing fibres to form the desired shape. This can be aided with suction. Once the resin has hardened and cooled the AFO can be finished by cutting it from the model, trimming it to shape and adding a calf strap to hold it on the leg. The orthosis is worn inside footwear, which secures it distally.

### Thermoplastic AFOs

In the last 10-15 years thermoplastics have become available and suitable for use in many developing countries. These materials have advantages and disadvantages. They can be moulded easily and if appropriate thermoplastics are chosen, and appropriate designs used, they can be sufficiently strong for orthopaedic applications.<sup>7,15,21,24</sup>

Thermoplastics can be inexpensive and readily available if they are widely used for other purposes. In the west, they are available in sheets. ALIMCO, a major supplier in India, also markets them in this form.<sup>a1</sup> In some countries where HDPE (high density polyethylene) or PVC (polyvinyl chloride) drainpipes are common, these pipes can be used in the manufacture of orthopaedic appliances.<sup>7,13,23</sup>

In order to become sufficiently malleable to be moulded over a plaster of Paris cast, thermoplastics need to be heated. Ideally this is done in an oven, although minor alterations can be carried out with the use of a heat gun. Temperatures required and times of heating vary between 180° and 300° Celsius depending on the plastic used. As in the manufacture of resin AFOs, a more accurate shape is usually obtained if a vacuum is used. Working with thermoplastics requires certain technical skills, which are less common in developing countries than the skills needed to manipulate

a. ALIMCO. GT road. Kanpur 208016, India.



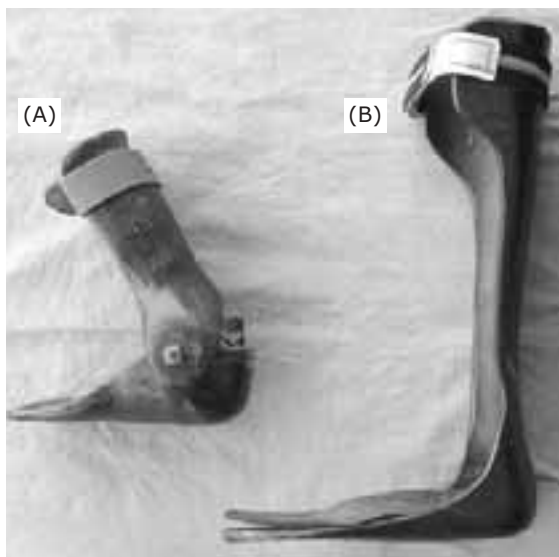
leather, wood or metal. Wenner explains the basics of using thermoplastics.<sup>28, 29</sup> In Nepal and India, a system has been developed to mass-produce AFOs in a number of different sizes.<sup>23</sup> This has the advantage of significant cost savings due to the reduction in materials and time needed to make custom casts.

When thermoplastics are used in large appliances like Knee-Ankle-Foot Orthoses (KAFOs) a combination with a metal (e.g. aluminium) is necessary. This is used to make side steels and knee joints to allow for flexion as appropriate. However, a 100% thermoplastic orthosis has been produced for children.<sup>25</sup>

The main disadvantages of thermoplastic or resin AFOs are their inability to cater for volume fluctuation and also the fact that the materials cannot “breathe”. In hot climates in particular, this can be a problem and may result in skin irritation. Drilling holes or cutting out parts which do not affect the strength and integrity of the orthosis can provide a solution to this problem. Regular washing of the limb and the use of stockings can also be of benefit.

#### *Making a Thermoplastic AFO*

The thermoplastic AFO is made on a modified plaster model of the lower leg in a similar way to the resin orthosis (Fig. 23-4). If required for insensitive feet, a micro-cellular rubber (MCR) foot-bed can first be applied to the plantar surface of the cast, and the AFO made over this. The cast is held firmly, with its posterior side uppermost, by means of an imbedded pipe or pole. The hot thermoplastic is draped over it and pinched together at the anterior side. This forms a seal and as the plastic starts to cool, it shrinks towards the cast. Accurate shaping of the orthosis is aided by use of vacuum, but it is possible to obtain an adequate contour by wrapping the hot AFO with elastic bandages. As with the resin AFO, when the orthosis is completely cooled, it is cut from the cast, the final shaping carried out and a calf strap applied.



**FIGURE 23-4** Two AFOs both made of High Density Polyethylene (Drain pipe). Brace (A) has an ankle joint which allows dorsiflexion.

#### **Alternative Designs of Cosmetic AFO**

The main function of an AFO for a client with a foot-drop is preventing plantarflexion during swing phase. Unfortunately the orthosis often also reduces the ability to dorsiflex the foot. This can be a problem especially in cultures where squatting is common for many activities. Solid ankle AFOs are the easiest to make, but they allow no movement of either the ankle or sub-talar joints. There are two designs however, which prevent plantarflexion and allow an appropriate amount of dorsiflexion. These are the Dorsiflexion Assist AFO and the Plantarflexion Stop AFO.

Thermoplastics can be used to make AFOs with different functions. Some differences can be achieved simply by changing the line to which the device is trimmed (the trimline).

Solid Ankle AFOs have a trimline anterior to the malleoli. By cutting the AFO back to behind the ankle, a more flexible orthosis is obtained, which can be used to support a flaccid foot-drop. This is known as a Dorsiflexion Assist or Posterior Leaf Spring AFO.

As the Achilles tendon area of this design of orthosis undergoes considerable cyclic stress, only some thermoplastics are durable enough to be used in this way. Another way of achieving passive dorsiflexion (used during the stance phase of gait or for squatting) is to cut several horizontal slots in the Achilles tendon area, which open during dorsiflexion, but close to prevent plantarflexion. Again, this is not easy to do, and poor manufacture or the use of inappropriate material or thickness will result in fracture of the device.

Passive dorsiflexion can also be achieved using a plantarflexion Stop AFO (Fig. 23-4a). This is more difficult to manufacture. The AFO comprises two sections with a joint at the ankle. This can be made from metal (some are available commercially) and moulded into the AFO. Alternatively it can be made using an overlap of the foot and calf sections, with a pivot connection. There is also a thicker plastic section behind the ankle on both sections, which come together to prevent plantarflexion. The use of joints requires attention to detail when modifying the cast to ensure that the medial and lateral joints lie parallel to each other and do not bind when the ankle is moved.

Finally, a few things to remember when supplying AFOs:

- They should have smooth contours and trimlines to ensure no damage to the insensate leg, and also to reduce the likelihood of stress fractures of the device.
- The AFO should be a close fit, but not apply pressure to the vulnerable bony prominences. When the AFO is removed any red marks on the skin should fade within 30 minutes or there will be danger of skin breakdown. Plastics do not “wear in” in the way that leather does, so persistent red marks should be taken seriously and the AFO modified before it

is re-applied. This is easily achieved by using a hot air gun to heat the material locally, then reshaping it.

- If a shoe with a moderate heel height is to be used, the AFO should allow for this, and variations in heel height should be avoided.

## LOSS OF JOINT STABILITY

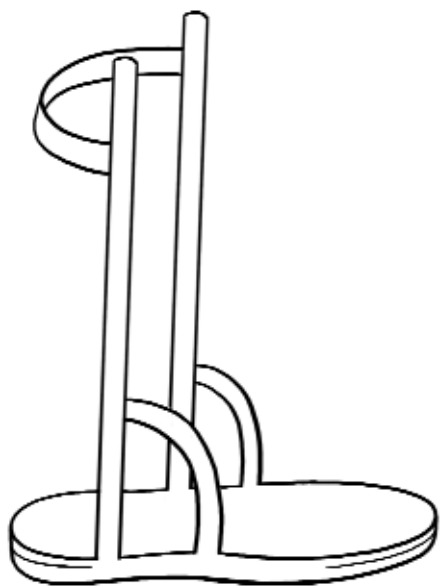
A further secondary effect of neuropathy can be loss of joint stability. This can be as a result of muscle imbalance, as referred to above, or neuropathy in the joint itself, leading to small fractures, which in turn can lead to breakdown of the joint. In the foot, this can result in the “rocker-bottom” foot, where the midfoot collapses to the point where it takes the bulk of the forces exerted during walking. Where joint stability is lost, it is possible to support the affected area by an orthosis in some cases. The purpose of this is to reduce the likelihood of worsening of the condition and in most cases, to facilitate mobility. This section outlines three such orthoses.

### Backslab

This is essentially an over-sized temporary AFO, which maintains the ankle in a neutral position during a period of healing of an ulcer. It is used in conjunction with appropriate dressings and bed rest, so in this case mobility during its use is not an aim. The dressings are applied to the limb, and the backslab fitted over the top. It is then held in place by bandages or straps. The fitting requirements for this orthosis are not so strict as described above as it is not intended to be used for walking. The orthosis does not need to be custom made, and can be re-used as long as it is decontaminated to prevent cross-infection. It is often made from thermoplastics or resin as described above, however wood has also been used for this purpose.<sup>29</sup>

### Fixed Ankle Brace (FAB)

A Fixed Ankle Brace is another name for a solid ankle AFO (Fig. 23-5). It is used for patients with instability of the foot and ankle or to provide immobilisation of the advanced neuropathic foot.<sup>2,9</sup> It is traditionally made from metal and leather set into a boot with a moulded insole, but can also be manufactured using resin or thermoplastics, as detailed above. As complete immobilisation of the foot and ankle is desired, it is important to incorporate into the AFO a "total contact" insole with pressure relief for the vulnerable regions. Walking with a completely rigid foot is very difficult, so progression is aided with a rocker built into the forefoot of the device.



**FIGURE 23-5** Fixed Ankle brace (FAB) (from Fritschl<sup>9</sup>).

### Patella Tendon Bearing AFO

When foot damage secondary to neuropathy is extensive, it can reach a stage where the plantar surface of the foot is of insufficient area to support the loads applied to it during gait. In this situation the only alternative is to bear weight more proximally. A patella tendon bearing (PTB) AFO offers this alternative. In leprosy

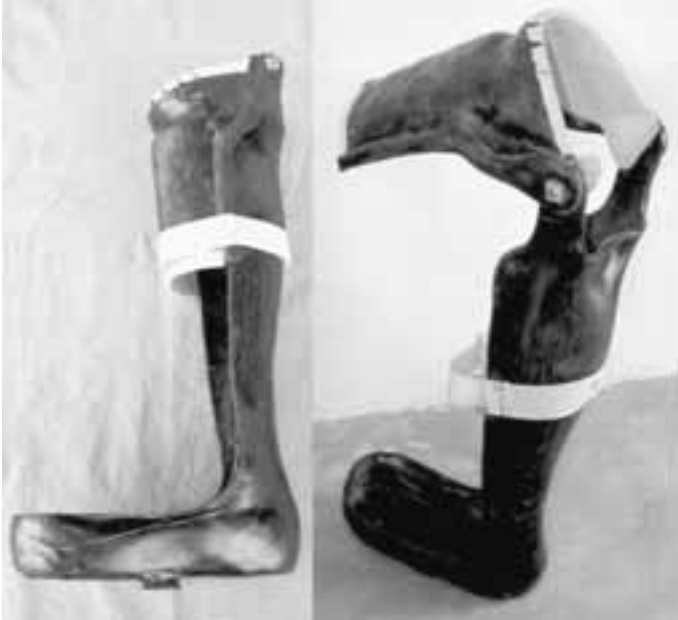and diabetic patients this type of orthosis can be used for ulcer healing.<sup>20</sup>

The principle is the same as the PTB socket in the below knee prosthesis (see below). The body weight is transferred to the calf section of the orthosis via the patella tendon and other pressure tolerant areas of the lower leg, while the foot and ankle are maintained in as neutral a position as possible. As with the AFOs referred to above, the PTB AFO can be made in the conventional style, using metal and leather, or from resins or thermoplastics. The calf section is the most important part of the orthosis, as it must fit well in order to transfer the weight from the limb to the orthosis to relieve the plantar surface of the foot.

There are two main designs of PTB AFO. The first uses an intact proximal section, similar in shape to the PTB socket of a prosthesis, but excluding the distal end. This is held at the required distance above the foot section, so that on standing, the weight is borne through the proximal section. To don the orthosis, the foot must be passed through the proximal section. As the foot is generally not very mobile when such an orthosis is indicated, and is often larger than the proximal section, this design can be very difficult, or even impossible to don and doff.

For this reason, the second design is more common. The calf section is made using posterior and anterior shells, which are separated to don the orthosis, and fastened once the leg is in the desired position.

A design combining these has been developed at Green Pastures Hospital in Pokhara, Nepal. This uses the two-part system, however the anterior and posterior shells are permanently connected medially and laterally by means of a pivot. This allows the proximal opening to be enlarged sufficiently to pass through the foot. It is then closed firmly when the foot is in place, applying the desired forces just distal to the knee (Fig. 23-6).



**FIGURE 23-6** Patella Tendon-Bearing brace. The design from Green Pastures Hospital and Rehabilitation Centre in Pokhara (Nepal), shown in its closed and open position.

## LOSS OF LIMB

As previously stated, a prosthesis is a device which replaces a missing part of the body. Many amputees manage without prosthetic intervention either through choice or lack of availability of appropriate services. Where improvement of function, mobility and cosmesis can be gained, however, the use of a prosthesis can be beneficial. Although amputations at different sites are common in leprosy, prostheses are frequently only made for the lower limbs.

There are different levels of amputation associated with leprosy, ranging from partial foot through Symes (ankle disarticulation) to trans-tibial. Partial foot amputations (which can be at different levels) have the advantage of being end-bearing. They are normally accommodated by means of a total contact insole together with boots incorporating a rocker sole.<sup>1</sup> A toe-filler, which does not contact the foot at the distal end, is used to maintain the

shape of the footwear. An AFO can also be used for partial foot amputees. This can have the advantage of storing energy during early stance and returning it in late stance.

Symes amputation residual limbs can also have the advantage of being end-bearing, and this level of amputation is only advisable when the distal tissue is strong enough to allow this.<sup>9</sup> The other main advantage of a Symes amputation over higher levels of amputation is the fact that less energy is required to mobilise with a longer residual limb.<sup>20</sup> Although Weaver states that Symes amputations are normally preferable to trans-tibial, this is not always possible in leprosy due to previous ulceration of the weight bearing area.<sup>27</sup> Symes residual limbs are however, much harder to fit with a cosmetically pleasing prosthesis due to the bulk at the distal end.

Amputation of part of the lower limb in this disease often follows considerable time of repeated ulceration of the affected part. In an attempt to save as much of the limb as possible, there may be repeated amputations at different more distal levels before a trans-tibial operation is carried out. It is not usually necessary to amputate above this level in leprosy. This is a common level of amputation, and amputees gain considerable benefit from the use of a prosthesis as distal end bearing is not possible. The bulk of this section will major on this type of prosthesis.

### ***Patella Tendon Bearing (PTB) Prostheses***

Three parts of the trans-tibial prosthesis can be distinguished: the socket, shin and foot/ankle.

- The socket is the interface between the residual limb and the prosthesis. During stance it transmits the forces generated

by gait to the stump, so the shape is very important if skin breakdown is to be avoided. During the swing phase of gait it prevents rotation of the prosthesis on the residual limb and maintains suspension of the prosthesis, either alone or in conjunction with straps or a sleeve.

- The foot is the contact with the walking surface, and provides a smooth roll over from heel strike to toe-off. This is sometimes enhanced by use of an ankle, which provides relative movement between the foot and shin.
- The shin section is the connection between the foot and the socket.

There are two categories of prosthesis: endoskeletal and exoskeletal. In the endoskeletal design the shin section is a tube which is usually attached by means of a series of bolts allowing for angular adjustment. An anatomically shaped foam and cosmetic sheath normally cover this. The exoskeletal prosthesis has an exterior strong shin section, which is shaped to be cosmetically acceptable. This design is harder to align accurately, but is more robust and can tolerate being immersed in water.

Shin pieces and feet are available in prefabricated form in some developing countries.<sup>17</sup> In India, ALIMCO markets a range of components in different sizes, and in Vietnam the INGO Prosthetic Outreach Foundation (POF) supplies the "monolimb" system which is based on a computer design of the socket.<sup>11</sup> This is a PTB socket with shin section attached. The foot is a separate component. The Jaipur foot, developed by Dr. P K. Sethi, is used both in India and further afield.<sup>18,22,28</sup> The foot can be used without shoes and allows the user to squat, which is important in some cultures. The ICRC (International Committee of the Red Cross) has developed a complete prosthetic system, together with a manual explaining its use, which is available in some areas.<sup>8</sup> Some

companies in the 'West' are also producing systems with developing countries in mind.

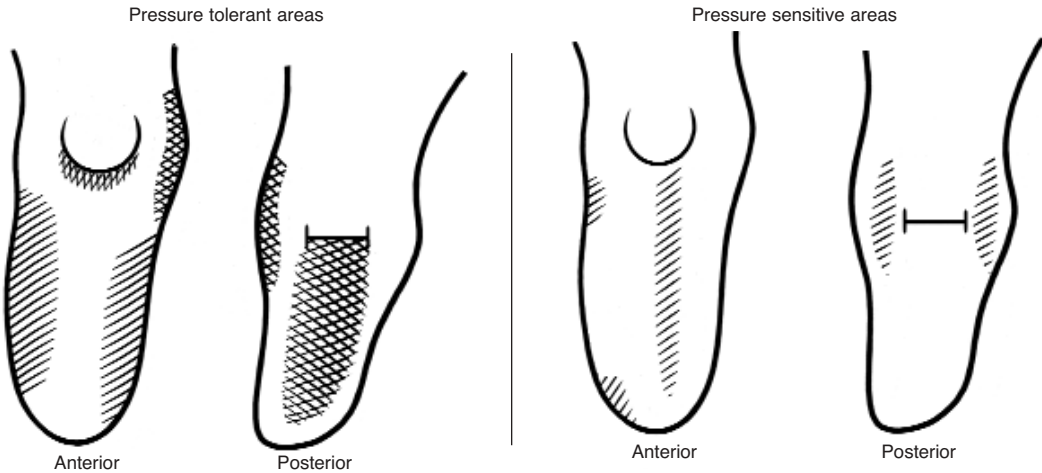
Although the use of prefabricated components in the manufacture of prostheses makes the process quicker, it is possible to produce them from raw materials. In various places there are descriptions of prostheses from aluminium, bamboo and plastics available.<sup>7,8,11,12,13,16, 28, 29</sup>

### Socket Design

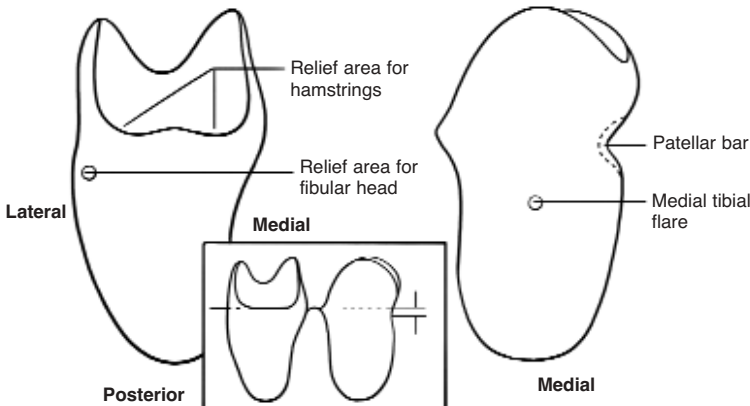
The PTB socket is commonly used for trans-tibial amputees. The principle of the design is to transfer forces incurred during gait to pressure tolerant areas of the residual limb, whilst protecting those areas which are pressure sensitive. It is therefore essential to have a good understanding of the anatomy of the lower limb to make an effective socket. The socket is custom-made for each amputee to ensure a good fit. To ensure that the correct information is collected for the production process the use of a common measurement form is recommended (Appendix I). The residual limb is loaded on the patella tendon, and this is counterbalanced by pressure in the popliteal area. Additional load is taken on the tibial flares. Soft tissues are also compressed to provide containment, load bearing and aid venous return. Pressure is avoided on the bony prominences of the fibular head, the tibial tubercle and the cut ends of both bones. The anterior distal end of the tibia is also protected, as are the hamstring tendons (Fig. 23-7).

The basic PTB socket covers the residual limb below the knee and extends proximally to the mid-patella anteriorly, to the level of the tibial plateau posteriorly and proximally to this on the medial and lateral sides (Fig. 23-8). Where supracondylar suspension is required from the socket, these sides extend further, and the socket is cupped in above the femoral condyles. The socket is manufactured in a similar way to the AFOs described above. Initially





**FIGURE 23-7** Pressure sensitive and tolerant areas on the stump (From Deckers<sup>6</sup> with permission).



**FIGURE 23-8** The trimlines for a PTB socket (from International Committee Red Cross manual, with permission<sup>8</sup>).

a cast is taken of the residual limb, together with measurements. The positive cast is carefully modified to ensure that the forces of gait are transmitted to the pressure tolerant areas. This model is then used to manufacture the socket.

Some prostheses are made with a hard socket against the limb, however in leprosy an intermediate soft socket is strongly recommended to provide extra protection. The soft interface can be made with resilient foam such as Pelite or Evazote. These can be shaped to the cast using heat. Microcellular rubber can also

be used, however this needs to be shaped by cutting and sticking it onto a thin leather liner. The hard socket is then built on top of the soft liner. This can be made from reinforced resin or thermoplastics as described in the AFO section.

### Suspension

Choice of suspension for a prosthesis depends on a number of factors, including the shape and length of the residual limb, the dexterity of the amputee's hands and even the climate. The supracondylar socket incorporates suspension in its design. If this is not used, the basic PTB socket is held onto the leg with a strap or elastic sleeve. The strap is tightened above the patella, and has two arms, which attach medially and laterally to the socket. Positioning of the attachments is important to allow for firm location of the socket on the limb as well as the ability to flex the knee in sitting. Sleeve suspension fits over the proximal part of the prosthesis and 10-15 cm above the knee. This type of suspension can be very hot to wear, so may be less suitable for tropical climates.

### Feet

Prefabricated feet are available in some areas, however it is also possible to manufacture them from wood and rubber (Fig. 23-9). The simplest design is the Solid Ankle Cushion Heel (SACH) foot. This incorporates a rubber heel wedge into the wooden foot. As the name suggests, there is no ankle movement, but the heel wedge compresses during early stance to simulate plantarflexion. Variation in the hardness of the rubber heel (which can be achieved by alternating rubbers of different densities) can be useful to control the rate of progression from heel-strike to foot-flat during the early part of the stance phase of gait. Pluyter describes the manufacturing process for different types of feet in more detail.<sup>16</sup>



**FIGURE 23-9** A wooden foot which can be made locally in the workshop.

In some cases it might be appropriate to consider using a rubber bumper at the end of the shin pylon instead of a foot. Although this is cosmetically inferior, ease of walking over uneven terrain may be increased and pressures on the residual limb may be reduced. The foot is often the component which requires the most maintenance, so where this is a problem, dispensing with the foot is a possibility. The idea of having no foot is, however, an anathema to

many people. The use of a small rocker can be a compromise (Fig. 23-10).<sup>16</sup>



**FIGURE 23-10** A man using a small prosthetic foot rocker, useful in uneven terrain.

### Symes Prostheses

Symes amputations have the advantage that the residual limb is long and can be end-bearing, so ambulation without the aid of a prosthesis or other walking aid is possible. This level of amputation does, however present some problems:

- Symes residual limbs are often bulbous at the distal end, as the malleoli are wider than the shafts of the tibia and fibula. The shape of the residual limb is difficult to fit with a cosmetically pleasing prosthesis, as the ankle will almost always appear disproportionately large.
- The length of the limb is advantageous in terms of the energy needed to walk, however there is limited space for a prosthetic foot.

Ideally, weight can be borne through the end of the limb, although sometimes the fat

pad moves away from the distal part of the tibia, making it unstable. The socket is made to accommodate end-bearing or take some of the forces more proximally, depending on the characteristics of the residual limb.

Older designs of prosthesis for Symes amputees were essentially boots made from leather, with a moulded insole and lace fastening. Toe fillers could be added to the sole and the whole thing inserted into an outer boot to give a more cosmetic finish. Nowadays it is more common to use a hard socket with a cosmetic foot. The socket must be sufficiently close-fitting to prevent rotation of the residual limb within the prosthesis.

Due to the shape of the residual limb, special consideration needs to be made in manufacture to allow the bulbous end to pass through the narrower section of the prosthesis. If a liner is used (and this is recommended in leprosy) a split down its length will make this possible. The outside of the liner is then built up to allow it to pass into the prosthesis if an intact shell is used as a socket. There are also

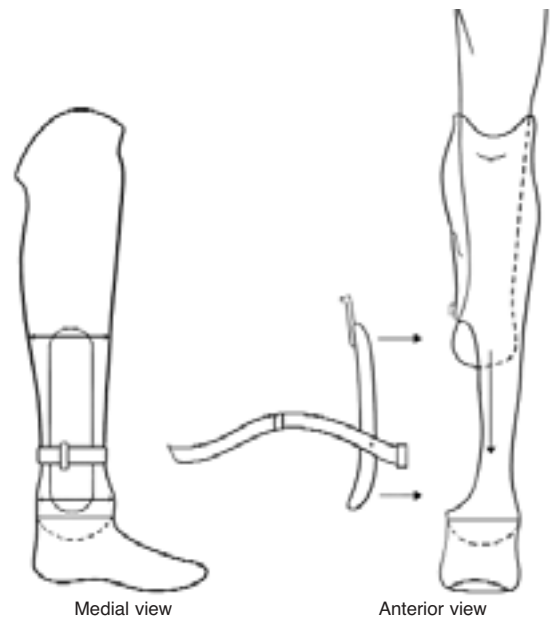
other designs of sockets. Some designs are more open, whilst others, like the 'Obturator Design', have a window and shutter/panel (Fig. 23-11).

The foot for a Symes prosthesis is attached directly to the socket. If there is sufficient space, a low wooden SACH design can be used. Otherwise a robust rubber sole can be attached to the socket and a toe filler used anteriorly. It is important that the foot does not impede progression from heel strike to toe-off. A softer rubber heel can provide some shock absorption.

### **Pointers in Fitting and Alignment**

It is important when supplying a prosthesis that it is a good fit and well aligned.

- If a socket is a poor fit there is a danger that damage will be caused to the residual limb or the prosthesis may not be firmly attached to the body. It is common for a residual limb to change in shape and volume over the first months or



**FIGURE 23-11** Two Symes prosthesis designs, one with an open socket and the other using the window and panel principle.<sup>81</sup>

even years after amputation. Normally the prosthesis is worn with one or more socks between the residual limb and the soft socket. The initial swelling may reduce and the socket become loose. For small changes, the addition of a sock may be sufficient to make up for the reduction in volume. A thin leather lining added to the soft socket will also make the socket more snug. Eventually, however it is recommended that a new socket be made for the prosthesis. Several socks or liners will only compensate for overall volume reduction, whereas the reduction tends to take place more in the pressure tolerant areas, so the overall shape required is different.

- Approximate trimlines are determined at the casting stage of the prosthesis, as the need for a particular type of suspension or additional medio-lateral stability is taken into account. However, the trimlines of the socket are finalised when the amputee is wearing the prosthesis. It is important to ensure that the socket is comfortable in sitting as well as during gait.
- The position of the socket with respect to the foot is also very important in maximising function. This is known as the “alignment” of the prosthesis. This alignment takes place in all three planes. In the sagittal plane, flexion/extension of the socket and dorsiflexion/ plantarflexion of the foot is considered, together with the anterior/posterior shift of the socket over the foot. In the coronal plane, abduction/adduction of the socket and inversion/eversion of the foot, together with mediolateral shift of the socket over the foot. In the transverse plane, the rotation or toe-out of the foot with respect to the socket is determined. The length of the prosthesis is, of course, also impor-

tant. There are standard bench settings for the relative positions of the socket and foot, but the optimum setting is best achieved on an individual basis with the patient giving feedback. It may also need alterations once the patient has gained confidence and has established a walking pattern. Alignment can also be a compromise between the perfect gait sought by the prosthetist and the comfort and security desired by the patient.

- When the prosthesis is being fitted, it is important to ensure that no undue pressures are placed on the residual limb. After a period of walking the prosthesis is removed and the limb examined. Impressions from the socks will remain on the skin, and show whether pressure is being borne on the sensitive or tolerant areas. If adjustments are not made at this stage, it is possible that there will be damage to the limb in the longer term. Alterations can be made to the soft socket by adding additional pads on the outside to increase pressure locally, or thinning the socket to decrease it. The hard socket is adjusted by heating it in the desired area and re-contouring it when soft.

## CONCLUSION

The purpose of this chapter is to outline some of the issues related to prosthetics and orthotics as related to leprosy. Manufacturing and supplying quality custom-made orthopaedic appliances is a continuous challenge. It is not something to undertaken lightly or by untrained personnel. Good results can only be achieved by a combination of knowledge, understanding, skills and co-operation. Co-operation with other (para)-medical disciplines is desirable, but if a truly beneficial outcome is to be achieved, then co-operation with the client is essential.

**REFERENCES:**

1. Brand P: Insensitive feet. A practical handbook on foot problems in leprosy. The Leprosy Mission London 1981
2. Bryceson A, Pfaltzgraff RE: Leprosy. Medicine in the Tropics. Edinburgh, Churchill Livingstone, 1990
3. Cross H, Sane S, Dey A, Kulkarni VN: The efficacy of podiatric orthoses as an adjunct to the treatment of plantar ulceration in leprosy. *Lepr Rev* 66:144-157, 1995
4. Dartnell C: Simple Orthopaedic Aids, Appropriate designs for developing country. Leonard Cheshire Foundation International, London, 1974.
5. Deckers J, Beckers D: Ganganalyse & Looptraining voor de Paramedicus. Bohn, Stafleu, Van Loghum, Houten 1996
6. Deckers J: Prothesetraining voor onderste extremiteit. Hoensbroek, 1999
7. ESCAP. Economic and Social Commission for Asia and the Western Pacific: Production and distribution of assistive devices for people with disabilities. United Nations Publications, New York, 1997
8. Foreget J: Technical Manual for Lower Limb Prosthetics. ICRC, Geneva, 2001
9. Fritschi EP: Surgical Reconstruction and Rehabilitation in Leprosy. The Leprosy Mission, Delhi, 1984
10. Huckstep RL: Poliomyelitis: A guide for Developing Countries - including Appliances and Rehabilitation for the Disabled. Churchill Livingstone, London, 1975
11. Mathews DE, Pye R.J, Burgess E.M: An Appropriate Trans-tibial Prosthesis for Developing Countries. Prosthetic Outreach Foundation, Seattle, [www.pofsea.org](http://www.pofsea.org)
12. Meanley S: Descriptions of Appropriate Orthopaedic Appliances. Pokhara, 1997
13. Meanley S, Reed N: An "appropriate technology" transfemoral prosthesis, using materials available in Nepal. *Prosth Orthot Int* 22, 123-128, 1998
14. Neville J: A footwear manual for the leprosy control programmes. Part 1 & 2. ALERT, Addis Ababa, 1990
15. Öberg K: Cost-benefits in orthopaedic technology by using thermoplastics in developing countries. *Prosth Orthot Int* 15:18-22, 1991
16. Pluyter B: Alternative Limb Making: The manufacture and fitting of low-cost below knee prostheses. AHRTAG, London, 1989
17. Pradip D, Poonekar MD, Pradhat KG: A look at the health care and Prothetic/Orthotic services in India. *Prosth Orthot World* 2:24-34, 1999
18. Pradip D, Poonekar MD: Prosthetic feet: Indian Scenario. *Prosth Orthot World* 4, 48-52, 2001
19. Pupulin E: A personal view of prosthetics and orthotics. *Prosth Orth Int*, 25: 93-95, 2001
20. Randall LB: Physical Medicine & Rehabilitation. WB Saunders, Philadelphia, 1996
21. Schuch CM: Thermoplastic applications in lower extremity prosthetics. *J Prosth Orthot* 3: 1-8, 1990
22. Sethi PK: Technological choices in prosthetics and orthotics for developing countries. *Prosth Orthot Int* 13: 117-124, 1989
23. Theuvenet WJ, Ruchal SP, Soares D, Roche P: Advantages, indications and the manufacturing of melted PVC waterpipe splints. *Lepr Rev* 65:385-395, 1994
24. Verhoeff TT, Poetsma PA, Gasser L, Tung H: Evaluation of use and durability of polypropylene trans-tibial prostheses. *Prosth Orthot Int* 23:249-255, 1999
25. Vesan JC: Orthese 100% polypropylene. Handicap International, Paris, 2000
26. Warren G: A foot drop spring. *Lepr Rev* 41:100-102, 1970
27. Weaver FA, Modrall JG, Beak S et al; Symes amputation: results in patients with severe fore-foot ischemia. *Cardiovasc Surg* 4:81-86, 1996
28. Wenner D: Disabled Village Children: A guide for community health workers, rehabilitation workers and families. The Hesperian Foundation, Berkeley, 1999
29. Wenner D: Nothing about us without us: Developing innovative technologies for, by and with disabled persons. HealthWrights, Palo Alto, 1998
30. Yawalkhar SJ: Leprosy for medical practitioners and paramedical workers. Ciba Geigy, Basle 1994

**Further recommended reading:**

1. Jensen JS, Hiem S: Preliminary experiences with modified Sach feet manufactured and used in tropical developing world setting. *Prosth Orthot Int* 23:245-248, 1999



## 342 Surgical Reconstruction & Rehabilitation in Leprosy

2. Jensen JS, Hiem S: Evaluation of polypropylene prostheses ICRC TT-amputees. *Prosth Orthot Int* 24:47-54, 2000
3. Jensen J.S. Clinical field-testing of ATLAS prosthetic system for trans-tibial amputees. *Prosth Orthot Int* 26:86-92, 2002
4. Verhoeff TT, Poetsma PA, Gasser L, Thung H: Evaluation of use and durability of polypropylene TT prostheses. *Prosth Orthot Int* 23: 249-255, 1999
5. Platt A, Corter N: Making health-care equipment. Ideas for local design and production. Intermediate Technology Publications, London, 1990

# Rehabilitation

• F. HERM

## INTRODUCTION

Physical rehabilitation can be defined as the process assisting persons who are limited or restricted in their individual range of activities to achieve an optimal level of functional ability. The rehabilitation process includes the socio-economic and mental aspects of the person's limitations and restrictions. However, for the special purpose of this book and its focus on the rehabilitation of individuals with neuropathic limbs, the present chapter will concentrate on the physical and functional aspects of rehabilitation.

Neuropathic limbs present a complex situation of impairment and resulting disabilities, which cause limitations and restrictions.<sup>3,34</sup> In most of the cases, this will result in a lifelong process of rehabilitative interventions, including ongoing activities for the prevention of further impairment and disability.<sup>26,27</sup> However, an awareness of the person's self-understanding is critical to the rehabilitation success. Therefore, one should not forget that the person has the right of choice and is an essential contributor to the rehabilitation process.<sup>20,35</sup>

In contrast to the classic therapeutic model, emphasizing diagnosis and treatment, physical rehabilitation comprises of multiple simultaneous interventions addressing both the cause and the secondary effects of the disease. Comprehensive rehabilitation therefore requires certain components such as defining specific potentials, plans, and goals and involves an interdisciplinary process, as shown in Table 1.<sup>15,20,31</sup>

**Table 1: Components of physical rehabilitation.**

- A unique plan, formulated by an interdisciplinary team, with the participation of the individual.
- Goals derived and prioritized through an interdisciplinary process.
- Full participation of the individual person.
- Improvement of the individual's functional potential.
- Reduction of the individual's impairments and activity limitations.

Based on these components, the various aspects of rehabilitation of neuropathic limbs will be described with experience and evidence based recommendations.

## Definitions

The terminology in the field of rehabilitation has been confusing for a long time. Recently, the new WHO Classification of Functioning, Disability and Health (ICF) has been published and helps to clarify the various terms used in the rehabilitation process. As a member of the WHO classifications, ICF describes health and health-related domains as body functions and structures, activities and participation.<sup>17,18,24</sup> These definitions are listed in Table 2 and will be referred to in this chapter.

**Table 2: WHO definitions**

In the context of health:

- Body structures are anatomical parts of the body such as organs, limbs and their components.
- Body functions are the physiological functions of body systems (including psychological functions).
- Impairments are problems in function or structure such as significant deviation or loss.
- Activity is the execution of a task or action by an individual.
- Activity limitations are difficulties an individual may have in executing activities.
- Participation restrictions are problems an individual may experience in involvement in life situations.
- Environmental factors make up the physical, social and attitudinal environment in which people live.
- Disability is the 'umbrella' term for impairments, activity limitations and participation restrictions.

### Phases of rehabilitation

Comprehensive rehabilitation requires knowledge of the individual's personal life situation, roles, and aims. Therefore, the first phase of rehabilitation focuses on the individual examination, assessment, and additional measurements, if required. The impairments and activity limitations as well as their restricting effects on the person are assessed and quantified. The person's unique characteristics that allow for adaptive capacity or compensation are identified and targeted for specific therapeutic interventions.<sup>20,31</sup>

The second phase of rehabilitation emphasizes treatment to arrest the process causing further impairment and preventing secondary impairments. This is the phase of medical and

surgical interventions such as the long-term use of anti-inflammatory drugs to reduce the impact of the inflammation and destruction, or corrective surgery such as tendon transfers to enable the affected limbs to perform movements that were lost due to the disease.<sup>26,27</sup>

The third phase focuses on the enhancement of physical performance, which is usually at the time of post-operative treatment and exercises. Physiotherapy can prevent further shortening of tendons, ligaments and atrophy of muscles and improve function through strengthening exercises and re-education and facilitation of functional movements.<sup>3,34</sup>

In the following phase of rehabilitation there is a focus on total personal adaptive techniques to minimize the final limitations. This can be the identification of "trick movements" to improve the performance of tasks or the strengthening of pinch and grip function to train "survival skills" or systematic exercises to improve certain activities of daily living. During this time prevocational assessments can take place.<sup>6</sup>

The last phase of rehabilitation directs efforts toward environmental enhancement to reduce limitations and restrictions.<sup>20,29</sup> Provision of adaptive tools, prosthesis and orthoses as well as modification of the individual's environment belong to this phase. A wheelchair can be an option as well as simple grip devices or braces. If appropriate, the whole environment can be adapted according to the individual needs. Examples are the building of a ramp instead of steps or the provision of an elevator and the modification of doorways, toilets and bathrooms, which allow a better performance for those otherwise restricted in their participation in daily life.<sup>12,28,35</sup>

The various phases and interactions of rehabilitation processes as well as their implications for the individual can be illustrated by case studies, such as the one presented below.

## CASE STUDY

A 35 year old, female multi-bacillary (MB) leprosy case is referred after 6 month of multiple drug therapy (MDT) for treatment of reversal leprosy reaction (type 1) and nerve function impairment (NFI). Physical examination, skin smear and voluntary muscle test (VMT) as well as sensory testing (ST) are done. Because of new nerve function impairment a steroid course is started. Taking into account the loss of protective sensation a self-care training and protective footwear are prescribed at this stage.

The same patient is referred again after one year for reconstructive surgery of a bilateral lagophthalmos and a mobile clawing of the right hand as there was only partial response to the steroid treatment. Furthermore, there are now socio-economic problems because of activity limitations and the social stigma. A team meeting is conducted, goals are set, and interventions planned. Accordingly, pre-operative exercises for the right hand are started and a socio-economic assessment is done. Secondly, after 5 days, an intrinsic replacement for the right hand is performed and during the immobilization period a temporalis muscle transfer for both eyes is completed. After post-operative physio-therapy, occupational therapy is started including a pre-vocational assessment and counseling. With progressing function of both, the right hand's grip and pinch movement and bilateral eye closure, the patient is discharged after a hospitalization period of 6 weeks only.

The patient comes back for follow up after 3 month and shows good functional outcomes with no lid-gap any more and good grip and pinch function of the right hand. After a recent home assessment, the social worker has initiated tailoring classes and linked the client to a self-help group in her area. Asked about her opinion, the client is satisfied with the interventions so far and optimistic regarding the outcome of the rehabilitation process.

## The rehabilitation team

It remains a challenge for health professionals to work in a team approach for the benefit of patients. However, rehabilitation comprises many different aspects including type and process of disease, primary and secondary impairments, various functional levels and special individual needs. These, in most of the cases, cannot be managed by one specialty alone or handled by individual professionals separately. Especially working with people affected by neuropathic limbs, a team approach is crucial to successful rehabilitation of the individual (Fig. 24-1).<sup>3,4,15,34</sup>



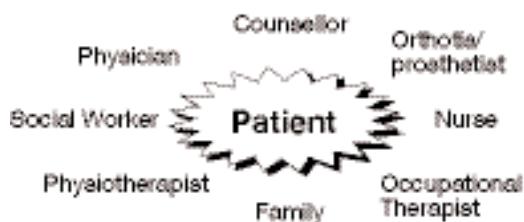**Figure 24-1** The rehabilitation team.

A health care team can be defined as a group of health professionals, each possessing particular expertise, who have a common purpose and goal (Fig. 24.2).<sup>23,31</sup> The common purpose and goal of the rehabilitation team is the comprehensive medical and social rehabilitation of persons affected by disability. There is an organized division of work within the group. While all members share responsibility for the patient's well being, each individual is also responsible for making and implementing decisions in their own specific area within the framework of the whole plan. The members meet together to communicate, collaborate, and consolidate knowledge. From these meetings plans are made, actions determined, future decisions influenced, and results evalu-

ated. The ideal health care team is the interdisciplinary one wherein members of different disciplines are involved in formal and informal arrangements that produce integrated performance and service delivery.<sup>23,31</sup>

Translated into the rehabilitation setting, the ideal rehabilitation team is the interdisciplinary team of professionals working in the various areas of the rehabilitation field being formally and informally connected through arrangements that maximize performance and outcome of the rehabilitation process.

**Figure 24-2** Potential members of the rehabilitation team.



The formal structure of rehabilitation team meetings comprises three main parts and issues. First, defining the individual's rehabilitation potential. This potential is based on the functional ability of the individual but includes the aspects of possible improvement through various interventions. It is more or less the realistic question of what could be achieved through medical treatment, surgery, physiotherapy, occupational therapy, orthopaedic devices, counselling and socio-economic support for the affected individual. The second part is the setting of the individual's rehabilitation goal. Goal means the functional outcome or level of participation one aims for. It is important though, to discuss the individual potential and goal with the individual patient to elicit their opinion on the process and especially on the goal and outcome. Having determined the potential and goal, it is then essential to create an individual and specific

rehabilitation plan.<sup>15,20,31</sup> Practically speaking, taking into account rehabilitation potential, rehabilitation goal and the patient's perspective, which interventions will be done, at what point of time and by whom?

### Functional potential

Functional outcome measurements provide a baseline against which changes in function can be measured and monitored over time. These data are useful in determining the effectiveness of a particular intervention, such as surgery, physiotherapy or mobility devices.<sup>10,12,20</sup>

In the context of rehabilitation, functional assessment has typically been applied to measuring what an individual is able to do for himself or herself, most commonly in self-care (activities of daily living, ADL) and mobility. Other areas of function frequently assessed include homemaking skills (cooking, cleaning, and laundry) and related instrumental skills, also referred to as community survival skills (telephone, managing finances, shopping). An activity scale used in our setting (GPAS) is based on 40 standardized questions, which measure the functional ability in our context. Most other functional assessment scales include an indicator of level of function, or degree of assistance needed to complete a particular task. The need for physical assistance ranges from indicators such as "care-taker" and "minimal assist" to "moderate assist" and "maximal assist" (Table 3).<sup>12,32</sup>

However, measuring rehabilitation potential means more. Apart from assessing impairment and limitations, it also includes the future: "What can be achieved with the assessed functional ability taking into account additional conservative and operative interventions?" It needs the special gift or ability of starting a process, and at the same time, having the result already in mind, in order to coordinate the process efficiently. It also requires an



updated knowledge on possible rehabilitative interventions and a combined assessment of various professionals. The aim is nothing less than the optimal level of functional outcome according to the existing limitation and environment.

### **Interdisciplinary goal setting and planning**

In the interdisciplinary approach, each distinct profession evaluates the person separately and interacts together at team meetings, where assessments, short-term and long-term goals are shared. The goals of each discipline are coordinated into a unified plan through the interaction of the team. The whole outcome therefore is more than the sum of the component parts. In our context, a team consisting of a surgeon, a physician, a physiotherapist, a nurse, an occupational therapist and an orthotist, will run assessment clinics. Decisions from these clinics determine the type of interventions to be performed, the sequence of the various activities, and the specific time frame for the individual rehabilitation process.<sup>4,15</sup>

Protocols with fixed time frames for certain procedures are helpful,<sup>5</sup> but should not be seen as the ultimate basis for the rehabilitation planning. If, for example, several interventions need to be planned, prepared and performed at the same time, one needs a good deal of management skills and common sense to provide the best quality of care in the shortest period of time. In the day to day management of a case, the physician and nurses have to be aware of the indications and contra-indications for the various interventions in order to guide the patient accordingly through all related medical and nursing procedures.

Timing for surgery is ideally done by the surgeon himself. But neuropathic limbs often present with conditions, where medical interventions, such as steroid treatment in leprosy reactions, are required first in order to prevent deterioration of the condition. The planning for

surgical interventions should also include consideration of the self-care needs of patients. It is no good planning interventions for both hands at the same time, when the patient will be immobilized for 3 weeks after the operation and might therefore be unable to perform even the simplest activities of daily living. The surgeon will also consider other, perhaps conservative, alternatives to surgical interventions and find ways to consult the physiotherapist, occupational therapist, and orthotist, who can be quite innovative in these cases.<sup>3,34</sup>

It is well known that apart from the surgical procedure itself, physiotherapy and occupational therapy are the most important components of reconstructive interventions. There is no functional ability after a tendon transfer without pre- and post-operative exercises and re-education of muscle activities. The transfer of movements into usual settings and activities as well as successful application of the new activities into the vocational environment, is the challenge of occupational therapy. Without these techniques there is anatomical correction but no functional gain.

Orthoses and prostheses can replace functions that are impossible to achieve through other conservative or operative interventions. In the final phase of rehabilitation these adaptive devices should be considered and applied.

In summary, the interdisciplinary team approach is an exciting challenge and provides a comprehensive pathway for the rehabilitation of persons having neuropathic limbs.<sup>15,23,31</sup>

### **Self-care and self-help: the participatory approach**

People with neuropathic limbs are often limited in their activities of daily living. Deformities and disability also lead to psychosocial problems. Affected persons may not be able to get a job or may even quit their job due to the negative attitude of others against the disease or deformity. In this way the whole family may

suffer.

Prevention of impairment and disability is therefore of utmost importance to people with peripheral neuropathies and neuropathic limbs. It has also become clear that institutional activities alone are not sufficient to prevent further disabilities for such risk groups. Our own hospital data has shown that many admissions could have been prevented by simple but timely care at home. Sensory and motor impairments are often life-long and therefore need an approach that is sustainable over a long period of time and minimises social disruption due to long hospitalization. The strategy that is widely believed to be most effective is known as self-care.<sup>11,21,33</sup>

Self care is based on the principle of transferring the prevention activities from the health professionals to the individual. It involves training individuals to be responsible for looking after their own affected body parts. This requires a transfer of knowledge, skills and motivation, which cannot be achieved by health education alone. It requires teaching as well as practice in a setting similar to the home situation. In such a setting people can learn to anticipate and overcome difficulties, using appropriate solutions under supervision and without risk of deterioration.

There have been very encouraging reports on the positive effect of self help groups in African and Asian communities. The World Health Organisation (WHO) encourages and supports community mobilisation and so called community based rehabilitation (CBR) programmes, since the overwhelming needs of those affected by disabilities and participation restrictions around the world cannot be met by institutions, programmes, and organisations only.

It has also been shown that self-help groups are a very successful tool for the reintegration of persons affected by leprosy into the community and for the continuing prevention of fur-

ther impairment. Apart from the reduction of foot ulcerations, qualitative outcomes include increased confidence to participate in society, restored dignity and self-respect and a sense of belonging to the community.<sup>2,11</sup>

### The role of assistive devices

A wide range of assistive devices are available to improve performance of the so called "community survival skills" or activities of daily living when there is a lasting impairment, which cannot be cured completely. In most cases simple devices improving grip function are sufficient to overcome activity limitations. These are foam padding for combs, cutlery and pens, which improve the grip function by simply increasing the contact area between hand and tool and decrease pressure through materials such as foam (Fig. 24-3). Special designed scissors can replace intrinsic function of the hand by integrating a spring or a plastic loop into the scissors, which then automatically will open after every cut (Fig. 24-4). Cutting boards are used to keep things fixed in place when cutting work needs to be done with a single hand only. For situations with severe deformity, such as complete loss of digits, the wrist cuff is helpful (Fig. 24-5 a-b). The pinch function, i.e. for writing, can be improved by simple writing aids as shown in the illustrations. Functional outcome assessment should take into account the avail-



**FIGURE 24-3** Comb enveloped in microcellular rubber.



**FIGURE 24-4** Scissors 'padded' and with a spring device to facilitate opening.

Orthoses can be constructed from metal, plastic, leather or any combination of these basic materials. Thermosetting materials develop a permanent shape when heat and pressure is applied.<sup>29</sup> For the prevention of further impairment and disability in neuropathic limbs, orthoses can play a major role. Apart from healing plantar ulcerations by immobilizing the involved feet, ankle foot orthoses (AFO) or patella tendon bearing braces (PTB) can be utilized for advanced stages of the neuropathic foot, when bone disintegration is imminent



**FIGURE 24-5** Wrist cuff as a writing aid (a) and an eating aid (b).

ability of assistive devices. Furthermore, in the process of planning surgical interventions one is advised to consider seriously whether the functional benefit of the operation really improves the functional ability more than the use of a simple assistive device.

### Orthoses

Orthoses and braces, as external devices applied to certain body parts, provide support, improve function, correct flexible deformities, and prevent progression of fixed deformities. A temporary orthosis is referred to as a splint.

(Fig. 24-6).<sup>11,8,34</sup> Furthermore, protective footwear using micro-cellular rubber (MCR) inlays, can prevent plantar ulceration and related impairments.<sup>3,34</sup> Different types of braces and orthoses can also be used to compensate limited ability or lost function. These devices are manufactured in our setting using high density polyethylene (HDPE) pipes that are heat moulded onto a plaster last. High density foam rubber covers the interior parts to provide adequate comfort. The resultant devices are rigid but lightweight, provide stability and protection, and costs of material are normally less than those for plaster bandages.<sup>8</sup>



**FIGURE 24-6** Modified patella bearing prosthesis.

### Physical modalities

Physical modalities that use physical energy for their therapeutic effect include thermotherapy (heat and cold), hydrotherapy, electrotherapy, light therapy (ultraviolet and laser), traction, and massage. Effects of general application of heat include relief of pain and muscle spasm, reduction of joint stiffness, and increase in joint range of motion.<sup>3,30,34</sup> Superficial heating agents, such as paraffin or wax, are used in our setting to heat joints with relatively little tissue covering (hand and foot). Electrotherapy, the therapeutic use of electricity, can be used to transcutaneously stimulate nerves or muscles with surface electrodes. Its physiologic effects include muscle group contraction, which can increase joint range of motion (ROM), re-educate muscles, retard muscle atrophy and increase muscle strength. Its use in neuropathic limbs is limited due to the risk of electrochemical burns in skin with decreased sensation.<sup>20,30</sup> The systematic effect of massage by means of rhythmically applied pressure and stretching of soft tissues can either be mechanical (lymphatic drainage, breaking of adhesion and softening scars) or reflexive (vasodilatation, relaxation and sedative effects). The “laying of

hands” also has psychological effects and can promote a sense of well-being.<sup>29</sup>

### Vocational assessment and guidance

For some patients it is impossible to resume their old profession, and retraining and vocational guidance are needed. Retraining should take into consideration the impairments and disabilities of the patient, including anaesthesia, so that in performing work there is no increase of impairment. Vocational guidance should consider the opportunities in the society and other local factors. It is no good training a person in a skill for which there is no opening, nor for a type of work that caste or ethnic group forbids. Direct client assistance and long-term interventions include also the risk of dependency on a specific programme or organisation. This does often prevent a sustainable income. Socio-economic interventions should therefore be carried out carefully and in a participatory approach including clients and their families in the decision making process as early as possible. Assistance should be offered after an extensive socio-economic assessment only, including a home visit. It has been shown however, that micro business skills training for people with disabilities provide opportunities for reintegration and income generation without creating too much dependency on the institution.<sup>6,9,14</sup>

### Outcome assessments

A number of functional assessment instruments have been developed over the last several decades, beginning with Rankin in 1957. These measurements vary in their purpose, scope, detail, and often the type of setting for which they were developed. The Barthel Index (1965) is one of the best known and most frequently used functional assessment scales. It has been extensively studied, showing its high degrees of validity, reliability and sensitivity to changes in function over time, and its use



across many types of physical disability. It has been used in our setting since 1997, but mainly for disabilities not related to leprosy. The original Barthel Index rates 10 aspects of function with a score ranging from 0 (dependent) to 100 (independent) (Table 3). The most commonly used instrument today is the Functional Independence Measure (FIM) consisting of 18 categories of function, each scored on a scale from 1 to 7. The FIM incorporates components of the Barthel Index but is more sensitive and inclusive.<sup>10,12,20,28,29</sup>

related treatment. High ranked items for a good quality of life (QoL) include health care, faith in God, spouse, family, emotional support, friends, home, standard of living, children and family health.<sup>28</sup> Several factors that modulate QoL are influenced by interventions such as counselling. The techniques, which promote healthy coping, include discussion of different perceptions, stress management and guidance in changing perceptions to being useful and experiencing ways of enjoying life. Family members play a critical role in promoting such

**TABLE 3: Categories of the modified Barthel Index.<sup>11</sup>**

	1 1QA\	2 Attempts task but unsafe	3 Moderate help required	4 Minimal help required	5 Full independent
Personal hygiene	0	1	3	4	5
Bathing self	0	1	3	4	5
Feeding	0	2	5	8	10
Toilet	0	2	5	8	10
Stair climbing	0	2	5	8	10
Dressing	0	2	5	8	10
Bowel control	0	2	5	8	10
Bladder control	0	2	5	8	10
Ambulation	0	3	8	12	15
Chair/bed transfers	0	3	8	12	15

#### Converted Score:

- 0-20 Total dependence
- 21-60 Severe dependence
- 61-90 Moderate dependence
- 91-99 Minimal
- 100 Independent of assistance from others.

#### Quality of life

Quality of life has become a slogan for assessing the outcome of all types of diseases and

behaviour change and should be included in interventions to facilitate healthy coping. Since depression and social support are the two most important predictors of QOL they must be addressed in the rehabilitation process. Other variables such as optimism, cognitive appraisal of the significance of disability, coping skills and family functioning are also predictive of QOL. A high score for activities of daily living (ADL) on discharge is another variable indicating good QOL. It has been suggested recently that it is better to talk about health related



QoL.<sup>1</sup> Table 4 shows an example for a health related QoL assessment instrument.

**TABLE 4: Dimensions of Quality of life (EQ-5D self-classifier)<sup>22</sup>**

- Mobility (no problem, some problems, confined to bed)
- Self-Care (no problem, some problems, unable for self-care)
- Usual Activities (no problems, some problems, unable to perform)
- Pain / Discomfort (no pain, moderate pain, extreme pain or discomfort)
- Anxiety / Depression (not anxious, moderately anxious, extremely anxious)

### Patient satisfaction

Patient satisfaction appears to be influenced by numerous demographic and socio-economic factors, such as age, gender, race, social and educational level. All these are considered to affect the degree of satisfaction. In general, older patients tend to demand less and to be more satisfied with the services received. It should be acknowledged however, that the relationship between physical health and satisfaction with medical attention varies according to whether an individual's physical health is self-evaluated or whether it is medically evaluated.<sup>7</sup>

### Summary

Rehabilitation is a process of combined actions rather than a single intervention. The rehabilitation process itself is divided in separate phases, which can be monitored and evaluated by certain instruments. Actions for rehabilitation are carried out by teams rather than by independent individuals and goal setting and planning are ideally also done in an interdisciplinary approach. The person affected by disabili-

ty or activity limitation should actively participate and become the owner of the individual process as soon as possible and as much as possible under the given circumstances. In some cases rehabilitation can become a life-long process and continuing interventions are necessary. In other cases a single rehabilitative procedure can make a life-changing difference. However, medical interventions and social reintegration may eventually lead to the adaptation of a new fulfilling role for the individual in family and society. Evaluation of the individual's quality of life and satisfaction are needed to define the final outcome of the rehabilitation. With the full commitment to reach the optimal level of functional ability for the individual, rehabilitation can be quite a challenge but also a rewarding process for all involved.

### REFERENCES

1. Andresen EM, Meyers AR: Health related quality of life outcome measures. *Arch Phys Med Rehabil* 81: Suppl 2 30-45, 2000
2. Benbow C, Tamiru T: The experience of self care groups with people affected by leprosy: ALERT, Ethiopia. *Lepr Rev* 72: 311-321, 2001
3. Brand, PW, Fritschi EP: Rehabilitation in leprosy, in: Hastings, RC, Leprosy. Churchill Livingstone, Edinburgh, UK, 1985
4. Brandsma JW, McDonald MR, Warren G et al: Assessment and examination of the neurologically impaired foot. *Lepr Rev* 72: 254-262, 2001
5. Brotzman, SB: Rehabilitation protocols. In: *Clinical Orthopaedic Rehabilitation*, Mosby, St. Louis, 1995
6. Bryceson, A, Pfaltzgraff, RE: Social, psychological and vocational rehabilitation. In: *Leprosy*. Churchill Livingstone, Edinburgh, UK, 1990
7. Carcamo CR, Lledo R: Predictors of satisfaction with surgical treatment. *Int J Quality Health Care* 13, 267-269, 2001
8. Chhetri HB, Herm FB: Modified patella tendon bearing brace for the neuropathic foot in leprosy. *Int J Lepr* 69: 2 S 234-235, 2001
9. Chinnery J, Sharma M: Development of appropriate micro finance schemes for people with disabilities in Nepal. *Int J Lepr* 69: 2 S 239, 2001

10. Cohen ME, Marino RJ: The tools of disability outcomes research functional status measures. *Arch Phys Med Rehabil* 81:2S, 21-29, 2000
11. Cross H, Newcombe L: An intensive self care training programme reduces admissions for treatment of plantar ulcers. *Lepr Rev* 72: 276-284, 2001
12. Dobkin, BH: Measures of impairment, measures of disability. In: *Neurologic rehabilitation - contemporary neurology series*, FA Davis, Philadelphia, 1996
13. Fairley M: Unique team concept, in: Hansen's disease - surgery and therapy: Overcoming disability. *Ortho Prosth World* 5 19-24, 2002
14. Grueber M, Gyanwali S: Experiences of micro business skills training of people with disabilities in Nepal. *Int J Lepr* 69: 2S, 239-240, 2001
15. Herm FB, Chhetri HB, Gurung R: The role of the rehabilitation team in prevention of impairment and disability. *Int J Lepr* 69: 2S, 183, 2001
16. Herm FB, Spackman J, Anderson, AM: Experiences with family supported rehabilitation of people with spinal cord injury. *Asia Pacific Disab Rehab J* 11: 31-34, 2000
17. International Classification of Functioning, Disability and Health, World Health Organisation, Geneva, 2001
18. International Classification of Impairment, Disability and Handicap. World Health Organisation, Geneva, 1980
19. Macdonald MRC, Brandsma JW, Warren G et al: Complications and management of the neurologically impaired foot. *Lepr Rev* 72: 263-275, 2001
20. O'Young B, Young MA, Stiens SA: The person, disablement, and the process of rehabilitation. In: *Secrets of PM&R*. Jaypee Brothers, New Delhi, India, 1997
21. Palande DD: Nerve involvement in leprosy - prevention and management of deformities: need for a paradigm-shift. *Lepr Rev* 6: 161-164, 1994
22. Rabin R, de Charro F: EQ-5D: a measure of health related status from the EuroQol group. *Ann Med* 33, 337-343, 2001
23. Rothberg IS: The rehabilitation team: future direction. *Arch Phys Med Rehabil* 62: 407-410, 1981
24. Schuntermann MF: ICIDH and Assessments. *Phys Med Rehab Kuror* 11: 28-36, 2001
25. Shah, S, Vanclay F, Cooper B, Improving the sensitivity of the Barthel Index for stroke rehabilitation. *J Clin Epidem* 42: 703-709, 1989
26. Srinivasan H, Palande DD: *Essential surgery in leprosy - techniques for district hospitals*. WHO, Geneva, 1997
27. Srinivasan H, *Prevention of disabilities in patients with leprosy - a practical guide*. WHO, Geneva, 1993
28. Taly AB, Sivaraman Nair KP, Murali T: Rehabilitation, outcome, and quality of life. In: *Neurorehabilitation principles & practice*. National Institute of Mental Health and Neuro Sciences, Bangalore, 1998
29. Tan JC: Orthoses. In: *Practical manual of Physical Medicine and Rehabilitation*. Mosby, St. Louis, USA, 1998
30. Tan JC: Physical modalities. In: *Practical manual of Physical Medicine and Rehabilitation*. Mosby, St. Louis, 1998
31. Van Bennekom CAM, Jelles F: Instruments to structure interdisciplinary team conferences in rehabilitation medicine, in: *Rehabilitation Activities Profile - the ICIDH as a framework for a problem oriented assessment method in rehabilitation medicine*. Dissertation, University of Amsterdam, The Netherlands, 1995
32. Van Brakel WH, Anderson AMA, Woerpel FC et al: A scale to assess activities of daily living in persons affected by leprosy. *Lepr Rev* 70: 314-323, 1999
33. Van Brakel WH, Anderson AMA: A survey of problems in activities of daily living among persons affected by leprosy. *Asia Pacific Disab Rehab J* 9: 62-67, 1998
34. Warren G, Nade S: The challenge of neuropathy. In: *The care of neuropathic limbs - a practical manual*. The Parthenon Publishing Group, New York, 1999
35. Werner D: *Nothing about us without us - developing innovative technologies for, by and with disabled persons*. HealthWrights, Palo Alto, 1998

# Appendices

---

- A Voluntary Muscle Testing (VMT)
- B Sensory Testing (ST)
- C Skin Care/Self Care Training
- D Removable Modified Total Contact Cast
- E Trial Walking
- F Eye Surgery Assessment (tendon transfer)
- G Hand Surgery Assessment (tendon transfer)
- H Foot Surgery Assessment (tendon transfer)
- I Trans Tibial Prosthetic Measurement Form

# Appendix A

## Green Pastures Hospital & Rehabilitation Centre

Nerve Function Assessment (Febr. '00)

Name:

Hospital No.:

						Day / Month					
						Year					
						<b>FACIAL</b>					
						Eye Closure (Grade)					
						Lid gap (mm) <sup>1</sup>					
						<b>ULNAR</b>					
						Abd. Little Finger					
						Abduction index finger					
						Intrinsic position R-S					
						Intrinsic position L-M					
						<i>FDP(R-S) – FCU</i>					
						<b>MEDIAN</b>					
						Abduction Thumb					
						Opposition thumb					
						<i>FPL-FDS (I)</i>					
						<b>RADIAL</b>					
						Wristextension					
						<b>COMMON PERONEAL</b>					
						Dorsiflexion (TA)					
						Eversion					
						<i>Ext.H – Ext. Digits</i>					
						<b>POSTERIOR TIBIAL</b>					
						<i>TP - FH</i>					
						<i>Great Toe Grip<sup>2</sup></i>					
						<b>Other Tests</b>					
						<i>Signature</i>					

First assessment weakness/paralysis in red; following assessments only deterioration in red

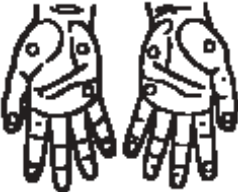

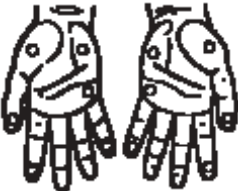




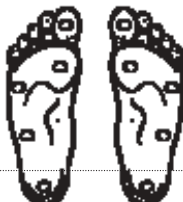
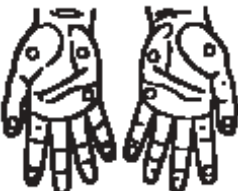



1 Light eye closure 2 S(5)-W(3)-P(0) Muscles in Italics added for more detail & research purpose

**Date:** Comments incl. duration of weakness/paralysis


# Appendix B

## Sensory Testing

Other impairments: ) =absorption; C =clawing/contracture; // = cracks. For wounds : draw to size

		<p>Date:</p> <p>Regular blink:    yes / no</p> <p>If no: comment on completeness, Bells' phenomenon, corneal sensation:</p> <p>Comments:</p>
		<p>Date:</p> <p>Regular blink:    yes / no</p> <p>Comments:</p>
		<p>Date:</p> <p>Regular blink:    yes / no</p> <p>Comments:</p>
		<p>Date:</p> <p>Regular blink:    yes / no</p> <p>Comments:</p>
		<p>Date:</p> <p>Regular blink:    yes / no</p> <p>Comments:</p>
		<p>Date:</p> <p>Regular blink:    yes / no</p> <p>Comments:</p>



# Appendix C

G. Warren

## Skin Care / Self-care Training

Individuals with insensate limbs need to know basic rules of self-care. The main problem is the sensory impairment, which eliminates the 'self protection' reflex. These people need to realise that prevention of impairments is possible. Anybody with (sensory) neuropathy, irrespective of the cause, requires the same basic care if they are to keep their limbs useful and functioning.<sup>5</sup> This includes skin care, removal of callosities and prevention of trauma, including suitable footwear.

### **Patients with sensory impairment should:**

- a. Inspect hands feet daily for symptoms i.e.: redness, swelling, raised temperature, blisters, cracks, ulcers, and then ask: How did this happen? What can I do to prevent it getting worse? The patient needs to learn to use his eyes as a substitute for loss of protective sensation.
- b. Never walk barefoot.
- c. Preferably wear socks as these reduce the chance of minor trauma. They also reduce dehydration of the skin that may occur in hot dry climates. Two pair of socks are better than one pair as any friction is dissipated between the two socks.
- d. Use gloves to protect hands during rough work or when in contact with hot objects.
- e. Be taught how to select suitable shoes from the local market, especially how to find soles that have suitable resilience, not softness.
- f. Check socks and shoes routinely for any irregularities that may harm the foot i.e.:

repaired holes, seams, stitching, foreign bodies and worn insoles.

A patient with neuropathy must learn that good footcare and footwear are essential if (s)he is to continue walking.

### **Footwear should have:**

1. Tough soles to repel stones, tacks and thorns;
2. Resilient insoles to cushion the sole especially when it is scarred or there is atrophy of the small muscles and hence loss of padding and
3. Adequate uppers that are secured on the feet by laces, buckles or Velcro.

In addition the footwear should be socially acceptable.

In some cultures only sandals are the common footwear. Persons with insensate feet have been known to continue walking unaware that the sandal has fallen off. It is important that in those instances sandals have a heel counter. This may be in the form of straps, or be an actual heel in the sandal. Sandals without a heel counter are kept on the feet by contraction of the intrinsic muscles. These may be paralysed when there is a neuropathy. Often the person is not aware of this. Every clinic should have samples of suitable footwear and insoles that are available locally, or be able to provide information where it can be obtained.

### **Autonomic Neuropathy**

With autonomic neuropathy there is alteration in the cycle of production and re-absorption of sebum and sweat. Initially these are still produced but not reabsorbed into the skin. Therefore it is not uncommon in BT/TT leprosy to find a build up of sebaceous material. If allowed to collect uninhibited it can fill the pits of the sebaceous glands and provide a breeding ground for infections. Removal often requires a solvent. A sebum build-up should be a warning that there is a relatively recent neural deficit.

When there is an acute autonomic nerve deficit the affected limb initially may feel warmer than the contralateral limb. It continues to secrete sebum and sweat. However after about 6-12 weeks the limb becomes cool and the persons with sensory impaired feet often complain of cold feet. The autonomic nerves also control capillary lability and when they cease to function the vessels no longer dilate under nerve control. However hyperemia still occurs as a physiological response to infection or trauma. Unfortunately many clinicians fail to accept this occurrence in the autonomically affected limb, and claim that the autonomic impaired limb is warm and if it is cool it shows a poor blood supply. Far from it, the coolness in the autonomically impaired limb often occurs because of the presence of an A-V shunt, and may be associated with distended veins. It has been shown that in people with diabetic neuropathy, the blood passing through the affected foot may be 5 times the amount that passes through a normal foot.<sup>1</sup> The foot has adequate capacity to become hyperemic if infection or trauma occurs. The significance of the alterations in the sebum and sweat cycles is that the skin becomes abnormally dry. A moist sweating foot usually has adequate sensory perception to protect from trauma. Therefore the presence of a dry foot may be a warning that neural impairment is present.<sup>5</sup>

### **Prevention of neuropathic foot problems- The effects of callous**

The natural response of a limb is to produce callous to protect the skin from trauma during use. The neuropathic limb produces more callous than usual. Callous that is well hydrated is supple and pliable but when it becomes dry it becomes hard and un-yielding and may tend to split and crack. As it builds up it produces pressure and local hypoxia or anoxia of the deeper tissues until an ulcer occurs. Cracks will not heal till the callous is removed and the area rested. The most effective way of immobilization and obtaining healing of ulcers/cracks is by the use of the Total Contact Cast (TCC).<sup>2-4,7,8</sup> If the skin is adequately hydrated the callous may remain moist and less likely to crack and while moist the callus can be easily trimmed.

Callous is a response to excessive pressures and friction and stress. It may not be possible to prevent callous build up but it is possible to ensure that it does not develop thick plaques and hard rough lumps.

A *daily routine* has been developed that *has proved effective* in many countries and has greatly reduced foot problems, especially ulceration. Every patient needs to be responsible for the care of his own feet. They should know from the time of diagnosis the importance of skin care and ulcer prevention and that this is the owners' responsibility. If that is impossible, as in the elderly or sight impaired, a relative or spouse should take the responsibility.

### **The daily routine is "Soak Scrape and Oil"**

1. The patient examines his feet to check what needs to be done.
2. The feet, and preferably the legs up to the knees, are soaked in plain, 'cool' water for about 15 minutes. This will rehydrate the skin, and make any callous softer. There is no need to add medication for routine use.

If there is some complicating skin condition some medication could be added. There is no advantage in adding emulsifier, as oiling after the soak will be more effective. While soaking, the patient should wash off dirt etc. Do not use a detergent as it dries the dermis. If soap is needed use oil based soap.

3. After the soak the patient should remove any rough callous or lumps. He is not to try and remove all the callous as that is the natural protection of the feet when it is spread evenly over the feet. It is best to keep one foot in the water while the other is being attended to, so that the second foot does not dry out before it is scraped.
4. Then oil should be rubbed into the skin, to prevent evaporation of the water that has absorbed into the skin. Patients are often given moisturising creams that are based on mineral oils. The human skin does not absorb mineral oils from the skin surface although it makes the skin feel smooth and oily. When observed closely, most of these creams, unless animal oils, do not go into the skin at all. Animal oils such as lanoline and fish liver oils are somewhat absorbed and these should preferably be used. However, these are relatively expensive and not always easy to get. Liquid paraffin is cheap and usually obtainable. If applied in adequate quantities it will prevent evaporation and keep the water in the skin. Avoid edible oils as these attract rats and cockroaches in developing countries.

The soaking of feet for leprosy patients was popularised by Paul Brand who recommended it about 50 years ago. It has stood the test of time and is available and affordable for all. Since then others have also emphasized the need for good foot care and elimination of mechanical problems in maintaining ulcer free feet.<sup>6</sup>

### Scraping

When thick callous dries out it cracks. This may be the start of an ulcer. The removal of callous is essential in ulcer prevention. The callous should be trimmed when the foot is still wet. Many prefer to remove callus with the foot dry rather than after soaking. Dry removal tends to result in cutting the callus rather than scraping it off. This often results in a rough surface. Long practice has shown that using a sharp knife e.g. a surgical scalpel on a well soaked skin results in a smoother and more effective scrape. The knife is used with just a wrist flicking action and scraped off as one would use a safety razor. Callous should not be cut off with scissors or a blade as one would use a carving knife, as this leaves a rough surface which may predispose to ulceration. Once the initial mass of callous has been removed it is possible to keep the foot in good condition by using a green nylon (not metallic) pot scraper, a pumice stone or similar material. In some countries the best material is baked brick. Do not use sandstone as it leaves the grains in the skin or wounds. In the Indian subcontinent the baked clay foot scrapers are effective if rough enough. If one of these 'scrapers' is rubbed on the wet callous every day it should keep the level of callous to a safe thickness.

There are clinicians that object to self-care, but it is necessary as worldwide and certainly in most leprosy endemic countries there is a shortage of 'foot specialists'. Even in 'developed' countries, a patient as a routine can only be seen every 6-8 weeks. This is not acceptable for a patient with a neuropathic foot who already has callous. In three months time they may have an ulcer that could have been prevented. The patient should scrape as soon as there is any hard skin. He should be instructed at the same time how to do it himself. If the patient or relatives are taught properly they ought to be able to keep the feet in good condition. Feet should be checked at every clinic

visit. Every clinic worker should be able to show and instruct self care.

## **CONCLUSION**

It is necessary that the patients learn that the future of their feet and hands depends on the patient himself and the care they take of them. Patients need to know that they can minimise the development of deformity and disability.

**THE DAILY CARE OF NEUROPATHIC LIMBS DEPENDS ON THE PATIENT UNDERSTANDING THE NEED TO REHYDRATE THE SKIN, REMOVE CALLOSITIES, APPLY OIL AND WEAR PROTECTIVE FOOTWEAR.**

## **REFERENCES**

1. Archer AG, Roberts VC, Watkins PJ: Blood flow in the diabetic neuropathic foot. *Diabetologica* 22:9-15, 1982
2. Armstrong DG, Stacpoole-Shea S: Total contact casts and removable cast walkers. *J Am Pod Med Ass*, 89:50-53, 1999 (Abstract)
3. Birke JA, Patout CA. The contact cast: an update and case report. *Wounds*, 12:26-31, 2000
4. Coleman WC, Brand PW, Birke JA: The Total Contact Cast. A therapy for plantar ulceration on insensitive feet. *J Am Pod Med*, 74:548-552, 1984
5. Coleman WC, Brand PW: The diabetic foot. pp. 1159-1181. In Ellenberg M, Rifkin H, eds. *Diabetes Mellitus*. 5th Ed., 1997
6. Delbridge L, Ctercteko G, Fowler C, Reeve TS, Le Quesne LP: The aetiology of diabetic neuropathic ulceration of the foot. *Brit J Surg* 72:1-6, 1985
7. Mueller MJ, Diamond JE, Sinacore DR: Total contact casting in treatment of diabetic plantar ulcer: controlled clinical trial. *Diabetes Care* 12:384-388, 1989
8. Myerson M, Papa J, Eaton K, Wilson K: The total contact cast for management of neuropathic plantar ulceration of the foot. *J Bone Joint Surg*, 74A:261-269, 1992
9. Sinacore DR, Mueller MJ, Diamond JE: Diabetic plantar ulcers treated by total contact casting. *Phys Ther*, 67:1543-1549, 1987

# Appendix D

G. Warren

## Removable Modified Total Contact Cast (TCC)

The following guideline enables the health worker to make a Removable Total Contact Cast (RTTC).

The standard TCC is made with minimal padding (bony prominences such as malleoli) so that there is a complete inability to move any part of the limb inside the cast. Immobilization is essential for the healing of fractures. It also assists in obtaining healing in the shortest possible time in soft tissue injuries or after surgery- especially in the sensory impaired limb.<sup>1-6</sup>

Often clinicians are hesitant to prescribe TCC for fear that the cast may produce ulcers. However, if the casts are moulded carefully to the shape of the foot/lower leg there should not be any movement inside the cast and ulcers should not occur. If the foot is swollen, when the cast is applied, then friction could occur as the swelling decreases. For the above reasons the RTCC has been designed. The limb can be inspected regularly. When the cast is (re)applied it will still be in total contact with the leg. As any swelling subsides an extra thick sock can be applied to maintain total contact. To achieve this the cast is applied over a uniformly thin layer of compressed wool, which is later replaced by a thick sock when the cast is bivalved.

If the limb has a wound that requires dressing, a dressing is applied before the cast is constructed. The same sized dressing is used at each dressing change so that the cast still remains a TCC but the wound can be dressed as needed. When the wound has healed a simi-

lar dressing is still used to occupy the space and ensure the accurate fit.

### **A) Special Considerations**

#### **1. Minimal Padding**

It is advisable to use stockinet, or a similar material, on the leg to hold any dressing, if still needed, in place and keep the plaster from direct contact with the skin. This is especially so with a fibre glass cast as this material can be very irritant and rough to the neuropathic skin. The polyurethane/resin casts (e.g. Dunacast pro) are 'softer' on the skin. If the cast is to be split, the stockinet can be placed over the layers of compressed wool and the stockinet will become part of the bivalved cast, serving as a lining on the finished splint. Do not use adhesive material on the skin, as it may produce an allergy or become loose, roll up, and create a pressure spot. A small amount of non-compressible material such as compressed wool, used to provide a double layer of uniform thickness inside the cast, makes friction spots during use and damage by the saw during removal of the cast, less likely. This wool should not compress enough to allow movement inside the cast if the cast is worn without bivalving. It is replaced by a thick wool sock after the cast is bivalved so that the cast is still fitting when it is replaced.

Stockinet placed over compressed wool can be used to hold in place any essential protective padding. The best padding is orthopedic felt of about 5 mm thickness. Moleskin, or micro-cellular rubber, can also be used.



Commonly used compressible foam is not recommended except for the top of the cast, as it compresses too much. Areas that may need some protective padding are: the top of the cast, the tibial crest, the malleoli, point of the heel, and the metatarsal heads or toe tips. If the toes are clawed use a pad on the dorsal surface to protect the interphalangeal joints from rubbing.

**2. Any Plaster of Paris slab should be rubbed smooth before application.**

This should remove rough ridges and small lumps of plaster that easily occur in a back slab. All plaster bandages should be rolled on carefully to avoid making one edge tighter than the rest. If polyurethane casting material is used, the reinforcing slabs are applied without wetting.

**3. The position desired inside the cast is obtained by manipulation before cast application.**

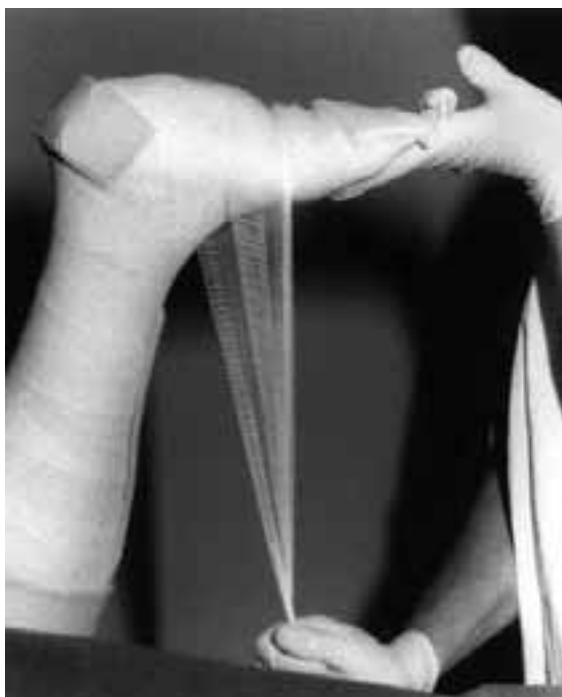This position is maintained until the cast is firm.

The foot should NOT be manipulated after cast application when the plaster is wet. Trying to improve the shape after the plaster is applied is a very common cause of pressure points inside the cast.

**4. Position for cast application**

The patient lies face down on the table with the knee at 90 degrees (Fig. D-1). It is helpful to use a cotton bandage looped around the arch to ensure that the ankle is slightly dorsiflexed and in a functional position without inversion or eversion. This bandage can ensure good moulding of the arch together with the hand of the assistant. The fingers of the assistant also ensure that the MTP joints do not extend. The fingers on the dorsum allow the plantar aspect of the cast to be applied with the toes straight.

In badly deformed feet, such as those with multiple fractures, several cotton bandages can be used to 'mould' the foot in the desired position while the wet plaster is applied (see technique). The bandage is then cut off, at the edge of the plaster, not pulled out, before the cast is completed. If the foot requires reshaping it is wisest to do the primary cast with Plaster of Paris, not fiberglass or polyurethane. Plaster of Paris is far easier to work on deformed feet. The fibre glass is more difficult to smooth over irregular areas.



**FIGURE D-1** Patient is in the position for application. The patient lies prone with the affected leg elevated so it is at 90 degrees to the table and the foot is parallel to the table. Note the bandage over the arch, the padding on heel and tibia and the fingers on dorsum as described in the text.

**5. The sole of the cast**

The sole of the cast should extend at least 1 cm beyond the toe tips to minimise trauma to the toes. The dorsal aspect may be left open if it is

not essential that the toes are fully incorporated in the cast. Make sure the sides of the cast in the metatarsal head area are not tight and compressing or constricting the toes.

## **6. Firm application**

With ordinary plaster of Paris it means it should be applied with some tension over the calf and ankle. There is always some loss of muscle bulk early after application of a first cast and if the plaster is not applied firmly round the ankle and foot it will move with every step and may cause an ulcer. With elasticised plaster bandages some practice is needed to ensure the cast conforms well. The polyurethane bandages are slightly elasticised and this does help in making a good contact.

## **7. Complete drying**

With plaster of Paris it is essential that the patient does not put the foot to the ground for 48 hours to ensure full drying. Drying is by chemical action and not influenced by heating or fanning. If walking is allowed before 48 hours the inner plaster shell may crack. This can cause localized friction or a pressure point. Polyurethane dries in about 20-30 minutes so the patient can leave the clinic walking soon after application.

## **B. Technique of application**

### **1. The foot is cleaned and excessive callous removed**

Any wound is cleaned and dressed. For a simple wound, the cast may well be a Total Contact Cast, not bivalved, at least not initially. Such ulcers can easily be left in the cast without inspection for 6-8 weeks and most will heal in that time. If an ulcer is present a single dressing square is used to cover the ulcer. Note the size of the dressing so that the same sized dressing can be used at every dressing change to ensure identical fit. If the wound is discharg-

ing or it is intended that the cast be bivalved for regular dressing change a more bulky dressing may be used. Select a standard dressing size- e.g. 10x10 cm gauze and wool pad. Apply this with whatever medication may be needed. Do not pack the wound as the packing may produce a local pressure point. If the ulcer is deep or a sinus it can be loosely packed to assist drainage if the cast is to be bivalved and the dressing changed regularly.

### **2. The patient lies prone**

The knee is bend at 90 degrees. The sole of the foot is parallel with the table top. This is the 'economic' position for the person applying the cast and the patient. During application it is essential that the foot is in a neutral position. Some dorsiflexion of the foot may further decrease pressures on the forefoot and mid foot. When the foot is 'boat-shaped' a Böhler iron might be better than a formal cast sole because the Böhler iron takes more of the patient's body weight through the lower leg.

### **3. Padding/protection**

A stockinet is pulled over the lower leg and foot to hold any dressing in place. The stockinet must extend 5 cm beyond the toe tips to just above the knee. A uniform layer of webril (or compressed cotton wool, not foam) is wrapped around the leg and foot. While the webril is being applied make sure the ankle is in the correct position so the wool will not wrinkle when the ankle position is maintained. The wool will be replaced by a thick sock after removal of the cast.

Then pull on a piece of stockinet to cover the foot and leg as high as the knee making sure that it is not deforming the toes and that the webril and any dressing are lying smooth and flat under the stockinet. If the stockinet around the ankle is wrinkled cut it once and stick the cut edges together with adhesive tape.

A piece of suitable protective material (see paragraph A4 above) is stuck to the stockinet around the malleoli and ankle and along both sides of the tibial crest, not right on the crest. The top of the cast, near the knee can be padded with layers of wool or compressed foam that will be turned over the cast. When the cast is bivalved this padding will be incorporated to be a permanent part of the finished cast.

#### 4. Maintaining desired position

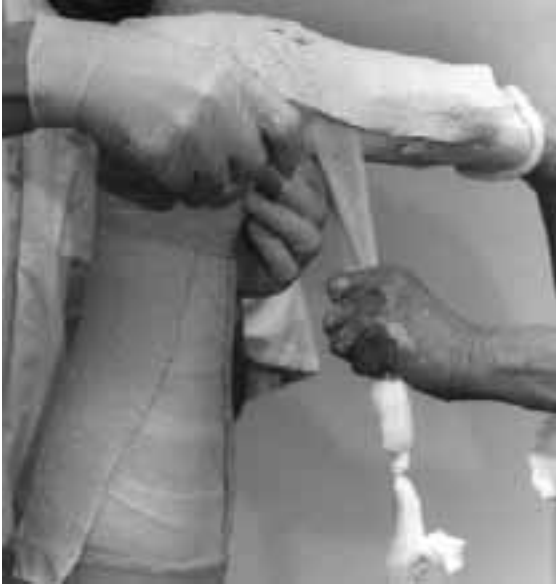If the foot needs to be stabilized in a better position or if there is a fracture that needs reducing, then place a piece of cotton bandage (2-3 cm wide) about 45 cm long round the arch of the foot and tie it in a knot that leaves a big loop below the foot (Fig. D-1). The assistant can then easily stabilize the position of the ankle by pulling on the piece of bandage to keep the ankle at 90 degrees or less. In- and eversion of the heel and foot can also be controlled by pulling the bandage in this way. With the other hand the assistant can plantar flex the toes at the MTP joints (not IP joints), by having the fingers on the dorsum of the foot. If moulding of the arch is needed, the assistant can increase the arch by the degree of tension exerted on the bandage while applying counter pressure with the fingers flat on the dorsum. This should allow the person applying the plaster to make a well-moulded sole without needing to apply local pressure through the plaster. In other words the bandage held by the assistant and the assistant's hand on the dorsum, hold the position so the casting material can just be laid onto the sole of the reshaped foot and bandaged on and rubbed into the curves. In very deformed feet it may be necessary to have two or more assistants pulling bandages in various directions to correct the deformity before applying the cast.

Once the position is satisfactory, commence the actual application. The method will

differ with the various materials available.

#### Plaster of Paris

- a) When Plaster of Paris (POP) is being used make a back slab. Use 15- 20 cm POP rolls and fold (dry) a backslab that extends from 1-2 cm distal to toe tips up to 5 cm below the knee. This needs 8-10 layers if NO fiberglass over-wrap, and 6 layers if fiberglass is used to reinforce the finished cast. Cut darts in it at the heel so it can be properly fitted without making lumps, or cut out wedges at the heel to leave the heel smooth.
- b) Wet the slab well and lay it on a flat table. Rub the plaster in well, making sure all the wrinkles and lumps have gone from the upper surface, and the cut darts are straight, and smooth to fit the heel.
- c) Apply the backslab onto the leg with the smoothed upper surface adjacent to the leg. Start at the toes and place the top (knee end) last. Rub the wet back slab into the arch of the foot and around the heel and sides of the Achilles tendon. Make sure the assistant holds the foot in the desired position. Carefully place the darts together so they make the heel fit without lumps. DO NOT push fingers into the wet plaster, as these may make dints and pressure points. Make sure the sides of the POP at the metatarsophalangeal area and toes are suitable, and protective. It may be most convenient to have the assistant have his little finger protecting one side of the foot and the thumb the other side so that the cast at the sides is not pulled in so tightly that it causes pressure. The cast must extend 1cm beyond the toe tips on the plantar surface when finished.
- d) Take a 10 cm roll of plaster bandage- soak it and start to wrap at the ankle (Fig. D-2). The first throw is passed across the front of the



**FIGURE D-2** The backslab is in place and the plaster is rolled commencing at the ankle.

ankle so that the edges are away from the ankle crease and kept smooth. The raw end of the bandage is over the back slab on the point of the heel. Pass the bandage over the heel point and then back round the ankle and then work outwards making figures of 8 around the ankle. Do not remove the positioning bandage through the arch, or anywhere else till the plaster has dried enough to stabilise the position. Be careful not to make creases in the plaster. Work around the positioning cotton bandages. Wrap plaster bandage round the toes making sure that toes are straight especially at the MTP joints and that the toes are not cramped laterally. The plaster bandage needs to be put on fairly firmly. Apply some tension while unrolling and applying the bandage, especially around the calf and upper leg. It is not advisable to use elasticised plaster bandages as it is very easy for these to be applied too tight without causing pain in the insensate leg.

### Polyurethane/resin

Note that fibre glass leaves a very rough surface and edges and easily damages atrophic or neuropathic skin. It should never be used directly on the skin. Polyurethane/resin bandages are not so likely to damage a-sensitive skin.

- a) To make the back slab take a 10 cm roll. Do not wet it. Use it dry to place over the foot in the position of the back slab. Ensure that the end reaches beyond the toes and let the stretch go before finalizing the length of the slab. The slab needs to reach from 2 cm beyond the toe tips to about 7-8 cm below the popliteal crease when the stretch has gone. Use about 6 layers and smooth it with your hand. Be careful that no one sticks fingers into the Polyurethane/resin bandages. Sudden dents and ridges make very rough areas next to the patient's skin. At the heel, smooth the excess on the sides to make a little pleat which is then cut flat so that the heel fits snugly.
- b) If using Polyurethane/resin take a 7.5 cm roll, wet it well, and start to wrap around the heel - being very careful with the first turn to go from heel point and fold the corners of the tucks into place without making rough bumps inside the cast. The narrower bandage is easier to apply, without wrinkles, than the wider bandages. It is essential that it is completely smooth as it is impossible to remove wrinkles later. From then on the application is much the same as for the POP cast but do not allow it to wrinkle around the bandage pulling the arch or foot into the desired shape. If necessary cut the polyurethane/resin bandage and start again at the toes.
- c) With the next 10 cm bandage start at the knee. Make sure the top is smooth. Cut off

rough cast if needed. Start at the back so the loose end is on the back slab and pull firmly. Pass three turns around the top and then spiral down the leg. Keep it very firm, and apply enough to make it strong. Turn the wool and stockinet down over the top of the cast and fix it with the next roll of plaster which will continue to spiral down the leg. Take up any slack bandage on the back of the leg and not on the front where a lump may be left. The fit of this is critical in making a true TCC. If using POP, when the leg piece is complete, use the palms of both hands to lift the plaster carefully off the tibia, by pressing in from both sides to relieve any pressure over the tibial crest. This cannot really be done with polyurethane/resin bandages and one needs to rely on the pads on either side of the tibial crest. Continue by completing the foot section. Cut off the bandage over the arch that was used for positioning. Do not try and pull it out. Complete the section over the arch with figures of 8 around the ankle and arch, and increase the strength around the toes and then turn back the stockinet at the toes. Make sure that there is adequate POP on the sole and ankle to allow walking and prevent ankle cracks. If the foot is rocker bottomed or the ankle is fixed in plantar flexion so that the sole is not basically flat, plantar grade and convenient for walking, the discrepancy ought to be corrected by a wad of POP, on the heel usually, before the final coat of casting material is applied.

d) If fiberglass or polyurethane is put on top it adds a lot of strength and helps protect from excessive wetting in bathrooms and rainy weather. There is no need to fill in the arch, provided adequate thickness of plaster has been applied. If the foot was held in correct position the patient ought to be able to walk on this cast with or without an overshoe. It


is better to walk on the straight plaster or in an overshoe than to apply a walking heel as the heel increases the leg length discrepancy. If a rubber heel is fitted into the arch it may push into the cast (especially a cast made of POP) that gets wet due to rain, floods, humidity or just carelessness, and cause local pressure over a relatively small area of the arch.

Insist that "NOT ONE STEP" is taken for 48 hours to ensure full drying of the thick POP cast. Putting the foot to the ground for standing at toilet or using the foot to weight-bear during "transfer from bed to chair" is counted as a step! Movement during drying results in cracks. For the patient with two casts applied on the same day it is preferable to insist on complete bed rest for 48 hours to ensure drying without cracking. It is better to wait longer. When using regular POP it is better to wait longer, say 72 hours or even a full week before bivalving.

When Polyurethane/resin is used the cast will be dry enough in half an hour for cutting or for walking.

a) Bivalve the cast, a little anterior to the mid-lateral line. Be careful at the malleoli to ensure you will be able to remove both pieces without destroying either (use an electric saw). You will need to cut the stockinet in the same line, with scissors. Try not to remove the stockinet that is attached to the POP, so do not pull and tug at the cast to remove it. The stockinet should be stuck to the plaster over the calf at least, and will provide a protection from putting the plaster directly against the skin. By using two layers of stockinet where there are dressings, it should be easier to remove the cast without breaking the cast or damaging the patient's skin. The adhesive moleskin, or other padding should be attached between





**FIGURE 3** **a.** A bivalved TCC showing the adhesive tape sealed edges and the foot, in the football sock, lying in the back slab part. The front half is lying alongside, ready to be applied. **b.** The two parts of the slab put together with Velcro tapes around that are not yet tightened.

the plaster and stockinet, to provide protection for as long as the cast is in use.

- b) Use adhesive tape (sticking plaster) to seal all the edges. This will eliminate roughness that may traumatise neuropathic skin and it keeps the stockinet in place. If the stockinet is loose and cannot be smoothed into place remove it completely rather than leave it rough. If that occurs it is best to apply adhesive moleskin or similar direct to the cast to provide the recommended padding on pressure points. It can also be applied over any other rough points or over any site where friction may be occurring in the future or the plaster is rough. Make sure the adhesive tape catches the stockinet and wraps over the cut plaster edges.
- c) Use Velcro straps with or without rings, to make sure the two pieces are easily replaced in the correct alignment (4-6 sets of straps).
- d) Redress the wound with the same amount of dressing material. Then apply a length of tubigrip that is long enough to turn back over the toe and at the top. Alternately, a long sock (e.g. easily stretched such as thick football sock, or hiking sock that goes right

to knee) can be used to replace the original stockinet. It will also fill the space which was occupied by the compressed wool (Webril) and hold the dressings in place. It is much better than a bandage as it will provide uniform thickness and is less likely to wrinkle, especially if turned down at the top. Apply the two pieces of cast around the leg. Use two socks if the cast seems loose. Extra socks can be added from time to time as the edema lessens or the cast seems to become loose. Fix the Velcro tapes. Turn down the top of the sock, over the Velcro, to keep the top firm. Make sure the patient realizes that this also helps to keep the sock smooth inside and prevents a "concertina" effect of the sock under the cast

- e) If necessary wrap an elastic bandage over the whole cast to make sure it does not slip. Well-placed Velcro should eliminate the need for the bandage. Some patients prefer the bandage which is satisfactory if really firm, so should not be an elastic bandage. Apply the overshoe and let the patient walk. Do not try and discard the dorsal side of the cast. In the neuropathic limb bandages that are tight enough to keep a back slab firm during walking may cause excessive

pressure, even gangrene of the skin, around the ankle and lower leg. Also, discarding the dorsal half eliminates the Total Contact Cast effect.

## NOTES

When the foot is fixed in plantar flexion and there is an ulcer over the peak of a boat shaped foot it may be difficult to get full healing by a TCC.<sup>4</sup> In such cases it is best to plan a non-removable cast made with a very firm well fitted leg piece. This extends from above the malleoli to just below the tibial flare, thick enough to support a Böhler iron. The patient can walk on the iron with the body weight being carried through the shin and calf instead of the foot. It ought to be used in markedly boat shaped feet or in feet in which the talus is in danger of compression. The foot is still encased in a plaster, and does not allow trauma by bumping or direct pressure on the ulcer during walking. This means the plaster on the foot merely holds the position without allowing any weight to be borne on the ulcerated area. If it is necessary to change the dressing at regular intervals a window or a 'trapdoor' of POP or padded fibre glass can be made. Attach it with adhesive over the ulcerated area to reduce the chance of the inflamed and traumatized area from pushing through into the hole of the trapdoor. This helps to prevent further trauma to the already traumatized area. In most situations it will be better to completely seal the ulcerated area, or the inflamed area tends to mushroom through the window.

## COMMENTS

Thick football or hiking socks (wool is best) are ideal. If the cast was made with little or no padding (as described) the sock provides enough padding to ensure close fit. If the patient loses weight or the cast seems loose just add another sock or two. It is easier to put on a sock without wrinkles than to put on a crepe bandage in the same thickness as previously. So a uniform 'padding' of sock is provided that can easily be increased, and it is easier

to put on than a uniformly thick bandage that does not produce excessive pressures or lumps.

All patients ought to wear long socks or tubigrip that turns over at top and bottom at all times when using a total contact bivalved walking plaster cast. It is very difficult to provide, by bandaging, a uniform thickness of padding from one day to the next, or in different parts of the leg, by other means. Also it ought to be a complete long sock. Short socks or those with toes cut out (so the patient's toes can be seen), tend to wrinkle up inside the cast and this may produce other problems.

Bivalved TCCs are meant for full time wear. Patients need to have this explained. Many think "I do not need it when at home". The cast protects from minor rubs, bumps, friction and even burns. In patients in whom there is a sensory neuropathy it is essential that they learn that they must actively protect their affected limbs at all times. However, a removable TCC may, in selected cases, allow the co-operative patient the privilege of a bath, and a dressing change. The cast is removed and replaced while sitting on the edge of the bath, no steps allowed thus keeping the foot rested and protected during normal daily activity. They allow many patients to be treated at home, instead of being hospitalised. But they require very careful application, and bivalving, and a co-operative patient.

The patient ought to be able to do his own dressing and replace the TCC himself. Hence his treatment can continue at home. Also the use of a TCC after bivalving can be utilized as a learning time while the patient learns self-care (appendix C). It can be slowly discarded as the patient undergoes Trial walking before being allowed to resume unrestricted walking (appendix E). The bivalved cast is valuable for the patient's future. He should keep the cast and if the foot suffers trauma or ulceration he can use the cast again, without having to go to clinic to get one made for him. The patient

needs to understand how the bivalved TCC can help. We can help the patient to learn and we may have to 'educate' the patient many times before the patient finally understands and learns to look after himself.

## REFERENCES

1. Brand PW: Insensitive Feet. The Leprosy Mission International, London, 1989
2. Coleman WC. Brand PW, Birke JA: The Total Contact Cast. A therapy for plantar ulceration on insensitive feet. *J Am Pod Med Ass*, 74:548-552, 1984
3. Novick A, Birke JA, Graham SL, Koziattek E: Effect of a walking splint and TCC on plantar forces. *J Prosth Orthot*, 3;168-178, 1990
4. Shaw ES. Wei-li His, Ulbrecht JS. Norkitis A, Becker MB, Cavanagh PR: The mechanism of plantar unloading in Total Contact Casts. Implications for design and clinical use. *Foot Ankle Int* 18:809-816, 1997
5. Warren G: The surgical conservation of the neuropathic foot. *Ann Roy Coll Surg* 71: 236-242, 1989
6. Warren G, Nade S: The Care of Neuropathic Limbs, Parthenon Publications, 1999

# Appendix E

G. Warren

## Trial Walking

Trial walking (TW) should be used when a patient with a neuropathic foot resumes normal walking after a long period of bed rest or a period in a walking plaster cast. This will test the integrity of the foot by showing if the healing of any pathological lesions of skin, soft tissues or bone is mature enough to withstand the stress of walking.<sup>2</sup>

### METHOD

- 1) Skin care (see appendix C).
  - a. Soak the foot and remove excess callus;
  - b. Oil skin;
  - c. Put on suitable footwear, preferably lace-ups.
- 2) Supervised walking.
  - a. Supervised walking for 3 minutes on a level surface;
  - b. Rest the foot with the shoe off and splint on, (foot elevated if indicated).
  - c. Two hours after the walk check the foot for heat and swelling. Any hand will do, preferably the patients' hand.<sup>1</sup> (chapter 13)
  - d. If the foot shows no heat or swelling repeat the above after 2 hours. Continue to walk each 2 hours i.e. up to 4 or 5 times daily as long as no symptoms occur.

The duration of the TW can be increased daily to 5, 10, 15, 20 minutes. Continue each day increasing the duration of walk till the foot

tolerates 30-40 minutes each session, without heat and swelling. Particularly notice if there is heat or swelling first thing in the morning as this would indicate that swelling has persisted all night and hence is probably of concern and not just 'travel oedema'.

Increasing walking sessions and/or increasing walking time are the 2 common factors to develop a graded walking exercises program for a foot that has been non- or partial weight-bearing for a prolonged time.

If bathroom scales are available then this could also be used to develop an individual graded walking program for the patient. The patient could be taught to 'load' the foot by say 20 kg, and walk for a certain length of time, or distance. The 'loading' of the limb can then be increased over a period of several days/weeks until the patient is full weightbearing. This may not always be 'practical' for leprosy patients in remote areas but could be practised with patients in special settings.

If there is a hot spot, then suspend all walking till the temperature and swelling has normalised. In some patients there is a very low degree of heat and it may be the swelling that indicates a problem. When heat and swelling persists it is advisable to rest and then start again with a shorter time of walking and proceed at a slower rate.

If the heat or swelling persists, or keeps recurring there is probably still active tissue pathology and complete immobilisation should be provided for 6-12 weeks before trial walking is again instituted.

A recommended schedule for trial walking is:

Day	1-2	3-5	minute walks.	
Day	3-6	Walk	5, 7, 10	minutes.
Day	7-9	Walk	7,10,15	minutes.
Day	10-13	Walk	10, 15, 20	minutes.
Day	14-16	Walk	15, 20, 25, 30.	Add steps.
Day	17-20	Walk	20, 25, 30.	Add steps or rough paths.
Day	21	Walk	25, 30 & 40	

A schedule could be handed to the patient on discharge on which the therapist marks the recommended duration for each session of walking.

A period of trial walking is mandatory for patients that have been immobilised for a prolonged period for neuropathic bone disintegration.

In addition trial walking could be used for:

- a) Patients resuming walking after prolonged inactivity following plantar ulceration. TW minimises the possibility of stress fractures in the osteoporotic bone and it allows the patient to monitor the ulcer scar to test if it is strong enough for use.
- b) Patient presenting with a hot swollen foot in the absence of other clinical signs. The swelling should subside within a few days if the patient rests. Trial walking is the guide to normal use. If swelling/heat returns the leg should be put back in a TCC for 6-8 weeks even if a firm diagnosis can not be made. There are patients in whom

a mildly swollen foot that was present for years suddenly disintegrated. Obviously a slowly progressing bone disintegration at last reached the stage when it could no longer withstand the stress. A stress fracture may present as heat and swelling but there is no visible sign on a radiograph for 6-12 weeks. If a TCC is used early in a stress fracture it would often prevent deformity.

## CONCLUSION

Trial walking is a simple way of testing the integrity of the foot and its ability to function without increasing trauma. Because of the lack of pain sensation it may be difficult to get the patients to co-operate unless they are under daily supervision as in a hospital. However, many patients have carried out TW at home with a removable TCC.

In the absence of pain, heat and swelling are the only signs that warn the patient that trauma has occurred to the foot and that something needs be done to assist the body to achieve healing. Trial walking allows the patient and clinician to test the limb's reaction to stress, act on swelling and heat and prevent neuropathic bone lesions.

## REFERENCES

1. Hoeksma AF, Faber WR: Assessment of skin temperature by palpation in leprosy patients: interobserver reliability and correlation with infrared thermometry. *Int J Lepr* 68:65-67, 2000
2. Warren G, Nade S: *The care of Neuropathic Limbs- a practical manual*. Parthenon, New York, London, 1999



# Appendix F

## Green Pastures Hospital & Rehabilitation Centre

### EYE SURGERY ASSESSMENT

(Pre- postoperative and Review)

Date: \_\_\_\_\_

Card No: \_\_\_\_\_

Age: \_\_\_\_\_ / YOB \_\_\_\_\_

Impairment grade:

RE	LE	RH	LH	RF	LF

#### RIGHT Eye

Discharge Date: \_\_\_\_\_      Review \_\_\_\_\_      Review \_\_\_\_\_

##### Normal

Blink: \_\_\_\_\_

Corneal Sensation:      yes/no      yes/no      yes/no      yes/no

Lidgap (tight eye closure)      \_\_\_mm      \_\_\_mm      \_\_\_mm      \_\_\_mm

Ectropion      yes/no      yes/no      yes/no      yes/no

Entropion      yes/no      yes/no      yes/no      yes/no

Tearing      yes/no      yes/no      yes/no      yes/no

Operation: \_\_\_\_\_

Date: \_\_\_\_\_ Surgeon: \_\_\_\_\_

Comments: (ocular pathology, adhesions, regular use of TT, etc.)

#### LEFT Eye

Discharge Date: \_\_\_\_\_      Review \_\_\_\_\_      Review \_\_\_\_\_

##### Normal

Blink: \_\_\_\_\_

Corneal Sensation:      yes/no      yes/no      yes/no      yes/no

Lidgap (tight eye closure)      \_\_\_mm      \_\_\_mm      \_\_\_mm      \_\_\_mm

Ectropion      yes/no      yes/no      yes/no      yes/no

Entropion      yes/no      yes/no      yes/no      yes/no

Tearing      yes/no      yes/no      yes/no      yes/no

Operation: \_\_\_\_\_

Date: \_\_\_\_\_ Surgeon: \_\_\_\_\_

Comments: (ocular pathology, adhesions, regular use of TT, etc.)

# Appendix G1

## Green Pastures Hospital & Rehabilitation Centre

### HAND SURGERY TENDON TRANSFER

(Pre- postoperative and Review)

Right – Left (circle)

Date: \_\_\_\_\_

Name : \_\_\_\_\_

Card no: \_\_\_\_\_

Gender : \_\_\_\_ Age: \_\_\_\_ (at time of surgery)

Imp.

RE	LE	RH	LH	RF	LF

**ANGLES:** Reverse side

#### MUSCLE TESTING:

##### *Ulnar*

Abd. Little finger    \_\_\_

Abd. Index            \_\_\_

Intrinsic position    \_\_\_

##### *Median*

Abd. Thumb           \_\_\_

Opp. Thumb           \_\_\_

\_\_\_\_\_

Duration of paralysis: \_\_\_\_\_

##### *Radial*

FDP-R/S            \_\_\_

FCU                \_\_\_

FDP-I/M            \_\_\_

FPL                \_\_\_

Pr.T                \_\_\_

PL                  \_\_\_

FDS                \_\_\_

ECRL/B            \_\_\_

ECU                \_\_\_

EDC                \_\_\_

EPL                \_\_\_

EIP/EDM           \_\_\_

**DEFECTS** (checklist)    (Key: 1=thumb; 2= index finger etc.)

	Pre Therapy	Pre-Op. Date:	Discharge Date:	Review	Review	Review
Flexor tightness						
Mallet deformity						
Boutonniere						
Absorbtion						
Check rein	XX	XX				

**Functional Assessment**

	<b>Pre Therapy</b>	<b>Pre-Op Date:</b>	<b>Discharge Date:</b>	<b>Review</b>	<b>Review</b>	<b>Review</b>
Grip strength						
Key pinch						
Grip contact						
Moberg test						
9 hole peg board						
SALSA						
Opposition						

**Subjective: Preoperative**

- What is of concern to the patient?                      Appearance – function – both                      (circle)
- List specific functions/tasks that the patient finds difficult or impossible to do:

**Hand surgery 1:** \_\_\_\_\_ **Date:** \_\_\_\_\_ **Surgeon:** \_\_\_\_\_

**Hand surgery 2:** \_\_\_\_\_ **Date:** \_\_\_\_\_ **Surgeon:** \_\_\_\_\_

**Previous surgery:**

**Review:** Is the patient pleased with the result?: very happy - happy - no change - worse

VMT Postop change?: \_\_\_\_\_

**Comments:**

# Appendix G2

## Green Pastures Hospital & Rehabilitation Centre

### HAND SURGERY : ANGLES

(Key: active - green; assisted - blue; contracture - red)

	Date: / /	Pre PT	Pre OP	Wk-1	Wk-2	Wk-3	Wk-4	Rev-1	Rev-2
Middle	100								
	90								
	80								
	70								
	60								
	50								
	40								
	30								
	20								
	0								

	Date: / /	Pre PT	Pre OP	Wk-1	Wk-2	Wk-3	Wk-4	Rev-1	Rev-2
Little	100								
	90								
	80								
	70								
	60								
	50								
	40								
	30								
	20								
	0								

Thumb IP  
MCP

	Date: / /	Pre PT	Pre OP	Wk-1	Wk-2	Wk-3	Wk-4	Rev-1	Rev-2
Index	100								
	90								
	80								
	70								
	60								
	50								
	40								
	30								
	20								
	0								

	Date: / /	Pre PT	Pre OP	Wk-1	Wk-2	Wk-3	Wk-4	Rev-1	Rev-2
Ring	100								
	90								
	80								
	70								
	60								
	50								
	40								
	30								
	20								
	0								

Web  
angle

# Appendix H

## Green Pastures Hospital & Rehabilitation Centre

### TT FOOT SURGERY ASSESSMENT

(Pre- postoperative and Review)

Date: \_\_\_\_\_

Card No: \_\_\_\_\_

Right / Left (circle)

Age: \_\_\_\_\_ / YOB \_\_\_\_\_

Impairment grade:

RE	LE	RH	LH	RF	LF

**MUSCLE grading** TA \_\_\_\_\_

PL/B \_\_\_\_\_

TP \_\_\_\_\_

EDL \_\_\_\_\_

Comments:

EH \_\_\_\_\_

#### ANGLES:

Review:

	Pre	Wk 1	Wk 2	Wk 3	Wk 4				
Date									
Pass. dorsiflexion KE		XX	XX	XX					
Pass. dorsiflexion KF		XX	XX	XX					
Active plantar flexion		XX	XX	XX					
Active dorsiflexion									
Rest position									
Active range									

(Active range=restposition minus active dorsiflexion)

Pre-surgery comments:

Surgery:

Date: \_\_\_\_\_ Surgeon: \_\_\_\_\_ Tendon(s) transferred \_\_\_\_\_

Cast removal date: \_\_\_\_\_

route: circumtibial - interosseus

Insertion: TA – EDL – EH – PT (circle)

Other:

Estimated angle of immobilisation: \_\_\_\_\_ degrees

Postsurgery comments:

Gait (discharge/review):



# Appendix I

## Trans Tibial Prosthetic Measurement Form

Client Name: \_\_\_\_\_ Date of Casting \_\_\_\_\_

File No: \_\_\_\_\_ Date of Fitting \_\_\_\_\_

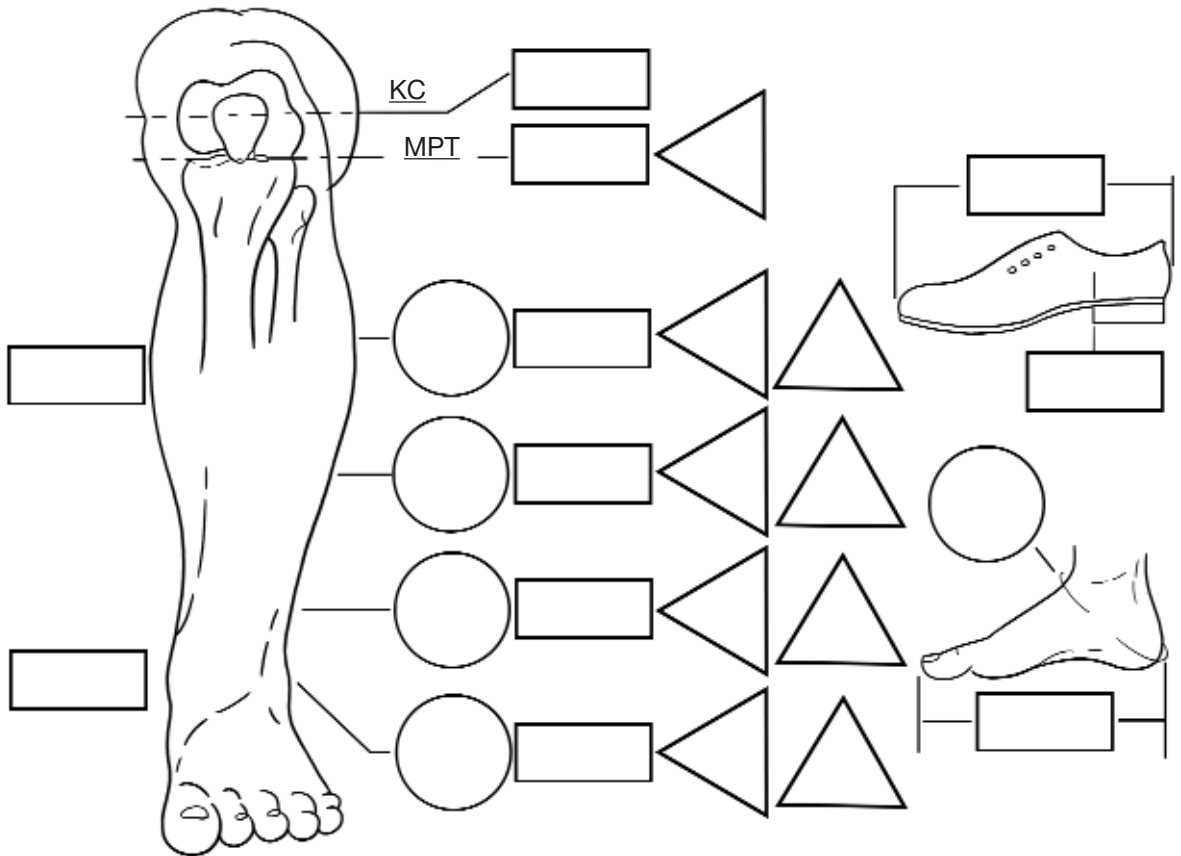
Male/Female: \_\_\_\_\_ Left/Right \_\_\_\_\_ Date of Delivering \_\_\_\_\_

Name Prosthetist \_\_\_\_\_

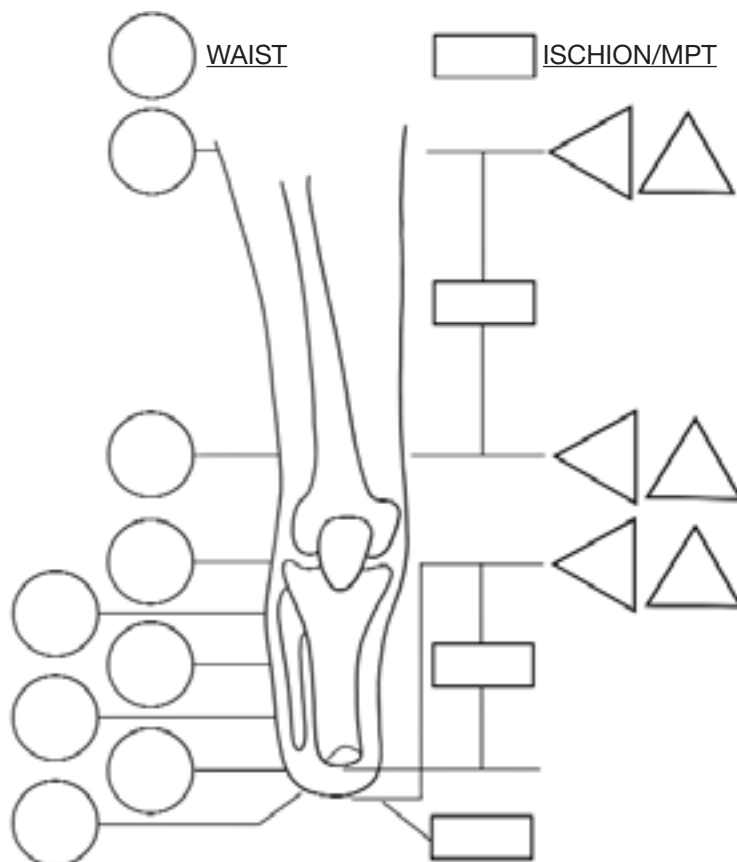
Remarks \_\_\_\_\_

\_\_\_\_\_

### STUMP MEASUREMENTS



**380** Surgical Reconstruction & Rehabilitation in Leprosy



	Old prosthesis	Mold: Initial Measurements	Mold: Final Measurements
0			
2.5			
5.0			
7.5			
10			
12.5			
15.0			
20.0			
AP			
ML			
MLSC			

# Indexes

## A

A-V shunt, 149, 360  
A1 pulley, 55  
Abductor Digiti Minimi Transfer, 74  
Achilles tendon lengthening 175, 179  
Activities of Daily Living, 19, 114, 327, 346  
Activity limitations, 344  
Acute ulcer, 206  
Adapted appliances, 123  
Adenitis, 201  
Adhesions, 2, 7, 55, 87, 127, 184, 318,  
Aesthetic surgery, 271  
Aetiology of joint stiffness, 127  
Amputation, 123, 158, 250, 335  
(see named techniques)  
Anaesthesia, 2  
Anastomosis, 52, 55  
Anderson tunneller, 5  
Angle measurement, 44  
Ankle Foot Orthoses, 329  
Ankle joint, 142  
Ankle arthrodesis, 161, 165, 170  
Ankle sprains, 144  
Anti Pronatory Orthosis, 243  
Anti-clawing muscles, 42  
Antibiotics, 152, 207, 209  
Antiseptic agents, 208  
Aphasic STJ Pronation, 136  
Aphasic STJ Supination, 137  
Aphasic Supination, 138  
Aphasic instability, 134  
Aphasic plantarflexion, 144  
Appliances, 237, 327  
Arteriitis, 194  
Arthritis, 202  
Arthrodesis, 6, 58, 63, 75, 79, 128, 228, 164, 186,  
189 (see also named techniques)  
Arthrotomy, 189  
Assessment, 19, 39, 44, 133, 179, 304, 306, 311,  
303

Assisted- active extension 43, 45  
Assistive devices, 348  
Attenuation (extensor mechanism), 43  
Autolytic debridement, 213  
Autonomic neuropathy, 2, 11, 13, 147, 360

## B

Backslab, 333  
Baggy ears, 298  
Ballpen test, 2, 14  
Barthel Index, 350  
Bed rest, 158  
Bells's palsy, 4  
Bell's phenomenon, 313  
Below-knee amputation, 250, 253  
Biopsy, 249  
Bivalved cast, 164, 363, 369  
Blindness, 257  
Blink, 257, 358  
Blister, 198, 200, 205, 359  
Blount's staples, 165  
Bone fixation method, 122  
Bone grafts, 278, 290  
Bone biopsy, 155  
Bony prominence, 227  
Boutonniere deformity, 43, 319, 321  
Boyd amputation, 251  
Braces, 161  
Brachioradialis to Flexor Pollicis Longus Transfer, 76  
Brand anastomosis, 6, 52  
Brand extensor to flexor four tailed (EF4T), 50  
Bucket-handle (flap), 220  
Bumpectomy, 163  
Bunnell's Flexor Carpi Ulnaris (FCU) Pulley, 70  
Burn 200, 204, 205  
Bursa, 203

## C

Calcaneal spurs, 143  
Calipers, 161

Callosities, 2, 359, 360,  
Campbell-Thompson Route, 70  
Canthoplasties, 260, 258  
Capillary lability, 149, 360  
Capsular reconstruction, 79  
Capsulectomy, 128, 132  
Capsulodesis, 50  
Carcinoma, 249  
Carpal tunnel decompression, 319  
Carpal tunnel syndrome, 72  
Carpometacarpal joint disorders, 66, 78  
Cartilage grafts, 262, 273, 276  
Castor oil drops, 258  
Cauliflower growth, 202  
Cellulitis, 209, 254  
Cerebral Palsy, 180  
Charcot foot, 150, 233  
Charcot-Marie-Tooth disease, 4  
Charnleys clamps, 165  
Check rein deformity, 68, 308, 320  
Choice of muscle-tendon unit, 7  
Chronic simple ulcer, 201, 210, 211  
Cigarette smoking, 159  
Circumtibial route (footdrop correction), 175, 182  
Classification of Mitten hands, 114, 116  
Claw finger correction, 131, 319  
Claw fingers, 34, 41, 304  
Claw toes, 178, 184, 188, 328  
Clostridial infections, 216  
Cobra pad, 243  
Cocaine, 273  
Cocket Hat procedure, 119  
Cocked toe, 188, 190  
Cockup wrist splint, 84  
Cold feet, 360  
Columella strut, 278  
Combined nerve palsies, 91  
Common peroneal nerve (paralysis), 175, 311, 329  
Compliance, 158  
Compression neuropathy, 12  
Congenital indifference to pain, 148  
Contracted claw hand, 58  
Contracture, 6, 34, 36, 43, 49, 78, 127, 308  
Cooking, 328  
Corneal exposure, 257, 323  
Corneum cuteum, 249  
Corticosteroids, 159  
Cosmesis, 335  
Cosmetic impairment, 305

Cosmetic procedure, 317  
Counselling, 1, 346  
Crack, 2, 34, 203, 204, 218, 359  
Crank handle action (thumb), 75  
Crockett's Operation, 287  
Cross facial nerve grafts, 258  
Cross-finger flap, 128  
Cross-Foot Flap, 232  
Cross-leg flap, 250  
Crutches 36-37, 179  
Cubital tunnel decompression, 318  
Culture, 210, 327  
Cuts, 204  
Cylindrical plasters, 304, 307

## **D**

Dacrocystitis, 323  
Debridement, 208, 213  
Decalcification, 152  
Decompression, 28-29,  
Decompression of the common peroneal, 176  
Deformity, 305  
Dehabilitation, 193  
Dehydration, 359  
Delayed healing, 213  
Diabetes, 34, 147, 152, 158, 251  
Diabetic neuropathy, 17  
Disability, 344  
Distal transverse metacarpal arch, 48, 54, 321  
Doppler, 292, 230  
Dorsal Flap Webplasty, 117  
Dorsal fixation of the lateral bands, 54  
Dorsalis pedis artery, 230  
Drainage, 206, 208  
Dressing, 206, 363  
Dry skin, 13, 204, 218  
Dwyer calcaneal osteotomy 186  
Dynamic procedures (tendon transfers), 50,  
Dynamic splints, 176  
Dynamic tenodesis, 77  
Dynamometry 14, 19, 45  
Dysplasia, 249, 318

## **E**

Ear cartilage graft, 258, 261  
Ear cartilage, 277  
Ear reconstruction, 271, 272, 273  
Ectropion 323

Electrical stimulation, 37, 258, 308, 314  
 Epicondylectomy, 29  
 Epineurotomy, 26, 28  
 Erythema Nodosum Leprosum, 194  
 Eusol, 207  
 Examination, 138, 142  
 Excursion of a muscle 7  
 Exercises, 34, 258, 306  
 Exposure keratitis 257  
 Extensor Carpi Radialis Longus to Adductor Transfer, 60  
 Extensor Carpi Radialis Longus to Flexor Digitorum Profundus Transfer, 77  
 Extensor to Extensor Many Tailed, 55  
 Extensor Indicis Proprius (EIP) Opponensplasty, 71  
 Extensor indicis transfer, 309  
 Extensor Pollicis Longus, 75, 89  
 Extensor Pollicis Longus Re-Routing, 72, 310, 322  
 Extensor Proprius Transfer, 58  
 Extensor diversion graft, 50  
 Extensor mechanism (finger), 43  
 External fixators, 128  
 Extra-plantar foot ulcers, 203  
 Eyebrow (replacement), 272, 293

## **F**

Face lifts, 272, 273, 299  
 Facial asymmetry, 313  
 Facial impairment, 271  
 Facial nerve, 257  
 Facial nerve grafts, 268  
 Facial paralysis 257, 272  
 Farina's procedure, 291  
 Fascia lata, 2, 52  
 Fascicular neurolysis, 319  
 Fasciitis, 143  
 Fasciocutaneous flap 228  
 Fiberglass, 364, 368  
 Fibrosis, 207  
 Filleted Toe Flap, 234  
 Finger flexor tightness, 36  
 First web space contractures, 66  
 First ray function (metatarsal), 244  
 Fish-mouth flaps 250  
 Fissures, 204  
 Fixators, 127  
 Fixed Ankle Brace, 18, 334  
 Fixed varus, 241  
 Flaps (skin), see named techniques

Flexor Carpi Radialis Transfer, 55, 87  
 Flexor Digitorum Superficialis to Adductor Pollicis Transfer, 60  
 Flexor Digitorum Superficialis Transfer, 55, 309  
 Flexor Pollicis Longus Transfer, 74  
 Flexor Pulley (Zancolli Lasso- Brooks), 57  
 Flexor tightness 6, 43, 307  
 Flexor to extensor transfer, 188  
 Flexor digitorum superficialis (FDS) transfer, 67  
 Flexor-adductor replacement, 63  
 Foam padding, 348  
 Foot function, 135  
 Foot orthosis, 240  
 Foot structure, 240  
 Foot-care, 218  
 Foot-drop, 36, 304, 329  
 Footdrop springs, 311, 329  
 Footdrop correction, 310  
 Footwear, 34, 213, 218, 228, 236, 237, 327, 359  
 (see also sandal)  
 Force (mechanics), 247  
 Forefoot equinus, 140  
 Forefoot valgus, 139  
 Forefoot varus, 139-140  
 Forehead flap, 276, 279, 291  
 Fractures, 161  
 Free skin grafting, 128  
 Friction, 205, 237, 247, 314  
 Froment's sign, 41, 59, 61, 75, 305  
 Frontalis muscle, 292  
 Full thickness grafts, 212, 296  
 Functional anatomy, 177  
 Functional assessment, 45  
 Functional orthosis, 240  
 Functional assessment, 304, 346  
 Functional impairment, 305  
 Functional sensibility, 42, 45

## **G**

Gait (analysis), 136, 141, 144, 176, 178, 329-330  
 Gas gangrene, 202, 216  
 Gillies method, 262  
 Girdlestone operation, 164, 172, 188  
 Gloves, 219, 328, 359  
 Goal setting (in rehabilitation), 347  
 Gold weight implantation, 260  
 Graded vs. Non-graded Tests, 12  
 Grading nasal collapse, 274



Grasp(ing), 41, 48, 114,  
Grice operation, 167  
Grip, 33, 45, 328  
Grip aids, 123, 344  
Grip strength, 90, 321  
Guideline, 305, 311  
Guillain-Barré, 4, 303  
Guillotine amputation, 254  
Guttae percha, 284, 286  
Guttering (of tendons), 322  
Guyon's canal, 74

## **H**

Hair follicles replacement, 272  
Half Flexor Pollicis Longus to Extensor Pollicis Longus transfer, 61  
Half gastrocnemius split, 186  
Hammer toe, 188  
Hand function, 114  
Harris mat 221, 239  
Hathi pad, 243  
Healing time, 160  
Health education, 113  
Heat, 150, 159  
Heel (strike), 229, 134-135 (see also gait, walking)  
Heel ulcers, 238  
Hereditary Motor Sensory Neuropathy, 303  
Hidden clawing (fingers), 42  
High Median Nerve Palsy, 76  
High stepping gait, 175, 329  
Historical Review (ulcers), 196  
Hooding, 43  
Hot spots, 149, 155, 205, 372  
Hyperaemia, 158, 360  
Hyperkeratosis (see also callous), 204, 249  
Hypermobility foot, 142  
Hypertrophic scars, 317

## **I**

ILEP, 304  
Iliac crest (bone graft), 279  
Imbalanced tension, 322  
Immobilisation, 8, 159  
Impairments, 33, 344  
Inclusion for Tibialis Posterior Transfer, 178  
Incorrect tension, 9  
Individual follicle planting, 294  
Infection, 198, 205, 216

Inflammation, 198, 205  
Insole, 237, 334, 359  
Interfascicular neurolysis, 28  
Internal fixation, 167  
Interosseous tendons, 58  
Intraneural fibrosis, 319  
Intrinsic plus, superficialis minus, 58  
Intrinsic reactivation technique, 58  
Intrinsic minus hand, 48, 219  
Intrinsic muscles, 39  
Intrinsic muscles of the foot, 328  
Intrinsic plus deformity, 49, 54, 320  
Inversion deformity, 182  
Ischemia, 196  
Island flap, 120

## **J**

Jaipur foot, 336  
Jeanne's sign, 41  
JESS techniques, 128  
Johnson's method, 264  
Joint stability, 133  
Joint stiffness, 34

## **K**

K-wires, 119, 130, 165  
Keratitis, 257  
Key pinch, 59-60, 65  
Krukenburg procedure, 123

## **L**

Lachrymal punctum, 258, 260  
Lagophthalmos, 257, 272, 313, 323  
Lasso procedure, 57, 307  
Latent clawing (see also clawing), 305  
Lateral band insertion: (Stiles - Bunnell - Brand), 56  
Lateral lower lid canthoplasty, 260  
Lateral tarsorrhaphy, 259  
Lateral femoral cutaneous nerve block, 2  
Lateral malleolus, 203  
Lateral tarsal strip procedure, 323  
Laterally based transposition flap for forefoot, 235  
Lepromatous leprosy, 194  
Leprosy bacilli, 194  
Leprosy reaction, 158  
Leprous rhinitis, 274  
Lid loading, 258

Lifestyle changes, 113  
 Liquid paraffin, 361  
 Lisfranc, 162, 171  
 Lisfranc's amputation 250  
 Load (mechanics), 247  
 Local flaps, 250  
 Long term follow-up, 317  
 Lumbricals, 48  
 Lymph nodes, 206  
 Lymphadenopathy, 250  
 Lymphangitis, 195, 201  
 Lymphatic stasis, 195

## M

Malignant ulcer, 249  
 Mallet finger, 54  
 Mallet toe, 190  
 Marjolin's ulcer, 249  
 Martin Gruber anastomosis, 40  
 Masseter transfer, 265-266  
 Mechanical debridement, 213  
 Mechanism of pinch, 65  
 Medial epicondylectomy, 30, 318  
 Medial plantar island flap for heel, 229  
 Medial tarsorrhaphy, 259  
 Medial arch support, 243  
 Medial canthoplasty, 323  
 Medial plantar artery flap, 227, 250  
 Median nerve, 31, 40  
 Median palsy, 308  
 Metacarpal transfer, 118  
 Metacarpophalangeal arthrodesis, 61  
 Metatarsal head resection, 171, 190  
 Metatarsal rocker, 244  
 Methylcellulose drops, 258  
 Micro business skills training, 350  
 Micro-cellular rubber, 219, 239, 349, 337  
 Micro-vascular muscle transplants, 258  
 Mid-wedge tarsal osteotomy, 165  
 Mime-therapy, 313  
 Mitten Hand, 113  
 Mobile clawing, 304, 306  
 Mobility devices, 346  
 Modifying tools, 328  
 Modulan, 123  
 Moleskin, 363  
 Moment arm (tendons), 70, 84, 177, 183  
 Monofilament (testing), 11, 14, 16, 33

Moulded footwear, 161  
 Moving two-point discrimination, 13-15  
 MRC scale, 18, 45  
 Multi-drug therapy, 7, 11, 194  
 Multidisciplinary approach, 327  
 Muscle flaps, 228  
 Muscle testing, 33, 45  
 Muscle excursions, 7, 84  
 Mycetoma, 216  
 Myodesis, 254  
 Myoplastic procedures, 254

## N

Nasal deformity, 273, 277  
 Naso-labial flap reconstruction, 274, 289, 291  
 Nasolabial face lift, 299  
 Neoplasia, 216, 249,  
 Nerve decompression, 318  
 Nerve function assessment, 12, 33, 357  
 Nerve function impairment, 25, 33  
 Nerve pain, 28  
 Nerve abscess, 25, 27, 318  
 Neurolysis, 25  
 Neuroma, 319  
 Neuropathic ulcers, 195  
 Neuropathic foot, 179  
 Neuropathic bone disintegration, 147, 150-151, 159  
 Neuropathy, 11, 12, 147, 158, 196  
 Non-specific ulcers, 193  
 Non-weight bearing examination, 142  
 Nose reconstruction, 271  
 Nutrition, 159

## O

Oblique retinacular ligament, 43  
 Oedema, 207  
 Oil, 34, 361  
 Opponensplasty, 8, 69, 72, 131  
 Opponensplasty (palmaris longus), 72  
 Orthopedic felt, 363  
 Orthoses, 185, 240, 327, 347, 349  
 Orthotics (therapy), 161, 176, 185, 188, 237  
 Osteitis, 218  
 Osteo-ectomies, 162  
 Osteo-syntheses, 119  
 Osteomyelitis, 202, 208  
 Osteopaenia, 152, 158, 159  
 Osteoplastic reconstructions of thumb, 120

Osteoporosis, 158  
Osteotomy, 161, 228, 164  
Outcome assessments, 350  
Overt clawing, 305

## **P**

Padding, 363, 365  
Pain, 34, 147, 205  
Pain perception, 159  
Pain sensation, 11  
Palmaris Longus to Extensor Pollicis Longus 87  
Palmaris Longus transfer, 55  
Palpebroplasty, 260  
Paraesthesia, 28, 147, 318  
Paramedian forehead flap, 291  
Parkes graft tenodesis, 50  
Participation restrictions, 344  
Patella Tendon Bearing (PTB) Prostheses, 335  
Patella Tendon Bearing AFO, 334  
Pedal pulses, 211  
Pedicle graft, 273  
Pes cavus, 241  
Phalangisation of digits, 122  
Phases of rehabilitation, 344  
Physical rehabilitation, 343  
Physiotherapy, 127, 344  
Pin prick test, 12, 15  
Pinch (grip), 41, 48, 65, 86, 114  
Pinch grip testing 14, 19, 33, 45, 305  
Pins and needles, 147  
Pirogoff amputation, 170, 251  
Pirrogoffs procedure, 170  
Pitfalls of opponens surgery, 75  
Plantar intrinsics, 199  
Plantar Metatarsal Pad, 245  
Plantar ulcers (causes of), 198  
Plantar aponeurosis, 143  
Plantar fascia, 227  
Plantar ulcer, 195, 197, 201  
Plantarflexed fifth ray, 139  
Plantaris tendon, 2, 51, 52  
Plastazote, 331  
Plaster of Paris 36  
Plaster of Paris, 211, 366  
Poliomyelitis, 303  
Pollicisation, 119, 130  
Polyethylene, 349  
Poron, 241  
Post nasal epithelial inlay, 275, 283

Post-auricular flap, 299  
Posterior interosseous fasciocutaneous island flap, 120  
Posterior tibial nerve (paralysis), 29, 185, 328  
Posterior tibial artery, 230  
Power grip, 60, 90  
Pre- and postoperative therapy, 179, 303  
Prefabricated feet, 338  
Pressure (mechanics), 141, 205, 239, 247  
Pressure points, 160  
Pressure sores, 227  
Prevention of impairment, 348  
Prevention of ulceration, 205  
Primary impairments, 42  
Primary thumb MCP Flexion, 61  
Profundus plus deformity, 58  
Pronated subtalar joint, 143  
Pronator Teres to Extensor Carpi Radialis Brevis Transfer, 84, 310  
Propulsion, 134, 238  
Prostheses, 253, 327, 335, 347,  
Protective footwear (see also footwear, sandals), 345  
Protective sensation, 11, 34, 36, 327  
Psychiatric morbidity, 317  
Psychological effects, 11, 237, 350  
Ptotic eyelid, 262  
Pulley advancement (Bunnell – Palande), 50  
Pulley, 8, 50, 60, 85  
Pulley advancement, 322  
Pulp-to-pulp pinch, 65-66  
Pulvertaft weave, 6  
Punch grafts, 273

## **Q**

Quality of life, 314, 351

## **R**

Radial nerve (palsy), 40, 83, 310, 323  
Radial artery forearm flap, 120  
Radial deviation (wrist), 322  
Radiographic examination, 155, 213  
Ray Amputation, 250  
Re-education, 309  
Re-Routing Abductor Pollicis Longus, 74  
Reaction (leprosy), 7, 9  
Reactional ulcers, 194  
Reactive forces, 134  
Reconstruction of the nose, 272  
Recurrence of clawing, 319

Recurrent plantar ulcers, 202, 217  
 Redness, 150  
 Reduced pain perception, 161  
 Rehabilitation potential, 346  
 Rehabilitation team, 345  
 Rehydrate (skin), 360  
 Release of contractures, 128  
 Reliability (of test), 13, 15  
 Resin, 331, 363  
 Responsiveness (of test), 15  
 Rest, 36, 160  
 Restoration of key pinch, 59  
 Retroposition (thumb), 66  
 Reversal reaction, 194  
 Reversed metacarpal arch, 55  
 Reversed medial plantar island flap, 235  
 Rib cartilage, 277  
 Rice planting (hair), 294  
 Rigid sole, 237  
 Rocker shoes, 238  
 Rotation skin flaps, 228  
 Rotational forces, 134

## S

SACHS foot, 338  
 Saddle nose, 272  
 Saline, 163, 208  
 Sandal (design), 237, 239, 359  
 Scabies, 3  
 Scar excision, 219  
 Scar, 163, 206, 219, 221, 229, 318  
 Scar tissue, 217, 317  
 Scraping, 361  
 Sebum, 360  
 Secondary defects, 42, 44, 147  
 Self care, 38, 179, 345, 347, 359  
 Self help (groups), 347  
 Semmes-Weinstein monofilament testing, 13, 33  
 Sensitivity (of test), 12, 13  
 Sensory impairment, 19  
 Sensory testing, 33, 45, 358  
 Septic arthritis, 127  
 Septicæmia, 202, 209, 216  
 Sequestrum, 204  
 Serial casting, 127  
 Sesamoid bone, 214  
 Shear force (mechanics), 134, 141, 237, 243, 247  
 Shock absorption, 134  
 Short foot, 170

Silastic slings, 258, 262  
 Silicone rubber, 278  
 Skin care (see also self care), 218, 359  
 Skin grafts, 212, 227, 228, 250  
 Skin scars (see also scars), 300  
 Skin crack, 198  
 Soak Scrape and Oil, 360  
 Soaking, 34, 207, 218, 361  
 Social acceptance, 273, 352  
 Socio-economic interventions, 350  
 socio-economic problems, 345  
 Socket design, 336  
 Spasticity, 180  
 Specificity (of test), 12-13  
 Spina bifida, 158  
 Splints (splinting), 25, 35, 41, 84, 127, 303, 306  
 Squamous cell carcinoma, 202, 249  
 Squatting, 36, 332  
 Stages of ulceration, 200  
 Standing, 133, 197  
 Stasis ulcers, 195  
 Static procedures (clawfinger correction), 49,  
 Static procedures (eye closure), 259  
 Static two-point discrimination, 14-15  
 Steroids, 11, 26, 27, 28, 176  
 Sticking plaster dressing technique, 211  
 Stigma, 48, 327  
 Strain (mechanical), 135  
 Stress (mechanical), 134, 198, 247  
 Stress fracture, 151, 158-159, 161  
 Sub-wedge talar osteotomy, 167  
 Subtalar joint, 133, 141  
 Subtalar pronation 240, 246  
 Superficialis transfer, 68  
 Supinated subtalar joint, 143  
 Surgical debridement, 213  
 Surgical decompression, 26  
 Swan neck (deformity), 49, 54, 68  
 Swelling, 150, 159, 205, 336  
 Syme's amputation, 250, 335  
 Syme's prostheses, 338  
 Synthetic grafting, 278  
 Synthetic prosthesis, 274  
 Syphilis, 273

## T

Tactile gnosis, 45  
 Tarsal cradle, 241  
 Tarsal platform, 241

Tarsal tunnel, 187  
Tarsorrhaphies, 258, 323  
Tearing, 323  
Temperature discrimination test, 17  
Temporalis Muscle Transfer, 262, 313, 323  
Tenderness, 205  
Tendon transfer surgery, 4, 303  
Tendon anastomosis, 175  
Tendon to bone anastomosis, 175  
Tendon to tendon anastomosis, 183  
Tendon to tendon insertions, 175  
Tenodesis, 50, 92, 185  
Tenolysis, 318  
Tenosynovitis, 202  
Tenotomy, 54, 189  
TENS, 37  
Tension (muscle/ graft), 6, 8, 53, 86  
Tension fraction, 7, 59  
Tetanus, 202  
The hinge hand procedure, 92  
Thermal sensation, 14  
Thermoplastics, 331  
Thumb web (contracture), 45, 127, 322  
Tibialis Posterior Transfer, 168, 182, 244, 312  
Toe amputation, 250  
Toe deformity, 187  
Toe island flap, 234  
Toe-filler, 335  
Tool adaptations, 34  
Total Contact Cast, 37, 151, 360, 363  
Total facial palsy, 265, 267  
Touch, 14  
Toxemia, 216  
Translational friction, 237  
Transmetatarsal amputation, 251  
Transposition flaps, 229  
Transverse carpal ligament, 70  
Trauma, 196  
Trial Walking, 164, 167, 372  
Trick movement, 75  
Triple arthrodesis, 162, 168  
Triple nerve palsy, 74, 83  
Trophic ulcer, 196, 197  
Two-point discrimination, 12, 45

## U

Ulcer prevention, 360  
Ulceration (stages of), 200

Ulcers, 193, 196  
Ulnar nerve (palsy), 29, 40, 47, 66, 304, 308  
Ulnar nerve paralysis in the thumb, 59  
Ultrasound, 37, 314  
Unfavorable result, 317  
Upper lid loading, 261

## V

V-Y plasty, 229, 235  
Vaseline, 163, 215  
Velcro, 369  
Vocational assessment, 350  
Voluntary muscle test, 18

## W

Walking, 37, 159, 198, 372  
walking plaster cast, 211, 370  
Walking strains, 219  
Walking-care, 218  
Warm and cold test tubes, 14  
Wax bath, 37  
Weakness, 59  
Web space contracture, 115, 322  
Webplasty, 75, 78  
Weight bearing, 142, 197  
Wheelchair, 37, 344  
Wooden sandal, 237  
Wrist drop, 310  
Wrist arthrodesis, 84, 89  
Wrist cuff, 348

## X

X-ray (see also radiography), 160

## Y

Yoking (tendons), 84

## Z

Z-deformity, 308  
Z-lengthening, 180  
Z-pinch, 322  
Z-plasty, 66, 115  
Z-thumb, 44, 59, 70  
Zancolli's volar MCP capsulodesis, 50  
Zinc oxide adhesive plaster, 211





**RICHARD J. SCHWARZ**, MD, FRCS. He started work in leprosy as the reconstructive surgeon at Anandaban Hospital, Kathmandu, Nepal from 1996-1998. He has worked as the reconstructive surgeon at Green Pastures Hospital and Rehabilitation Center, Pokhara, Nepal since 1998 and as the medical superintendent since 2002.



**J. WIM BRANDSMA**, physiotherapist, PhD. He first joined leprosy work in 1973 in Uganda, Kumi Leprosy Centre. From 1977-1983 and 1986-1989 he was based at the All Africa Leprosy and Rehabilitation Training Centre (ALERT), Addis Ababa, Ethiopia. During 1983-1986 he was a rehabilitation research consultant at the National Hansen's Disease Centre in the USA (Head Dr. Paul Brand). From 1990 until 1998 he was a research associate with the Dutch National Institute for Allied Health (NPI, Amersfoort, Netherlands). From 1998, he has been a rehabilitation consultant in India (Karigiri Leprosy Research and Training Centre, Tamil Nadu) and Nepal, Green Pastures Hospital and Rehabilitation Centre.

---

Over 50 years have now passed since **Dr. Paul Brand** first began performing reconstructive surgery for persons affected with leprosy. During the past decades the medical community has recognised that principles and procedures developed for leprosy patients are applicable to persons affected by neuropathies from other aetiologies. Surgeons in other fields, especially in reconstructive facial surgery and tendon transfer surgery to correct paralytic deformities, have adopted operations developed and refined by surgeons working with leprosy patients.

(from the preface)

The editors felt the need of updating the knowledge, theory and practice of surgical and associated measures available today for the reablement of persons affected by disabilities secondary to peripheral nerve paralysis and tissue destruction due to loss of protective sensation. They have succeeded very well indeed. Most of the authors are young professionals, like general, orthopaedic, and plastic surgeons, podiatrists, and prosthetists.

● **Dr. D. Palande**

This book has been written by professionals with wide experience in their special fields and its wisdom is intended for general application wherever leprosy is still prevalent as part of a general service. This book is offered to those who have to cope with the still active pandemic of leprosy in the whole developing world.

● **Dr. E. Fritschi**

**EKTA BOOKS**, Kathmandu, Nepal

*Surgical Reconstruction & Rehabilitation in Leprosy and other Neuropathies*

ISBN 99933-1-371-8



9 789993 13717