

General Principles of Reconstructive Surgery for Leprosy and Other Peripheral Neuropathies

• R. SCHWARZ

In dealing with patients with peripheral neuropathies one must be careful to consider the whole patient and not focus strictly on the nerve deficit presented to the surgeon. Nerve deficits are often multiple, and the urgency of dealing with these deficits differ. In general it is best to listen to the patient as to what their particular needs and priorities are, and to develop a rehabilitative/surgical program in response to these perceived needs. However, patients occasionally have misguided priorities and may need counselling and advice to convince them of the need for certain interventions. For instance, a patient may wish to have their claw hand corrected first for work purposes or social reasons, whereas the surgeon may advise him/her to correct a concomitant lagophthalmos first to prevent corneal ulceration. Similarly a foot drop may seem less of a problem to the patient than a claw hand, yet the former carries a greater risk to the patient and should receive priority.

The attitude and motivation of the patient is focal to the success of therapy or any surgical intervention. Rehabilitative interventions are rarely curative but rather improve function. However continued misuse of the anaesthetic limb can quickly eliminate any benefit the patient received from the surgery. The patient must therefore first understand the care of neuropathic limbs in order to prevent further disability. During this time the patient's attitude to their disease and bodies can be assessed. The patient who will not carry out the simple daily

checks required of a patient with a neuropathic limb is unlikely to gain long-term benefit from a complicated surgical procedure.

Most patients will be very cooperative with therapy, as it is in their self-interest to do so. However some may be more resistant to intervention, as Enna has described.⁴ Particularly in leprosy there are patients who have had their deformity for long periods of time and have simply adapted to it. For those living in a leprosy settlement even the stigma of the deformity may be gone and with it the patient's motivation for change. Other patients may have excessive fears of the potential adverse effects of surgery, especially if they know a patient who has experienced an adverse result. These patients need to be given a realistic understanding of the risks and benefits of surgery so that they do not deny themselves the chance for rehabilitation on the basis of misunderstanding. Other patients with long-standing neuropathies have developed adaptive habits to circumvent the motor deficit, and it will be more difficult in these patients to get them to consistently use the transfer. An example of this would be the patient with median nerve loss who uses the key pinch to grasp objects, and may from force of habit fail to use a "successful" opponensplasty.

The introduction of multi-drug therapy for leprosy over a decade ago has rendered a prolonged and inadequate treatment into a rapid, reliable and effective cure. Neuritis secondary to reaction is also much more effectively treat-

2 Surgical Reconstruction & Rehabilitation in Leprosy

ed now. As a result the number of patients presenting with disability has decreased considerably over the years.

Great care must be taken when caring for patients with peripheral neuropathies. Insensate limbs are prone to pressure ulceration while in plaster and to tearing or cracking the skin during therapy. After autonomic denervation the skin becomes dry, making patients prone to ulcers and cracks which increase the risk of post-operative infection. Infection can occur without pain and when hidden by dressing or plaster detection can be dangerously delayed. The results of tendon transfer surgery are greatly diminished by adhesions and so all care must be taken to avoid these. Much has been written about appropriate surgical technique, and the reader is referred to any standard surgical textbook for these techniques. A few important points of surgical technique as related to reconstructive surgery will be covered in this chapter, as well as particular considerations in tendon transfer surgery.

Often primary care workers are not aware about reconstructive surgery and do not refer patients with a paralytic deformity to a surgical service, if available. Most university surgical departments have specialists on staff, who could perform most operations needed by leprosy patients. The leprosy program could call on an experienced leprosy surgeon to provide the necessary training of the surgeons willing to help. This will also help in removing the fear for leprosy when leprosy patients are treated in a University Hospital.

ANAESTHESIA

Most patients coming to operation will have significant sensory loss and often smaller procedures can be done with no anaesthetic or only local anaesthesia. All patients will find the operative experience easier with a peri-opera-

tive narcosis, such as Pethidine mixed with Phenergan. Hand procedures will usually require a tourniquet and thus will require anaesthesia of the upper arm. An axillary or brachial block will be sufficient in almost all cases. Mixing Bupivacaine 0.5% with Lignocaine 2% will increase the duration of action while decreasing the toxicity.

For minor procedures in the foot an ankle block will often suffice. Removal of the plantaris tendon can be quite painful and a spinal anaesthetic may be needed. If an anaesthetist is present a short general anaesthetic can be used. For this reason fascia lata is easier to harvest. Lignocaine 0.5% can be used as local anaesthesia for this. Alternatively a lateral femoral cutaneous nerve block with a femoral nerve block can be used. However these are not always successful and if supplemental local is needed there are potential problems with Lignocaine toxicity when the axillary block is added. For larger procedures below the waist spinal anaesthetic is used.

I have found that virtually all procedures on the face can be carried out using local anaesthesia with adrenaline. Planning and marking should be done before the local infiltration to avoid confusion from distortion. Again Bupivacaine should be added for longer procedures or those requiring large volume of anaesthetic.

PREPARATION FOR SURGERY

Foci of Sepsis

The operative area should be free of wounds and cracks for at least one week prior to surgery. These are a potential portal of entry for organisms. As well the limb must be inspected on the table as patients or staff may cause skin trauma in the immediate pre-operative period. Callouses need to be trimmed and examined carefully. Controversy arises when considering

operating in the presence of a wound elsewhere on the body. There is increased risk of wound infection in the presence of distal sepsis, and one also has to consider the risk to other patients when a patient with an ulcer is transferred into the clean surgery ward. The latter risk should be minimal with appropriate dressing technique, and there is considerable mixing of patients regardless of bed location due to social interactions. When considering this issue it is important to distinguish the type of wound present, in essence whether this is a superficial healing ulcer or an infected or deep ulcer. If the latter type is present reconstructive operations should be delayed. If the ulcer is superficial and clean then it is reasonable to put the affected limb in a plaster one or two days prior to surgery and then proceed with surgery.⁵ One has to keep in mind the psychological, financial and relational effects of prolonged hospitalization on the patient and his family. Scabies should be treated and operation deferred until at least one week after the burrows have disappeared.

The Use of the Tourniquet

A tourniquet is helpful for almost all operations on the extremities, including many septic operations. The safest type is the pneumatic tourniquet inflated to about 100 mm Hg above the patient's blood pressure. The following points need to be considered:

- 1) A smooth layer of cotton wool should be applied before applying the cuff.
- 2) The cuff must be applied smoothly to ensure even distribution of pressure. The tourniquet must be rapidly inflated to avoid temporary venous tourniquet effect.
- 3) Gravity exsanguination for 60 seconds is adequate. I do not use an Esmarch bandage as seeing some blood in the vessels as the procedure progresses helps in hemostasis.
- 4) A limit of 90 minutes tourniquet time is advisable. After this point the tourniquet can be deflated and re-inflated ten minutes later if need be.
- 5) It is best to deflate the tourniquet before skin closure to check for hemostasis, although with careful technique one can leave the tourniquet in place until the skin is closed.

Skin Preparation

We use two ten minute soap and water scrubs, on the night before and on the morning of the surgery. The shaving is done the morning of surgery. Povidine is used for pre-operative skin disinfecting.

Skin Incisions

In general skin incisions in the hand should be made in the skin creases. Incisions on the fingers should be longitudinal just dorsal to the mid-lateral line, or along the joint crease on the palmar surface. (Fig. 1-1). Diagonal incisions on the palmar surface are also acceptable, ensuring that a longitudinal palmar incision never crosses a joint line. The interphalangeal joints should be approached with a midline

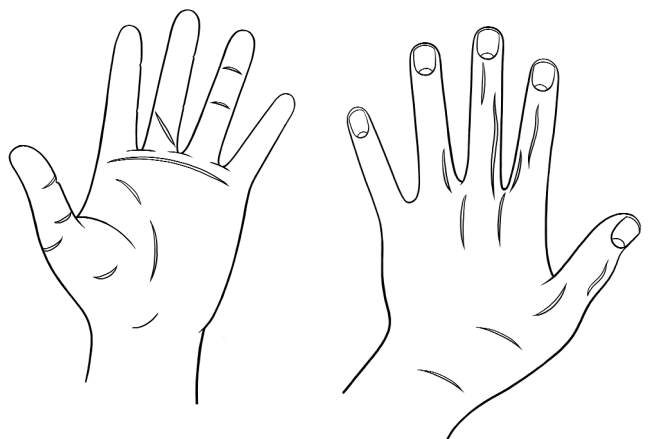


FIGURE 1-1 Palmar and dorsal views of the hand showing acceptable incisions in the hand.

4 Surgical Reconstruction & Rehabilitation in Leprosy

dorsal longitudinal incision. Transverse or oblique incisions will impair the venous drainage with resultant potential loss of the digit. The longitudinal incision does leave one with buckled skin after straightening a joint but this is preferable to losing the finger! When straightening a chronically contracted joint it is imperative that it is not fixed under tension. Tension on the soft tissues can cause spasm of the vessels with ischaemic necrosis of the digit. Therefore following such surgery frequent vascular checks of the digit are necessary.

In the foot, incisions on the weight-bearing surfaces are to be avoided. Surgery on the metatarsal-phalangeal joints should be through a dorsal incision rather than yielding to the temptation to approach through an ulcer on the sole. The dorsal skin often has a poor blood supply and thus all flaps and incisions should have a broad proximal base. Toes, like fingers, should be approached via a mid-lateral or dorsolateral incision, and the joints should be approached via a dorsal longitudinal incision.

TENDON TRANSFERS IN PERIPHERAL NEUROPATHIES

Etiology

The number of diseases for which tendon transfers are an appropriate and effective method of treatment are limited (see Table 1-1). There are a host of other peripheral neuropathies described but the vast majority do not lend themselves to tendon transfers due to their progressive nature. World-wide the most common disease requiring tendon transfer surgery is leprosy, although there are large regional variations in frequency of etiologies. In the West trauma would be the leading etiology. It is important for the physician caring for these patients to recognize conditions which can be benefited by transfer surgery so that

patients with a correctable deformity are referred in a timely fashion.

TABLE 1.1 Etiology of Neuropathies Suitable for Tendon Transfer.

1. Trauma a) Nerve
 b) Nerve root
 c) Incomplete spinal cord
2. Leprosy
3. Charcot- Marie-Tooth Disease
4. Polio
5. Guillain- Barré Syndrome
6. Bell's Palsy
7. Spinal Muscular Atrophy
8. Syringomyelia
9. Congenital Absence of Muscle/Nerve
10. Cerebral palsy

Pre-Operative Preparation

The patient must be properly evaluated and prepared for the planned surgery. Most of this process is covered in the chapter on pre-operative physiotherapy as well as in each individual chapter. It is essential to understand the concepts in this chapter before embarking on any tendon transfer operation. The operation must be done right the first time, as secondary procedures give less than satisfactory results. The presence of deformity does not constitute an indication for surgery. Some patients with long-standing deformity have developed compensatory habits which can give adequate function. Surgical intervention can disrupt this habit and render the hand less functional, even though more cosmetically pleasing, than before surgery. Especially with severely disabled hands thorough discussion with both the patient and therapists is necessary pre-operatively to determine the patient's needs and expectations. The patient must understand what the operation can be expected to accomplish, and also be informed of non-surgical

alternatives such as small prosthetic aids or splints.

Considerations in Tendon Transfer Surgery

Technique

It is of particular importance that trauma to the tendons and surrounding tissues are kept to a minimum. The opening incision should be done firmly, and then deepened in a single plane rather than opening separate planes, which causes more scarring and potential devascularized fat (Fig. 1-2). Scissor dissection should be done with careful snipping using sharp scissors rather than tearing tissues with forced opening of the scissors. Tissues, especially tendons, must be kept moist throughout the procedure. Gloves should be washed of

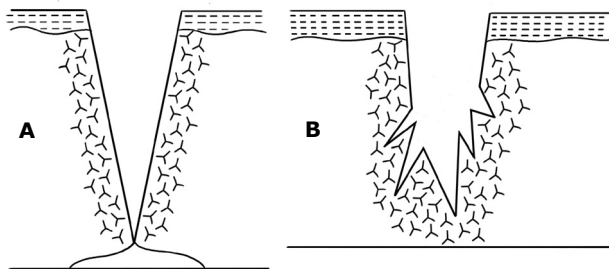


FIGURE 1-2 Technique of making an incision. **A.** Correct **B.** Incorrect

powder prior to commencing the procedure. The time that the tendon is out of the body should be minimized to avoid dessication of the tendon. It should be kept moist while it is exposed. Preparing routes prior to taking out the donor tendon minimizes tendon exposure. To reduce the risk of infection the tendon should not be allowed to touch the patient's skin nor should it be handled with the fingers. Dissection should be minimized and incisions and routes carefully planned before commencing. Tendons should not be tunnelled through scar tissue or under a skin graft. Either a different route must be chosen or a flap done prior to

embarking on a transfer. Skin incisions should be planned so that skin sutures will not be in contact with tendon sutures. Skin closure should be done with monofilament nylon so that they may be left in the full three weeks the limb is in plaster without developing stitch infection. Skin closure should be meticulous with careful approximation and no inversion.

Tunnels must not be made too tight to cause friction on movement, but neither should they be so large as to cause a large healing response with subsequent adhesions. The tendon must be checked for free gliding after it is brought through the tunnel. Tunneling should be done with a fine-jawed tendon passer such as an Anderson tunneller (Fig. 1-3). When tunneling one needs to probe around with the tip to find the path of least resistance. As Brand points

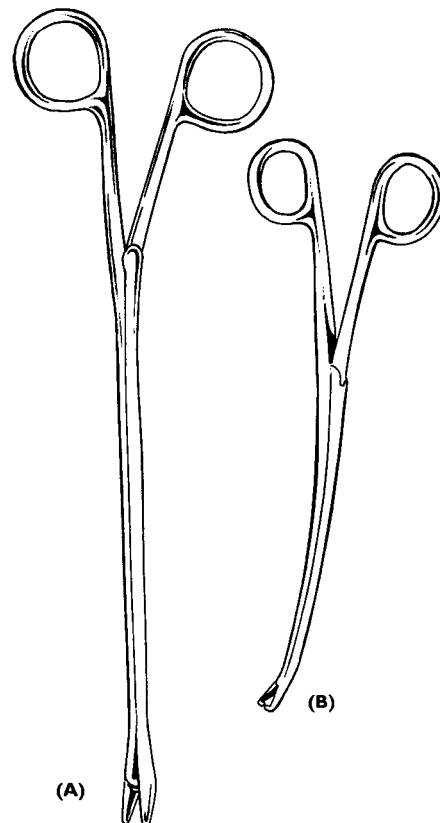


FIGURE 1-3 Anderson tunnellers.

6 Surgical Reconstruction & Rehabilitation in Leprosy

out, forcing a tunneller through a layer of fascia can cause adhesions at that point, and natural tunnels must be used as much as possible. The anastomosis should be done in a way to minimize raw or uneven surfaces, and tendon ends should be buried. A Brand anastomosis (see Fig. 1-4) is an excellent technique of end-to-end tendon anastomosis that buries both ends of tendons and creating a smooth join with a very gradual profile, which will minimize friction. For tendon joins distal to the last moving joint where the anastomosis is not gliding, a Pulvertaft weave is appropriate. It is strong and technically simple, and if free gliding is not required tendon ends do not need to be covered. Transfers should not be left adjacent to bone as the incidence and consequences of adhesions are greater than with fascia or muscle, as adhesions to bone will be immobile. For strength and ease of tying a fine multifilament nylon is used, whereas fine monofilament nylon is used when the suture will be exposed on or near a moving tendon.

It is not advisable to carry out an arthrodesis of a joint close to a tendon transfer at the same time. Either the prolonged immobilization will adversely affect the transfer mobilization, or the early mobilization will harm the bony fusion.

Tension must be set carefully. In many standard procedures, tensions have already been determined and often splints are available to assist in obtaining the correct tension. In each case however the actual result should be assessed visually to ascertain that the tension is correct for the individual patient. The reconstructive surgeon should always be prepared to revise an anastomosis if the tension is not correct. Do not accept a less than ideal result—future revision is much more difficult!

Patient Factors

Any patient who may benefit functionally from

a transfer procedure should be considered for surgery. The patient needs to be motivated to be considered a candidate for tendon transfer surgery. We use the pre-operative physiotherapy period to assess the patient's motivation. Time and patience are required in order to learn the transfer, and the patient must be intelligent enough to be able to isolate the donor muscle. The patient must be willing to take the time required for healing and learning to use the transfer. Occasionally more than two procedures are required and the patient must have the patience and understanding to be able to tolerate this.

Patients as young as age eight to ten are able to understand transfer concepts, and patients younger than this will usually start spontaneously using a transfer once they are free to use the operated limb. A young child should not have necessary surgery deferred due to young age, as the risk of developing secondary deformity is too great. In our experience, older age is not a predictor of poor transfer results.⁶ Therefore advanced age in itself should not be a factor in the decision. There should be no medical or anaesthetic contraindications. The patient should have been off steroids for at least two weeks.

Timing of Transfer

In general the operative area should be infection-free, with good skin condition and free of any wounds for at least one week. In the hand there should be minimal long flexor tightness as well as minimal joint contractures. In late presenting cases it may take many months of physiotherapy and serial casting before the limb is ready for tendon transfer, but attempting transfer before proper preparation would invite failure. In nerve trauma following repair one should in general wait until reasonable hope of recovery of nerve function is lost. If nerve function is regained after a transfer pro-

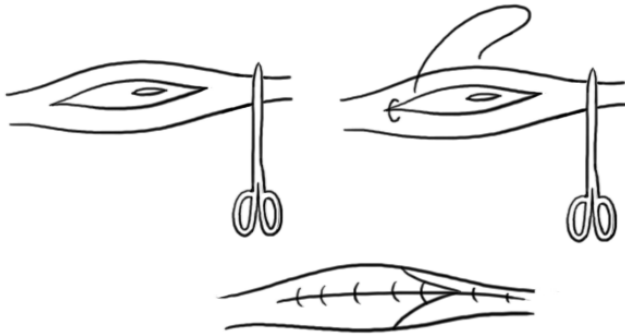


FIGURE 1-4 Brand tendon anastomosis (from Fritsch⁵, used with permission).

cedure is done it will simply not be used, and the donor morbidity incurred will be for naught. Some, including Brand² and Burkhalter³, have advocated early transfer surgery to function as a splint in order to prevent deformity and prevent the patient from learning bad habits. This approach is reasonable in some patients who appear to be developing early deformity or in those in whom the chance of recovery is considered remote, especially if the proposed donor morbidity is minimal (i.e. palmaris longus). However, for the most part a good therapy unit can keep a hand or foot supple and contracture-free with simple exercises while awaiting nerve recovery.

In leprosy the patient should have completed at least six, and preferably the full course of MDT (multi-drug therapy) prior to transfer, as this early period has an increased frequency of reactions with possibility of further nerve damage and loss of function of the donor muscle. Likewise the patient should have been reaction-free for at least six months prior to surgery. This applies particularly to transfers in the hand. It has also been argued that the stress of surgery may precipitate a reaction, although there is no concrete evidence to support this theory. Again one must balance the potential risks of early operation with the risk that the patient may not return in a reasonable time for

the necessary surgery. The nerve palsy should have been present for at least one year to allow the nerve time for potential nerve regeneration.

Choice of Muscle-Tendon Unit

The choice of tendon is predicated initially on what muscles are available. Therefore full voluntary muscle testing must be carried out on the involved limb to determine the full breadth of options. Following transfer the muscle must work at a disadvantage, and as well must contend with adhesions. The strength must therefore be at least 4/5 on the MRC scale, as usually the strength will drop one grade post-transfer. The excursion of a muscle is also important, in that the donor muscle must have equal or greater excursion than the recipient tendon in order to produce a full range of motion of the recipient biomechanical unit. For instance flexor carpi ulnaris is a powerful muscle but its minimal excursion makes it a poor option to use as a transfer to extensor digitorum communis with its greater excursion. The excursion of a muscle is dependent largely on its muscle fibre length, and these are usually recorded as resting fibre length. These excursions can be found in standard charts.² The strength of the donor and recipient as well should roughly match. Muscle strengths have been measured by their tension fraction, which is the percentage of the total power in the limb provided by the given muscle. Examples of standard muscle excursions and strengths are seen in Table 1-2.

Donor morbidity must always be minimized. If the choice is available one must attempt to use the operative procedure with the least trauma to the hand to minimize post-operative hand swelling. The procedure should be easy for the patient to learn. Check to ensure that the patient is able to localize the proposed donor muscle. In general in-phase (i.e. a flexor tendon being used as a flexor) operations are easier to learn than out of phase

8 Surgical Reconstruction & Rehabilitation in Leprosy

TABLE 1-2 Muscle Variables

Muscle	Excursion	Tension Fraction
ECRL	9.3	3.5
ECRB	6.1	4.2
FCR	5.2	4.1
PL	5.0	1.2
EIP	5.5	1.0
EDM	5.9	1.0
FDS(M)	7.0	3.4
FDS(R)	7.3	2.0
Interossei	1.4-2.5	2.8-4.5
Lumbricals	4.9-6.6	0.1-0.2

Numbers from Brand PW. *Clinical Mechanics of the Hand*. CV Mosby, St Louis, 1985.

ones. There are exceptions to this such as the extensor to flexor multi-tailed transfer (EFMT) in which wrist extension actually accentuates the efficiency of MCP joint flexion.

The type of hand must also be taken into consideration. A stiff or large hand will tend to do better with an EFMT whereas a fine mobile hand does well with a "Lasso" procedure, and a hypermobile hand such as is often seen in India may do best with a palmaris many-tailed transfer. The possibilities should be discussed with both the patient and the hand therapist to assist in the decision of which donor would best suit the particular needs of the patient. Obviously the surgeon and therapist's experience is important, as an unfamiliar procedure with good reported results can fare disastrously in inexperienced hands. It is best to become expert with the technique and potential problems of two or three transfers than to attempt all available transfers.

Route

The particular route chosen depends principally on the operation being carried out but also depends on what the operation is intending to accomplish. For example, there is a choice of six routes for a standard FDS opponensplasty.

The particular route chosen will depend on the patient's occupation and his own stated need for the type of grasp required. A labourer might require a wide grip and so a more proximal pulley would be used giving more abduction. However a teacher may require more fine tip-to-tip opposition and so a more distal pulley would be used. The reader should refer to the specific surgical chapter for more detail.

Acute angulation at a pulley is to be avoided as this increases friction and reduces the efficiency of the transfer. If the line of pull is not in a straight line then there should be no more than one pulley, as again the friction may prove too great for function of the pulley.

CONTRAINDICATIONS

These are best described as correctable/ uncorrectable than relative/absolute.

Correctable

1. Sepsis in limb or distant site.
2. Joint or skin contracture.

Uncorrectable

1. Lack of suitable muscle/tendon to transfer.
2. Non-compliant patient.
3. Progressive neuropathy.
4. Inappropriate disease i.e. some spastic conditions.

POST-OPERATIVE CARE

The cast needs to prevent movement and tension of the transfer, but need not be tight enough to effect bony immobilization. The limb is put in a position to take the tension off the transfer in a safe position i.e. in the hand the metacarpal-phalangeal joints at 80° and the inter-phalangeal joints straight. The cast should be well padded especially in the sensory deficient limb. Within the constraints of keeping tension off the transfer the cast should be made as comfortable as possible. Edema predisposes

to adhesions and as such the limb should be elevated for one week post-operatively.

The period of immobilization is variable. For tendon to tendon joins, in the foot where stiffness is less of a problem the cast is removed at 4 weeks. However in the hand where stiffness can adversely affect results mobilization is commenced by three weeks, and often at one week. Joint stiffness is particularly a problem in the elderly. Tendon to bone joins require immobilization for 6 to 8 weeks. Protection of the transfer against sudden strain during sleep or at-risk activities is required for 3 months after the operation.⁷

TRANSFER FAILURE TO FUNCTION

A transfer may fail to function adequately for several reasons as follows:

1. Incorrect tension. It is unusual to have a transfer sutured under too much tension. The more usual situation is inadequate tension. If this is the case one should wait at least three months before re-operation.
2. Slipped Suture. This is usually due to post-operative infection where the suture is rejected and extrudes from the wound some weeks after the procedure. It can also happen if the mobilization is too vigorous. In this situation the tendon cannot be felt and no movement of the transfer is seen.
3. Adhesions. Adhesions can develop after any tendon transfer. The best policy is avoidance by good surgical technique, appropriate routing and early mobilization. When established, early 'aggressive' therapy is needed to prevent this from becoming permanent.
4. Lack of patient understanding. Again, the solution is more therapy- with understanding.
5. Reaction following operation. This is unusual but possible. This can be detected by voluntary muscle testing and sensory testing. If the transferred muscle/ tendon has become paralyzed, a second tendon could be transferred, but only after a period of a year.

REFERENCES

1. Brand PW: described in Fritchi, EP: Surgical Reconstruction and Rehabilitation in Leprosy. The Leprosy Mission, New Delhi, 1984
2. Brand PW, Hollister A: Clinical Mechanics of the Hand, 3rd ed. CV Mosby, St. Louis, 1999
3. Burkhalter WE: Early tendon transfer in upper extremity peripheral nerve injury. Clin Orthop 104:68-79, 1974
4. Enna CD: Preoperative Evaluation. pp. 16-30. In Enna CD, McDowell F (eds): Surgical Rehabilitation in Leprosy. The Williams and Wilkins Company, Baltimore, 1974
5. Fritchi, EP: Surgical Reconstruction and Rehabilitation in Leprosy. The Leprosy Mission, New Delhi, 1984
6. Schwarz RJ: Results of opponensplasty. J Hand Surg (in press)
7. Warren G: Tendon Transfers. pp. 215-222. In Conally WB (ed): Atlas of Hand Surgery. Churchill Livingstone, 1997