

Surgical Management of Neuritis

• B. RICHARD

INTRODUCTION

Impairment of peripheral nerve function may lead to the loss of autonomic, sensory and motor functions. In the upper extremity this may lead to dry, insensate skin on fingers that can no longer grasp and manipulate objects with precision and power control. The inappropriate use of the unbalanced hand or foot, and its inability to protect itself from the strains of daily stress, can lead to skin breakdown, infection and the more serious sequelae of neglected painless sepsis. While it is reasonable to say that the patient with leprosy can be cured of his bacteriological infection, we are less able to deal with the problem of nerve damage. Neuritis is a state of inflammation within a peripheral nerve that may lead to impaired function. There are a number of modalities to manage this problem. These can be divided into medical and surgical interventions and are attempts to reverse the pathology or mitigate its effects. Medical treatment mainly involves the use of anti-inflammatory drugs (e.g. steroids) and splints (rest) to encourage nerve recovery. Health education is also invaluable in preventing disability by promoting understanding of the aetiology of tissue damage. Occupational therapy and assistive devices can be employed to enhance function and prevent or reduce deterioration when established nerve damage is present. Surgery is of benefit in alleviating nerve pain in those with chronic painful irreversible nerve impairment. Draining a compressive sterile nerve abscess and motor reactivation of hand, foot and facial palsies, by tendon transfer, are all valuable interventions. Surgery, while heralded as a

method of reversing nerve impairment by decompressive neurolysis operations, is actually of unproven benefit and in urgent need of a controlled clinical trial to test its true usefulness.

The primary task of the leprologist is to cause no harm and if possible to alleviate nerve damage. This responsibility is most easily carried out by first assessing the extent and reversibility of the nerve damage. Those with a new nerve impairment (less than 3 months) and those with a recent nerve impairment (less than 12 months) may benefit from a course of steroids. Nerve function impairment must not be considered irreversible until the deficit has been present for at least three years. Irreversible means that the motor end plates and sensory organs are biologically present but completely non-functional because of atrophy and are no longer capable of recovery in the presence of a new or recovered nerve axon reaching the end plate or sense organ. Whilst no studies exist in support of this recommendation, and some surgeon would consider eighteen months of no recovery to be irreversible, I believe we should not consider a period less than 3 years or patients may be submitted to unnecessary treatments. This is especially true of the very long peripheral nerves like the lateral popliteal which often show improved function some years after a complete foot drop.

In many of its chapters, this book deals with the use of surgical motor reactivation for established palsy. This chapter will first address the issues of surgical intervention that attempt to reverse nerve function loss. Indications and

techniques for nerve surgery will then be discussed.

LITERATURE REVIEW

In the 1970's there were several publications on neurolysis of peripheral nerves that reported improvement in nerve function. Antia stated in 1974 that "... careful and complete release of the thickened nerve may not only relieve the pain, but may also result in recovery of sensory and motor function".¹ Twenty years later Antia says, "Traditional surgical decompression of the posterior tibial nerve yields equivocal results".² Why after twenty years do we still not know whether surgical decompression of the leprosy nerve is beneficial?

The answer lies in a review of the neurolysis papers. In most of these studies the patients were poorly selected with acute new cases mixed with longstanding nerve impairment cases. More importantly, there were no control groups.^{6-10,16,17,19,20}

Neurolysis means different things to different surgeons and this has made comparison of results of limited value. Neurolysis can mean, a simple surgical decompression at the sites of predilection (for example dividing the flexor retinaculum at the wrist); an epineurotomy, which can be longitudinal or meshed, deroofing or excisional; interfascicular neurolysis with microsurgical instruments; or simple nerve rerouting, such as an anterior transposition of the ulnar nerve. Neurolysis has been performed by few surgeons and has not gained universal acceptance. That patients who have a surgical decompression do improve is not in doubt. The question is whether they improve more than if they had received only medical therapy. There is a study purporting to demonstrate that decompression used in conjunction with steroids is better than decompression alone.²¹ However, in this study patients with

an acute painful neuritis received steroids in addition to the surgical decompression, while the decompression alone was for patients with established sensory loss. The first group fared better than the second. It is not surprising that the patients with more recent loss had better results. In a comparative study, Dandapat has shown a benefit with perineural steroid injections given at the same time as a neurolysis.¹¹ Group A received surgical decompression and epineurotomy while group B, in addition to surgery, received an injection of long acting steroid placed around the nerve after completion of the neurolysis. In Group A, 57.1% showed an improvement in the nerve evaluation test score, whilst in Group B, 83.3% of patients had improved. This demonstrates only that steroid injection improves the results of ulnar nerve decompression.

One study compared oral steroids against surgery and oral steroids.¹⁸ Patients were randomly allocated to the medical or surgical group. Surgery consisted of a medial epicondylectomy and decompression of the nerves. The results showed a statistically significant improvement in both groups as assessed by improvement in motor and sensory functions and reduction of pain and tenderness. The study did not demonstrate any added benefit from the surgery as compared to steroid therapy alone. Clearly decompression surgery has no present or substantial evidence base for its claimed advantage of nerve function improvement.

There are other reasons why neurolysis has not been more widely practiced. Firstly, with the development of steroid therapy to control reactional episodes, there appears to be an effective 'medical decompression' of nerves often with subsequent nerve recovery. Many patients presenting with a nerve function loss of less than three months duration will gain a complete or good recovery with steroid therapy. This has certainly taken the pressure off any

need to find a surgical method of improving nerve function, especially when many leprosy control programs do not have a competent reconstructive surgical arm to their program.

Just how steroids work in patients with recent nerve impairment is not known. Whether it is a reduction of oedema in the swollen nerve effecting a 'medical decompression', and/or the steroids mitigate the immune reaction more systemically, is not known. Steroids have not been tested in a blind controlled trial for their efficacy in controlling and reversing recent nerve impairment. It would be unethical to carry out such a study now.

For the present, in most centres, steroids have replaced surgical decompression in the treatment of recent nerve impairment, and surgery is reserved for nerve abscess and unresponsive nerve pain.^{3,14}

However, despite the success of chemotherapy there is a group of patients who fail to respond and are left with a social and functional disability. This has given impetus to explore new avenues in the search for motor and sensory recovery in the hand.

SURGICAL OPTIONS AND THE FUTURE

The scientific rationale for surgery in promoting motor and/or sensory recovery is to decompress the nerve at the sites of mechanical compression. This could be supplemented with an epineurotomy or interfascicular neurolysis in order to permit the regenerating nerve to pass through the 'compressive' area and reach its end organs. For this to be effective the surgery needs to be performed before the skin's sense organs or skeletal muscle fibres have irreversibly atrophied. This probably means the patient should have a nerve impairment of less than three years, although many surgeons would use a rule of less than one year. Alternatively, if the understanding is that the

nerve is irreversibly damaged at the site of 'compression', then jumping the lesion with a muscle graft or other nerve conduit is a surgical possibility (Pereira). Again this must be done before the sense organs have atrophied. However, any patient receiving any of these types of operations within the desired three year period could just as well have made a nerve recovery spontaneously. So it behooves those who do these operations to demonstrate not only that they are successful, but that they are more successful than if the operation had not been done. The International Federation of Anti-Leprosy Associations (ILEP) has reviewed the history of neurolysis and made a plea for controlled, multicentre, trials to test the hypothesis that surgical decompression has a benefit over steroids alone.⁵ Others have made similar pleas.^{4, 21,22,23}

INDICATIONS FOR SURGERY

Nerve abscess

The presence of a fluctuant swelling on or within a fusiform swollen peripheral nerve suggests a nerve abscess.³ Often the patient is classified towards the tuberculoid end of the spectrum, and usually the nerve has some residual nerve function. The differential diagnosis is reaction neuritis with oedema of the nerve, which will be soft and tender. The fusiform swelling may also represent a chronic fibrosis, which will be hard, non-tender and more symmetrically swollen. The patient may recently have had an episode of reaction. The first line of management must be directed towards control of the disease process with a course of steroids and splinting if the nerve is painful. The diagnosis of an abscess can be confirmed by ultrasound, when available, and by needle aspiration of purulent material, which proves sterile for bacteria on microbiological culture. The pathology of the condition is necrosis of one or more fascicles within the

28 Surgical Reconstruction & Rehabilitation in Leprosy

nerve with pus production and a capsule formation. This may be within the swollen peripheral nerve or it may herniate like a pedunculated cyst. The swelling will be fluctuant and mobile transversally but not longitudinally. It is important that the surgeon does not make the nerve function worse by surgery, nor create a chronic wound sinus. It may be possible, under local anesthetic to simply aspirate the nerve abscess with a large bore needle, and wait for nerve function to improve. A chronic, or recurrent abscess can be surgically exposed under regional or general anaesthesia, the abscess cavity opened and drained and very carefully cleaned of its pseudocapsule wall, without avulsing nerve fascicles. The wound is then closed with separate fascial layers to reduce the chance of a chronic wound sinus. Under no circumstances should the abscess be surgically excised as this might slice through nerve fascicles that might otherwise have recovered.

Nerve Pain

Patients with established irreversible nerve impairment occasionally suffer from persistent nerve pain many months or years after completing chemotherapy. Examination of these peripheral nerves will demonstrate firm hard fusiformly swollen nerves. Shooting pains and paraesthesia can be elicited by tapping the nerve trunks at the sites of predilection and often more proximally as well (Tinel-Hoffman sign). In these patients the distal nerve and its sensory organs or muscle end plates are not functioning, but the peripheral nerves are full of thousands of proximal regenerating nerve fascicles trapped in a fibrotic mass. There is no strategy at present to provide viable endpoints for these regenerating nerve axons which cause the nerve pain. While there has been no randomized controlled trial to demonstrate the efficacy of neurolysis for such patients there is much anecdotal evidence to suggest that

releasing the proximal compression in these patients reduces their pain. An oral course of Gabapentin or Cabamazipine should first be tried for several weeks, as this may suffice. Surgery to relieve pain is designed to release compressive forces on the swollen peripheral nerve. This is only after all the acute or acute on chronic loss of nerve function has been adequately dealt with by courses of steroids and splintage. Patients with persistent pain may have fibrotic scars causing compression. These can be external to the nerve at the sites of predilection, and worsened by osseo-ligamentous tunnels, or intraneural fibrosis. In these instances, nerve decompression will often reduce the pain. Procedures include any of the techniques of decompressing the anatomical area in which the nerve lies, deroofting the epineurium, or inter/intra fascicular neurolysis.

Lack of improvement of nerve impairment with steroid therapy

While more controversial (see above), many surgeons strongly advocate surgical nerve decompression for patients who fail to respond to steroid therapy. For this to be effective it should be done early (less than three months), which of course will obscure the possible effect of the steroids, emphasizing again the need for a randomized controlled trial.

SURGICAL TECHNIQUES

Once it has been agreed that some form of surgical decompression of the leprosy involved nerve is needed, mechanical decompression of the fibro-osseous tunnel and release of the intermuscular membrane at the site of predilection can be considered to be the minimum level of intervention. The next issue to consider is the type and extent of an epineurotomy and interfascicular neurolysis. In considering the

choice, the surgeons experience of intra-neural surgery, and availability of micro instruments and magnification should be taken into account. How far to extend the neurolysis proximal and distal to the site of predilection is also not determined. Turkof and Richard have demonstrated a reduction in electrophysiological nerve conduction considerably more proximal than the macroscopically obviously involved section of an involved nerve.^{23,26,27} Therefore any neurolysis required at the site of nerve compression might need to be extended, at least by an epineurotomy, into the more proximal nerve trunk. Whether this is an absolute or relative indication is not known at present.

Neurolysis, as a technique, demands micro-instruments and magnification in order to safely operate on, and in a nerve. The interested reader should consult Salafia and Chauhan's book on Treatment of Neuritis in Leprosy.²⁴ However, it is my opinion that such techniques need to be validated by randomised controlled trials to assess their usefulness, rather than offering the technique to occasional patients.

Posterior Tibial Nerve

Release

Using appropriate anaesthesia, either general, regional or local, and after limb exsanguination by elevation and application of a tourniquet on the thigh, the medial aspect of the ankle is prepared for surgery. An incision behind the medial malleolus, approximately 6-8 cm long, will expose the flexor retinaculum (Fig. 3-1). When the whole extent of the retinaculum is visible it can be incised by sharp dissection to expose the underlying posterior tibial vessels and nerve. It may be necessary to release the neurovascular bundle more proximally into the calf and under the medial gastrocnemius. There is no evidence that a more proximal or distal neuro-

lysis will improve the result of the decompression.¹⁶

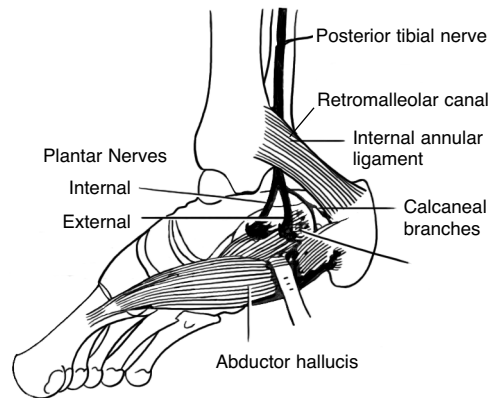


FIGURE 3-1 Anatomy of posterior tibial nerve at ankle. (Modified from Carayon A, *Surgical Rehabilitation in Leprosy*, Williams and Wilkins, 1974).

Ulnar nerve at the elbow

Using appropriate anaesthesia and following limb exsanguination by elevation and application of a tourniquet as proximal as possible on the upper arm, the elbow is prepared for surgery with the shoulder abducted and fully externally rotated and the arm on a side table.

Options for surgery on the ulnar nerve are varied. Traditionally the operation of choice was an anterior transposition of the nerve. A simple nerve release and epineurotomy are advocated by some.¹³ A medial epicondylectomy is preferred by some as it does not interfere with the blood supply and patients regain use of the limb faster.

Simple Decompression

Simple decompression involves an 8 cm incision, a little anterior to the skin markings of the nerve, to expose the medial epicondyle and the medial intermuscular septum. The fascia that overlies the nerve is divided and the dissection is extended to release the crescentic free margin of the flexor carpi ulnaris beneath which the

nerve disappears (Fig. 3-2). The proximal medial intermuscular septum is released as it may be compressing the swollen nerve. An epineurotomy is then carefully carried out along its exposed length. Devascularising the nerve is avoided by dissecting its deep aspects. There is evidence in non-leprosy ulnar nerve surgery that a simple epineurotomy, with or without a medial epicondylectomy, gives similar results to an anterior transposition. It also has the advantage of not interfering with the blood

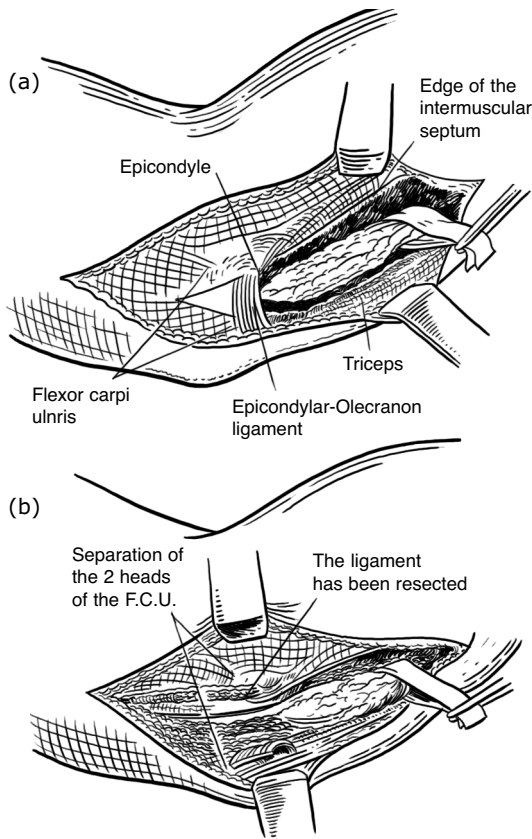


FIGURE 3-2 Simple unroofing of ulnar nerve at elbow. **A.** Following exposure **B.** Following unroofing. (Modified from Carayon A, *Surgical Rehabilitation in Leprosy*, Williams and Wilkins, 1974).

supply of the ulnar nerve.^{12,13,15}

Medial Epicondylectomy

Patients with a large fusiform nerve that on elbow flexion dislocates out of the ulnar groove

between the medial epicondyle and the olecranon may benefit from an additional medial epicondylectomy or anterior transposition of the ulnar nerve. Once the ulnar nerve is seen and retracted posteriorly the medial epicondyle is exposed by sharp subperiosteal dissection and reflection of the common flexor origin. The ulnar nerve, with its blood supply and fascial bed, are visualised in order to protect these tissues during the osteotomy. One then proceeds to remove, obliquely, the medial epicondyle and a portion of the supracondylar ridge (Fig. 3-3). An osteotome or rongeurs suffice to

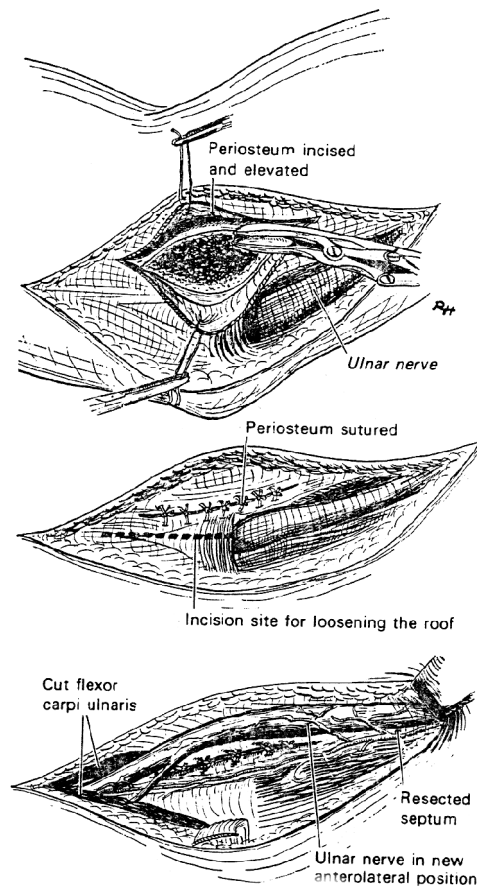


FIGURE 3-3 Medial epicondylectomy. **A.** Removal of medial epicondyle after raising periosteal flap. **B.** Periosteum closed to minimize adhesions, fibrous arch divided and two heads of flexor carpi ulnaris separated. The ulnar nerve is then translocated anteriorly. (Modified from Carayon A, *Surgical Rehabilitation in Leprosy*, Williams and Wilkins, 1974)

remove the bone. The periosteum is closed over the filed bone edges and with the nerve retracted anteriorly, the common flexor origin is sutured to its new bone origin. The collateral elbow ligaments are left intact in this dissection. The wound is closed and a bulky soft dressing applied for 10 days. Decompression of the ulnar nerve at the wrist (Guyon's canal) alone may not be beneficial when in most cases the nerve may be more severely damaged proximally in leprosy affected persons.

Median Nerve

Release

Following appropriate anaesthesia and application of a tourniquet, the whole upper limb is prepared allowing access to the wrist, the forearm and cubital fossa. This is because the median nerve needs to be decompressed at the wrist and sometimes at the pronator teres arch as well. A longitudinal anterior wrist incision that extends 4 cm proximal and 3 cm distal to the wrist crease, and lies to the ulnar side of the palmaris longus, will allow adequate direct vision of the carpal tunnel ligament and minimise surgical damage to any aberrant motor branch of the thenar muscles when dividing the ligament with a scalpel. Whilst the mechanical cause of the compression is the carpal tunnel itself the nerve is often grossly swollen proximal to the carpal tunnel. As with other decompression surgery, if the epineurium looks thickened, tight or pale in colour then a longitudinal epineurotomy can be performed and extended proximally into the forearm if necessary. When a positive pronator arch impingement provocation test is present (Tinel sign in the cubital fossa, pain on pronation of the flexed forearm against resistance, or pain on resisted flexion of the middle and ring fingers) then a cubital fossa exploration for a possible second median nerve granuloma should be performed. A second curved incision is made over the proximal volar forearm across the cubital fossa and up the medial side of the

distal upper arm after dividing the lacertus fibrosus. This exposes the pronator teres arch and the fibrous origin for the deep head of the flexor digitorum superficialis. Release of these tight structures might expose a second fusiform swelling in the median nerve deep in the cubital fossa.²⁷ An epineurotomy may also be appropriate.

Other Surgery

Decompression of the Facial nerve has been described.²⁸ However, there is inadequate evidence to recommend it as a treatment option at present. Similarly, anyone contemplating decompression of the Common Peroneal nerve should only do so as part of a Randomised Controlled Trial. They should consider continuing the neurolysis into the thigh as far as the bifurcation of the sciatic nerve.²³

CONCLUSION

While surgical release of compressed nerves is associated with nerve recovery in many cases, a randomized controlled trial is necessary to prove that surgery with steroids is better than steroids alone. For those with neuritis pain or nerve impairment not responding to steroids, nerve decompression may be indicated. Complete release avoiding devascularization of the nerve may lead to safe and good results in competent hands.

REFERENCES

1. Antia NH: The significance of nerve involvement in leprosy. *J Plast Reconst Surg* 54:55, 1974
2. Arolkar SK, Antia NH: Vascular surgery of the posterior tibial compartment for plantar ulceration in leprosy. *Lepr Rev* 66:48-54, 1995
3. Bhagat KP, Wange HM, Tekani BU: Management of nerve abscesses in leprosy. *Ind J Derm Ven Lepr* 46:110-112, 1980
4. Bourrel P: Surgical Rehabilitation. *Lepr Rev* 62:241-254, 1991

32 Surgical Reconstruction & Rehabilitation in Leprosy

5. Bourrel P: Preliminary recommendations on the uses of surgery for the treatment of leprosy neuritis. ILEP Medical Bulletin No. 4, 1-3, 1992
6. Brandsma JW, Nugteren WAH, Andersen JB, Naafs B: Functional changes of the ulnar nerve in leprosy patients following neurolysis. *Lepr Rev* 54:31-38, 1983
7. Carayon A: Surgical decompression of leprosy neuritis. Objectives, techniques, indications and results. *Chirurgie* 110:225-234, 1984
8. Carayon A: Surgical decompression of leprosy neuritis: Anatomic-clinical and physiopathological bases. *Chirurgie* 110:219-224, 1984
9. Chaise F, Bourrel P: Les resultats eloignes de la decompression chirurgicale du nerf tibial posterieur dans les neuropathies de la maladie de Hansen. *J Chir (Paris)* 124:315-318, 1987
10. Chaise F, Roger B: Neurolysis of the common peroneal nerve in leprosy. *J Bone Joint Surg* 426-429, 1985
11. Dandapat DD, Sahu DM, Mukherjee LM, Panda C, Baliarsing AS: Treatment of leprosy neuritis by neurolysis combined with perineural corticosteroid injection. *Lepr Rev* 62:27-34, 1991
12. Froimson AL, Zahrawi F: Treatment of compression neuropathy of the ulnar nerve at the elbow by epicondylectomy and neurolysis. *J Hand Surg* 5:391-395, 1980
13. Guegan Y, Pinel JF, Javaudin Y: Neurolysis of the ulnar nerve at the elbow: Report on 20 cases. *Neurosurgery* 28:127-129, 1982
14. Nores JM, Redondo A, Vernerey C, Gentilini M: Surgical treatment of leprosy neuritis. Results of 114 operations. *Presse Médicale* 17:1756-1759, 1988
15. Oommen PK: Ulnar nerve decompression by medial epicondylectomy of the humerus and a method of assessing muscle power status by totaling the muscle grading. *Lepr India* 51:336-340, 1979
16. Palande DD, Azhaguraj M: Surgical decompression of posterior tibial neurovascular complex in treatment of certain chronic plantar ulcers and posterior tibial neuritis in leprosy. *Int J Lepr* 43:36-40, 1975
17. Pandya NJ: Surgical decompression of nerves in leprosy. An attempt at prevention of deformities. A clinical, electrophysiological, histopathological and surgical study. *Int J Lepr* 46:47-55, 1978
18. Pannikar VK, Ramprasad S, Reddy NR, Andrews P, Ravi K, Fritschi EP: Effect of epicondylectomy in early ulnar neuritis treated with steroids. *Int J Lepr* 52:501-505, 1984
19. Ramarorazana S, Rene JP, Schwartzl E, Randrianomenjanahary J: Résultats à un de 466 décompressions nerveuses réalisées chez 123 lepreux en cours de polychimiotherapie à Madagascar. *Med Trop* 55:146-150, 1995
20. Rao KS, Balakrishnan S, Oommen PK, Swamy MKS, Durai V: Restoration of plantar sweat secretion in the feet of leprosy patients. *Ind J Lepr* 59:442-449, 1987
21. Rao KS, Swamy MKS: Sensory recovery in the plantar aspect of the foot after surgical decompression of posterior tibial nerve: Possible role of steroids along with decompression. *Lepr Rev* 60:283-287, 1989
22. Richard BM. Sensory Re-ablement of the hand in leprosy : The next surgical frontier. *Ind J lepr* 69:109-117, 1997
23. Richard B, Khatri B, Knolle E, Lucas S and Turkof E: Leprosy affects the tibial nerves diffusely from the middle of the thigh to the sole of the foot, including skip lesions. *Plast Reconstr Surg* 107:1717-1724, 2001
24. Salafia A, and Chauhan G: *Treatment of Neuritis in Lepr osy*. A Salafia, Mumbai, 1997
25. Shah A: Evaluation of nerve function deficit. Its improvement by nerve decompression or corticosteroid therapy. *Ind J Lepr* 58:216-224, 1986
26. Turkof E, Tambwekar S, Mansukhani K, Millesi H, Mayr N: Intraoperative spinal root stimulation to detect most proximal site of leprosy ulnar neuritis. *Lancet* 343:1604-1605, 1994
27. Turkof E, Tambwekar S, Mansukhani K, Millesi H, Mayr N: Intraoperative electroneurodiagnostics to detect a second granuloma in the cubital area of the median nerves affected by leprosy: a new approach to prevent incomplete surgery. *Int J Lepr* 63:409-416, 1995
28. Turkof E, Richard B, Assadian O, Khatri B, Knolle E, Lucas S : Leprosy affects facial nerves in a scattered distribution from the main trunk to all peripheral branches and neurolysis improves muscle function of the face. *Am J Trop Med Hyg* 68:81-88, 2003

Other Reading

Ebenezer M, Andrews P, Solomon S: Comparative trial of steroids and surgical intervention in the management of ulnar neuritis. *Int J Lep* 64:282-286, 1996

Pereira, JH, Bowden, REM, Narayanakumar, TS and Gschmeissner, SE: Peripheral nerve reconstruction using denatured muscle autografts for restoring protective sensation in hands and feet of leprosy patients. *Ind J Lepr* 68, 83-91, 1996

Pereira, JH, Palande, DD, Subramanian, A, Narayanakumar, TS, Curtis J, and Turk, JL: Denatured autologous muscle grafts in leprosy. *Lancet* 338, 1239-1240, 1991