

## Use of External Fixators in the Neuropathic Hand

• A. SALAFIA  
G. CHAUHAN

### INTRODUCTION

Deformities of hands and feet in leprosy pose a challenge to the surgeon as they are, usually, compounded by loss of sensation. The problem becomes complex when stiffness of small joints is present, especially. The proximal interphalangeal joints (PIP) which are often fixed in flexion contracture.

Thumbweb contractures are also quite common, while wrist joint stiffness and distal interphalangeal joints (DIP) flexion contractures are less common. Metacarpo-phalangeal (MP) joint stiffness is unusual. This chapter will discuss indications and techniques of surgical release of contracted joints/tissues.

### Aetiology of Joint Stiffness

The causes of stiffness are:

- 1) Disuse and / or lack of exercises following multiple nerve damage;
- 2) Trauma and
- 3) Septic arthritis.

Flexion deformities of PIP joints in leprosy are the result of:

1. Skin contractures, as sequelae of trauma, burns or long-standing flexion as in cases of neglected claw fingers deformity.<sup>1,2</sup>
2. Shortened tendons and muscles, both intrinsic and extrinsic, due to long-standing paralysis, trauma and infection.
3. Adhesions of the long flexors to their sheaths.<sup>3</sup>
4. Contracture of the volar capsule and retraction of the collateral ligaments,

which may occur in long-standing claw deformity.

5. Bony deformities, traumatic or exostotic, or ankylosis following septic arthritis.

We like to use a working classification of all forms of flexion deformities caused by soft tissue contracture. A *mild degree* of deformity is one in which the joint(s) can not be moved actively, but there is full passive range of motion. *Moderate*: a joint cannot be put through a full range of motion. *Severe*: the degree of movement is very limited and it is easy to mistake, clinically, this degree of contracture with joint fusion. In such cases radiography is necessary to clear the issue.

### MANAGEMENT

1. Assessment of the deformity both clinical and radiological.
2. Intervention: operative or non-operative.

Non operative management entails techniques such as splints, serial casting, and physiotherapy. None of the non-operative methods will be sufficient in most of the moderate and all the severe forms of contracture.

### Operative Methods

There are a number of conventional methods used for correction of moderate and severe degrees of PIP contractures; the choice of technique depends upon the causes of contracture, the patient's expectation and financial capabilities, and the surgeon's expertise.

The following techniques are available:

- 1) Release of contracture and free skin grafting using a full-thickness graft, known as Wolfe graft.<sup>12</sup>
- 2) Release of contracture and wound closure using local flaps (i.e. cross finger or flag flap, Z-plasty) in cases of PIP joint contractures<sup>6</sup>, while wrist and MP contracture, may, at times, require vascularised grafts (cutaneous, fascio-cutaneous).<sup>5</sup>
- 3) Release of contractures by resection of collateral ligaments, also known as capsulectomy of Curtis.<sup>4</sup>
- 4) Joint replacement.

All these surgical methods have some disadvantages.

### **Free skin grafting**

Though a relatively easy surgical procedure, this is not of great help in many cases. In moderate and severe contractures, the neurovascular bundle is also shortened so that an attempt at fully extending the finger in one stage would risk finger necrosis. To be effective, this procedure may have to be repeated at least twice and the finger extended gradually over a period of months. Moreover while attempting to extend the joint, the tendons may be exposed: A skin graft over a tendon does not take and even if it does, it would limit the movement of the finger.<sup>2</sup>

### **Local Flaps**

Only those who have a good training in hand surgery should do these procedures. In leprosy, a cross-finger flap appears to be the best choice in cases of PIP joint contracture, while a vascularised flap would require training in microsurgery and the necessary equipment to perform it.<sup>6</sup> However, a flap does have some of the disadvantages of a free skin graft. It does not

take care of the collateral ligaments and the volar plate, which are powerful contracting forces, so much so that one more surgery would be required to release these. Even by such combined surgery, full extension of the fingers is possible and advisable only if the dorsal skin is healthy and has a good venous drainage. Further, while a flag-flap is possible in theory for all fingers, cross-finger flaps cannot be done for all the fingers of the same hand.

### **Capsulectomy**

A capsulectomy can solve the problem of capsular contracture, but it is not an easy procedure, and alone is seldom sufficient to achieve full extension.

### **External Fixators and Distractors**

External fixators have been used for years in cases of fractures and arthrodesis as an alternative to intramedullary K-wires and Plaster of Paris (POP). Distractors along with external fixators are used in a variety of conditions: fractures and arthrodesis, tissue expansion, congenital deformities (ulnar and radial deviation, Epidermolysis Bullosa Dystrophica) (BB Joshi-personal communication) and for lengthening or shortening of bones.

External fixators have been used especially in America since the late 1800's. This design was modified by Mantero (Italy) in 1976.<sup>9</sup> In 1991 Joshi introduced the external fixators and distractors called JESS (Joshi External Stabilizing System).<sup>7</sup> Various modifications followed the first set of JESS.<sup>8</sup>

### **Types of JESS**

- a) The single JESS is composed of a rod, a static block and a distracting one. The earlier version had a nut at the end of the static block that, when in place, may touch the skin of the finger's web leading to necrosis; the later version, made of polycarbonate, eliminates this problem to a certain extent.

- b) The axial JESS has a few versions. The one commonly used by us is the uni-axial version. This can be used in the correction of a variety of conditions.

#### Advantages of JESS

1. All soft tissues, including volar capsule, can be gradually lengthened over a period of time. The vessels are also lengthened gradually so that the chances of vascular damage are minimized.
2. Skin grafts and flaps leave scars on the volar aspect of the fingers. This is a great disadvantage in the anesthetic hand because this may make the hand more prone to further damage. Any additional surgery of tendons could be compromised by the scars. K-wires, used along with JESS, leave tiny negligible scars on the lateral aspect of the fingers, which do not cause any problem surgically or otherwise.
3. The rate and amount of release is controlled.
4. It is an easy procedure and surgeons can perform it with minimal training.
5. Compared to capsulectomy and skin flaps, it is much easier to perform, and in one session the problem can be addressed. The time needed for each finger is only about 15 to 20 minutes, while the surgical time for the axial JESS is about 2 hours.
6. The compliance of the patients is very good. The patient is taught how and how much to turn the knob, or somebody else can do it for him.
7. When a single JESS is used, local infiltration of any suitable anesthetic agent is sufficient. When more than one finger is involved, regional anesthesia or even general anesthesia are advised, depending on the cooperation of the patient.
8. The operation can be repeated in case of failure.
9. No hospitalization is usually required.
10. Lastly, the JESS instrumentation is economical. This last statement needs to be qualified. European and American single distractors are rather costly, in the range of US \$ 300 each. This is the very reason that prevented us from using distractors prior to the introduction of the JESS. However, the single JESS costs around \$ 5-10 US each. Furthermore, the JESS is also reusable and adaptable to various conditions. An axial JESS costs about \$ 80 US.

The possible complications after this procedure are few and easily avoidable. They include:

1. **Mechanical:** misalignment of the K-wires. Possible complications, which we have not experienced yet, are: impalement of tendons and impalement of neurovascular bundle.
2. **Biological complications:** pin-track infection leading to extrusion. Pin track infection can occur in any surgery wherein K-wires are used.
3. Ulceration caused by the rubbing of JESS on adjacent skin.

#### Various uses of JESS in leprosy

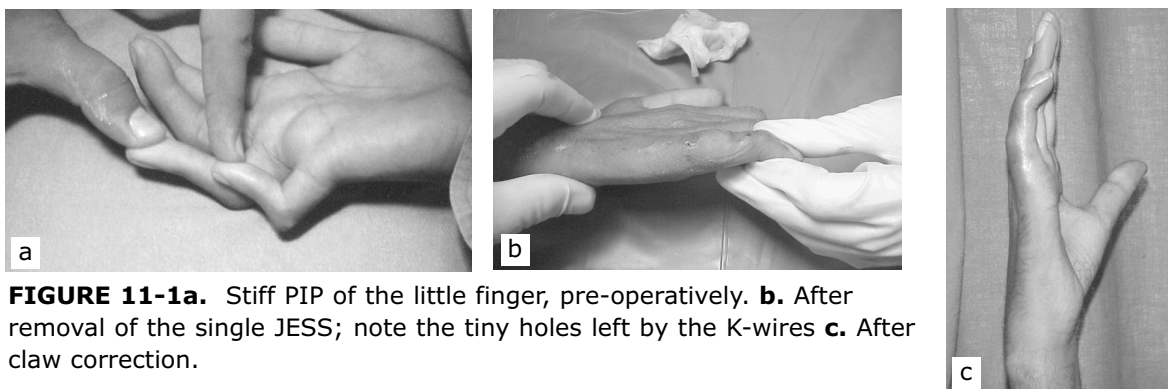
A. **The single JESS** is used by us, with excellent results, in the following conditions<sup>10</sup>:

1. PIP joint stiffness, prior to claw hand correction (Fig. 11-1 a,b,c).
2. First web contractures; in cases of combined web contracture and opponens-plasty, we opt for a two-stage surgery. In the first stage, a 'Z' or 'W' plasty of the first web is carried out and the JESS is used to keep the thumb in opposition (Fig. 11-2 a,b). In the second stage, the JESS is removed and a tendon transfer is

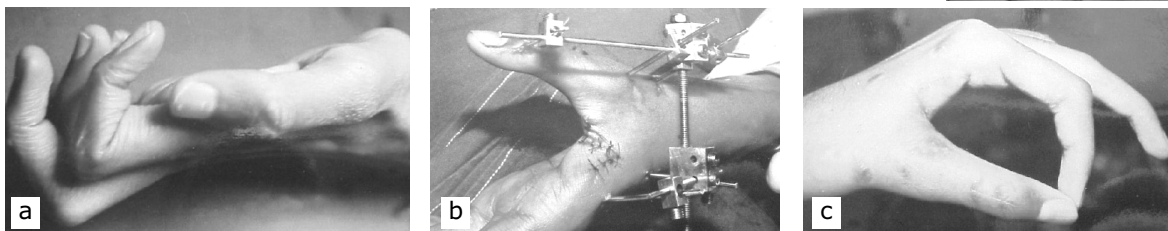
performed (Fig. 11-2c).

3. Skin contracture due to burns / scalds / trauma.
4. In cases of fractures; (the original use of distractors).
5. Arthrodesis, to keep the bony structures in the selected position and for compression and healing (Fig. 11-3).
6. Pollicization: the distractor helps in maintaining alignment.

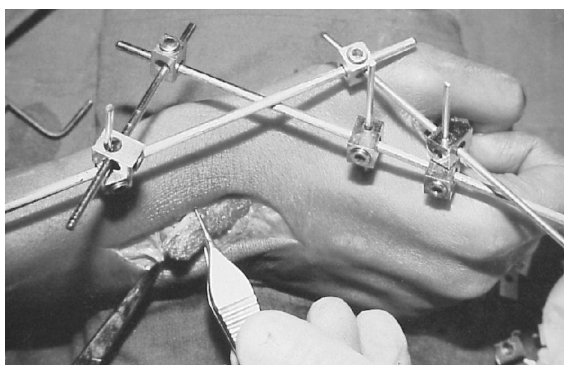
**B. The axial distractor.** Whenever more than one finger is involved, the choice would be an axial distractor that allows distraction of all fingers at the same time. We use it regularly and in some cases we have combined an opponens plasty with distraction of the fingers. In such cases the thumb can also be anchored, by means of an elastic band, to the axial frame to maintain the desired position (Fig. 11-4 a-d).



**FIGURE 11-1a.** Stiff PIP of the little finger, pre-operatively. **b.** After removal of the single JESS; note the tiny holes left by the K-wires **c.** After claw correction.



**FIGURE 11-2** A case of long-standing median palsy with retropulsed thumb. **a.** Lateral view pre-operatively. **b.** Z-plasty of first web and application of JESS. JESS removed after 20 days, and opponensplasty done. **c.** Final result.

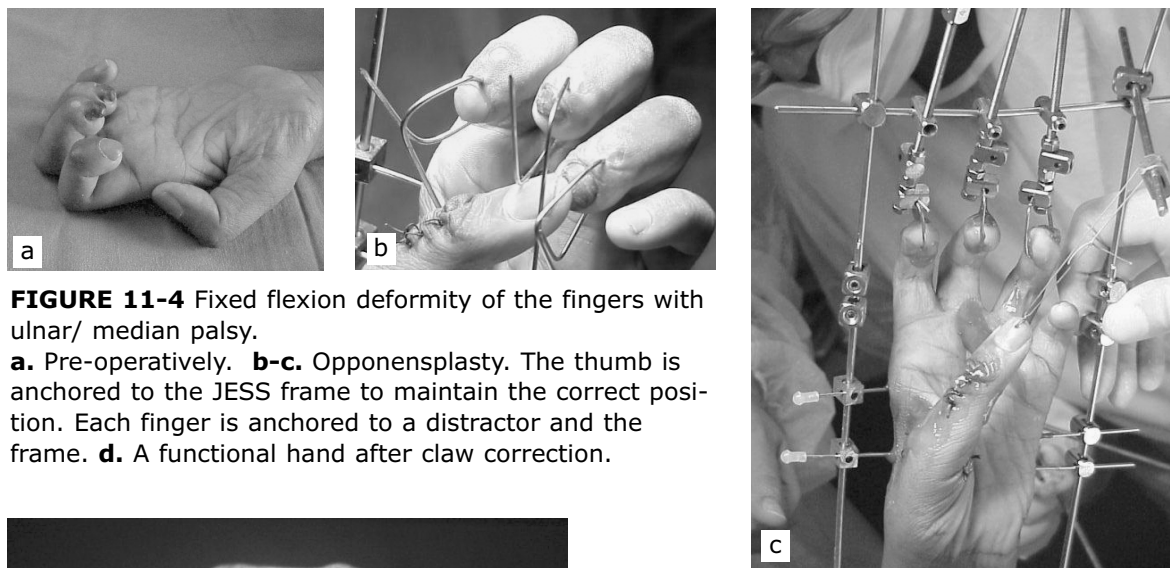


**FIGURE 11-3** A case of wrist drop. The JESS is used to stabilize the wrist after bone graft.

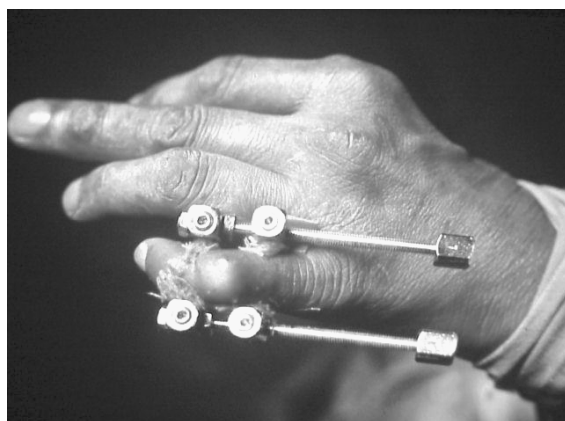**Technique for single JESS**

Two K-wires (1.2 or 1.5 mm in size) are drilled at right angle to the long axis of the phalanx about 12 – 20 mm away from the joint. (Fig. 11-5). Ideally the K-wires should be parallel to each other.

A distractor of suitable length (generally 7.5 cm) is attached to the K-wires. Distraction is attempted immediately. Care should be taken not to overdo this. It is best, on the first day, to stop as soon as resistance is met. A full turn of



**FIGURE 11-4** Fixed flexion deformity of the fingers with ulnar/ median palsy. **a.** Pre-operatively. **b-c.** Opponensplasty. The thumb is anchored to the JESS frame to maintain the correct position. Each finger is anchored to a distractor and the frame. **d.** A functional hand after claw correction.



**FIGURE 11-5** Bilateral single JESS.

the distractor's knob will bring about a 0.5 mm lengthening. At this rate, a joint with a 90° flexion deformity, can be brought to 180° extension in approximately 20 days. Bilateral application of distractors will achieve better results and stability, however care must be taken to ensure that the distractor is not in touch with the web skin. Failure to do so may lead to necrosis of the skin.

**Technique for the axial JESS**

Select four K-wires of 2 mm, four K-wires of 1.5 mm and four K-wires of 1.0 mm each. All wires are inserted at right angles to the long

axis.

Drill four K-wires of 2 mm each in this order: two wires in the mid-forearm and two proximal to the wrist joint. Two wires will be on the ulnar side and two on the radial side. Drill four K-wires of 1.5 mm in the hand. One is drilled distal to the base of the 2nd ray and one proximal to the head of the same. A similar procedure is used for the 5th ray. Rods are attached to each of these wires: this is the beginning of a frame. A 1.0 mm K-wire is passed at the base of each distal phalanx. On these wires the distractors are attached. Now a rod is passed through all four digital distractors and then the rod is anchored to the main frame. The frame is complete (Fig. 11-4c). A number of modifications can be carried out as



needed.<sup>8</sup>

When the flexion deformity is mild, an elastic band can be used instead of the distractor. The rubber band will gradually distract the joint. In this case there will not be much control over the amount of distraction achieved. That is why we prefer the distractors over the rubber bands.

One of the many advantages of the axial distractor over the single JESS is that while distracting a PIP joint by a single JESS, the DIP joint is not distracted. On the contrary the axial distractor, because it is attached to the base of the distal phalanx, will extend every joint.

We advise to delay the actual distraction by a couple of days, because this type of surgery does give rise to a certain amount of edema of the hand and stress on the vessels. By waiting 2-3 days we can assess the vascularity of the fingers and decide on how much distraction to apply. It is better to adopt a slow pace in distraction than a fast one.

## CONCLUSION

We find the application of JESS very useful in neuropathic hands, especially in cases of long standing PIP joint contractures. In view of this, we have abandoned all other procedures like skin grafting, flaps and capsulectomy in favor of distractors which we find easier to use. With distractors we achieve better results than with flaps or capsulectomy.

## REFERENCE

1. Boyes JH: Skin and Contractures. pp 187-303. In Bunnell's Surgery of the Hand, 5th. ed. JB Lippincott, Philadelphia, 1970
2. Brand PW: Deformity in leprosy. pp. 447-464. In Cochrane RG (ed): Leprosy in Theory and Practice, 2nd ed. John Wright & Sons Ltd., Bristol, 1964
3. Brunelli G: Manuale di Chirurgia della Mano. pp. 203-207. Aulo Gaggi, Bologna, 1983
4. Curtis RM: Capsulectomy of the interphalangeal joints of the fingers. J Bone Joint Surg 36A:1219, 1954
5. Fritschi EP: Reconstructive Surgery in Leprosy. John Wright, Bristol, 1971
6. Glicenstein J, Leclercq C: Skin contractures in the hand. pp. 439-464. In Tubiana R (ed): The Hand, Vol. 2. WB Saunders, Philadelphia, 1985
7. Joshi BB: Lecture demonstration at the Anglo India Congress on Hand Surgery, Goa, Nov 1991
8. Joshi BB: Joshi External Stabilization System, Basic Techniques as applied to Hand and Wrist. JESS Research and Rehabilitation Centre, Bombay, 1999
9. Mantero R: Un apparecchio di Hoffman modificato per il trattamento delle lesioni della mano. Riv Chir Mano 13:134-150, 1976
10. Salafia A., Chauhan G. Joshi External Stabilizing System (JESS) in proximal interphalangeal joint (PIP) contractures in leprosy. Ind J Lepr, 69: 331-339, 1997
11. Tubiana R: Skin flaps. pp257-286. In Tubiana R (ed): The Hand (Vol. 2) WB Saunders, Philadelphia, 1985
12. Wolfe JR: A new method for performing plastic operations. Brit Med J, 2: 360, 1875