

## Management of Ulcers in Neurologically Impaired Feet in Leprosy Affected Persons

• H. SRINIVASAN

### INTRODUCTION

If one is asked to visualise a 'typical leprosy patient', it is almost certain that the imagined figure will be a beggar, having a deformed hand – most probably crooked and shortened fingers – and a bandaged foot. This shows the extent leprosy is identified in the mind of the public with debilitation, deformity and ulcers. Despite the fact that hardly 10% of leprosy-affected persons have ulcers at any one time, one cannot imagine a leprosy patient without them. Of the two, deformities and ulcers, the latter, especially ulcers in the feet, are of the greatest importance because impaired mobility is a very serious 'handicap' for leading a normal life in society. In addition, frequent episodes of acute infection may interfere with work and smelling ulcers make the affected person an object fit for ostracisation. Ultimately, the patient may end up as a 'scarred' individual with mutilated or amputated feet, an object of pity dependent on others both physically and economically. Ulceration of the feet is the single most common cause of morbidity and debilitation of leprosy-affected persons. In view of this, it should be evident that any worthwhile leprosy project must have a planned programme for managing, i.e., treating and preventing, ulcers in leprosy-affected persons. The fact that most leprosy projects do not have such a programme only exposes their lopsided priorities, dictated more by preoccupation with 'public health' than concern for patients' welfare.

### Different kinds of Ulcers

Leprosy-affected persons develop ulcers for a variety of reasons and the characteristics of the ulcers such as their location and clinical features vary accordingly. Broadly speaking, the ulcers may be classified into two groups, based on whether pre-existing nerve damage is a predisposing cause, as 'neuropathic' and 'non-neuropathic' ulcers. Unlike non-neuropathic ulcers, which may occur anywhere in the body, neuropathic ulcers occur only in sites having partial or total sensory nerve function deficit, which also come into physical contact with the external world. Neuropathic ulcers are thus mostly found on the soles of the feet. Accordingly, they can be classified as 'plantar' or 'extra-plantar' ulcers. Non-neuropathic ulcers may be "specific" or "non-specific" depending on whether ulceration was part of the disease process (Fig. 15-1). Of the different types of ulcers, neuropathic plantar ulcers are the most important clinically. They will be discussed in greater detail in this chapter.

### Non-neuropathic Ulcers

The non-neuropathic ulcers group, as the name implies, are not due to nerve function impairment. They may be divided into specific or non-specific depending on the aetiology. Specific ulcers occur as part of the disease process and clinical picture of leprosy. Non-specific ulcers are not related to leprosy pathology. The non-specific ulcers in leprosy-affected persons are usually stasis ulcers.

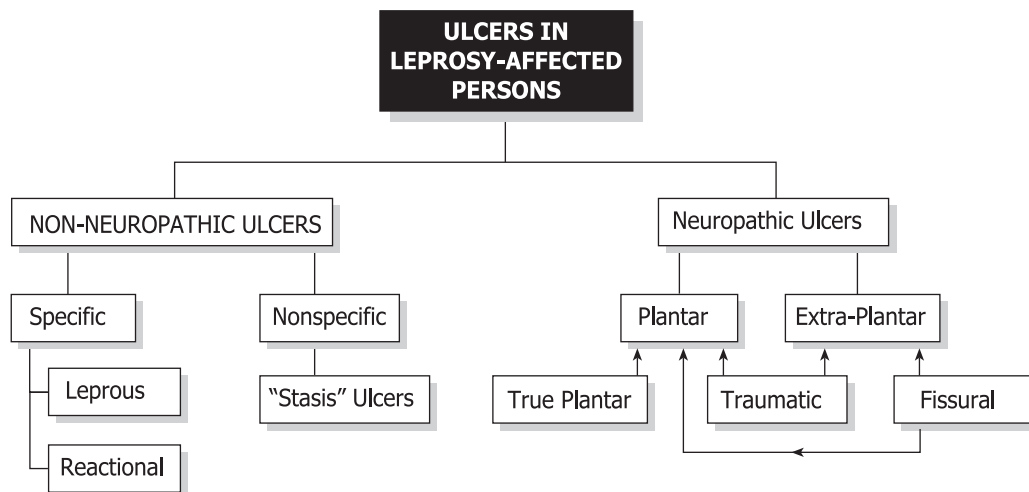


FIGURE 15.1 Ulcers in leprosy affected persons.

**Specific Ulcers**

Specific ulcers occur in the tissue background of leprous pathology. Specific ulcers are of two types: leprous or reactional. The former are seen in advanced cases of lepromatous leprosy while the latter are found in association with severe leprosy reaction, usually Erythema Nodosum Leprosum (ENL).

Leprous ulcers occur because of skin breakdown over rapidly expanding lepromatous nodules. They are seen in patients with untreated, advanced, lepromatous leprosy. They are now uncommon indicating early case detection and good patient coverage under national leprosy programmes. Leprous ulcers are found in sites of heavy infiltration and nodulation such as the face, elbows, dorsum of hands, and inside of the nose. The ulcers occur because the stretched skin over the nodule gives way exposing the leprous granuloma underneath, which appears as pale granulation in the floor of the ulcer. The ulcer discharge is heavily laden with leprosy bacilli. These ulcers will heal rapidly once multidrug therapy is started. The ulcers need to be kept clean and covered with a bland dressing. There is no evidence to suggest that topical use of anti-leprosy drugs

like rifampicin or dapsone is necessary for healing these ulcers.

Reactional ulcers occur as part of the clinical picture of severe lepra reaction, usually ENL but sometimes reversal reaction (RR). The ENL lesions develop into vesicles and pustules, or intense inflammation in coalesced ENL lesions or erythema multiforme-like lesions develop into large blisters that break open to expose large raw areas. In other cases of severe reaction, because of the intensity of inflammation, which in very severe cases may be compounded by arteriitis, there is tissue necrosis and breakdown, resulting in ulceration. Reactional ulcers are mainly seen on the extensor surfaces of the limbs and trunk. As they are part of the reactional process, aggressive treatment of the reaction with sufficiently high doses of steroids and adequate supportive therapy are needed for healing. Keeping the ulcer clean and covering them with a bland dressing is sufficient.

Like leprous ulcers, reactional ulcers are usually superficial, often in the level of epidermis, with scarring only of the skin. Often the scars are hyperpigmented, occasionally vitiliginous. Ulcers on the fingers, especially over the proximal interphalangeal joints, may some-

times pose difficult therapeutic problems. In cases of severe reaction, there may be necrosis of the full thickness of the skin overlying the joint. In such cases, there is a great danger of the finger becoming stiff in a straight or flexed position. In such cases, the fingers need to be splinted in the functional position so that if they become stiff, they would still be of some use. Treatment of reactional ulcers involving the hand may pose problems to the therapist for, in order to achieve early resolution of inflammation the part needs to be rested, whereas the hand has to be kept mobile to prevent it becoming stiff. In severe cases, there is also a danger of necrosis of the tissue overlying the joint, due to associated arteriitis. That would expose the joint to secondary infection. These possibilities must be anticipated and treatment of high quality under the daily guidance of an experienced physiotherapist or technician is needed to prevent such outcomes.

### Non-specific Ulcers

The most common chronic, non-neuropathic, non-specific ulcers are those similar in appearance to stasis ulcers. These ulcers are usually seen in middle aged or elderly persons, treated earlier for long-standing lepromatous leprosy. The ulcer, often located in front of the ankle and extending up the leg, is usually quite large. It occurs on the background of pachydermatous skin that may also exhibit varicose changes. The skin of the lower leg may be atrophic, thin and shiny. The ulcer frequently extends over the region of the medial or lateral malleolus. There is usually a history of some trivial injury preceding ulceration and the ulcer progressively enlarging instead of healing until it has attained the present large size.

The floor of the ulcer is sclerotic and covered with thin, pale granulation that may be easily scraped off without causing much bleeding. There is copious serous or sero-sanguinous discharge oozing from the ulcer, which is usu-

ally not positive for acid-fast bacilli. The bed of the ulcer is densely scarred and feels hard. A vitiliginous area indicating the past extent of ulceration often surrounds the ulcerated area. In their location, appearance and clinical behaviour these ulcers resemble the stasis ulcers seen in persons with incompetent venous valves or blocked lymphatics due to frequent attacks of lymphangitis and consequent blood or lymphatic stasis. No information is available in the published literature to show whether vascular or lymph stasis is actually present in these cases and, if so, their aetiology.

These ulcers are very refractory to treatment, healing is very tardy, tentative and often temporary. Skin grafts, even split-thickness grafts, often fail to take. Clinical experience suggests that keeping the ulcer clinically and bacteriologically clean and using occlusive, compression dressing coupled with exercises to improve drainage of blood and tissue fluid from the lower limb might assist healing. However, none of these treatments have been well studied.

### NEUROPATHIC ULCERS

Neuropathic ulcers occur in a part of the body as sequelae of a pre-existing sensory deficit. These ulcers are found in those denervated parts of the body which come into contact with the external world. That happens because denervation has made the part vulnerable to the events and stresses that occur at that interface, initially at the time of their occurrence or subsequently. The foot is constantly in contact with the ground carrying the weight of the body in the course of its activities like walking and running. The soles of the feet are, therefore, the most frequent sites to develop neuropathic ulcers and these ulcers are known as '(neuropathic) plantar ulcers'. These ulcers cause maximum discomfort to the patients and in view of their importance they are discussed in some

detail below. Ulcers occurring in other denervated sites, such as the dorsum and lateral malleolar region of the foot and the hands are described under '(neuropathic) extra-plantar ulcers'. Neuropathic plantar ulcers are usually referred to simply as 'plantar ulcers'. They are also commonly known as 'trophic ulcers' and less commonly as 'perforating ulcers', 'penetrating ulcers', or 'mal perforans'.

### **Concepts of Causation of Plantar Ulcers: A Historical Review**

It is worth recapitulating briefly the evolution of our concepts of the causation of plantar ulcers since all of them still persist to a varying extent, among the affected persons and health workers alike, thereby impacting treatment and outcome, sometimes adversely.

#### **Leprosy is the cause**

Till about the last decade of the 19th century it was the general belief that leprosy "devitalized" tissues, depriving them of their ability to survive and withstand stresses. It was believed that tissues rotted and dropped off (e.g., shortening of fingers and toes). The additional stress of carrying the body weight and the resulting pressure caused the "devitalized" bones and other tissues of the foot to undergo necrosis. Ulceration was seen as the means by which the body attempted to get rid of the dead tissue. Finding pieces of dead bone in the depths of these ulcers coupled with the observation that removal of those pieces and resting the foot usually healed the ulcer were considered as providing proof of this view.<sup>17</sup> Thus, leprosy was considered to be directly responsible for these ulcers. For that reason, these ulcers were considered highly infectious and thought to be a serious way the disease spread in the community. Many lay people and even some leprosy workers still subscribe to this view. Hence, the advocacy and use of topical anti-leprosy drugs, ranging from hydnocarpus oil to

rifampicin, by some people even today for healing these ulcers.

#### **Neuropathy is the cause**

By the last few decades of the 19th century it had been established that the nervous system controlled the functioning of most if not all of the organs of the body. It was then postulated that there ought to be 'trophic' nerves that regulated cell metabolism in order to maintain the integrity of cells and tissues against 'wear and tear'. In patients with leprosy and other neuropathies it was presumed that the 'trophic nerves' would also be damaged in due course, and that this would cause 'devitalization' of cells, tissues and organs. Thus denervation and particularly damage to the hypothetical "trophic nerves" was presumed to be the primary cause of 'devitalization' of tissues which then broke down under conditions of normal use or abnormal stress. These ulcers were therefore called 'trophic ulcers', a term that is still in use widely.

#### **Trauma is the cause**

According to this line of thinking unperceived injuries to the foot and neglect of those injuries were considered to lead to the formation and maintenance of ulcers. Both lack of perception of the injury initially and neglect of the injured part subsequently were explained as being due to insensitivity and consequent lack of feeling of pain, because of damage to the peripheral nerves. The fact that these ulcers always occurred in feet with loss of protective sensation, and the not infrequent finding in their depths of foreign bodies like stones, were taken as proof for this view. This situation continued till the middle of the 20th century.

#### **Ischemia is the cause**

Around 1950, Paul Brand and a band of young orthopaedic surgeons under his leadership

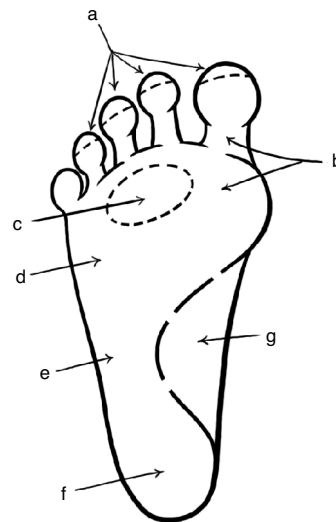
started taking interest in the problems of leprosy-affected persons. They were struck by the fact that there was great damage to deeper tissues and that the ulcers occurred almost exclusively in the weight-bearing areas. This suggested that these ulcers might be pressure sores, somewhat like bedsores. Simple measurements, of the area of weight-bearing surface and the load on that area, assuming that 50% of the weight was borne by the heel and the other 50% by the ball of the foot, showed very clearly that pressures in the sole during standing would far exceed the blood pressure, blocking entry of blood to the compressed part of the sole. It was evident that continued standing without relieving the sole of the foot, by frequent shifting of weight from one foot to the other, would cause severe ischemia. That would be sufficient to lead to ischemic necrosis of the subcutaneous tissue and then of the overlying skin causing ulceration. Persons with insensitive feet would not feel the ischemic pain and so (it was postulated) would not shift the weight from their feet periodically as healthy individuals do, thus allowing development of ulcers. On this basis patients were instructed not to stand for 'prolonged periods'.<sup>13</sup>

While the logic of this hypothesis was sound, the basic premise that one could stand for "prolonged" periods (for four to five hours or longer! - which is what "prolonged" means in the present context) without swaying, continuously loading the sole, was not realistic for two reasons. Firstly, people rarely, if ever, stand like that.<sup>7</sup> Secondly, the body cannot stand still even for a few seconds, as the living body is constantly swaying, mostly forwards and backwards, as the muscles are constantly pulling the body in one direction or the other to prevent it from falling. Thus, standing is an act of dynamic equilibrium and one cannot stand 'absolutely still' even for a minute, let alone for the hours required to produce ischemic necrosis and ulceration of the sole.

### Walking is the cause

Price, a surgeon working in Nigeria, published in 1959 three papers on plantar ulcers in leprosy which gave us a new insight into the causation of ulcers.<sup>33-35</sup> It was Price who introduced the term 'plantar ulcer', instead of the then popular 'trophic ulcer'. Price made three important observations:

a) The ulcers were not randomly distributed in the weight-bearing area of the sole; instead, there was a bias for the ulcers to be located under the metatarsal heads. About 70% of the ulcers occurred in this part of the sole, with 10% occurring in the heel, and a further 10% in the midlateral part of the sole. The risk of ulceration of the forepart of the sole of the foot was therefore about seven times greater than that of the heel. This pattern of preferential ulceration of the ball of the foot was confirmed soon after in South India, at Karigiri and Chingleput (Fig. 15-2).<sup>41,44</sup>



**FIGURE 15-2** Frequency of distribution of ulcers in sole of the foot a) tips of toes <5%; b) big toe region 30-50%; c) central toe region; 2nd-5th metatarsal heads 20-30%; d) Metatarsal head region 15-20%; e) mid lateral border of the foot (base of 5th metatarsal) 15-20%; f) heel 5-10%; g) instep <1%.

b) The ulcers started as blisters over areas of necrosis. There was an initial area of deep inflammation followed by necrosis of the subcutaneous tissue, which was followed by the development of the 'necrosis blister'. While the blister usually lay over the area of necrosis, the blister fluid sometimes tracked along paths of 'least resistance' and surfaced at a distance.

c) The ulcers developed in one of three ways:

1. through infection of a (usually penetrating) wound giving rise to a traumatic ulcer;
2. through infection of a deep skin crack, frequently found in the anhidrotic soles of these patients, or, infection of a 'bursa' deep to a callosity/corn through a fine crack giving rise to a fissural ulcer or,
3. more commonly, because of the stresses and strains on the tissues of the sole during walking giving rise to a 'true' plantar ulcer. Price pointed out that the stresses and strains of walking lead to ulceration and that this explains the special vulnerability of the ball of the foot for ulceration. According to Price, only the last type of ulcers would qualify to be called 'plantar ulcers'. However, it is common experience that these ulcers, once they have developed, behave the same way and have to be managed the same way irrespective of their initial cause, be it trauma, fissure or walking. Probably for this reason and also because patients are rarely seen at the initial stage, no distinction is now made between 'true' and other types of plantar ulcers and all are referred to simply as 'plantar ulcers'.

Price did not, however, explain why walking strains should cause ulceration in insensitive feet only. Brand has advocated the idea that leprosy patients with insensitive feet walked 'excessively'. He has shown experimentally that even a small rise in stress when

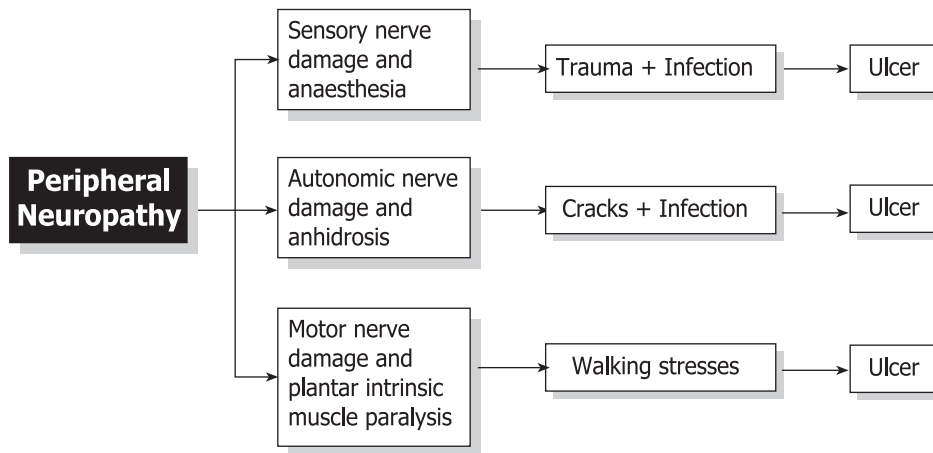
repeated innumerable times causes aseptic inflammation at that site and that the inflamed sites then break down easily.<sup>6</sup> Patients were, therefore, advised not to walk 'too much' and to rest their feet at periodic intervals if they had to walk 'long distances'. Srinivasan found that a history of prolonged walking preceded the initial development of ulcers in only a few cases. His study showed that insensitivity of the sole introduced a risk of ulceration (ca. 6% in his patients) and that the risk increased (12-72%) when there was associated paralysis of the plantar intrinsic muscles.<sup>45</sup> This study further showed that paralysis of muscles or muscle groups rendered particular sites more vulnerable.

That observation would further support the thesis that paralysis of the plantar intrinsic muscles increases the risk of ulceration in the ball of the foot.

### Current View of Causation of Plantar Ulcers (Fig. 15-3)

The currently held view is as follows. A minority of ulcers (ca. 10%) arise from perceived or unperceived injuries with neglect of these injuries resulting in infection and tissue damage. Another small proportion (ca. 5%) arise from neglect of deep cracks in the dry (anhidrotic) and hyperkeratotic skin of the sole, or, from infection of 'bursae' underlying callosities or corns, through fine cracks. The majority of plantar ulcers arise from breakdown of plantar subcutaneous tissue due to the stresses and strains of normal walking.

All plantar intrinsic muscles exert their effect in the region of the metatarso-phalangeal joints. When these muscles are paralysed, the compression and shearing forces are increased, even during normal walking. The plantar intrinsic muscles are maximally active during the "push off" stage of walking when the fore part of the foot pushes the ground backward in



**FIGURE 15-3** Current concept of plantar ulceration.

order to propel the body forward.<sup>1</sup> Their contraction creates a thrust that will counter the compressive, shearing and distracting forces at the metatarso-phalangeal joint region that are normally generated at this stage of walking. When the plantar intrinsic muscles are paralysed, this protective effect is lost, and the toes get clawed during the “push off ” stage of walking, causing momentary increases in stresses and strains in the region of the metatarso-phalangeal joint at each step. Brand has shown that even small increases in stresses can

lead to breakdown of tissue if repeated long enough, causing ulceration.<sup>6</sup> Similarly, paralysis of long muscles also increases the risk of ulceration at specific sites due to momentary increases in stresses at those sites as shown below (Fig. 15-4).

**Other causes of plantar ulceration**

While most plantar ulcers arise in the manner described above, other (known or not yet known) causes may be operating occasionally

Muscle Group Paralysed	Site Made Vulnerable
Plantar intrinsics	Ball of the foot
Abd. hallucis group	I Metatarsal head region
Interossei-lumbricals	II, III, & IV Metatarsal head region
Abd. dig. minimi group	V Metatarsal head region
Fl. dig.brevis / interossei & lumbricals	Tips of toes
Foot dorsiflexors	Heel
Peronei (evertors)	Head / Base of V metatarsal
Calf muscles (plantar flexors)	Heel

**FIGURE 15-4** Sites rendered vulnerable to ulceration by particular muscle paralysis.\*

\* The reader is advised to also study chapter 12 for additional insights into the pathogenesis of plantar ulceration (eds.).

to give rise to an ulcer. Thus obvious or occult anatomical anomalies and variations, improper or ill-fitting footwear, vascular insufficiency or rare fungal or bacterial infections may lead to ulceration of different parts of the foot. These factors, however, usually determine the site of an ulcer rather than initiate one.

### STAGES OF ULCERATION

The pathogenesis of plantar ulcers may be described in terms of three 'stages' namely the stage of 'threatened' ulcer, the stage of 'concealed' ulcer and the final stage of 'overt' or open ulcer.

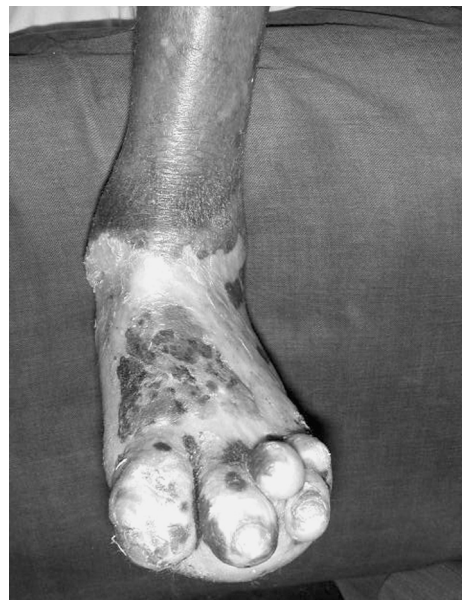#### Stage of threatened ulcer

In terms of pathology, this stage may be called "pre-ulcerative stage of aseptic inflammation". Increased stress repeated over a period of time gives rise to a focus of traumatic (aseptic) inflammation in the region of the subcutaneous layer of the sole of the foot, which is most vulnerable to mechanical stress. This occurs at the site of increased stress, usually under a joint or a bony prominence, very often just distal to the head of a metatarsal. The affected site is oedematous. This is seen as mild or obvious splaying of a toe, which stands apart from its neighbour to a greater or lesser extent.<sup>33-35</sup> The affected site is often tender to deep digital pressure. Clinicians do not often get to see feet in this stage since patients rarely report at this stage.

#### Stage of concealed ulceration

This is the stage of "necrosis blister". The inflamed site undergoes necrosis on continued subjection to stress, by walking, with the subcutaneous tissue undergoing colliquative necrosis. The liquefied tissue mixed with some blood is forced to the surface by continued walking to present as a blister. This is the so-called 'necrosis blister'. This blister usually directly overlies the area of necrosis, but some-

times, when the overlying tissue is too tough, it may track along a path of least resistance and emerge to the surface at a distance, at the side of the toe or in the interdigital web.<sup>33-35</sup> This stage also often goes unnoticed. Even when noticed, patients may mislead the physician by attributing the blister to (an unperceived) burn as, in their experience, burns cause blisters (Fig. 15-5). Only close questioning will reveal that 'the burn' was an assumption or an inference and not a fact or direct observation.



**FIGURE 15-5** Burn in a newly diagnosed leprosy patient; patient presented with the burn.

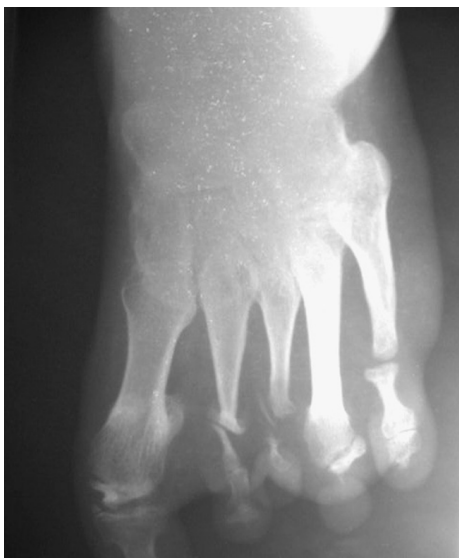#### Stage of overt ulceration

With the formation of the necrosis blister the essential process of ulcer formation namely, destruction of the subcutaneous tissue, is complete except that the "ulcer" is not seen or obvious as it is still covered with skin. When the skin overlying the blister breaks open, the ulcer site becomes exteriorised, the necrotic area becomes exposed to the external world and there is an obvious ulcer.



### PROGRESSION OF PLANTAR ULCER

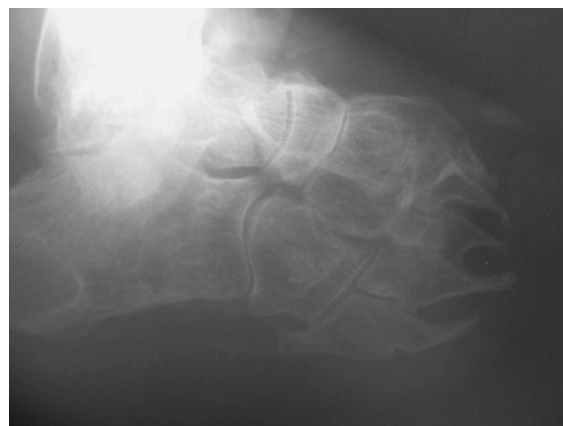An ulcer does not usually bother the patient except for its nuisance, as there is usually no accompanying pain. It may enlarge to some extent and continue like that, without healing, for some weeks or a few months. Sooner or later it can become acutely infected with 'street organisms' like *Staph. aureus*, *E. coli*, or *B. proteus*.<sup>9,11,14,31</sup> The part becomes swollen, the oedema showing up prominently over the dorsum even when the infected site is in the sole, and the edges of the ulcer are also swollen. There is copious discharge of pus or sero-sanious fluid, which may be foul smelling. The floor of the ulcer is often covered with necrotic tissue. There may be associated groin adenitis, lymphangitis and fever, depending on the severity and extent of localization of infection. Examination of the blood shows polymorphonuclear leukocytosis. The ulcer presenting in this fashion, with acute inflammation, is often referred to as an 'acute ulcer'. Initially, the infection and inflammation are confined to the subcutaneous tissue and plane, without it extending to deeper tissue or structures like bones, joints or tendon sheaths. In that case



**FIGURE 15-6** Early digit/metatarsal bone loss secondary to ulceration.

they are also called 'simple ulcers' or 'uncomplicated ulcers'. Usually, the patient seeks relief at the stage of acute inflammation and with treatment the inflammation subsides, and the ulcer may also heal. Or, after improving for some time, the ulcer may remain unchanged and continues to be present as a small raw area. The acute ulcer has become quiescent and has entered the chronic stage. From now on it is referred to as a 'chronic ulcer'.

The chronic ulcer, as the name suggests, remains unchanged and unhealed for some time and then may flare up again as an acute ulcer. With treatment the acute inflammation subsides and the ulcer reverts to the chronic status once more. Over the course of years, this cycle (chronic ulcer → acute ulcer → chronic ulcer) may be repeated (Figs. 15-6,7). During any one of the acute episodes the infection may break through the natural barriers and extend to one or more deeper structures such as an underlying joint or bone or an adjacent tendon sheath or, a 'plantar space'. Ulcers in the midlateral border of the foot are dangerously close to cubo-metatarsal and calcaneo-cuboid joints to which infection may easily spread and from there to the other tarsal joints. Such extension of infection to deeper structures converts the 'simple ulcer' into a 'complicated ulcer'. In this



**FIGURE 15-7** Advanced bone loss secondary to ulceration.

manner, the plantar ulcer may result in additional complications like osteomyelitis, septic arthritis or tenosynovitis. These complications may result in fixed deformities of toes or foot, loss of bone and flail or disorganised joints. It is not anymore a plantar ulcer, but a sinus with deep ramifications associated with profound structural changes in the foot, with corresponding functional consequences. The term 'penetrating ulcer' is sometimes used to refer to an ulcer that extends deeply into a tarsal bone, like the calcaneus. Sometimes, the sinus finds its way through the full thickness of the foot and opens out in the dorsum of the foot. Such an ulcer, which perforates the foot through and through, is called a '*perforating ulcer*' or *mal perforans*. Severe and repeated infection causes extensive tissue necrosis with replacement of the dead tissue with scar tissue. Scar tissue cannot withstand the stresses and strains generated in the foot during walking and, sooner or later it may break down and the ulcer that healed with great difficulty breaks open readily. These ulcers, which recur readily, with little provocation and despite taking proper care and adequate protective precautions including the use of appropriate footwear, are referred to as 'recurrent ulcers' in which the recurrence of the ulcer itself is the main complication.

**CONSEQUENCES OF REPEATED ULCERATION**

Each episode of recurrent ulceration is associated with additional tissue damage and further scarring at the site making the part more vulnerable to ulceration. Further, soft tissue loss, scar contraction, pathological fractures and bone loss associated with chronic osteomyelitis, and destruction of an underlying joint often cause development of fixed deformities, abnormal bony prominences and functional abnormalities. During walking and even

during standing, these abnormalities can cause increased pressures and other stresses and strains on the already vulnerable scar leading to the breakdown of the scar even more readily. A vicious spiral is set up in this manner leading to progressive and extensive destruction and mutilation of the foot. The plantar ulcer may rarely develop some other complications such as life-threatening clostridial infections (tetanus, gas gangrene), or, septicæmia. Occasionally, long standing ulcers may undergo malignant or premalignant degeneration developing into a 'cauliflower growth' that may be squamous-cell carcinoma or identical-looking pseudo-epitheliomatous hyperplasia.<sup>49</sup> The natural history of plantar ulcers is shown in Fig. 15-8.

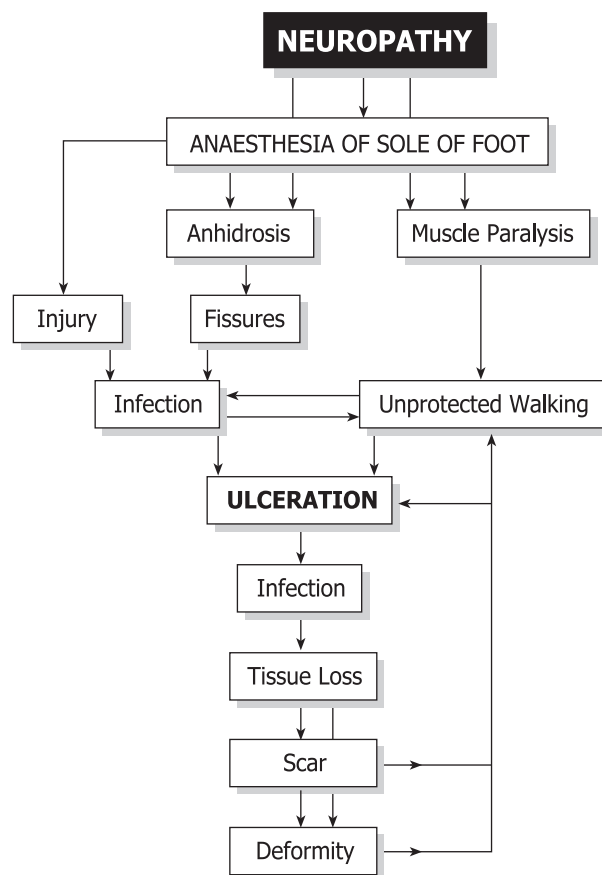
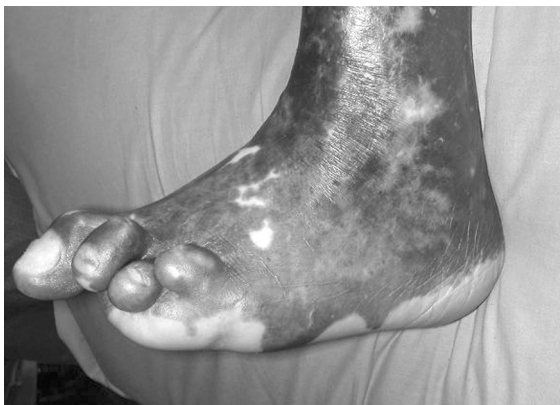

FIGURE 15-8 Natural history of plantar ulceration.

## LOCATION OF PLANTAR ULCERS

As pointed out by Price, plantar ulcers are not distributed randomly in the sole of the foot, but are found more often at some sites than others. Thus, the forefoot is the most favoured site, accounting for 70% to 80% of the ulcers. Srinivasan showed that even in the ball of the foot, the frequency of ulceration progressively increased from the lateral to the medial part, the first metatarsal head region being the most common site (Figs. 15-2 and 9).<sup>46</sup> Ulcers are least common in the region of the medial arch (instep) of the foot. The frequency of ulceration increases progressively in the following order: tips of one or more toes, pulps of one or more toes, heel, mid lateral border of the foot (base of 5th metatarsal), region of the 5th metatarsophalangeal (MTP) joint, region of central three MTP joints and the region of the MTP joint of the big toe being the most common sites. Although the last three sites are commonly referred to as being 'under a metatarsal head' (MTH region), the ulcer is usually located just distal to and not right under the metatarsal head. The toes are webbed to a much greater extent than the fingers and the metatarsal heads are not located as far forward in the ball of the foot as commonly imagined. The exact location of an ulcer is determined by a number of factors. A traumatic ulcer may occur any-



**FIGURE 15-9** Forefoot deformity secondary to plantar ulceration.

where in the sole of the foot, since a thorn, nail, or a sharp stone will penetrate any part of the foot with which it comes into contact. Fissures, and fissural ulcers, on the other hand, occur around the margin of weight-bearing areas in the sole.

## NEUROPATHIC EXTRA-PLANTAR ULCERS

### Extra-Plantar Foot Ulcers

Neuropathic ulcers may also be found in sites other than the sole of the foot. These are known as extra-plantar ulcers. Thus in the foot, extra-plantar neuropathic ulcers are seen on the dorsum or over the lateral malleolus. The ulcers over the dorsum of the toes are due to rubbing of the toe (usually the second toe) by an ill-fitting strap of the sandal or the upper of the shoe. In these cases, the toe is usually deformed, having a fixed or mobile claw deformity. Sometimes, a flail little toe develops ulceration over its dorsum, again due to frictional trauma from the shoe or sandal.

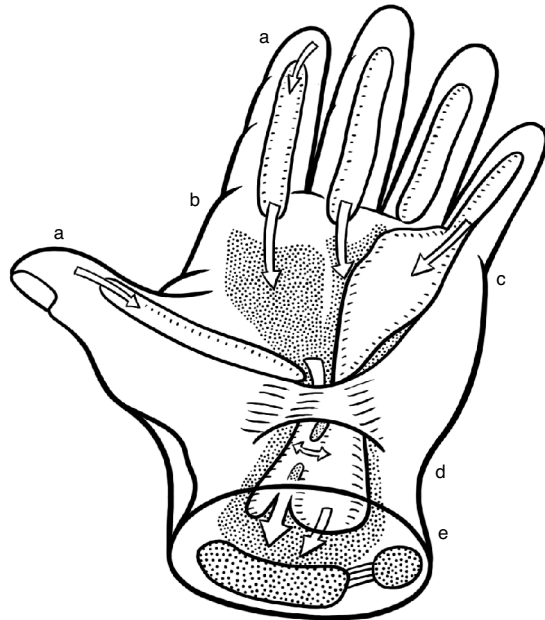
Ulcers over the lateral malleolus arise from pressure and friction due to cross-legged sitting. The tissues over the lateral malleolus get caught between the ground and the underlying bone. Repeated and continuous compression causes the skin over the lateral malleolus to be thickened and hyperkeratotic and a corn develops in that area. The corn increases the compression and shear stresses, causing an adventitious bursa to develop between the corn and the underlying lateral malleolus. The bursa becomes chronically inflamed with thickening of its walls, because of repeated trauma from sitting. At some stage, fine cracks develop in the skin overlying the bursa. The bursa may get infected, a collar stud abscess develops, bursts open discharging pus leaving behind a chronic sinus communicating with the infected bursa underneath. The skin overlying the infected bursa may slough off and a large indolent ulcer extending over the entire lateral malleolar area

develops. If not treated properly and promptly the bone may also become involved. With continued neglect, the infection may spread further to involve the ankle joint with disastrous consequences. Instances are not unknown in which the entire talus had been extruded as a sequestrum in cases of sepsis of the ankle.

### Extra-Plantar Hand Ulcers

Neuropathic ulcers occur also in the hand. In fact, hand ulcers are at least as common as plantar ulcers but they usually heal quicker as, unlike the feet, wound healing in the hands is not complicated by having to bear the weight of the body. Ulcers in the hand are mostly 'traumatic' in origin and are caused by burns (cooking, cigarettes), cuts and abrasions. The digital pads, palmar and dorsal aspects of fingers and hypothenar eminence are most often affected. Sometimes, vermin like rats chew up the insensitive fingers or toes of the patient during sleep. To prevent this happening Brand advised patients to keep a dog or a cat as pet to keep the area vermin free. Because they are not painful the wounds are neglected and not allowed to heal by treating them properly, rest. As a result, they continue to remain as festering sores. Often, digital pad infection is allowed to extend deeper and progresses into osteomyelitis of the terminal phalanx, and loss of its distal parts through sequestration. Fingers in leprosy-affected persons get shortened progressively in this manner, sometimes to mere stubs. The infection may also spread proximally, to the flexor synovial sheath and through that involve the spaces of the palm, or, even Parona's space in distal 1/4th of the front of forearm (Fig. 15-10).

Infection of the synovial sheath may also lead to necrosis and loss of flexor tendons of the finger, leaving behind a stiff and straight finger, reducing hand function. Besides the traumatic ulcers, fissural ulcers are also not uncommon in the hand. Persons doing hard



**FIGURE 15-10** Spread of infection in the hand: a) from pulp of finger to flexor synovial sheath. b) from flexor sheath to palmar spaces. c) flexor sheath to ulnar bursa. d) from radial bursa to ulnar bursa and vice versa. e) from palmar space (white arrows) and flexor sheath (black arrows) to Parona's space.

manual labour develop areas of hyperkeratosis in the region of digital creases and the thickened dry skin will crack when the finger is passively straightened during the course of work. In this manner a fissure develops, usually at the site of the middle digital crease or at the proximal digital crease located at the base of the finger. These fissures are initially shallow but in course of time may become quite deep to expose the subcutaneous tissue and even the flexor tendon or its sheath. The fissure is surrounded by grossly hyperkeratotic skin and frequent movement keeps the fissure open and prevents its healing. Secondary infection may enter through the fissure to involve underlying structures with consequences similar to those mentioned earlier.

Pressure and friction sores are also seen in the hand. Friction sores may occur over the

dorsum of a finger at the PIP joint level due to rubbing away of the skin and deeper tissues during activities like soaping a garment over a stone. Pressure or friction sores in the hands are seen in persons who habitually use their hands to push the ground down (for getting up), or, downwards and backwards (in order to move forwards). Tips of claw fingers become sclerotic and the sclerotic tissue gets worn out in course of time due to the use of great force used during gripping objects, presenting a small circular sore. Pressure sores in the hand typically occur over the 'heel' (proximal medial (ulnar) corner, i.e., base of hypothenar eminence) of the palm, over the pisiform bone. Infection may spread from an ulcer at this site to the bone underneath and, with continued neglect, spread to the other carpal bones and intercarpal joints, which may result in carpal disorganisation.

## MANAGEMENT OF NEUROPATHIC ULCERS

It would be evident from the foregoing discussion that we should aim at achieving three goals: 1. healing of ulcer(s) already present, 2. prevention of recurrence of ulcers that have healed and, 3. prevention of ulceration in individuals with sensory neuropathy, if they are at risk of developing neuropathic plantar or extra-plantar ulcers.

When there is a plantar ulcer, our primary aim is to get the ulcer healed. As the first step, the feet should be carefully examined. Ask the patient whether there is impairment or loss of sensibility in feet and hands, including the affected foot. Although patients' statements in this regard are fairly reliable, it is better to assess sensation.<sup>28</sup> People are often not aware of sensory impairment of insidious onset.

*Examining the foot with plantar ulcer.* Ask for a history of impaired sensibility in the affected

foot as well as the other foot and hands, its extent and duration. Use a few explanatory queries such as "Does the ground feel normal while walking? Do you feel the small stones or the hot ground under your feet during walking? Does it hurt when you step on a pebble?" This will confirm that you and the patient have understood each other correctly. Next, even in cases of recurrent ulceration, ask for the details of how the ulcer started originally and what happened subsequently. In the patient's replies, try to identify actual observations from inferences: the patient may say that he had a 'burn' whereas he is not aware of any episode of the burn and had actually noticed only a blister; the patient may say he had an abscess, but only blood stained thin fluid, not pus, drained from the 'abscess'. When asking a leading question such as "Did you have a wound? Did you walk a long distance?" always explain what you mean by the terms used in your question. The terms 'wound' and 'long distance' may not mean the same to the patient as it does to you. The primary aim of examination is to assess the state of the ulcer, whether it is an acute, simple chronic, complicated chronic or a 'recurrent ulcer', in order to determine the line of treatment.

Take time to examine the affected foot with care. In addition, always examine the other foot, and in leprosy affected persons, both hands and both eyes. Look at the affected foot carefully for signs of infection, inflammation, swelling and deformity. Feel the skin for areas of increased temperature ('hot spots'); palpate the bones for thickening and tenderness; move the joints looking for instability and stiffness, and examine the posterior tibial neurovascular bundle, behind the ankle, for tenderness. Pain and tenderness at this site in a patient with a plantar ulcer, but no active leprosy, often indicates chronic inflammation of lymphatics running along with the posterior tibial vessels and nerve rather than posterior tibial neuritis due

to leprosy. Elicit the story of each and every scar. Finally, do not fail to examine the draining regional lymph nodes.

When you notice a deformity in the foot or toes, ascertain whether that was a consequence of previous episodes of ulceration. Find out whether the patient wears any footwear, its type and when she/he uses them. Many patients in rural areas use footwear only on some specific social occasions, like coming to a hospital. Have a good look at the footwear, check its pattern of wear and verify its fit and whether the footwear itself could have caused any damage to the foot.

Carefully examine the ulcer. Note the characteristics like its edges (e.g., scarred / hyperkeratotic / heaped up / rolled out / sloping and healing etc.), the floor (for the presence of slough, nature of the granulation - whether it appears normal, hypertrophic, very pale etc.), openings of sinuses and extent of fibrosis around the ulcer. Note the nature of the discharge from the ulcer, whether it is copious or

scanty, thick or thin, purulent or serous etc. Ask, and look for the presence of fine grains of bone ('bone sand') in the discharge. If sinuses are identified, probe them to identify their track and the presence of any sequesters in their depths. Finally, note whether the regional lymph nodes are enlarged and tender. The aim and details of management depend upon the type and the condition of the ulcer as identified by clinical examination. Figure 15-11 summarises the aims of management and the principles of treatment of the different types of plantar ulcers.

#### Management of acute ulcer

The goal of management at this stage is to control the effects of and limit the damage caused by acute infection and inflammation and convert the acute ulcer into a healing ulcer. The acutely inflamed ulcer with œdematous edges and dirty slough-covered floor copiously discharging smelling pus is changed to a clean ulcer having thin sloping margins, and its floor

Type of Ulcer	Aims and Principles of Treatment
<b>1. Acute Ulcer</b>	Control acute inflammation and convert acute ulcer into a "healing" ulcer and treat it as such, using elevation, cleansing, dressing and, if necessary, antibiotics.
<b>2. Chronic Simple, or, Healing Ulcer</b>	Allow the ulcer to heal, by providing appropriate dressing, and protecting from physical or chemical injury.
<b>3. Chronic Complicated Ulcer</b>	Eliminate complication and convert complicated into a "healing" ulcer and treat it as such.
<b>4. "Recurrent" Ulcer</b>	Identify the cause of recurrence of each ulcer and work out methods to eliminate it. Usually involves scar revision and / or abatement of load on the scar tissue plus special protective footwear.

**FIGURE 15-11** Aims and principles of treatment of different types of plantar ulcers.

covered with healthy granulation, scantily discharging somewhat gummy serous fluid indicating that the ulcer has entered the healing phase. This aim is achieved by: (1) elevating the part, (2) cleansing the ulcer, (3) establishing proper drainage, and, where necessary, (4) using suitable antibiotics. In order to apply the above, the patient with an acutely infected and inflamed (plantar or extra-plantar) ulcer should be admitted as an in-patient in a medical facility, put to bed and prohibited from walking. Minimal necessary investigations would include estimation of haemoglobin getting a radiograph of the affected part for assessing the possible presence and extent of bone involvement. Other investigations, like estimation of blood sugar, blood culture and culture from the ulcer for identifying the pathogen are done when indicated.

#### **Elevating the part**

An essential first step in the management of acute ulcers is elevation of the affected part. Elevation improves venous and lymphatic drainage and reduces oedema. Hanging the limb down adds to tissue tension (and pain) by gravitational effect. Persistent inflammatory oedema leads to fibrosis and contractures of the joints of hand or foot.

#### **Cleansing the ulcer**

Cleansing procedures aim at physically eliminating all necrotic tissue and particulate matter, foreign bodies like grit and other detritus as well as floating debris of dead tissue from the ulcer. Soaking the foot daily for about twenty minutes and then irrigating the ulcer with warm normal saline or a mild antiseptic solution will achieve this aim in a few days. Soaking and irrigation are done as often as necessary, twice or thrice a day if need be, depending on the amount of discharge from the ulcer. Whirlpool baths providing vigorous agitation

are very effective in mechanically cleansing acute ulcers. In between sessions of soaking-irrigation, the ulcer is covered with moist dressings, pieces of gauze soaked in a mild antiseptic solution. Deep ulcers, and those communicating with cavities, are loosely packed with a ribbon of gauze soaked in the cleansing agent. "Eusol" (Edinburgh University Solution) containing 1.25 parts each of chlorinated lime (calcium hypochlorite or bleaching powder) and boric acid for 100 parts (w/v) of clean, not necessarily sterile, water is very useful for cleansing purposes, for soaking, irrigation as well as dressing.<sup>4</sup> Eusol is an effective antiseptic and deodorant and is also much less expensive to make than the other antiseptic agents sold in the market. Eusol has a necrolytic action and the liberated nascent chlorine functions as a mild antiseptic even in the presence of necrotic organic matter.<sup>63</sup> Compared with the other buffered hypochlorite solutions like Dakin's and Milton's solutions, Eusol has a lower pH (7.5 to 8.5 cf 9.5 and 10.5 to 11.2) and is therefore less irritating to tissues, although it is not as tissue-friendly as the more modern but much more expensive preparations like hydro-gels and hydro-colloids.<sup>10,20</sup> Eusol should be freshly made, preferably daily; in any case at intervals of not more than once a week. Non-buffered hypochlorite solutions (e.g., chlorosol) are far more stable than the buffered ones and provide greater available chlorine (about 0.4% cf about 0.25%) but are highly irritating to the tissues as they have very high pH (about 11.5) and so are not used.

Other agents commonly used in moist dressing of plantar ulcers are: concentrated magnesium sulphate, glycerine-magnesium sulphate paste, acriflavine, mercurochrome and hydrogen peroxide. The first two are absorptive dressings as the chemicals used are hypertonic / hygroscopic. They absorb water from the wound and thus maintain a moist environment congenial for autolytic debridement and

wound healing. Hypertonic saline dressings would be equally effective. Acriflavine and Mercurochrome are used mainly for their antiseptic properties, but, except for being colourful and so impressive to the patient and others, they are virtually useless for that purpose as organic matter such as necrotic tissue inactivates them. The nascent oxygen liberated by hydrogen peroxide has an antiseptic effect but one should avoid using hydrogen peroxide for irrigating closed cavities for fear of complications like life-threatening oxygen embolism.<sup>2,43</sup> Cetrimide BP and chlorhexidine (Savlon™ is a combination of both) are efficient cleansing and antiseptic agents, effective in even low concentrations, and so quite useful as cleansing agents. But, in view of their deleterious effect *in vitro* on fibroblasts, they are better avoided for repeated use in clean ulcers as they may interfere with fibroblast activity essential for wound contraction and healing.

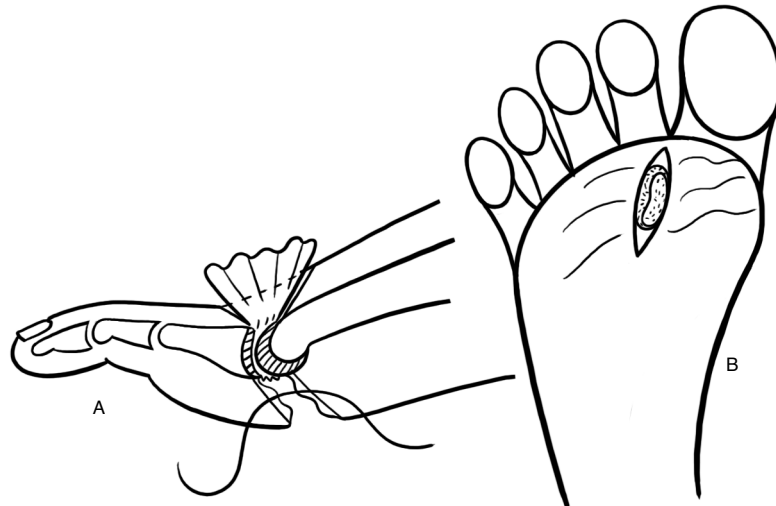
A variety of other cleansing agents and dressing materials such as polyvinyl film (permeable to O<sub>2</sub> and moisture but not to bacteria), hydro-colloids and hydro-gels, honey, sugar paste, Debrisan™ (a proprietary preparation of micro fine plastic granules that keeps the wound moist by capillary action), collagen sheets and a host of others have been tried in recent times in plantar ulcers of leprosy patients, persons with bed sores, burn wounds and foot ulcers in diabetic subjects.<sup>15,29,39,64</sup> All of them have been found to be 'effective' in obtaining 'early' wound healing. Even if the claims are valid, it is difficult to say at present how important a place they have in the routine management of ulcers in leprosy, especially in the field. It is also worth noting that a meta-analysis of 47 reports of 35 randomised controlled trials comparing the usefulness of a variety of cleansing agents in chronic wounds concluded "there was insufficient evidence to promote one ... agent over another".<sup>5</sup> We must also remember that, in many cases, plantar

ulcers in leprosy-affected persons remain unhealed not because some particular dressing agent has not been applied but because they have been neglected and not rested.<sup>56</sup>

### **Establishing drainage**

An important factor in the persistence of infection is damming up of pus in deeper tissues and spaces. Prompt draining away of the infected exudates without allowing them to accumulate is necessary for rapid elimination of infection. Ensuring proper drainage is achieved by surgery. However, extensive surgery involving wide opening up of tissue planes and spaces is contraindicated during the acute stage of the ulcer. Surgery is therefore confined to minimal necessary drainage procedures like incision and release of pent up pockets of pus, making counter incisions in non weight bearing areas for better drainage of deep cavities, removal of loosely lying slough and pieces of dead bone too large to be flushed out by irrigation and loosely packing the wound with gauze ribbon soaked in Eusol. In forefoot ulcers, with acute osteomyelitis of a metatarsal, a 5-cm long dorsal longitudinal counter incision over the maximally affected point to drain the infected site is a useful procedure. The ulcer is dressed from then on through this wound, to promote healing from below. After about two to three weeks of treatment along the above lines, when acute inflammation has subsided, surgical debridement is done (see later) and under antibiotic cover, it may be possible in carefully selected cases to close the plantar wound by sutures (if judged feasible) and continue dressing from the dorsum (Fig. 15-12). The ulcer is thus allowed to heal from the sole upwards. By this procedure one may be able to minimise the scar in the sole. Otherwise, it is treated as a 'chronic/healing ulcer'.





**FIGURE 15-12** Diagram of dorsal drainage procedure. **a.** Transverse section showing the extent of joint excision (hatched) and the dorsal corrugated drain. **b.** Elliptical excision of plantar ulcer, sutures in place but not tied (from Fritsch<sup>13</sup>, used with permission).

### Use of antibiotics

In the management of acute ulcers, the first general rule is “Do not use antibiotics as a routine”. The second general rule is “Do not fail to use appropriate antibiotics when needed”. The two rules are complementary and not contradictory.

Neuropathic ulceration in general is a chronic condition in the sense that episodes of ulceration and acute inflammation tend to occur repeatedly in many persons. The body defences are adequate to meet the situation and localise the infection in most instances. One can usually obtain control of inflammation, elimination of infection and healing of the ulcer with cleansing, drainage, dressing and debridement procedures alone, without the use of antibiotics. Routine and indiscriminate use of antibiotics randomly, especially in the absence of identification of the offending organism by culture and sensitivity studies, is sure to promote colonisation of the ulcer with antibiotic-resistant bacteria rendering the antibiotics useless when they may be needed urgently. Hence the

injunction against routine use of antibiotics.

Notwithstanding the above, appropriate antibiotics must be used when they are indicated. The stress is on ‘appropriate’ and ‘when indicated’. There are ‘absolute’ and ‘relative’ indications for using antibiotics. Absolute indications include life-threatening infective conditions like septicæmia, infection with highly virulent staphylococci and streptococci (necrotising fasciitis), and infection with clostridia. These conditions are medical emergencies in which aggressive antibiotic therapy is indicated for saving the life of the patient. The ‘relative’ indications are the presence of complications indicative of failure of localisation of infection like cellulitis, acute adenopathy of regional lymph nodes and systemic toxæmia. Antibiotics may also be needed in cases of involvement of deeper structures like underlying bones, joints or tendon sheaths. In these cases, the decision to use antibiotics depends on the extent, duration and severity of the local condition.

Plantar ulcers are often contaminated with

'street organisms' such as *Staph. aureus* and *E. coli*. That does not mean that they are necessarily the cause of the clinical condition. Culture-sensitivity results from surface swabs of the ulcer are, therefore, not very reliable guides for selecting the suitable antibiotic agent and so have limited value. To get more reliable information, one should culture the needle aspirate from the ulcer bed or from the biopsied tissue from the ulcer. The few reports in the literature on the bacterial flora in plantar ulcers do not always clearly mention whether the source of the culture material was from acute or non-acute ulcers, whether the ulcer was a recurrent one or a first occurrence and whether the swabs had been taken from deep inside the ulcer.<sup>9,11,14,31,61,66</sup> Therefore, the pattern of bacterial flora in different types of ulcer is generally unknown.

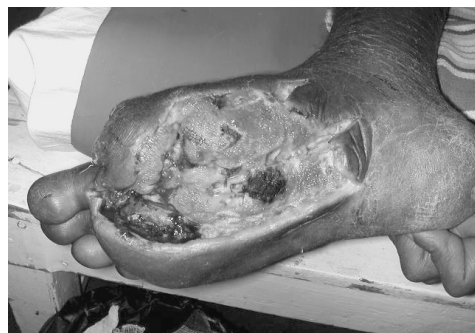Where the facility is available, one should always attempt to identify the causative pathogen in acute infections by culture of material taken from the depths of the ulcer and its antibiotic sensitivity and administer an appropriate antibiotic or combination of antibiotics. When not available one should use a newer broad-spectrum antibiotic such as the newer penicillin derivatives, quinolones, or a combination of antibiotics, to cover both gram positive and negative organisms.

The acute ulcer will become a 'healing ulcer' in two to three weeks of treatment. All the signs of acute inflammation will have subsided; the discharge will have diminished to scanty, gummy, serous ooze; the floor of the ulcer, now free of all slough, will consist of pink, healthy granulation tissue; and the edges of the ulcer, from being oedematous and inflamed, will have become sloping with bluish epithelium creeping over healthy granulation tissue. Management of a 'healing ulcer' is almost the same as that of 'Chronic (simple) ulcer', except that we need not scrape the ulcer. If any of the above signs are not found, i.e., if inflammation persists, or, purulent discharge

continues, or, there is no evidence of healing, then this suggests the presence of an underlying complication hindering healing. In that case, the ulcer is to be re-evaluated and treated as a "complicated ulcer".

### Management of Chronic (Simple) Ulcer

A chronic ulcer, as its name indicates, is one that does not heal easily and even if it heals, it may take a long time to do so (Fig. 15-13). Broadly speaking, there are two reasons for the ulcer not to heal. The ulcer may not heal because of the presence of a complication that interferes with healing, like persistent infection (usually in a deep structure like a bone or a joint), in which case it should be seen as a 'complicated ulcer', or, the ulcer has not been allowed to heal. These, chronic 'simple' ulcers, do not heal because they have been prevented from healing by absence of rest and unprotected walking. Under those conditions, the delicate epithelium growing over the granulation tissue is physically ground down and destroyed by the stresses generated during walking.



**FIGURE 15-13** Late stage of a plantar ulcer.

'Chronic simple ulcers' are quiescent ulcers (i.e., not acutely inflamed), which are also usually superficial. They are usually painless, a few millimetres deep, have punched out appearance, with heaped up hyperkeratotic margins, and have a floor of pale granulation covered with whitish film of fibrin or a thin

layer of greyish necrotic tissue. Florid or exuberant granulation tissue, protruding from the ulcer ('proud flesh'), indicates the presence of sequestra or foreign bodies deep inside the ulcer. The ulcer bed feels hard because of heavy scarring due to previous episodes of ulceration. There is little discharge from the ulcer, just a spotting of slightly turbid sticky fluid or slight blood staining of the dressing. Pedal pulses are normal. Absent pedal pulses, very pale granulations and practically no bloodstaining would suggest ischemia as the reason for the non-healing of the ulcer. The chronic simple ulcer is best treated by applying a below-the-knee plaster of Paris cast after cleaning the ulcer.<sup>3</sup> This method of treatment of plantar ulcers in leprosy patients was first described in the literature in 1939, and its usefulness confirmed a few years later.<sup>16,19</sup> It became the standard method of treating plantar ulcers, all over the world, only in the '60s after Price published this technique.<sup>30</sup> The moulded inner shell of the plaster cast minimises the vertical pressures (compression load per unit area) over the ulcer. By making the sole rigid and by connecting the leg and the foot rigidly, deformation of the foot, during walking, is minimised and the foot gets 'physiological rest'. By avoiding repeated dressing and not allowing any other kind of interference with the ulcer, the process of epithelialisation is protected and healing is promoted.

The ulcer is cleaned with normal saline and dressed with wet saline gauze for a couple of days. It is then gently scraped, with a periosteal elevator or a 10-blade knife, to remove any surface debris and the edges of the ulcer are thinned by tangential shaving off of the thick hyperkeratotic tissue. The ulcer is then covered with a layer of sterile vaseline (petrolatum) gauze, which is packed from above with small pledgets of moist (but not soaking wet) cotton wool so that the Vaseline gauze conforms to the contours of the ulcer and no dead space is left

between the gauze and the ulcer. The limb is encased in an adequately, but thinly, padded, well-moulded, below-the-knee plaster cast (see Appendix D). After 48 to 96 hours, when the plaster cast has dried well (not just hardened but it should have completely dried, as it would break otherwise) it is converted into a walking plaster cast by adding a walking wooden rocker sole. At this stage, it is better to cover the toes completely with a toe cap (after padding the part and allowing sufficient room on the top of the toes for them to bend at their middle joint without rubbing on the toe cap) using plaster bandages. That prevents the front end of the cast shovelling sand and gravel into the cast under the foot. The patient is instructed regarding recognition of a tight plaster cast, how to take care of the limb and the cast, and is then permitted to walk. It is best to measure the feet for appropriate footwear before the plaster is applied and keep them ready for use by the time the cast is removed. Usually, the plaster cast is removed after six weeks, by which time the ulcer should have healed completely. Occasionally a small raw area may still be present that may be treated with a second plaster cast as before or with sticking plaster dressings, without recourse to plaster casting.

#### **Sticking plaster dressing technique**

If for any reason the patient refuses to have the plaster cast, especially when the ulcer is small (< 10 to 12 mm) and not deep (i.e., does not extend deep to the deep fascia), or, a plaster cast is not advisable due to poor skin condition, or, we cannot give the cast for some other reason, it is best to resort to the "sticking plaster technique" for treating the ulcer. In this technique, the ulcer is cleaned and the surrounding areas are mopped completely dry (this is very important as the tape will not stick to moist skin), and narrow (3 or 4 mm wide), overlapping strips of ordinary zinc oxide adhesive plaster (coated with ZnO<sub>3</sub> paste) are laid

## 212 Surgical Reconstruction & Rehabilitation in Leprosy

directly over the ulcer without any intervening gauze piece or medication.<sup>59</sup> The plaster strips should extend for at least 15 cm, all round, beyond the margins of the ulcer. If the adhesive plaster spans the ulcer, because of its depth, leaving a dead space between the ulcer and the plaster, packing the top of the plaster with small pledgets of cotton wool, or small wads of gauze, and using a bandage or larger pieces of sticking plaster to retain them in position will eliminate the dead space and establish total contact between the ulcer and the plaster strips. The outer bandage may be changed daily or as often as necessary. However, the adhesive plaster dressing is not removed daily but kept on for four to seven days, or, till it starts peeling off. The oily exudate is wiped clean, the ulcer is mopped dry and dressed with adhesive plaster strips, exactly as before. The patient is instructed to keep the plaster dressing as long as possible, avoid walking as much as possible and if the foot gets wet, mop it dry, without removing the sticking plaster strips, at the earliest opportunity. When the foot gets dirty, it is washed well and mopped dry only. Apart from these instructions, there are no other prohibitions. In fact, patients may be given the plaster strips to take home, after teaching them and a member from their family the correct way to apply the sticking plaster strips.<sup>22</sup> This technique is very useful, particularly in the field. This useful mode of treating plantar ulcers, was first discussed in connection with venous ulcers by Gilje in 1948 and applied successfully to treat burn wounds and popularised for use in ulcers in leprosy in the late '70s and early '80s by Stenström.<sup>30,57,60</sup> It was described originally by Paul in Sri Lanka for treating ulcers in leprosy patients in the 1930s!<sup>32</sup>

Under treatment, using the sticking plaster technique, the ulcer undergoes autolytic debridement and it heals completely, in the moist environment, in three to eight weeks.

The delicate epithelium covering the newly formed scar needs to be protected (with sticking plaster, cotton wool and bandage) for another three weeks or so before exposing it to direct weight bearing in footwear.

### Use of skin grafts

Healing of large (>20 mm) simple ulcers is significantly hastened by covering them with split-thickness skin grafts (medium-thickness, preferably from the instep), after cleaning them up and scraping them. The graft takes in two weeks, but it should be protected for another three to four weeks. Even if the graft does not take, it serves as the perfect dressing for the raw area and the ulcer heals under it. It should be noted that there is great shearing strain at the graft-skin junction because of the difference in the thickness of the two structures and this junction dehisces in course of time. Therefore, it is best to replace the split-thickness graft at the earliest opportunity with a full-thickness skin graft, taken preferably from the dorsum of the foot.

Innumerable methods of treating plantar ulcers are found in medical literature, ranging from local use of a variety of antibiotics, anti-septic agents, vitamins, other chemical, biological and plant extracts, anti leprosy drugs and their derivatives, vasodilators, surgery for improving blood flow in the foot to stretching and surgery on the posterior tibial nerve and perineural injections of vasodilators and other chemicals, magnetotherapy and homeopathy all claiming good results.<sup>8,38,39</sup> For a critique of such practices readers may consult the papers by Price and Srinivasan.<sup>36,37,54</sup> Evidently, if any attention is paid to the ulcer, it will usually heal.

We must bring home to the patient that healing is only one stage in the natural history of the ulcer, the next stage being recurrence of the ulcer, that recurrence is not inevitable and that the patient's efforts are needed to achieve that. Therefore, the patient's responsibility to

take care of the foot does not diminish or disappear with getting the ulcer healed. In fact it increases and it becomes even more important that he/she should continue to use protective footwear (indoor as well as outdoor) besides taking other protective foot-care measures. Otherwise, the ulcer is most likely to recur and each bout of recurrence makes it that much more difficult to heal it subsequently.

### Management of (Chronic) Complicated Ulcer

One reason for the non-healing of an ulcer is the presence of a complication. The most common complication is the continued presence of a focus of non-specific infection in a deeper structure, which has become infected from the ulcer. Healing is significantly retarded when a sufficient bacterial load (>10<sup>5</sup> bacteria per gram of tissue) is present. Breakdown of the wound and delayed healing occur when there is 'invasive infection, not just colonization of the ulcer'. The non-specific infection may thus persist in an underlying bone or joint or improperly drained tendon sheath or soft tissue space. This deep site of infection communicates with the exterior through one or more sinus tracks and the wound gets constantly re-infected from the deep pocket. The infection destroys the epithelium, effectively preventing healing of the ulcer. It is evident that we can get the ulcer to heal only if we get rid of the deep focus of infection and this is achieved through surgical debridement. One should attempt to locate the focus of infection by careful clinical examination, systematically examining the whole foot, not just the ulcer site, and all the structures likely to be involved such as bones, joints, tendon sheaths and plantar tissue spaces. Radiographic examination is equally important and that should always be done without fail.

### Debridement

In the technical jargon of people working in the

field of management of chronic wounds, the term 'necrotic tissue' refers to dead tissue that looks black and is adherent to living tissue, 'non-viable tissue' refers to creamy white stringy non-living tissue that is loosely adherent to live tissue, 'cleansing' is removal of foreign matter from the ulcer and 'debridement' is removal of non-viable tissue from the wound. Based on the means used, ulcer debridement has been described as autolytic, biochemical, mechanical and sharp or surgical.

In *autolytic* debridement we make use of the body's own ability to digest and dissolve non-viable tissue. Occlusive and semi-occlusive dressings, left in place for a few days allow accumulation of the exudates from the wound and permit concentration of white cells, enzymes like elastase and growth factors which help clearance of the necrotic material and promote healing. In adopting plaster of Paris casting and using the sticking plaster technique of dressing chronic ulcers, we are using autolytic debridement to get the ulcer healed.

*Biochemical* debridement is achieved by using enzymes to digest and dissolve the non-viable tissue. This is particularly useful in sites that are difficult to access for sharp or surgical debridement.

*Mechanical* debridement is achieved by using the so-called 'wet-to-dry dressing' technique. A moist coarse-meshed gauze is used to cover the wound and it is allowed to dry. Later when the gauze is ripped off, necrotic tissue adherent to the gauze comes off along with the gauze.

In *sharp* or *surgical* debridement the necrotic tissue is removed by sharp dissection using knife and scissors.

Those specialising in treating chronic ulcers, especially burns, decubiti (bed sores) and chronic venous stasis ulcers in the leg have developed the above terminology. Leprosy workers do not make such fine distinctions in terminology while dealing with plantar ulcers.

## 214 Surgical Reconstruction & Rehabilitation in Leprosy

Generally, 'biochemical' and 'mechanical debridement' are not used in leprosy. We use the word 'cleansing' to refer to non-surgical methods of cleaning up an ulcer. "Debridement" is used more as in the context of acute traumatic wounds to denote surgical cleaning of the ulcer to get rid of all dead and doubtfully viable tissue and hopelessly infected tissue as well as any foreign matter that may be present in the ulcer.

*Surgical debridement.* A chronic ulcer develops a micro-environment that is hostile to wound healing and different from that of an acute wound.<sup>66,67</sup> The exudates have a diminished amount of growth factors and the macrophages are less responsive to carry out repair due to senescence, proteolytic activity is increased and there is bacterial contamination in these wounds.<sup>58,65</sup> All these factors adversely affect wound healing. Furthermore, necrotic tissue is a very good medium for bacterial growth; and the persistent inflammatory activity that results delays the healing process, preventing it from moving on to the next stage of wound repair. It is logical, therefore, to eliminate these hostile environmental factors by surgical debridement and convert the chronic ulcer into an acute wound that has greater potential for healing.<sup>12</sup>

Surgical debridement is the technique of ridding an ulcer of dead and doubtfully viable tissue and foreign material, using surgical dissection in order to achieve healing of the ulcer. This is not a bedside procedure like "scraping the ulcer". During the procedure, every part of the ulcer is systematically attended to as described below.

*Ulcer margin.* Excise a thin (ca. 1 to 1.5 mm) rim of the edge of the ulcer cleanly using a size 10 or 11 blade knife to get a freely bleeding edge for the ulcer; and thin the thickened and hyperkeratotic margins of the ulcer by tangentially shaving off the superficial layers of the skin, using size 10 blade knife.

*Floor of the ulcer.* Curette the floor of the

ulcer thoroughly using a sharp Volkmann's curette or the sharp edge of a curved periosteal elevator, removing in the process all dead and devitalised tissue and unhealthy granulation as well as any foreign matter like grit, sand particles, thorns and splinters. Control any bleeding with hot gauze packs. The base of the ulcer is now exposed.

*Base of the ulcer:* Examine the base of the ulcer visually and by probing carefully for openings of sinus tracks, curette the sinus tracks thoroughly and fully lay them open. Search the deep ends of the sinus tracks for pent up pockets of infection like abscess cavities in bones, joint spaces, tendon sheaths and tissue spaces. These are thoroughly curetted and spiky or rough bone ends are trimmed. Infected tendon sheaths should be curetted in their entirety and proper drainage ensured by appropriate and adequate counter incisions. In the process of dealing with the base of the ulcer, remove all badly infected soft tissue as well as pieces of sequestra and small grains of dead bone ('bone sand') and the rough surfaces of infected ends of bones. In the case of ulcers under the head of the first metatarsal, if found infected and deformed, one should not hesitate to excise the concerned sesamoid bone(s) in toto. At the same time, one should be careful not to remove too much of normal and near normal tissue in the process of debridement. The guiding principle in carrying out surgical debridement is: "*Ruthless excision of all dead and devitalised tissue, but careful conservation of all healthy tissue*". At the end of the procedure, a badly draining deep ulcer with infected sinuses and deep foci of infection will have been converted into a healthily bleeding, freely draining, clean and comparatively shallow wound.

*Counter incisions:* Wherever felt necessary, one should not hesitate to make adequate counter incisions in order to ensure free drainage. Counter incisions are usually needed over the

dorsum of the foot, sometimes along the sides of a toe or the foot, over the proximal part of a tendon sheath, below the ankle or in the region of the tarsal tunnel for draining infected long flexor tendon sheaths.

*Dressings:* After completing surgical debridement, the wound is dressed with one layer of Vaseline (petroleum jelly) gauze overlaid with pledgets of moist gauze (in order to eliminate dead space between the wound and the Vaseline gauze), and covered with bulky gauze dressing. The wound is subsequently dressed

once a day for a few days and when the discharge from the wound becomes mere blood staining of the gauze, the limb is encased in a below-the-knee plaster of Paris cast. The cast is retained for at least six weeks. In most cases the wound would have healed by that time. If not, another plaster cast may be applied and retained for another four weeks or longer depending on the state of the residual ulcer. If it is a small, superficial and healing wound we may use the sticking plaster technique described earlier without resorting to a cumbersome plaster cast.

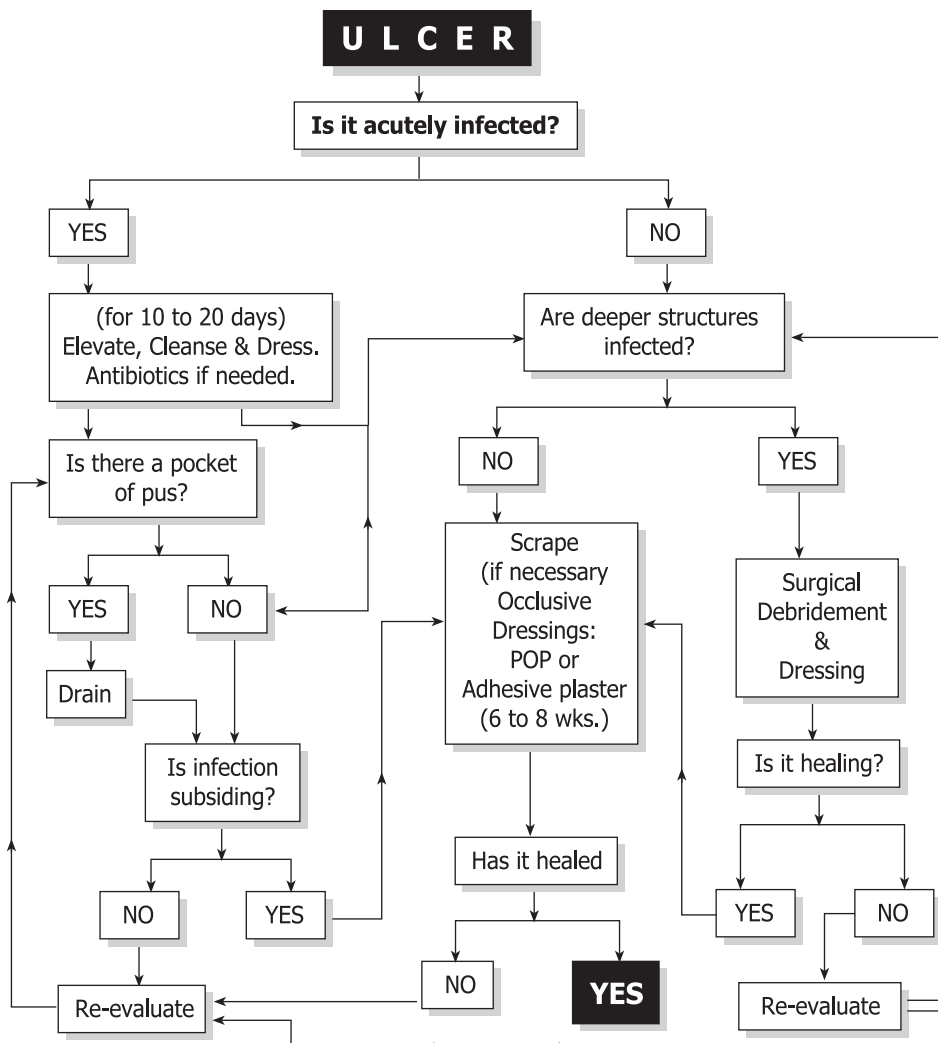


FIGURE 15-14 Decision Tree for the Management of Plantar Ulcer.

A summary of the management of plantar ulcers is shown in Figure 15-14. While it does not include all contingencies, it shows the major approaches to the management of plantar ulcers. It should also be noted that, in order to avoid complicating the chart further, it does not cover the problem of recurrent plantar ulceration and occasional complications like malignant degeneration.

### **Other complicating factors**

Sometimes, some other feature besides local spread of non-specific infection complicates the situation. The complicating factors include neoplastic degeneration, septicaemia, clostridial infections and deep fungal (and pseudofungal) infection.

*Neoplastic degeneration.* Chronic ulcers are known to undergo malignant transformation and plantar ulcers are no exception. It is not a very common occurrence and probably not more than 1 to 2 % of plantar ulcers seen in a leprosy hospital will be malignant. Malignant plantar ulcers usually present as 'cauliflower growths' (CFGs), which are proliferative fungating lesions developing in a fairly long-standing ulcer of a few years' duration (see Chapter 18).<sup>40,42</sup>

*Septicaemia.* In patients debilitated by inanition, or, in the concomitant presence of debilitating conditions like diabetes or tuberculosis, generalised septicaemia may develop. The condition must be treated promptly and aggressively with parenteral antibiotics and supportive measures, as emergency. Surgery is limited to necessary drainage and debridement procedures only.

*Deep fungal infection.* Occasionally, the plantar ulcer is complicated by concomitant development of mycetoma ('Madura foot') due to deep (subcutaneous) fungal or pseudofungal infection such as actinomycetes and Nocardia. Considering that chronic plantar ulcers provide excellent opportunities for infection by

these organisms, such infections are surprisingly rare and only a few case reports are found in the literature.<sup>18,21</sup> In view of its infrequency, there is not enough published information to suggest which one, the mycetoma or the plantar ulcer, is usually the primary lesion and even whether they are related to one another at all. It should also be mentioned that heel ulcers presenting with chronically infected calcaneum and gross thickening of the bone, fibrosis of soft tissue and multiple sinuses around the heel area, clinically indistinguishable from mycetoma, are far more common than mycetomas. In these cases, the diagnosis of mycetoma must be established by diligent search for fungal colonies (white, yellow or black "granules") in the discharges and scrapings from sinuses or by biopsies of deeper tissues.

Prolonged antibiotic therapy and anti fungal medication, for at least six to ten months, combined with repeated debridement of sinuses and abscess cavities in the bones and soft tissues are required for getting rid of these infections.

*Clostridial Infection.* A chronic wound, especially in the foot, is always in danger of infection with clostridia, especially with *C. tetani*, but the patient rarely develops local or even general tetanus. Occasionally, gas gangrene may supervene. The patient is in a state of toxæmia and collapse and the condition is characterized by severe toxæmia, swelling of the part, crepitus in the subcutaneous tissue and muscles and translucent areas delineating muscles and tissue planes in the radiograph. There is thin bloody discharge from the ulcer and necrotic patches in the limb. While swabs are taken for bacteriological diagnosis, one does not wait for the results to start treatment. Treatment is started on clinical diagnosis. This is a surgical emergency carrying a grave prognosis and calls for emergency amputation, aggressive administration of antibiotics and supportive therapy.



### Management of Recurrent Plantar Ulcers

Recurrence of plantar ulceration is so common a feature that it is “normally” expected to occur. Most people would consider healing as just one stage in the natural history of the ulcer, the next being its recurrence. This is a defeatist view, which could have been valid half a century ago, but not now. It should be emphasised that recurrent ulceration is a preventable condition in almost all instances if the problem is tackled rationally, diligently and with optimism, applying practices of orthopædics, podiatry and plastic surgery. We should also remember that management of plantar ulceration always has two aims: (a) an immediate aim to get the ulcer healed, and (b) a long-term aim, to ensure that it does not recur.

Recurrent plantar ulcers are of two general types: 1. those that recur because the affected person has not taken normal precautionary preventive measures, and 2. those that recur despite adequate precautionary measures. Most of them belong to the first category and, for their prevention, they require diligent practice of ulcer-preventive practices by the affected persons. However, in a small proportion of patients, the ulcer has already recurred a number of times (because of earlier negligence) and the tissues have suffered such severe damage that ordinary or standard preventive measures are inadequate to prevent recurrence. This type of recurrent ulcers needs additional measures, by way of surgery and/or special footwear, besides standard foot-care practices for their prevention.<sup>56</sup> These are the ‘true recurrent ulcers’ and their management is discussed in this section.

#### Causes of recurrent ulceration

Plantar ulcers recur for the following four reasons:

1. *The original causes continue to operate.* The conditions that originally contributed to the

development of the ulcer continue to be present. They are: denervation and consequent insensibility and dryness of plantar skin, with or without plantar intrinsic muscle paralysis, combined with unprotected and unlimited use of the feet. If normal plantar tissue, structured to withstand walking strains, gave way under these conditions originally, it is not surprising that scar tissue, which is not structured to withstand walking strains, gives way again and again. This is the first kind of recurrent ulcer mentioned earlier. The remedy here is to follow ulcer-preventive foot-care practices, including the use of appropriate protective footwear, diligently.

2. *The scar tissue is of poor quality:* Because of repeated bouts of ulceration and healing the scar at that site becomes dense, brittle, ischaemic and unstable, ready to breakdown even under conditions of less than normal loading. In some feet, the scar is of such poor quality that taking literally half a dozen steps, even with protective footwear, is sufficient to make it breakdown and cause recurrence of the ulcer. The remedy here is to improve the quality of load-bearing tissue, by tissue replacement, or, protect the scar, by some means, preventing the load falling on the scar.

3. *The scar is loaded excessively.* The scar tissue that replaces the normal, finely loculated, subcutaneous fat layer lacks the latter’s springiness and shock-absorbing cushioning effect. Repeated infection or neuropathic bone disintegration may distort the local anatomy by destroying local structures, and these changes result in excessive loading of the scar tissue. This, inevitably, causes early breakdown of the scar and recurrence of ulcer. The remedy here is to protect the scar by modifications in the footwear or by surgically realigning anatomical structures such that the scar is relieved of much if not the entire load.

4. *There is a periodic flare up of infection.* Lastly, as with infection in the larger bones, infection in the bones of the foot also tends to persist and flare up periodically, with opening up of old sinuses and ulcers and formation of new ones. This kind of acute-on-chronic osteitis happens particularly in feet with infection of the calcaneum or some other major tarsal bone like the cuboid, sometimes in feet with infection of the metatarsal head. Often a minor injury triggers the episode, most probably by producing a local hæmatoma, which would permit an invasive proliferation of the pathogenic organism. The remedy for preventing recurrence of ulcers from this cause is to eradicate the infection with aggressive treatment using all available methods viz., cleansing, repeated surgical debridement and adequate use of effective antibiotics. Occasionally, one may have to resort to radical surgery to get rid of the infected focus. Thus, subtotal resection of the calcaneum (excising much of the body of the calcaneum, leaving behind only the talo-calcaneal joints with some bone underneath) has been found very useful to eliminate the hopelessly infected sclerotic bone not amenable to antibiotic therapy.<sup>52</sup> After this procedure, the patient can walk with any type of footwear in which the heel is built up and cushioned.

We can avoid recurrent ulcers by a) having the patient diligently practising foot-care procedures including constant use of appropriate protective footwear and b) eradication of infection locally. If the ulcers still recur, the foot is evaluated afresh and, depending on the local condition, c) replacement of the scar with better quality tissue and, d) use of surgical and non-surgical measures to relieve the load on the scar will help prevent recurrence of these ulcers.

**Foot-care (see also Appendix C)**

The denervated feet of affected persons are substandard structures, both structurally and

functionally, and they require special care measures to maintain their integrity without which they will invariably breakdown. The dry, anhidrotic and insensitive plantar skin (sole) should be cared for properly to avoid development of cracks and fissures, which are precursors to ulcers. Further, in many leprosy-affected persons, the foot is structurally weakened because of muscle paralysis and walking with such weakened feet without protective footwear damages the plantar tissues, especially the subcutaneous fatty layer that acts as shock-absorbing cushion, and causes ulceration. Therefore, we need 1. 'skin care' practices to keep the skin intact and avoid it breaking up, and 2. 'walking-care' practices to permit walking without exposing the foot to the danger of ulceration.

1. 'Skin care' practices have two different aims: a) keeping the skin soft and supple. Otherwise the denervated, dry skin develops cracks which become portals of entry of infection leading to ulceration; and, b) protecting the insensitive skin from being wounded from without. The first aim of keeping the sole soft and supple is achieved by the procedure of daily soaking, scrubbing and smearing with oil. The foot is soaked in soapy water or saline for ten minutes, the sole is scrubbed with a pumice stone or any similar object with a rough surface to scrape off superficial keratin layers, washed, mopped to remove the excess moisture and smeared with some oil, preferably one which will not attract ants and other vermin (e.g., neem (margosa) oil or castor oil). This procedure should become a daily habit, like brushing one's teeth. If the patient can afford it, moisturising lotions could be used, though this is less effective than soaking and oiling. The second aim of preventing wounding of the sole (by nails, thorns, sharp stones or hot surfaces) is achieved by using footwear with tough soles. Such footwear should be worn, preferably all the time one is on one's

feet or, at least every time the person goes out of the house, and not just on some special occasions (like going to the weekly village fair or going to the town for seeing a cinema), as is the habit with some people. While leprosy institutions provide their clients footwear with tyre soles for this purpose (because of considerations of cost), those who can afford it can use commercially available modern, lightweight, durable and tough soles made of synthetic material. While plantar skin is protected by footwear, using gloves when handling hot or rough objects protects palmar skin. This topic is dealt with in detail elsewhere.<sup>55</sup>

2. *Reduction of walking strains.* The second aim of protecting the feet from walking strains is achieved by two strategies namely: a) reducing the duration of walking, avoiding walking long distances and using a vehicle if one has to do so; and b) using appropriate protective footwear (with suitable modifications and inserts depending on the local condition of the foot) in order to reduce the strains on the feet during walking.

When the foot is merely anaesthetic, as mentioned earlier, the foot only needs to be protected from being injured from without and this is achieved by having a tough outer sole to the footwear. Where there is plantar intrinsic muscle paralysis in addition, a shock-absorbing, pressure-reducing modification is needed and this is achieved by the addition of a soft springy insole to the footwear. Microcellular rubber (MCR) that will mimic the action of the normal subcutaneous layer in the sole of the foot is the material most often used for this purpose. The average hardness of the normal (unscarred) human sole is about 20 shore 'A' (personal observation in South Indian patients who were not using footwear as a routine). MCR of similar, or preferably slightly less (say, 15 shore A), hardness is to be used in the routine footwear intended for leprosy affected persons having plantar intrinsic muscle paralysis

besides loss of sensibility in the sole. If the foot has already had ulcers, the scar may be protected by additional modifications such as a rigid sole-rocker, metatarsal bar, extended heel or arch support (Chapter 17).

#### Improving quality of scarred site

Durability of the scarred weight-bearing site is obtained by replacing the unstable scar with tissue of better quality, or by shifting the scar to a non-weight-bearing locale. Figure 15-15 lists

#### Scar excision and wound closure by:

- Suture or skin graft
- Local flap or distant flap
- Island pedicle flap or free flap, or,
- Shifting scar to non-weight-bearing site

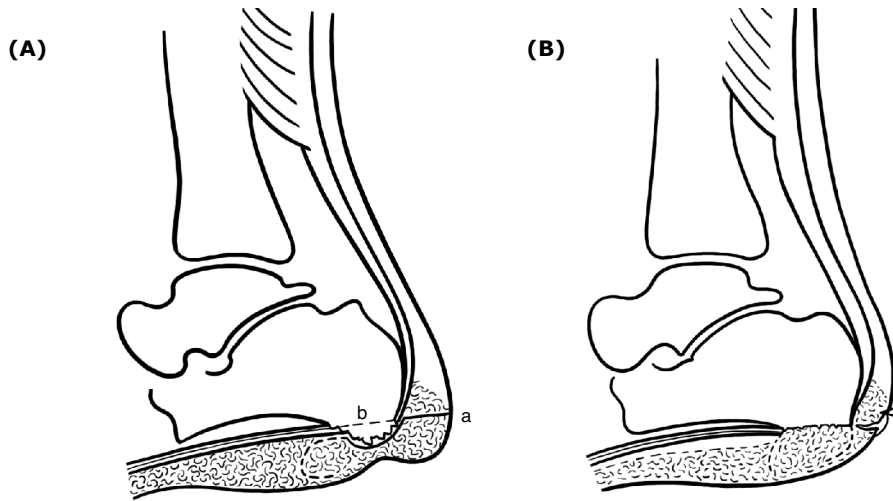
**FIGURE 15-15** Means of improving scar sites.

the common methods of achieving this aim.

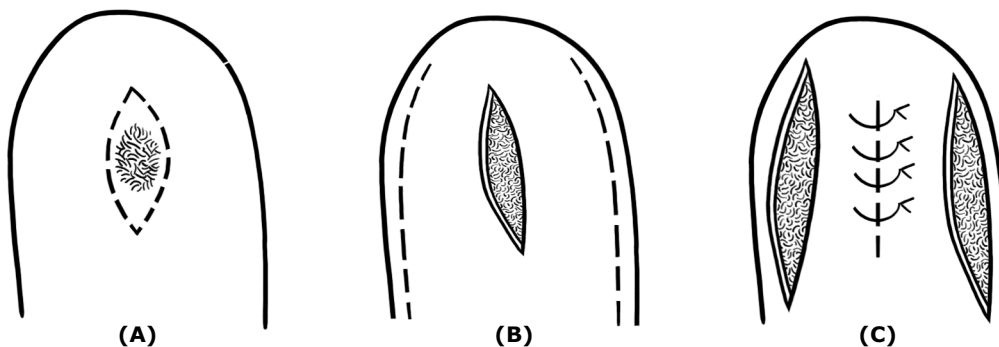
Where feasible the scar is excised, the wound edges are undermined and the wound is closed by direct suturing. If possible, a subcutaneous fat flap may be interposed between the scar and the deeper tissues in order to improve the shock-absorbing quality of the weight-bearing site.<sup>46</sup>

When closure by excision and re-suture is not feasible, skin grafting may be done to cover the raw area. Depending on the local condition, we may use split-thickness or full-thickness skin graft. Split-thickness graft may be taken from the sole itself, from a non weight-bearing area like the instep. The dorsum of the foot is a good donor site for full-thickness skin graft in the sole of the foot.

*Use of local flaps.* Using a local flap, mobilised from around the ulcer may be a better way to cover the raw area resulting from excision of the scar. This has the advantage of providing tissue very similar to the one that was lost due to ulceration. Small to medium sized unstable adherent scars in the middle of



**FIGURE 15-16** Improving scar site. Schematic illustration of the procedure: Interposition of subcutaneous fat flap between bone and skin combined with bumpectomy to reduce load on scar in heel. **A.** a) incision for exposure. b) level of bump excision. c) incision for mobilising subcutaneous fat flap. **B.** Following completion of the procedure.



**Figure 15-17** Scar excision and skin closure in heel using a bi-pedicle (bucket handle) flap **A.** Scar in heel and incision for excising the scar **B.** Scar excised; incisions in the margins of the heel for mobilising bi-pedicle flaps. These incisions should be longer than the gap in the skin and should be made in the non weightbearing area **C.** Bucket handle flaps mobilised and central gap closed without tension to provide a linear (and stable) scar in place of the broad, adherent (and unstable) scar.

the heel are so excised as to give an antero-posteriorly oriented oval or lens-shaped wound. This wound is then closed by raising two bucket-handle flaps from the two sides of the central wound, by making two release incisions, one on each side of the lateral margin of the heel, and suturing them together to provide a linear scar in place of the earlier unstable broad scar (Fig. 15-17).

The release incisions made for raising the

bucket handle flaps should be longer than the central wound in order to ensure tension-free closure.<sup>50</sup> An adherent and unstable scar under a metatarsal head may be excised and closed in his manner except that here the wound created by excising the ulcer is transversely oriented and the release incision (which should be longer than the wound to be closed) is also made transversely, about 20 mm to 25 mm anterior to the wound, just a few millimetres

proximal to the creases at the bases of the toes.

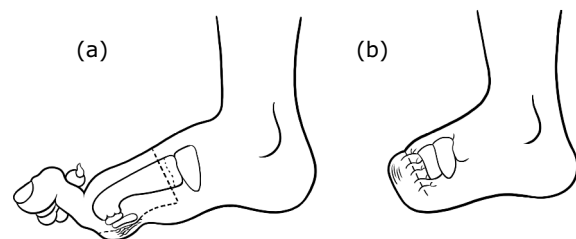
Another way of raising a local flap of good quality to replace a scar is to fillet a toe (i.e., remove all the remnants of phalanges in the toe leaving behind only the soft tissue) and use the now available skin of the toe for closing the raw area created by excising the unstable scar (Chapter 16). This procedure is indicated when the unstable scar is located under the head of a metatarsal, whose toe (or its neighbour) has become a functionless flail appendage and a positive nuisance while wearing footwear because of previous ulceration. Instead of amputating and discarding such a toe, it may be filleted and the soft tissue used for scar replacement as mentioned above.

We may also use a rotation flap to cover the raw area resulting from excision of an unstable scar. The scar is excised using a triangular incision and one side of the triangle is extended as a widely sweeping curve. A back cut of adequate length is made, sufficient to mobilise the flap to fully cover the wound created by scar excision but not so long as to endanger the blood supply of the flap. The flap is rotated to cover the raw area and sutured, using, if necessary, a free skin graft to cover any raw area in the region of the back cut.

The local flaps mentioned thus far are within the capabilities of a competent surgeon interested in this kind of surgery. There are other flaps, local and distant, like artery pedicled island flaps and composite (free) flaps, which have been found useful in dealing with recurrent ulceration, but they require specialist (plastic / microvascular) surgical expertise (Chapter 16).<sup>23-27</sup>

*Shifting scar to non weight-bearing site.* When the ball of the foot is badly scarred and normal protective precautions by way of foot-care and walking-care, including modifications in the footwear, are unable to prevent the breakdown

of the scar, one may resort to diverting the body weight away from the scar (e.g., patellar tendon bearing (PTB) orthosis), or, diverting the scar out of the way of body weight. We may achieve the second aim by doing a transmetatarsal amputation (bone section just distal to the bases of the metatarsal bones) and closing the wound using a long plantar flap incorporating the unstable scar near its distal end. When the flap is turned over to cover the wound, the scar is automatically shifted to the dorsum or the front end of the foot, escaping weight-bearing, and weight is now borne by



**FIGURE 15-18** Transmetatarsal amputation for preventing recurrent forefoot ulceration.

**a.** Grossly deformed toes and unstable and adherent forefoot scar. Interrupted line shows skin incision to give a long plantar flap. Dotted line shows the level of bone section, preserving the proximal one-inch of the metatarsal.

**b.** Amputation completed. Note suture line is on the dorsal side and the scar has been shifted to a non-weightbearing site of the foot.

normally structured plantar tissue (Fig. 15-18).

### Reducing stress on the scar

Another reason for frequent recurrence of the plantar ulcer is that the scar, which is already of poor quality, is further subjected to excessive stress during walking. The site of excessive stress and its relation to the scar may be demonstrated by taking footprints, preferably using a Harris mat, but they can be taken even without it. The scar may be relieved of excessive stress by introducing modifications in the footwear or by surgery (Chapter 16, 17).

## CONCLUSION

It should be made clear that there are no set solutions, like cookery recipes, telling us what to do for a given ulcer, because each foot, and each ulcer in a given foot, has a unique history and morbid anatomy of its own. Nevertheless, with the knowledge of the varieties and patterns of stress and loading that a foot is subject to during standing and walking, one can work out a solution for relieving the particular stress in the given case. This means that one should examine the foot very carefully, and study each ulcer in that foot, develop a plausible hypothesis about how the ulcer is stressed during standing and walking and, work out a method of eliminating that stress based on that hypothesis.<sup>48,51</sup> The following case summaries illustrate this approach.

**CASE 1.** PRN (male, 37 years). Problem: Frequently breaking down ulcer in the region of proximal phalanx (area between the two digital creases on the plantar surface) of right big toe. Ulcer starts as a crack in the old scar, and the crack widens into an ulcer. No involvement of bone or tendon sheath or chronic local infection. Plantar anaesthesia present. No plantar intrinsic paralysis. Hypothesis: The relatively unyielding scar gets unduly stretched during walking causing it to breakdown. Proposed solutions: 1. Replace scar with tissue that can stretch better or, 2) eliminate the stretching stress by making the plantar tissues of the big toe lax, by shortening the skeleton of the toe.

The second solution was adopted and excising the distal half of the proximal phalanx shortened the toe. Follow-up 18 months later showed no recurrence of the ulcer.

**CASE 2.** RK (male, 28 years). Problem: Frequently recurring ulcer in left foot under 3rd metatarsal head (MTH). Originally started as an area of hyperkeratosis under MTH 3,

which broke down and developed into an ulcer. No underlying deep infection. Footprint shows very high pressure under MTH 3. Plantar anaesthesia present, no plantar intrinsic paralysis. Hypothesis: Head of 3rd MT wedge shaped giving rise to high pressure under this MTH. Proposed solution: Duvries' condylectomy (through a dorsal approach, tangential excision of the undersurface of the MTH making it flat (instead of being wedge shaped) and thus enlarging the weight-bearing area many times).

This was done. Follow-up 11 months later showed no recurrence. Footprint showed no high-pressure sites.

**CASE 3.** RM (male, 35 years). Problem: Recurrent ulceration of terminal pad of 2nd toe (left foot). Earlier had ulcer of big toe pad and during one episode of severe infection the big toe was removed. Second toe ulceration started some months later. Ulcer over pulp (terminal pad) of 2nd toe with no bony involvement and no big toe. Second toe much longer than the others. Anaesthesia medial half of sole with paralysis of muscles supplied by medial plantar nerve. Walking footprint shows dragging of tip of 2nd toe with high pressure. Hypothesis: In the absence of big toe, tip of the 2nd toe bears most of the stress of transfer of load from the foot. Proposed solution: Shorten the 2nd toe so that it is level with the others so that all four toes share walking stresses and reduce that on the 2nd toe.

This was done by excising the middle phalanx of the 2nd toe. Follow-up one year later showed an ulcer-free 2nd toe.

**CASE 4.** MS (male, 19 years). Problem: Frequently recurring ulcer under first MTH (right foot). Started with ulcer under MTH3 many years ago followed later by ulceration under MTH 1. Foot shows a deep cleft under MTH3, dorsal migration of 2nd and 3rd toes, and severe secondary hallux valgus with thin

adherent scar under MTH1. The 1st MTH ulcer heals without difficulty, but recurs promptly on walking (with protective footwear) even for a day or so. Footprint shows high-pressure area under MTH1. Hypothesis: Repeated ulceration led to loss of head and distal shafts of 2nd and 3rd metatarsals with shortening of these rays and dorsal migration of the central toes followed by hallux valgus because of loss of lateral support to big toe. Hallux valgus rendered the big toe useless permitting severe overloading under MTH1. Proposed solution: Correct hallux valgus, release the dorsal scar and bring the toes forward and retain them in that position by fusing the 2nd toe with the big toe and 3rd toe with the 4th (surgical syndactylia).

This was done. Seen eight months later, the foot was ulcer-free.

**CASE 5.** VKR (male, 28 years). Problem: Recurrent ulceration under 3rd and 4th MTH for the last seven years. Ulcer recurs despite protective footwear and foot-care practices. End-on (frontal) view of non weight-bearing foot shows severe 'reversal of the distal transverse metatarsal arch' (the metatarsal heads describe an arch with convexity towards the ground). Third degree clawing of 2nd, 3rd and 4th toes (flexion contracture of PIP joint, dorsal migration of toe with the base of proximal phalanx of the toe resting on the neck of its metatarsal and the MTH can be felt in the sole, like a pebble just under the skin). Walking footprint shows high pressure area under 2nd, 3rd and 4th MTH's. Hypothesis: Because of the 3rd degree claw deformity, the concerned MTH is pushed down by the PP of the toe during walking (during contraction of FDL and EDL muscles). Proposed solution: Reduce the dislocation of MTP joints, re-position the toes to lie in front of their MTH's instead of lying on top of them, straighten the toes and lift up the "fallen" metatarsal heads by transplanting concerned EDL tendons to the necks of their

respective metatarsals (proximalization of EDL).

This was done through a dorsal approach. Follow-up for five years showed no recurrence of the ulcer.

**CASE 6.** M (female, 31 years). Problem: Recurrent ulcer in middle of left heel. Adherent scar in the middle of the heel with a bony mass just under the scar. X-ray with marker over the scar shows abnormally prominent calcaneal tubercle directly above the scar. Hypothesis: Scar breaks down due to excessive shearing and compression during walking. Proposed solution: Convert broad adherent scar into thin linear scar-by-scar excision and resuture and enlarge bony weight-bearing surface by excising the bossy calcaneal tubercles to provide a larger, flat surface. If feasible, interpose between bone and scar, a local fat flap mobilized from one side.

This, including fat flap interposition, was done. Seen 14 months later, the ulcer had not recurred.

**CASE 7.** JM (male, 57 years). Problem: Recurrent ulceration of both heels for many years, despite use of protective footwear and practicing foot-care. Has sound scar in mid heel. Ulcer found in anterior heel area. X-ray (with marker over ulcer) shows secondary calcaneus recurvatus deformity ("boat-shaped calcaneum") with ulcer under the front end of calcaneum. Subtalar articulation is intact. It is this ulcer that keeps recurring now. Hypothesis: The posterior pillar of longitudinal plantar arch has been lost because of the bony deformity. Therefore, during heel strike, the front end of calcaneum hits the ground and this is the reason for recurrent ulceration under front end of heel. Proposed solution: Restore posterior pillar to produce normal heel strike. This was done by doing a displacement osteotomy of calcaneum. Seen 18 years later, the heel was ulcer-free.

It should be evident from the above illustrative case summaries that a plantar scar may be overloaded due to dynamic and/or static stresses, because of obvious, or not so obvious or even occult, anatomical abnormalities (e.g., talipes, congenital varus 5th toe and wedge shaped MTH respectively). Our experience shows that it is worth taking the trouble and spending time to identify the exact cause of recurrence and eliminate it. The expertise required is eclectic and techniques from the disciplines of orthopaedics and plastic surgery are needed for surgery in this field.

## REFERENCES

1. Basmajian JV: Muscles Alive: Their Functions Revealed by Electromyography. Baltimore, Williams & Wilkins, 1962
2. Bassan MM: Near fatal systemic oxygen embolism due to wound irrigation with hydrogen peroxide, *Postgrad Med* 58:448-451, 1982
3. Birke JA, Novick A, Hoard A, et al.: Methods of healing plantar ulcers in Hansenís disease patients. *The Star* 51:5-10, 1992
4. Bloomfield SF, Sizer TJ: Eusol B.P.C. and other hypochlorite formulations used in hospitals. *Pharm J* 235:153-157, 1985
5. Bradley M, Cullum N, Sheldon T: The debridement of chronic wounds: a systematic review. *Health Techn Assess* 3, No. 17, 1999
6. Brand PW: Pressure sores: the problem. pp.19-23. In Kenedi RM, Cowden JM, Scales JT(eds): *Bed Sore Biomechanics*. Macmillan, London, 1976
7. Brand PW: Insensitive Feet: a practical handbook on foot problems in leprosy, 3rd ed. The Leprosy Mission, London, 1991
8. Chakraborti D, Datta S, Chakraborti T: Trial of homeopathic medicine in the prevention of disability. *Proceedings 16th International Leprosy Congress, Salvador, Brazil*, pp. 314, 2002
9. Cherian E, Vanaja G, Krishnan R, Bhatia VN: Bacterial flora of ulcers treated by three types of dressings. *Ind J Lepr* 60:389-391, 1988
10. Dakin H.D: On the use of certain antiseptic substances in the treatment of infected wounds. *Brit Med J* 11: 318-320, 1915
11. Ebenezer G, Daniel S, Suneetha S, et al: Bacteriological study of pus isolates from neuropathic plantar ulcer associated with acute inflammatory phase. *Ind J Lepr*, 72:443-449, 2000
12. Ehrlich HP: Why wounds need to be debrided. pp. 23-29. In Westerhof W and Vanscheidt W (eds): *Proteolytic Enzymes and Wound Healing*. Springer, Berlin, 1994
13. Fritschi EP: *Surgical Reconstruction and Physical Rehabilitation in Leprosy*. The Leprosy Mission, Delhi, 1984
14. George M, Bhatia VN, Kar HK, Roy RG: Anaerobic flora in trophic ulcers in leprosy patients. *Ind J Lepr* 57: 336, 1984
15. Gorse GJ, Messner RL: Improved pressure sore healing with hydrocolloid dressings. *Arch Dermat* 123: 766-771, 1987
16. Haythornthwaite HW: Closed plaster for trophic ulcers. *Lepr India*, 15:20-22, 1943
17. Impey SP: *Handbook of Leprosy*. J&A Churchill, London, 1896
18. Jayakumar J, Aschoff M, Renuka G: Mycetomas in leprosy. *Ind J Lepr*, 65:229-233, 1993
19. Khan JS: Treatment of leprosy trophic ulcers. *Lepr India* 11:19-21, 1939
20. Kozol R.A., et al: Effects of sodium hypochlorite (Dakin's Solution) on cells of the wound module, *Arch Surg* 123: 420-423, 1988
21. Kulkarni RB, Patil RT, Praveena S: Actinomycotic mycetoma due to *Nocardia brasiliensis* in a case of leprosy. *Ind J Lepr* 73:263-265, 2001
22. Kumar A, Laxmanan M: Adhesive zinc tape treatment of uncomplicated ulcers amongst leprosy patients. *Lepr Rev* 57:45-91, 1986
23. Liwen D, Futian L, Zaimeng W, Juan J: Techniques for covering soft tissue defects resulting from plantar ulcers in leprosy: General considerations and summary. *Ind J Lepr* 71:279-295, 1999
24. Liwen D, Futian L, Juan J, Guocheng Z: Techniques for covering soft tissue defects resulting from plantar ulcers in leprosy-2: first toe web and dorsal foot flaps. *Ind J Lepr* 71:297-309, 1999
25. Liwen D, Futian L, Jugen Z, Yongling Y, Juan J, Guocheng Z: Techniques for covering soft tissue defects resulting from plantar ulcers in leprosy-3: use of plantar skin or musculocutaneous flaps and anterior leg flap. *Ind J Lepr* 71:3-16, 1999
26. Liwen D, Futian L, Juan J, Guocheng Z: Techniques for covering soft tissue defects resulting from plantar ulcers in leprosy-4: use of



- medial leg flap and medial knee flap. *Ind J Lepr* 71:17-30, 1999
27. Liwen D, Futian L, Juan J, Guocheng Z. Techniques for covering soft tissue defects resulting from plantar ulcers in leprosy-5: use of the flap in the inguinal region and latissimus dorsi musculocutaneous flap. *Ind J Lepr* 72:227-244, 2000
  28. Malaviya GN, Husain S, Girdhar A, Girdhar BK: Sensory functions in limbs of normal persons and leprosy patients with peripheral Trunk damage. *Ind J Lepr* 66:157-164, 1994
  29. Molan PC: Honey as a dressing for wounds, burns and ulcers: a brief review of clinical reports and experimental studies, *Primary Intention* 6: 148-158, 1998
  30. Ovington L: Wound dressings: their evolution and use. pp221-232. In V.Falanga, (ed): *Cutaneous Wound Healing*. Martin Dunitz, London, 2001
  31. Palande DD, Desevery C, Rajagopalan MS: Plantar ulcers with osteomyelitis underneath. A bacteriological study. *Lepr India* 49:322-329, 1977
  32. Paul M: Surgical measures in leprosy. *Int J Lepr* 4: 29-34, 1936
  33. Price EW: Studies on plantar ulceration in leprosy. *Lepr Rev*, 30:98-105, 1959
  34. Price EW: The natural history of plantar ulcers. *Lepr Rev*, 30:180-183, 1959
  35. Price EW: The etiology of plantar ulcers. *Lepr Rev* 30:242-248, 1959
  36. Price EW: The complications in plantar ulcers. *Lepr Rev* 31:97-103, 1960
  37. Price EW: Plantar ulcers in leprosy: A review of the literature. *Lepr Rev* 32:108-116, 1961
  38. Raghupathi SG, Subramanyam S, Deenabandhu A et al.: Exposure to pulsed magnetic fields in the treatment of plantar ulcers in leprosy patients: a pilot, randomised, double blind controlled clinical trial. *Ind J Lepr* 69:241-250, 1997
  39. Rao KS, Mahendra Kumar, Oommen PK et al.: Collagen sheet and its usefulness in healing ulcers in leprosy patients. *Ind J Lepr* 59:435-441, 1987
  40. Richardus JH, Smith TC: Squamous cell carcinoma in chronic ulcers in leprosy. A review of 38 consecutive cases. *Lepr Rev* 62:381-387, 1991
  41. Ross FW: Aetiology and treatment of plantar ulcers. *Lepr Rev* 33:25-40, 1962
  42. Sane SB, Mehta JM: Malignant transformation of trophic ulcers in leprosy: a study of 12 cases. *Ind J Lepr* 60: 93-99, 1988
  43. Sleigh JW, Linter SPK: Hazards of hydrogen peroxide. *Brit Med J* 291:1706, 1985
  44. Srinivasan H: Trophic ulcers in leprosy-I: distribution of ulcers in the sole of the foot. *Lepr India* 35:119-127, 1963
  45. Srinivasan H: Trophic ulcers in leprosy-II: ulceration and plantar intrinsic paralysis. *Lepr India* 36:110-118, 1964
  46. Srinivasan H, Mukherjee SM: Trophic ulcers in leprosy III. Surgical management of chronic foot ulceration. *Lepr India* 36:186-193, 1964
  47. Srinivasan H: Plantar ulcers and corrective surgery: determining factors in localization of foot ulcers in leprosy patients. *Lepr India* 37 (Suppl 3A): 3-8, 1965
  48. Srinivasan H: Reconstructive surgery and prevention of neuropathic plantar ulcers. In *Proceedings of International leprosy Seminar, Agra, 1967*. Published by Ministry of Health, Government of India, New Delhi, 1967
  49. Srinivasan H, Desikan KV: Cauliflower growths in plantar ulcers in leprosy. *Lepr India* 43:24-32, 1971
  50. Srinivasan H: Heel ulcers in leprosy patients. *Lepr India* 48:355-361, 1976
  51. Srinivasan H: Reconstructive surgery for correction of deformities of foot and for prevention of recurrent plantar ulceration. pp 637-649. In Dharmendra (ed): *Leprosy-Vol. 1*. Kothari Medical Publishing House, Bombay, 1978
  52. Srinivasan H: Surgery of os calcis in leprosy patients. *Bull Tamil Nadu Orthop Assn*, 28-32, 1981
  53. Srinivasan H: Prevention of recurrent neuropathic ulceration of the forepart of the foot. *Ind J Surg* 44:300-304, 1982
  54. Srinivasan H: Do we need trials of agents alleged to improve healing of plantar ulcers? *Lepr Rev* 60:278-282, 1989
  55. Srinivasan H: Prevention of Disabilities in Patients with Leprosy. Geneva, World Health Organization, 1993
  56. Srinivasan H, Palande DD: Essential Surgery in Leprosy: techniques for district hospitals. pp.18-35. Geneva, World Health Organization, 1997
  57. Süderberg T et al: Treatment of leprosy wounds with adhesive zinc tape. *Lepr Rev* 53:271-276, 1982
  58. Stadelman WK, Digenis AG, Tobin GR:

## 226 Surgical Reconstruction & Rehabilitation in Leprosy

- Impediments to wound healing. *Am J Surg* 176 (Suppl. 2A):39S-47, 1994
59. Stenstrøm S, Bergman G, Bergman S: Wound healing with ordinary adhesive tape. *Scand J Plast Reconstr Surg* 6: 40, 1972
  60. Stenstrøm S et al: Leprosy wound healing with ordinary adhesive tape: a preliminary report. *Scand J Plast Reconstr Surg* 10:241, 1976
  61. Sturm AW, Jamil BMC, Adam KPWJ et al: Microbial colonizers leprosy skin ulcers and intensity of inflammation. *Int J Lepr* 64:274-281, 1996
  62. Tarnuzzer RW, Schulz GS: Biochemical analysis of chronic and acute wound environments. *Wound Rep Reg* 4:321-325, 1996
  63. Taylor HD: The solvent action of antiseptics on necrotic tissue. *J Exp Med* 27:155-164, 1918
  64. Tudhope M: Management of pressure ulcers with a hydro-colloid occlusive dressing: results in twenty-three patients, *J Enterostomal Ther* 11:102-105, 1984
  65. Vande Berg JS, Rudolph R, Holan C, Haywood-Reid PL: Growth factors and chronic wounds: Fibroblast senescence in pressure ulcers. *Wound Rep Reg* 6:38-49, 1998
  66. Vinodkummar CHD, Harikrishnan S, Bhatia VN, Rot RG: Bacteriological study of trophic ulcers in leprosy patients. *Lepr Rev* 55: 504, 1983
  67. Yager DR, Chen SM, Ward SI et al: Ability of chronic wound fluids to degrade peptide growth factors associated with increased levels of elastase activity and diminished levels of proteinase inhibitors. *Wound Rep Reg* 5:23-32, 1997