

Squamous Cell Carcinoma and Amputations

• R. SCHWARZ

SQUAMOUS CELL CARCINOMA

The incidence of squamous cell carcinoma in the foot is very high in patients affected with chronic plantar ulcers from leprosy.^{1,7,10-13} Those with chronic ulcers due to other neuropathic diseases appear to have a much lower incidence given the paucity of reports in the literature. The development of carcinoma in leprosy patients is due to the prolonged ulceration to which these patients are subject, especially in those patients residing in developing countries who are unable to seek medical attention early. Richardus and Smith¹⁰ found that patients with a malignant ulcer had a history of ulceration of 15 years duration. Interestingly matched controls with benign plantar ulcers had an average duration of ulceration of 26 years. The pathologic progression is similar to that seen in a Marjolin's ulcer, a squamous cell carcinoma arising in an old burn scar.⁶ The chronic attempts at wound healing over many years gradually leads to metaplastic changes, which then progress to dysplasia and finally neoplasia. As in Marjolin's ulcer, squamous cell carcinoma usually arises after a history of an ulcer being present for many years or decades. These patients often present with large fungating tumours already involving bone (Fig. 18-1), but they may also present with flat benign appearing ulcers as well. Bobhate et al¹ found that plantar ulcers in the heel are more likely to undergo malignant transformation than those in the forefoot. Any suspicious ulcer or any ulcer that fails to heal with appropriate conservative management should be biopsied. It must be kept in mind that the pathologic diag-

nosis of these lesions is difficult. In one study 41% of squamous cell carcinomas had a benign diagnosis on initial biopsy.⁸ Some required up to four biopsies (the last biopsy including the foot!) to establish the diagnosis. In the same study review by four different pathologists showed considerable conflict in pathologic diagnoses, the most common benign diagnoses being corneum cutis and hyperkeratosis.

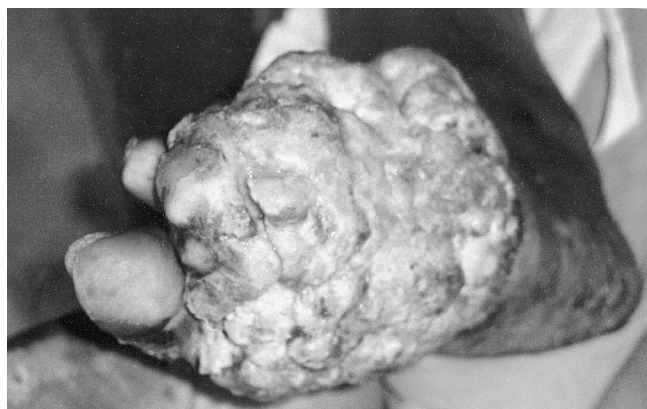

FIGURE 18-1 Fungating squamous cell carcinoma of the foot, treated with excision and coverage with medial plantary artery flap.

Obviously the best management is prevention, emphasizing again the need of appropriate counselling and footwear in those with loss of sensation in the sole. When patients present with established carcinoma, one tries to preserve as much of the foot as possible while performing a curative resection of the cancer. A minimum of 1 cm clearance of the tumour at the margins is necessary, although for late stage tumours 3-5 cm is recommended due to the deep invasion that is sometimes present.

Surgical resection margins should be checked by the pathologist, and re-excision planned if the margins are involved. In relatively early cases it may be possible to perform a curative resection without an amputation. Some cases of the heel we have treated with wide excision and a medial plantar artery or cross-leg flap for reconstruction, with no recurrence for up to 5 years. However, at present we would not recommend a cross-leg flap due to the risk of seeding tumour to the other leg and the development of better, local flaps such as the medial plantar artery flap (see Chapter 16). Fritschi reports patients treated with excision and skin grafting with no recurrence for years.⁴

The majority of patients will require an amputation of some kind. If on one side of the forefoot, the half bearing the cancer is excised in a wedge and the other side is used to close the wound after removal of the metatarsals.⁴ This will preserve some toes for the patient. I would recommend tendon Achilles lengthening after this procedure, which is essentially a Lisfranc's amputation. Other patients will require a Boyd's or Syme's amputation to achieve a curative resection (see below for technique).¹³ Only in large tumours involving the heel will a below knee amputation be necessary. McDonald reports that 40% required a foot saving amputation and 52% required a below-knee amputation.⁸ 8% were treated with local excision and flaps. No recurrences were reported.

Patients frequently present with popliteal, femoral and inguinal lymphadenopathy^{1,12}. In most cases this is due to inflammatory lymphadenopathy. This can be diagnosed by fine-needle aspiration cytology, or the surgeon can wait until after excision of the tumour to see if the lymphadenopathy resolves. In those with proven metastatic disease in the groin, a block dissection of the femoral lymph nodes is carried out, although these patients have a poor prognosis.

AMPUTATIONS

While all reasonable efforts to preserve a foot should be expended, some patients will present with a foot that is no longer salvagable. This may be due to destruction of the foot by infection, gross bony destruction by neuropathic bone disease or osteomyelitis, or massive plantar ulceration. Amputation does not mean failure but should be approached with the goal of preserving as much quality weight-bearing sole as possible. Especially for those patients living in remote areas, being able to walk without a special prosthesis is a great advantage. Amputations at various levels are described below. Other than the toe amputation all should be done under tourniquet control with pre-operative exsanguination, releasing the tourniquet prior to skin closure to check hemostasis. A single dose of pre-operative antibiotic, covering gram-positive organisms, should be given.

Toe Amputation

Fish-mouth flaps are created on the dorsal and ventral surfaces preserving all fat, starting the incision at the level of intended bone section and making the plantar flap slightly longer than the dorsal flap. Tendons are divided as far proximally as possible. In the great toe the sesamoids are removed. Digital nerves are divided proximally and the vessels ligated and divided. If the amputation is through the level of the metatarsophalangeal joint the joint capsule must be resected but the articular cartilage can be left. Skin is closed in one layer.

Ray Amputation

This is of benefit to preserve as much of the distal weight-bearing foot as possible. It is usually used on the first and fifth digits but can be used for multiple digits.

Technique: Fishmouth flaps are raised at the base of the digit and a longitudinal dorsolater-

al incision is then extended to the base of the metatarsal. Part or all of the metatarsal is removed and the tendons are then divided proximally. Skin is closed in a single layer.

Transmetatarsal Amputation

This is seldom indicated in leprosy but is more common in diabetes due to vascular insufficiency. A long plantar flap is raised just distal to the level of the metatarsophalangeal joints and with a dorsal flap extending just beyond the mid-metatarsal level. The flaps are slightly longer on the medial side because of the greater foot thickness here. The metatarsals are divided taking care to preserve at least the proximal quarter. Skin is closed in two layers with a drain left in that is removed in 48 hours.

At times the patient may present with advanced infection and destruction of the forefoot but preserved toes. Patients like their toes and if possible the surgeon should try to preserve them. In this situation the metacarpals can be excised as needed, the edges smoothed with a file, and any plantar ulcerations excised and closed. The dorsal wounds are left to close on their own and may be skin grafted after an appropriate time interval to speed healing.

No special footwear is needed.

Lisfranc's Amputation

This procedure is indicated in severe forefoot destruction. A fishmouth incision is made distal to the tarso-metatarsal joints and amputation is made through this level. The incision can be closed by either the plantar or dorsal skin flap, and if there is a shortage of skin due to infection the wound can be left to close by secondary intention. The foot retains dorsi-flexion function, and no special footwear is needed. The patient may request a filler in the toe to fill out the shoe and prevent it from "flapping".¹⁶

Boyd Amputation

This gives a more functional foot than a Pirigoff as the weight bearing area of bone is larger and the weight bearing skin is sole rather than the skin of the back of the heel. It is commonly used for squamous cell carcinoma of the forefoot.

Technique: Starting at a point just anterior and one cm inferior to the distal medial malleolus, a long flap is made on the sole just distal to the fifth metatarsal base, ending at a point at the tip of the lateral malleolus (Fig. 18-2).² The dorsal flap is made at the level of the talo-navicu-

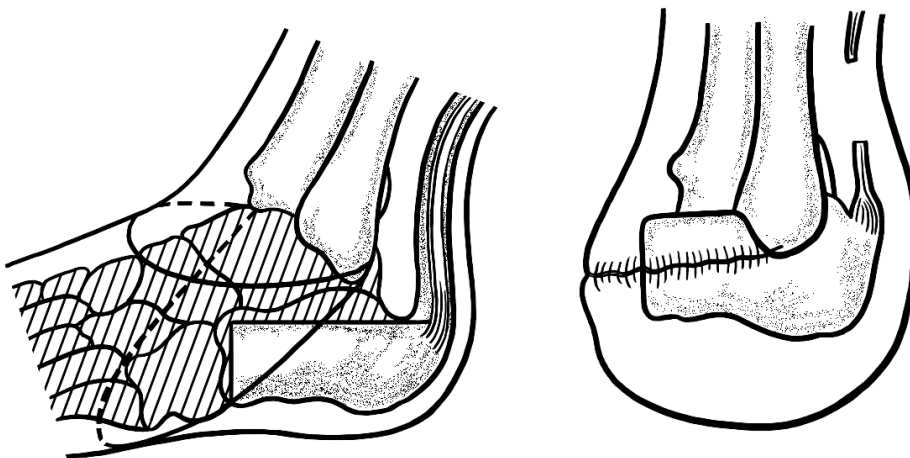


FIGURE 18-2 Boyd Amputation.

lar joint. The distal foot is removed through the midtarsal joints. The talus is removed according to the technique of Whitfield. In this the talus is grasped, pulled inferiorly and the ligaments superior to the talus are divided. Lateral ligaments are then divided, after which the inferior and finally the posterior attachments are divided. The calcaneus is divided just distal to the peroneal tubercle and the superior surface cut off transversely with an osteotome. The distal tibial articular surface is removed and the malleoli are trimmed on their inner surfaces to fit the calcaneus. Tendons and the medial and lateral plantar nerves are divided high. The calcaneus is then shifted slightly forward inserted into the mortise and fixed with a Steinman pin from the heel. Skin is closed in two layers with a drain in place that is removed in 48 hours. A plaster is placed and left for three months. The pin is removed at one month and weight bearing is commenced. The walking plaster is left until the arthrodesis is complete, usually by three months.

Pirigoff Amputation^{9,16}

While not as functional as the Boyd, it is possible to perform a Pirigoff amputation with a shorter ventral flap, allowing salvage of the foot in certain cases. Weight bearing occurs on the skin covering the back of the heel, similar to a Syme's amputation.

Technique: Starting at a point just anterior to the medial malleolus, the sole flap is cut at the level of the talo-navicular joint, ending 1 cm above the lateral malleolus (Fig. 18-3). The dorsal flap cut at the level of the talo-navicular joint. The distal foot is removed through the midtarsal joints and the talus removed as in the Boyd amputation. The ankle joint articular cartilage is removed as for the Boyd amputation. The calcaneus is cut at a right angle through the neck, or more proximally just anterior to the posterior tubercle. In this case the calcaneus is transected at an angle 30° to the long axis of the tibia, although this angle can be varied. The calcaneus is then rotated forward to oppose the anterior calcaneal surface to the ankle mortise and fixed in place with a Steinman pin. Skin is closed in two layers with a drain in place, which is removed at 48 hours. A plaster is applied. The pin is removed at one month. The plaster is removed at three months and weight bearing commenced.

Syme's Amputation

A Syme's amputation is indicated if the sole skin is insufficient to preserve the calcaneus. It has the disadvantage of not entirely weight-bearing on sole skin. It requires a special prosthesis to walk a significant distance, but can be used for very short distances without a prosthesis such as to go to the toilet at night. It has

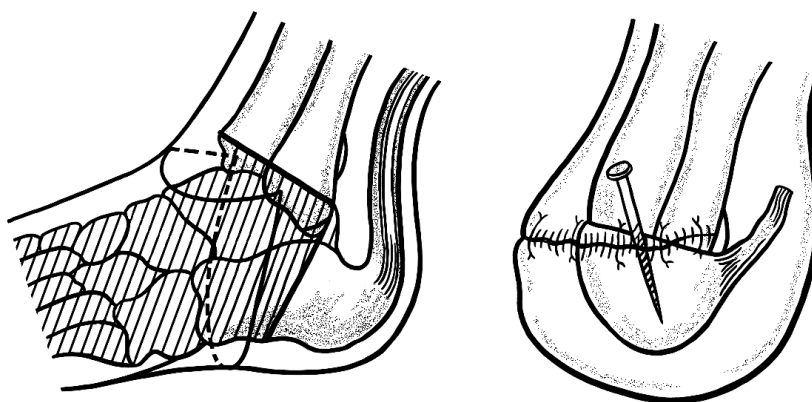


FIGURE 18-3 Pirigoff amputation.

a tendency to form a pseudobursa, making the weight-bearing skin pad very mobile. If this occurs it can be excised, but it has a tendency to re-form. Common causes of failure are flap necrosis due to overzealous trimming of the dog-ears and posterior migration of the heel pad.⁴

Technique: Starting 1 cm inferior to the medial malleolus, the plantar flap is made at the level of the mid-calcaneus, ending at the tip of the lateral malleolus (Fig. 18-4). The anterior flap is made at the level of the ankle joint. The medial and lateral ligamentous attachments of the ankle are divided starting with the blade in the joint space, taking care not to damage the vessels. A bone hook is placed in the talus to place it in extreme equinus after which the posterior ankle joint capsule and then the Achilles tendon are divided. The plantar flap is taken off the calcaneus in a sub-periosteal plane, being careful to preserve the blood supply to the flap. The foot is then removed through the ankle joint. Soft tissues are dissected off the distal tibia and fibula with the periosteal elevator. The periosteum is then divided sharply 6 mm above the joint line and the bone then divided at this level, perpendicular to the line of the tibia. All tendons and the medial and lateral plantar nerves are divided high and vessels are tied. The heel flap is brought forward to be sutured to the anterior flap ensuring that the suture line is anterior to the weight-bearing surface. Wagner has described a technique to

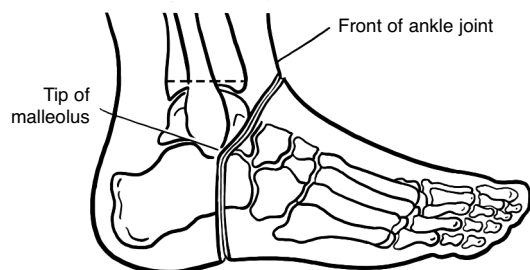


FIGURE 18-4 Syme's amputation- skin flaps. (from Richardson⁹, used with permission)

prevent the posterior migration of the heel flap.^{8,15} Holes are drilled through the anterior edge of the tibia and fibula and the fascia of the heel flap is then sutured to the bones through these holes. A drain is left and removed at 48 hours, and a bulky dressing applied. Weight bearing is commenced at one month with a prosthesis, or a prosthetic cast can be applied after the drain has been removed and early ambulation commenced. A patient with a left Syme's amputation and a right Pirigoff amputation is shown in Fig. 18-5.

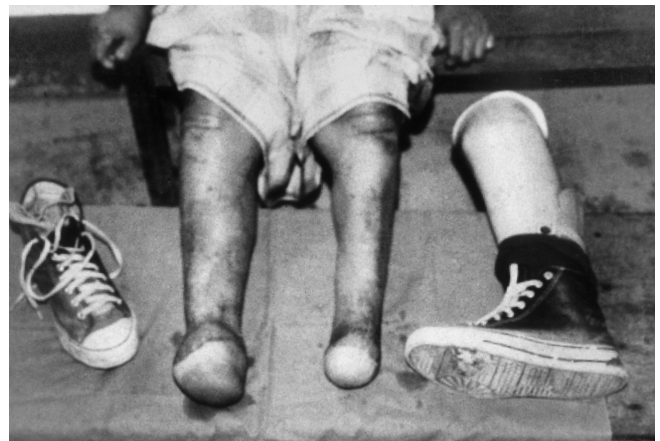

FIGURE 18-5 Patient with a left Syme's amputation and a right Pirigoff amputation. The patient is able to ambulate with bare feet, but uses a patellar weight bearing prosthesis on the left when walking long distances.

Below-Knee Amputation

If the septic or other destructive process makes a more distal amputation impossible, the surgeon should carry out a below-knee amputation without unnecessary delay so that the rehabilitation process can start as soon as possible. For amputations for peripheral vascular disease there are many factors regarding the estimation of blood supply to the calf skin that can be used to predict flap survival and wound healing. The reader is referred to a surgical textbook for a full discussion of these issues.¹⁴

In amputations for neuropathy the blood supply is generally good and good wound healing can be expected in almost all cases. In those patients with an active septic process in the foot at the time of amputation, there is an increased likelihood of wound infection, especially if cellulitis is extending up the calf. In these cases one should consider a guillotine amputation at the level of the ankle as an initial procedure. The definitive procedure can then be carried out several days later after the infection has been controlled. Both the standard Burgess³ amputation and the fishmouth amputation have been reported, but only the Burgess amputation is described in the following text. The fishmouth amputation is shown and briefly described in Figure 18-6. In non-ischaemic limbs tension myoplastic procedures are performed or even firmer stabilization with myodesis. These are contraindicated in the ischaemic limb as they may further compromise a tenuous blood supply. Preserving adequate length of the stump is important, as it has been shown that a short stump leads to

increased energy expenditure of ambulation.⁵
Technique: A point is marked 12.5-17 cm below the joint line, or 10-12.5 cm in ischaemic limbs, depending on body height.¹⁴ Points are then made at the mid-point of the calf on both medial and lateral sides 1 cm proximal to the first point and the points connected (Fig. 18-7). The width of the calf is then measured, and the length of the posterior flap is then marked at this length plus 1 cm. The anterior flap is 1 cm long. The anterior flap is then cut down to periosteum and the periosteum is then raised proximally. Muscles of the anterior compartment are divided. The anterior tibial vessels and peroneal nerve are divided and then ligated above the level of bone transection, first pulling on the nerve to allow them to retract well above the amputation levels. The tibia is cut 1 cm proximal to the tip of the anterior flap, beveling the anterior aspect and filing the edges smooth. After dividing muscles in the lateral compartment the fibula is divided 1 cm above the level of the tibial amputation. The posterior tibial vessels are then doubly tied and

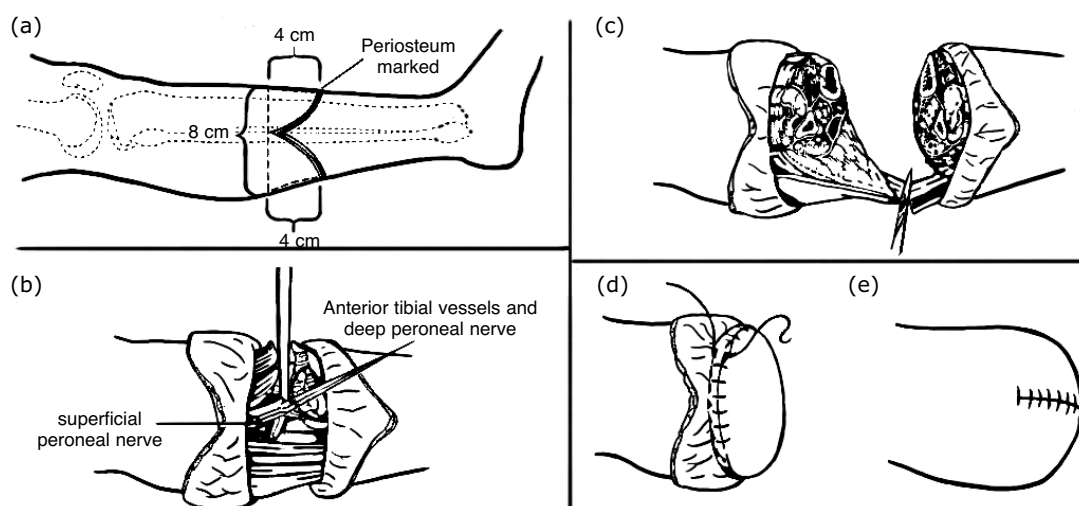


FIGURE 18-6 Below-knee amputation for non-ischaemic limbs. **a.** Skin incisions creating equal anterior and posterior flaps, each one half of the anteroposterior diameter of the leg. **b.** Anterior tibial vessels and deep peroneal nerves all divided and ligated high to avoid painful neuromas. **c.** Fashioning of long posterior myofascial flap. **d.** Posterior myofascial flap sutured to periosteum anteriorly. **e.** Skin closure (From Tooms¹⁴, used with permission).

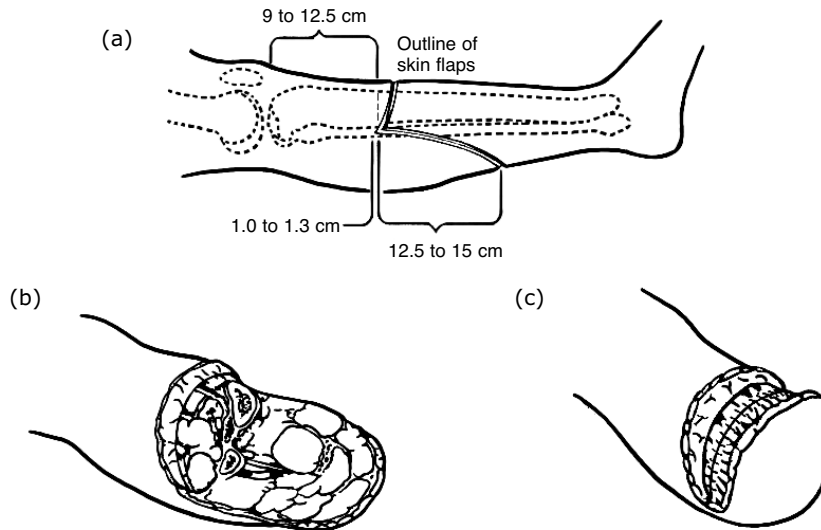


FIGURE 18-7 Burgess' below knee amputation **a.** Skin incisions. **b.** Distal leg removed and muscles bevelled. **c.** Posterior fascia sutured to periosteum and anterior fascia (Modified from Tooms¹⁴, used with permission).

divided. The posterior tibial nerve is divided high and allowed to retract. The posterior muscles are divided, leaving only gastrosoleus muscle mass attached to the posterior flap so that the stump will not be too bulky. An amputation knife is used to bevel this muscle mass. Gastrocnemius tendon is divided 1 cm proximal to the level of the skin flap, taking care not to separate the skin from the underlying muscle. The wound is well irrigated and hemostasis obtained after release of the tourniquet. A drain is left and removed at 48 hours. The posterior fascia is sutured with some tension to the anterior fascia. Skin is then closed with interrupted sutures and a padded bandage placed, ensuring that this does not compromise circulation to the stump. Stump bandaging is commenced at one week and continued until the stump is ready for prosthesis fitting. The stump will shrink over the first three to four months, after which permanent prosthesis fitting can be done. A temporary prosthesis can be fitted in the interim.

References

1. Bobhate SK, Madankar ST, Parate SN, Chaudhary RK, Kumbhalkar DT: Malignant transformation of plantar ulcers in leprosy. *Ind J Lepr* 65:297-303, 1993
2. Boyd, HB: Amputation of the foot, with calcaneotibial arthrodesis. *J Bone Joint Surg* 21:997-1001, 1939
3. Burgess EM: Prevention and correction of fixed equinus deformity in mid-foot amputations. *Inter-Clin Bull* 6:20, 1966
4. Fritchi, EP: *Surgical Reconstruction and Rehabilitation in Leprosy*. The Leprosy Mission, New Delhi, 1984
5. Gonzales EG, Corcoran PJ, Reyes RI: Energy expenditure in below knee amputee: correlation with stump length. *Arch Phys Med Rehabil* 55:111, 1974
6. Konigova R, Rychterova : Marjolin's ulcer. *Acta Chir Plast* 42:91-4, 2000
7. Kumaravel S: Neoplastic transformation of chronic ulcers in leprosy patients--a retrospective study of 23 consecutive cases. *Ind J Lepr* 70:179-87, 1998
8. McDonald M: Squamous cell carcinoma in plantar ulcers. In *Book of Abstracts of the First Asian Leprosy Congress*, Agra, Nov, 2000

256 Surgical Reconstruction & Rehabilitation in Leprosy

9. Richardson EG, Tooms RE: Amputations about the foot. pp 1973-1990. In Canale ST (ed) *Campbell's Operative Orthopaedics*, 9th ed. Mosby, St. Louis, 1998
10. Richardus JH, Smith TC: Squamous cell carcinoma in plantar ulcers in leprosy. A case control study. *Lepr Rev* 64:270-4, 1993
11. Richardus JH, Smith TC: Squamous cell carcinoma in chronic ulcers in leprosy: a review of 38 consecutive cases. *Lepr Rev* 62:381-8, 1991
12. Sane SB, Mehta JM: Malignant transformation in trophic ulcers in leprosy: a study of 12 cases. *Ind J Lepr* 60:93-99, 1988
13. Soares D, Kimula Y: Squamous cell carcinoma of the foot arising in chronic ulcers in leprosy patients. *Lepr Rev* 67:325-9, 1996
14. Tooms, ET: Amputations of the lower extremity. Pp532-541. In Canale ST (ed) *Campbell's Operative Orthopaedics*, 9th ed.. Mosby, St. Louis, 1998
15. Wagner FW Jr: Management of the diabetic-neurotrophic foot: Part II. A classification and treatment program for diabetic, neuropathic and dysvascular foot problems. In Cooper RR (ed): *AAOS Instructional Course Lectures*, vol 28. CV Mosby, St. Louis, 1979
16. Warren GW, Nade S: *The Care of Neuropathic Limbs*. Parthenon Publishing Group, 1999

Other Reading

1. Pinzur MS, Kaminsky M, Sage R, Cronin R, Osterman H: Amputations at the middle level of the foot: A retrospective review. *J Bone Joint Surg* 68A: 1061-70, 1986
2. Sage R, Pinzur MS, Cronin R, Preuss HF, Osterman H: Complications following mid-foot amputation in neuropathic and dysvascular feet. *J Am Pod Med Ass* 79:277-81, 1989