

Unfavourable Outcomes after Reconstructive Surgery in Leprosy

• G.N. MALAVYA

INTRODUCTION

Any surgical procedure has a risk of morbidity and these are generally complications of the anaesthetic or the procedure itself. In consenting the patient for the proposed operation it is these risks and benefits which are considered before agreeing to the operation. Complications can lead to an unfavourable result, but in reconstructive surgery it is usually a technical failure that leads to a suboptimal result. An unfavourable result after a tendon transfer or cosmetic procedure is not unusual and determining the causes of such an outcome may give insight into its treatment and future prevention.

There is a scarcity of information in the literature regarding unfavourable results of corrective surgery in leprosy patients. Most of these outcomes are due to one or more of the following factors - wrong surgical plan made due to an overlooked problem at the proposed operative site, imperfect technique, inadequate physiotherapy, non-cooperation of the patient or a surgical complication such as sepsis or a tendon fixation gives way. Occasionally having an unrealistic expectation and selecting a procedure in an overzealous attempt to restore normalcy can lead to a poor result.

Lack of anatomical knowledge is at the root of many surgical errors. Anatomy does not change but with advances in surgical techniques our needs for an understanding of various structures change.

A careful evaluation of the unfavourable result may reveal the factor(s) which can be

held responsible for such an outcome. It may not be possible to give the exact incidence of these outcomes because of inadequate follow-up.

Initial examination of the patient is an important first step in avoiding an unsatisfactory result.⁹ One must evaluate both the deformity and patient and get a general idea whether or not surgical procedures are necessary, what can be achieved by surgery and how. Psychiatric morbidity is extremely common in leprosy patients, the commonest being neurosis.²²

Long term follow-up is not only instructive but is necessary for a good result. Patients need reinforcement of their efforts which is best provided by periodic visits to the therapist. In the post-operative period note any lack of compliance to post-operative treatment and search out reasons for this rather than simply blame them. There may be an underlying social or financial problem. The aspirations of the patient are also changing²² perhaps because of the hope being given to them by field staff or because of increasing medical knowledge in the population. These over expectations of patients may be a factor in some of these bad results because patients lose motivation when they see the reality.

The general complications which can occur with any surgery viz. infections, scarring, hypertrophic scars, tourniquet injury and increased cold sensitivity can occur in any case. In some cases, leprosy disease might show exacerbation whereas in some others a lepra

reaction might develop in spite of all the precautions.

Ischemia deserves special mention because many of these anaesthetic and paralysed hands show positive Raynaud's phenomena i.e. finger tips first become pale and then discoloured bluish when exposed to cold. Fingers may also swell-up. One has to be careful while immobilising the limb in a complete plaster cast after surgery, in situations where controlled room temperatures are not available during winter.

Adhesions may form along the course of the transferred tendon if tissue handling technique is poor or tendon suturing is not done properly. These adhesions interfere with tendon gliding and in severe cases transferred muscle may become non-functional. In mild cases gentle massage along the course of the tendon, electrical stimulation of muscle and ultrasonic therapy can help to break these adhesions. In severe cases, formal tenolysis might be required.

The unfavourable outcomes can be listed according to the type of surgery performed.

NERVE DECOMPRESSIONS

Peripheral nerve trunk decompressions can be performed in leprosy either for relief of intractable pain, to drain a chronic abscess or to restore sensory -motor functions in cases in which steroids have not helped. Although these procedures are quite straight forward, they have their own set of unfavourable outcomes.

The scar may become adherent to the nerve trunk restricting the mobility of nerve and may cause a traction injury. Such nerves may become painful and need re-exploration to release adhesions. Locally available subcutaneous tissue can be brought in as a flap to lie between the skin and nerve and also to cover the nerve.

In cases where nerve abscess has been evacuated a discharging sinus may form in the line

of scar which refuses to heal (Fig. 22-1). The sinus may need excision and removal of necrotic tissue, or a course of rifampicin and isoniazid can be tried which may dry the sinuses in about six months.¹⁰

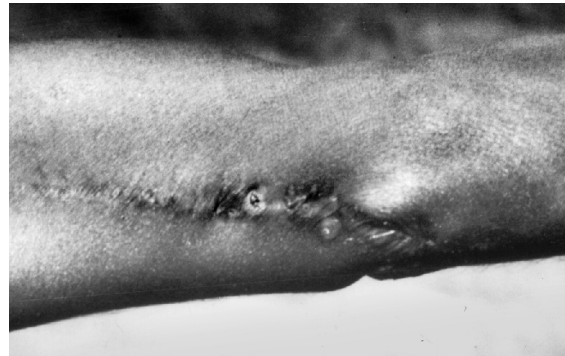

FIGURE 22-1 Sinus along the line of incision for cubital tunnel decompression.

A patient who has undergone nerve decompression should not have prolonged and significantly greater pain post-operatively even though sensations described as paraesthesia and dyesthesia may develop, in some cases even months after surgery. For paraesthesias dilantin has been tried but is not very successful. Carbamazepine (Tegrital) has relieved symptoms in some cases but needs careful monitoring.

The surgical trauma can lead to progression of paralysis. It is unlikely that a good surgical release will precipitate acute neuritis in other nerves due to sudden release of antigens because the patients are given steroids post-operatively.²⁶

Cubital tunnel decompression

After cubital tunnel decompression and the release of Osborne ligament the ulnar nerve may start subluxating or even dislocating when elbow is flexed. This may require an anterior transposition or medial epicondylectomy depending upon the width of the medial

epicondyle. If the epicondyle is larger in size it is easier to perform an anterior transposition.

The segmental and longitudinal blood supply of the nerve should be preserved as much as possible. Excessive mobilisation of the inflamed ischemic nerve trunk can be deleterious. Excision of the medial intermuscular septum if not done adequately may lead to incomplete decompression and dampen the process of recovery or rather may be more damaging. The medial head of triceps may snap against the nerve trunk causing recurrent injury.

The elbow and surrounding area may become anaesthetic due to injury of the medial cutaneous nerve of forearm. A neuroma may form. Persistent oozing from the nerve surface and/or nerve bed may lead to haematoma formation and secondary scarring. Fascicular neurolysis (which is not recommended) may induce intraneural fibrosis and cause nerve fiber damage. Prolonged immobilisation can lead to a stiff elbow.

Carpal tunnel decompression

Incomplete division of either the area of nerve compression proximal to the transverse carpal ligament or the most distal part of the carpal ligament can result in failure of nerve recovery. Following carpal tunnel decompression the fingers should be exercised and wrist immobilised in 10° extension to prevent prolapse of nerve trunk in the wound which may cause adhesion formation. Damage to the palmar cutaneous branch of the median nerve can occur.

Common peroneal and posterior tibial nerve decompression

Drop foot may develop due to excessive traction on the common peroneal nerve while the nerve is being decompressed for neuralgic pain or nerve abscess. Injury to posterior tibial vessels may occur while dissecting the nerve trunk

in the neurovascular bundle during tarsal tunnel decompressions.

CLAW FINGER CORRECTION

The overall success rate of claw finger correction varies from 75-90% depending upon the procedure and assessment criteria used. The results are usually reported in terms of fingers, not in the context of the whole hand.^{4,5,19,20,28,29} Even though it is said that results are stable after one year following surgery, the condition of the hand alters subsequently due to available care, overuse and misuse.

Correction of claw finger deformity requires a precise balancing of flexor and extensor forces across MCP and PIP joints of the fingers.^{7,13} There can be a recurrence of clawing. The most common cause of recurrence is difficulty in re-educating the transferred muscle tendon unit in cases where dynamic correction has been made. Active co-operation of the patient is required to isolate and activate the transfer, which is difficult in older age groups especially with long standing paralysis or low intelligence. Low motivation in patients to learn, and lack of trained staff to educate may also affect the result of the operation.²¹

There is always some loss of the tension during post-operative exercises due to stretching. Poor tendon to graft juncture, improper adjustment of tensions on individual slips or one of the slips getting loose, can alter length-tension relationships during the post-operative period and result in recurrence of clawing in one or more fingers. Such an event requires re-exploration to tighten or re-attach the slip(s) after properly positioning the fingers.

Overlooked residual long flexor contractures, boutonniere deformity and wrist flexing habit (which patients develop as an adaptation to live with their claw deformity) in cases having long standing paralysis also contribute to

recurrence. Volarly routed transfers lose some mechanical advantage when the wrist is flexed and suffer from disuse. The use of a volar wrist splint for several months after surgery and periodic supervision till the transfer is integrated into its new role, can help overcome this problem.

Swan Neck Deformity

Problems of over-correction are seen in cases where insertions have been made in lateral bands especially in hands with long thin fingers having hypermobile joints (Fig. 22-2). Lateral band insertion procedures^{2,5,12} add to PIP joint extensor forces as a result of which the PIP joint hyper-extends and the DIP joint flexes. This intrinsic plus deformity is severely disabling because it interferes with fist closure and grasp function. In hands with long thin fingers and hypermobile joints, over enthusiastic efforts to exercise PIP and DIP joints can damage PIP joint mechanisms (volar restraints) accentuating PIP joint hyperextension. Over correction was noted in about 15% cases by Brand⁵ and 8% by Palande.²⁰

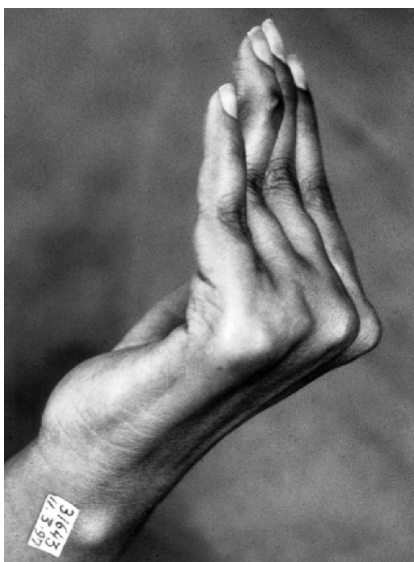

FIGURE 22-2 Intrinsic Plus Deformity after lateral band insertion procedure for correction of finger clawing.

Removal of the flexor digitorum superficialis (FDS) from a finger produces several problems of which "check rein" and "swan-neck" deformity are well known (Fig. 22-3).^{8,24,25}

Superficialis minus deformity is seen in 50% of fingers where FDS has been removed, more often in patients with hypermobile finger joints.⁸ It is characterised by extension of the PIP joint and flexion of the DIP joint. It is very much like intrinsic plus deformity but the mechanisms are different. In swan-neck deformity, extensor predominance over PIP joint is due to removal of FDS and laxity of volar plate of PIP joint. When the FDP attempts to flex the finger its smaller moment arm at the DIP joint results in DIP joint hyperflexion without PIP joint flexion. The problem is accentuated by attaching a motor unit to the lateral bands.

The best treatment is prevention. There is an increased incidence of swan-neck and check-rein deformities using a lateral incision as compared to a distal palmar incision. North and Littler¹⁸ suggested removing FDS through the proximal digital crease incision leaving about a 2 cm long FDS stump in situ to reinforce the volar plate. They felt that this would minimize the risk of superficialis minus deformity.

PIP Joint Extension Limitation

Check-rein deformity is characterised by a rigid flexion contracture of the PIP joint due to scarring at the level of division of the FDS to the tendon sheath, may appear as late as 7 to 9 months post-operatively. It must be diagnosed early, at which point cylindrical casting will both treat it and prevent its progression. The deformity can often be readily corrected by forceful extension of the joint to tear the adhesion if diagnosed in the immediate postoperative period. If it is diagnosed late and is not correctable by physiotherapy, operative release of the adhesions is indicated with post-operative splinting to prevent recurrence.

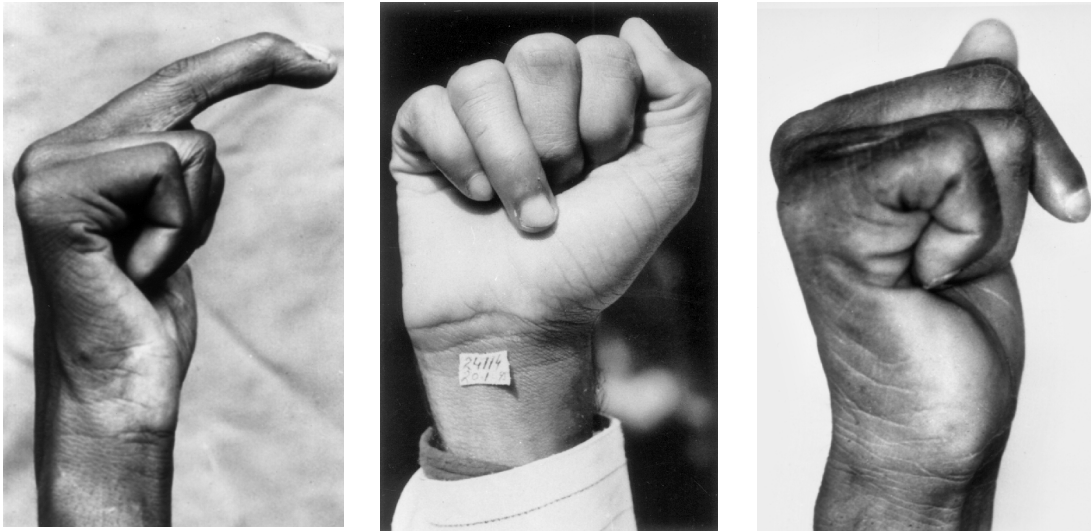


FIGURE 22-3 Problems seen after removal of FDS for transfer. **a.** Flexion of DIP joint **b.** Incomplete fist closure. **c.** PIP joint flexion limitation.

Active PIP joint extension limitation may occur due to overlooked attritional boutonniere deformity, inadequate tension on the transferred slips, or residual long flexor contractures. This is differentiated from a check-rein deformity in which there is both active and passive PIP joint extension limitation.

MCP joint extension contracture is mostly seen with dorsally routed transfers like the extensor many tailed procedure and is either due to adherence of tendon juncture in the distal forearm and/or wrist or due to adherence of the transferred slip to inter-metacarpal fascia.

Other Unfavourable Results

Inability to completely close the fist is seen in cases where FDS from ring finger has been removed for claw finger correction or opponensplasty. In high ulnar paralysis, ring and little finger profundus tendons may be weak and when FDS is removed, profundus alone is unable to flex those fingers completely. FDS should not be removed from the ring finger if the FDP is weak. Reduced grip strength is sometimes complained of by patients who have

their ulnar-median palsy corrected by FDS transfers.

Distal transverse metacarpal arch (DTMA) may be reversed in some cases pre-operatively and can get exaggerated when conventional lateral band insertion procedures are used, especially those where the motor is dorsally routed. Due to reversal of DTMA the cascading pattern of finger closure is altered and instead of converging towards the scaphoid tubercle in the palm, the fingers are splayed so that total contact digito-palmar grasp is not possible. Ranney²³ has described the procedures to restore it to normal.

Median nerve damage during procedures that route a tendon through the carpal tunnel has long been considered a risk. Brandsma and Brand⁶ have shown that when the tendon is tunneled correctly through the carpal tunnel there is no increased risk of loss of median nerve function. There is sufficient space in the normal CT to accommodate one more tendon. If the tendon tunnel is passed close to the floor of tunnel posterior to all tendons, the risk of injury to the median nerve is minimal. If the

tip of tunneler is not fully closed the branches to the thenar muscles are at risk. The nerve should be carefully retracted towards the thumb to protect it because a medial retraction is likely to stretch the motor branch. Median nerve palsy detected in the early post-operative phase is likely to be due to direct injury to the nerve and there is a possibility of recovery in the coming 6 to 8 weeks. If the palsy is insidious, appearing after about 6 months or more, it is likely to be due to attrition of the nerve in the carpal tunnel.

Deviation of fingers to the radial or ulnar side post-operatively on fully opening the fingers may be seen. The potential causes are several. There may have been poor alignment of tendon slips in the proximal palm, imbalanced tension during insertions or there may be radial or ulnar guttering of extensor tendons. In pulley advancement procedures, too much excision of a pulley can cause drift due to off center pull of flexors. Radial drift may also develop because of an intrinsic plus due to excessive tension on transfers or intrinsic recovery (Fig. 22-4).

OPPONENSPLASTIES

In leprosy ulnar-median paralysis is more common than isolated median palsies. An overlooked web space contracture before surgery may prevent full abduction and pronation of the thumb.¹⁴

A common problem seen after surgery in cases who have ulnar-median palsy is recurrence of a thumb web contracture. Even in cases where the webspace has been restored by serial splinting pre-operatively the web contracture may recur.

Patients with long standing ulnar-median palsies tend to use key pinch for thumb function. This is done using the long extensor. With this adaptation the thumb web contracts. This

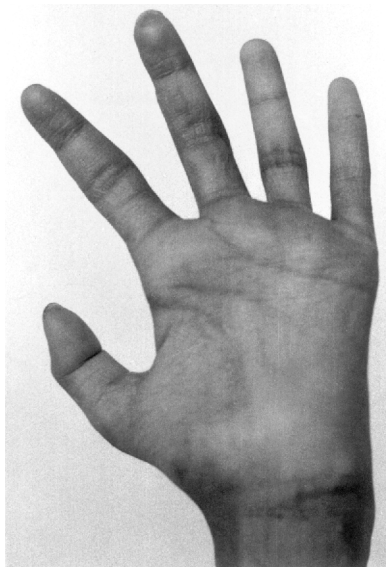


FIGURE 22-4 Post-operative radial deviation of fingers.

adaptive movement is difficult to correct with therapy, and is one of the important causes of failed surgery. This can be corrected by extensor pollicis longus re-routing (see Chapter 7 also for discussion of crankshaft deformity).

Migration of the pulley may adversely alter the mechanics of the transfer. Migration of the transfer anterior to MCP joint flexion axis leads to excessive MCP joint flexion whereas posterior migration leads to a Z-pinch with hyperextension of MCP joint (Fig. 22-5). The latter can be corrected by re-routing the tendon distal to the MCP joint, or by carrying out a MCP joint arthrodesis.

In extensor indicis opponensplasty there may be some extensor lag in the index finger and in some cases independent extension of the index finger is lost.

Subluxation of the CMC joint of the thumb may occur in ulnar median palsy and can prevent function of the opponensplasty. Overlooked contractures in trapezo-metacarpal joint may also render an opponensplasty ineffective (See Chapter 7).

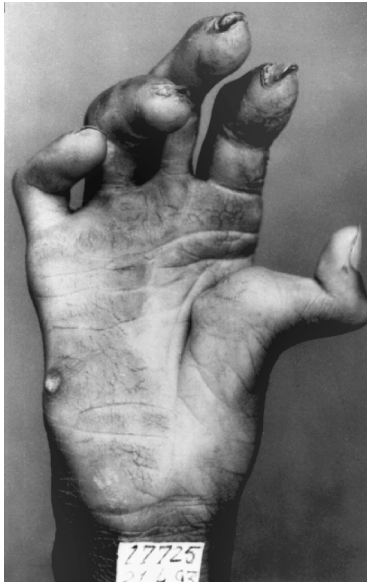

FIGURE 22-5 "Z" Pinch due to radial migration of transfer.

RADIAL NERVE PALSY RECONSTRUCTIONS

These are usually seen in association with ulnar and or ulnar-median nerve palsies. The accepted procedure for correction of wrist drop involves transfer of pronator teres to ECRB. Occasionally full wrist extension is not achieved. The excursion of pronator teres may be a limiting factor although it is more likely to be due to poor technique or adhesions. Wrist extension may be weak due to less tension in wrist dorsiflexors and patients may complain of poor grip.

High tension in the finger extensors may result in a weak grip.

One handed activity patterns are seen in cases who have unilateral palsies. Since the other hand is normal, patients start using the unaffected hand for most of their daily activities as they find it more convenient. Consequently, when the patient is expected to use the operated hand during rehabilitation, he fails to do so and the transferred muscle is unable to integrate itself into its new role. This

problem is more severe in persons in whom the non-dominant hand has been surgically corrected.¹⁶

DROP FOOT CORRECTION

These problems are covered in Chapter 14.

FACIAL SURGERY

Local procedures such as medial canthoplasty or tarsorrhaphy may be ineffective in controlling tearing and corneal exposure. A longer length of tarsorrhaphy not only looks unsightly but it also interferes with the temporal field of vision. An ineffective procedure on the medial side can be supplemented with a lateral procedure such as a lateral tarsal strip procedure. If local procedures fail to treat the lagophthalmos, a temporalis muscle transfer can be done.

Temporalis Muscle Transfer

1. Dynamic correction of lagophthalmos using temporalis musculofascial sling requires motivation on the part of patient.¹ Unwillingness to learn the use of transfer badly affects the result.
2. The transfer may be too loose in which case it can be tightened through a small incision at the lateral canthus. There may be a residual lag apparent only on lying supine as in sleeping. The eyes therefore need protection during sleep.
3. The transfer may be too tight with restriction of vision. In this situation the upper slip can be divided at the lateral canthus. Z-lengthening is usually ineffective.
4. The lachrymal sac may get injured while suturing the transferred slips at the medial angle of the eye leading to dacryocystitis.
5. Post-operatively ectropion can occur due to inferior migration of the lower slip. This can be corrected by exposing the entire lower

slip and holding it up beside the tarsal plate with prolene sutures which can be pulled out in ten days.

6. The muscle may leave a cosmetically unacceptable bulk at the side of the face.

Eyebrow Reconstruction

Restoration of eyebrows either with a skin graft or a skin flap can lead to subsequent problems. Loss of hair may occur and the reconstructed eyebrow may not look as convincing as it used to be immediately after surgery due to poor growth of the hairs. While suturing it is to be ensured that the graft lies on the orbicularis muscle bed and not on subcutaneous tissues. While defatting the graft the hair bulbs need to be carefully preserved. Patchy growth of hair in eye brows does not give a good cosmetic result. This can be remedied by rice-planting technique (see Chapter 20).

CONCLUSIONS

While reporting our results we often fail to mention possible pitfalls and assume that other clinicians will learn by their own observations and experience. It is essential that persons who want to undertake such surgery be forewarned so that they do not repeat avoidable errors. The chances for an undesirable result can generally be reduced by application of basic principles, careful assessment of a given patient, application of the dynamics of surgery and anticipation of the idiosyncrasies of each transfer. When unfavourable outcomes do occur they should be dealt with promptly with realistic reassurance of the patient.

REFERENCES

1. Antia NH: The temporalis musculofascial sling for correction of lagophthalmos. *Ind J Surg* 28:389-396, 1966
2. Antia NH: The palmaris longus motor for lumbrical replacement. *The Hand* 1:139-145, 1969
3. Antia NH, Pandya NJ: Surgical correction of nasal deformities in leprosy: A 16-year review. *Plast Reconstr Surg* 60:768-777, 1977
4. Brand PW: Paralytic claw hand. *J Bone Joint Surg* 40-B: 618-632, 1958
5. Brand PW: Tendon grafting: Illustrated by a new operation for intrinsic paralysis of the fingers. *J Bone Joint Surg* 43-B:444-453, 1961
6. Brandsma JW, Brand PW: Median nerve function after tendon transfer for ulnar paralysis. *J Hand Surg* 10-B:30-32, 1985
7. Brandsma JW, Ottenhoff de Jonge. Flexor digitorum superficialis tendons transfer for intrinsic replacement. Long term results and defects on donor fingers. *J Hand Surg* 17B:625-628, 1992
8. Brandsma JW, Brand PW: Claw finger correction: Considerations in the choice of technique. *J Hand Surg* 17B:615-621, 1995
9. Burkhalter WE: Complications of tendon transfers for nerve paralysis in the hand. pp 60-69. In Boswick JA (ed): *Complications of Hand Surgery* 1st Ed. WB Saunders, Philadelphia, 1986
10. Husain S, Mishra B, Malaviya GN: Rifampicin and Isoniazid in the treatment of leprosy nerve abscess. *Acta Leprologica* 10:199-201, 1997
11. Kulkarni, VN, Mehta, JM: Observations of tarsal disintegration in the cases operated for foot drop. *Ind J Lepr* 57:598-600, 1985
12. Littler JW: Tendon transfers and arthrodesis in combined median and ulnar paralysis. *J Bone Joint Surg*.31-A: 225-234, 1949
13. Malaviya GN: Present trends in correction of claw fingers in leprosy. *Euro J Plast Surg* 13:115-118, 1990
14. Malaviya GN: Restoration of abduction opposition of thumb with reference to leprosy palsy. *Euro J Plast Surg* 13:120-125, 1991
15. Malaviya GN, Husain S: Correction of mild and moderately collapsed nose in leprosy patients using a second metatarsal cortico-periosteal bone graft -II, Long term follow-up results. *Euro J Plast Surg* 18:114-117, 1994
16. Malaviya, GN: Unfavourable results after claw finger correction surgery as seen in leprosy. *Ind J Lepr* 69:43-52, 1997
17. Malaviya, GN: Median nerve palsy following claw finger correction in leprosy: effect of M. leprae or a consequence of surgery. *Ind J Lepr* 74:217-220, 2002

18. North ER, Littler, JW: Transferring the flexor superficialis tendon. Technical considerations in the prevention of proximal interphalangeal joint disability. *J Hand Surg* 5:498-501, 1980
19. Palande DD: Correction of paralytic claw fingers in leprosy by capsulorrhaphy and pulley advancement. *J Bone Joint Surg* 65-A:514-521, 1976
20. Palande DD: Correction of intrinsic minus hands with reversal of transverse metacarpal arch. *J Bone Joint Surg* 58-A:59-66, 1983
21. Palande DD: Surgical correction of intrinsic minus fingers. *Ind J Lepr* 58:537-542, 1986
22. Ramnathan U, Malaviya GN, Jain N, Husain, S: Psychosocial aspects of deformed leprosy patients undergoing surgical correction. *Lepr Review* 62:402-410, 1991
23. Ranney DA: Restoration of hypothenar muscle function in ulnar nerve paralysis. *Lepr Rev* 44:196-202, 1973
24. Ranney DA: The Superficialis minus deformity and its treatment. *The Hand* 8:209-214, 1976
25. Reddy NR, Kolumban SL: Effects on fingers of leprosy patients having removal of sublimis tendons. *Lepr India* 53:594-599, 1981
26. Rydevik B, Lundborg G, Nordborg C: Intra-neural tissue reaction induced by internal neurolysis. *Scand J Plast Reconstr Surg.* 10:3-8, 1976
27. Selvapandian AJ: Surgical correction of foot drop. pp 330-339. In McDowell F, Enna CD (eds): *Surgical rehabilitation in leprosy.* Williams and Wilkins, Baltimore, 1974
28. Srinivasan H: Extensor Diversion -A new approach in correction of intrinsic minus fingers. *J Bone Joint Surg* 55-B:58-65, 1973
29. Srinivasan H: Dermadesis and flexor pulley advancement. First report on a simpler operation for correction of paralytic claw fingers in patients with leprosy. *J Hand Surg* 10:979-982, 1985